Spinal Deformities

The Essentials

Robert F. Heary
Todd J. Albert

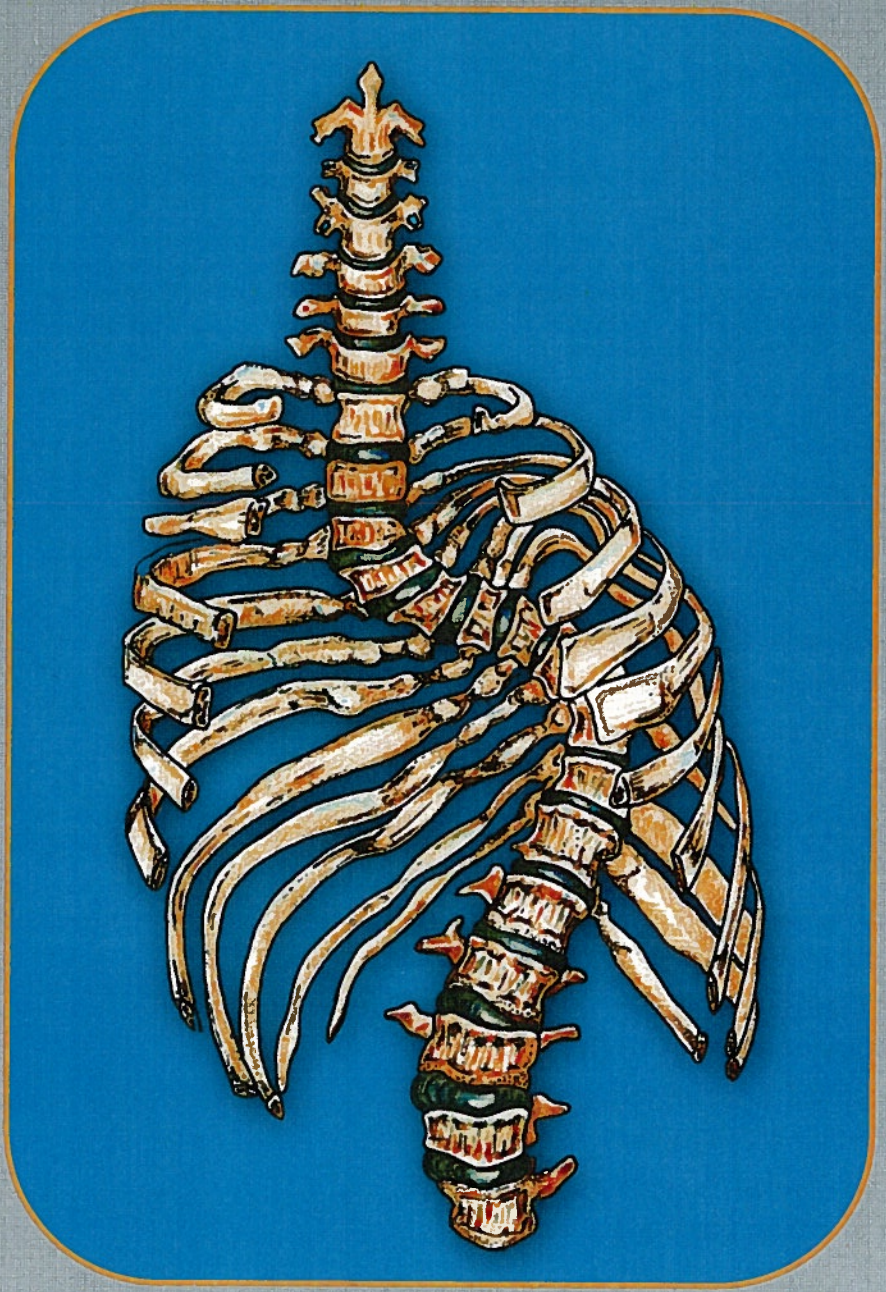

Thieme

Contents

Foreword ix
Edward C. Benzel
Foreword xi
James W. Ogilvie
Preface xiii
Contributors xv

Section I Principles of Spinal Deformities 1
Chapter 1 Overview of Spinal Deformity 3
Robert F. Heary
Chapter 2 Imaging Modalities for Spinal Deformities 12
Daniel K. Resnick and John Sandin III
Chapter 3 Anesthesia in Spinal Deformity Surgery 19
Jolie Narang and Ellise Delphin
Chapter 4 Intraoperative Neuromonitoring in Spinal Deformity Surgery 29
Daniel M. Schwartz and Anthony K. Sestokas
Chapter 5 Anatomical Variants with Spinal Deformity 38
Christopher M. Bono and William Accousti
Chapter 6 The Lenke Classification System for Adolescent Idiopathic Scoliosis 45
R. Shay Bess and Lawrence G. Lenke
Chapter 7 Principles of Sagittal Plane Deformity 59
Stephen L. Ondra and Shaden Marzouk
Chapter 8 Principles of Coronal Plane Deformity 66
Moe R. Lim, Joon Y. Lee, and Todd J. Albert

Chapter 9 Flexible versus Fixed Spinal Deformity 76
Sumon Bhattacharjee, Rod J. Oskouian Jr., and Christopher I. Shaffrey

Chapter 10 General Medical Issues in Spinal Deformity 88
Paul K. Kim and Joseph T. Alexander

Chapter 11 Natural History of Spinal Deformity 94
John E. Lonstein and Amir A. Mehbod

Section II Treatment of Spinal Deformities 99

Chapter 12 Congenital Scoliosis 101
Robert B. Winter

Chapter 13 Infantile Scoliosis 113
Michael T. Rohmiller and Behrooz A. Akbarnia

Chapter 14 Neuromuscular Scoliosis 124
John P. Lubicky

Chapter 15 Anterior Surgery for Thoracic Scoliosis 144
Randal R. Betz, Peter O. Newton, Linda P. D'Andrea, David H. Clements III, and Harsh Grewal

Chapter 16 Posterior Surgery for Thoracic Scoliosis 154
Yongjung J. Kim and Lawrence G. Lenke

Chapter 17 Anterior/Posterior (AP) Surgery for Spinal Deformity 171
Keith Synnott and Bernard A. Rawlins

Chapter 18 Anterior Surgery for Adolescent Thoracolumbar and Lumbar Scoliosis 178
Timothy R. Kuklo and Brett A. Freedman

Chapter 19 Scheuermann's Kyphosis 192
Suken A. Shah

Chapter 20 Technological Advances in Spinal Deformity Surgery 206
Max C. Lee and Daniel H. Kim

Chapter 21 Surgery for Adult Spinal Deformity 217
John P. Kostuik, D. Greg Anderson, and Khaled M. Kebaish

Chapter 22 Osteotomies and Vertebral Column Resections for Complex Spinal Deformities 230
Elias C. Papadopoulos and Oheneba Boachie-Adjei

Chapter 23 Adult Spinal Deformity Revision Surgery 240
Keith H. Bridwell

Chapter 24 Surgical Treatment of Spondylolisthesis 249
Ronald L. DeWald and Christopher J. DeWald

Chapter 25 Prevention and Treatment of Post-traumatic Deformity of the Thoracolumbar Spine 261
Ahmad N. Nassr, Kern Singh, David W. Wimberley, and Alexander R. Vaccaro

Chapter 26 Bracing and Nonoperative Treatment of Spinal Deformity 270
Christopher M. Bono

Index 279

Section I

Principles of Spinal Deformities

Chapter 1

Overview of Spinal Deformity

Robert F. Heary

Spinal deformity is a complex and dynamic process that occurs in both the sagittal and coronal planes of the thoracolumbar spine. Successful treatment is aimed at achieving satisfactory balance in both of these planes. The spinal curvatures in adult deformity differ greatly from those in adolescent deformity. As a general rule, the curves in adults tend to be stiffer, whereas the adolescent curves are more flexible. In addition to cosmetic concerns, adult patients frequently present with pain and neurologic symptoms. Adolescents usually do not have this degree of pain or neurologic symptoms. Deformity surgeries tend to be complex procedures with high rates of operative and perioperative complications. The goals of deformity surgery are to obtain a solid fusion with a balanced spine, to relieve pain, and to prevent further deformity. A secondary goal is to achieve curve correction and in so doing to improve the cosmetic appearance.

The first reported record of scoliosis was by Hippocrates. In ancient times, traction was attempted, unsuccessfully, to correct scoliotic deformity. In the 16th century, Ambroise Pare is credited with describing the first use of bracing to treat scoliosis. Pare used an iron corset to attempt to correct coronal plane deformity.

In 1962, Harrington reported the first successful use of spinal implants in the correction of scoliosis.[1] As such, the modern era of deformity correction with spinal instrumentation began. The Scoliosis Research Society, the oldest formal spine society, was established in 1966. Initially, spinal deformity correction was performed solely by orthopaedic surgeons. The early phases of deformity correction predominantly focused on correction of coronal plane scoliotic curvatures using distraction. Over time, it has become apparent that correcting coronal deformity with pure distractive mechanisms leads to an imbalance in the sagittal plane and the development of "flat-back" deformity.[2,3]

Spinal deformity consists of coronal plane deformations referred to as scoliosis and sagittal plane deformations that usually result in kyphosis. There is a dynamic process in the interaction between coronal and sagittal plane curvatures. Adult spinal deformity presents as curvatures that were present prior to skeletal maturity, which are termed persistent idiopathic curvatures, and curvatures arising later in life, as a result of degenerative changes.[4] As a general rule, larger curves are generally less flexible than smaller curves.[5,6]

Prior to treating spinal deformity, it is essential to have an understanding of the natural history of untreated spinal curvatures. In a landmark study published by Weinstein and Ponseti, the natural history of scoliotic curvatures was determined with a mean follow-up period of 40 years. These authors determined that 68% of adolescent idiopathic curvatures progressed beyond skeletal maturity. Thoracic curvatures greater than 50 degrees progressed at an average of 1 degree per year, thoracolumbar curves progressed 0.5 degrees per year, and lumbar curves progressed 0.24 degrees per year. Thoracic curvatures of less than 30 degrees tended not to progress.[7] Moe and Lonstein have estimated that there are 500,000 adults in the United States with curvatures exceeding 30 degrees.[8]

Significant differences are present between the curves affecting adolescents and adults. The presenting symptoms in adolescents are typically curve progression and cosmesis rather than pain.[5,6,9,10] On the other hand, adults tend to present with pain and neurologic abnormalities. Curve progression and cosmetic issues tend to be less problematic in the adult population.[5,6,9,11] In addition, adult patients are more likely to be anxious and depressed regarding their deformity.[9] Axial pain and radicular pain are characteristic of adult deformity and much less frequent in adolescents.[5,6] Adult deformity tends to be more rigid than curvatures of adolescents, and therefore, the surgical correction of these curves is more difficult.[4–6,12] Accordingly, higher complication rates have routinely been reported in the correction of adult deformity.[4,6,11] The successful treatment of deformity combined with pain, typically present in adults, is more challenging than the treatment of adolescent patients with idiopathic scoliosis.[10] With adult

curvatures, due to the rigidity of these curves, there is often the need to perform a release procedure followed by curve correction. Adolescent curvatures, which tend to be more flexible, can often be treated with curve correction procedures from either a single anterior or posterior approach. Whereas bracing may have a role in modifying curve progression in adolescents, there is no therapeutic role for bracing in altering curve progression in adults.[11] The etiology of pain produced in adult deformity is a combination of muscle fatigue, trunk imbalance, facet arthropathy, and degenerative disk disease.[11]

The primary treatment goals of spinal deformity are to halt deformity progression, relieve pain, and improve function. The operative treatment goals include obtaining a solid fusion with a balanced three-dimensional spine as well as to prevent further deformity.[10] The amount of curve correction obtained in adult patients is less important than producing a stable, balanced, and pain-free spine.[11,12] The ultimate goal in deformity correction is to obtain a balanced spine in both the sagittal and coronal planes. Takahashi et al. compared adult patients over the age of 50 years with younger adult patients. They found that the radiographic results were less satisfactory in the older patients; however, pain relief was more reliable when compared with the younger adults with deformity.[6]

The surgical treatment of patients with spinal deformity is a major undertaking. Over the past two decades, spine surgeons from the disciplines of both orthopaedic surgery and neurologic surgery have made increasing advances in the evaluation and treatment of patients with spinal deformity. It is important to recognize that some patients with spinal deformity are not fit to undergo the extensive surgery often required for surgical correction. As a result, some patients with spinal deformity are best served with conservative, or palliative, treatment with methods such as exercises, braces, and medications.

♦ Spinal Deformity Terms and Principles

As with all medical disciplines, a unique set of terms are applicable to spinal deformity. Specific terms are used to describe vertebrae, angles, lines, and curves. The end vertebra is the most cephalad and most caudal vertebra of a curve for the curve's inflection point **(Fig. 1–1)**. This applies to measurements made in both the coronal and sagittal planes. A neutral vertebra is defined as having symmetric pedicles on a standing

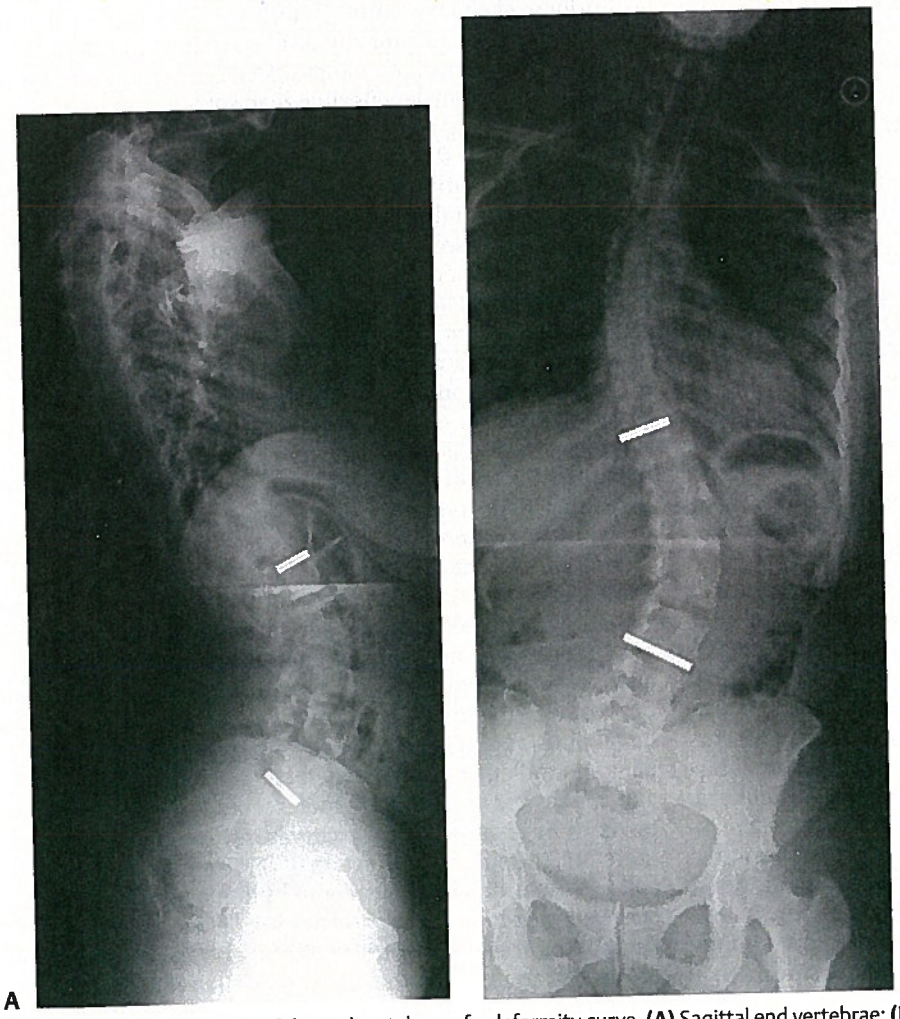

Figure 1–1 Demonstration of the end vertebrae of a deformity curve. **(A)** Sagittal end vertebrae; **(B)** coronal end vertebrae.

posterior/anterior (PA) radiograph **(Fig. 1–2)**. The central sacral line is determined by first drawing a line connecting the superior-most aspects of the iliac crests. A perpendicular drawn from the midpoint of the S1 vertebra superiorly defines the central sacral line. The vertebra that is intersected at its midpoint by the central sacral line is referred to as the stable vertebra **(Fig. 1–3)**. Many surgeons use the concepts of the stable vertebra and the neutral vertebra when determining which level to include in spinal stabilization constructs.

Plumb lines are used to determine coronal and sagittal balance. In the coronal plane, a plumb line is drawn from the center of the C7 vertebra to the center of the sacrum in a spine with normal alignment. Emami et al. have defined greater than 25 mm of deviation between C7 and the sacrum as evidence of coronal decompensation.[2] In the sagittal plane, a line drawn from the center of the C7 vertebra should intersect the S1 vertebra on a standing 36″ lateral radiograph.[2,13,14] Because of its readily identifiable location on lateral radiographs Eck et al. have defined sagittal plane variations with respect to the anterior-most aspect of the S1 vertebra.[14] Other authors have stated a plumb line from the center portion of the C7 vertebra should intersect the posterior-most aspect of the S1 vertebra.[2,13] A deviation of greater than 40 mm has been defined as sagittal decompensation.[2] By convention, when the C7 sagittal plumb line is anteriorly displaced, a positive value is assigned. A negative value is given for posterior displacements of the C7 sagittal plumb line **(Fig. 1–4)**. With respect to naming of curves, a structural curve is a curve that does not demonstrate normal mobility on lateral bending radiographs. A nonstructural, or compensatory curve, is a flexible portion of a curve with normal mobility on lateral bending films **(Fig. 1–5)**. This is typically present either above or below a structural curve. In the naming of coronal plane curvatures, the location of the convex portion of the curve determines its name. For example, a curve that has a convexity on the right side may be referred to as a dextroscoliosis, whereas a curve convexity on the left side is a levoscoliosis.

Skeletal maturity is that point where no further longitudinal bone growth occurs. This typically occurs during adolescence. Female patients tend to achieve skeletal maturity at an earlier age than male patients. As a general rule, female patients will reliably achieve skeletal maturity by 18 months after the onset of menarche. Numerous grading scales are available for determining skeletal maturity in adolescent patients. Adult deformity refers to curvatures present in patients after skeletal maturity has been achieved.

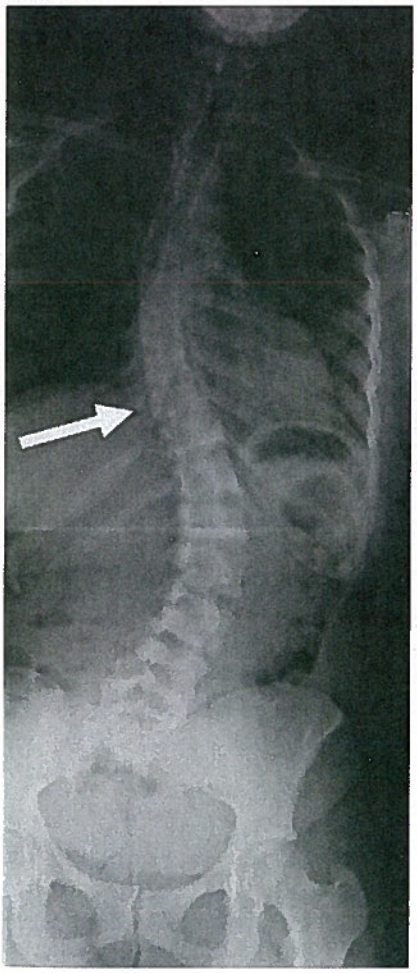

Figure 1–2 Identification of the neutral vertebra in a coronal plane deformity curve. The T10 vertebra is the neutral vertebra (*arrow*).

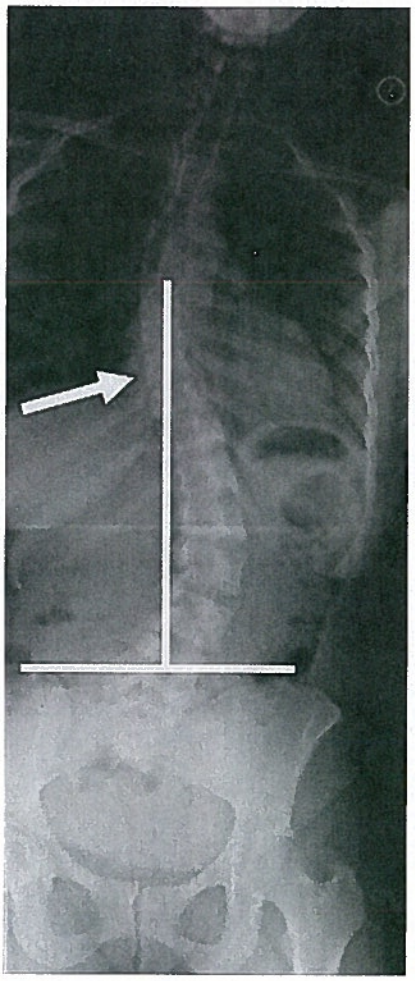

Figure 1–3 Identification of the central sacral line and the stable vertebra in a coronal plane deformity curve. The T9 vertebra is the stable vertebra (*arrow*).

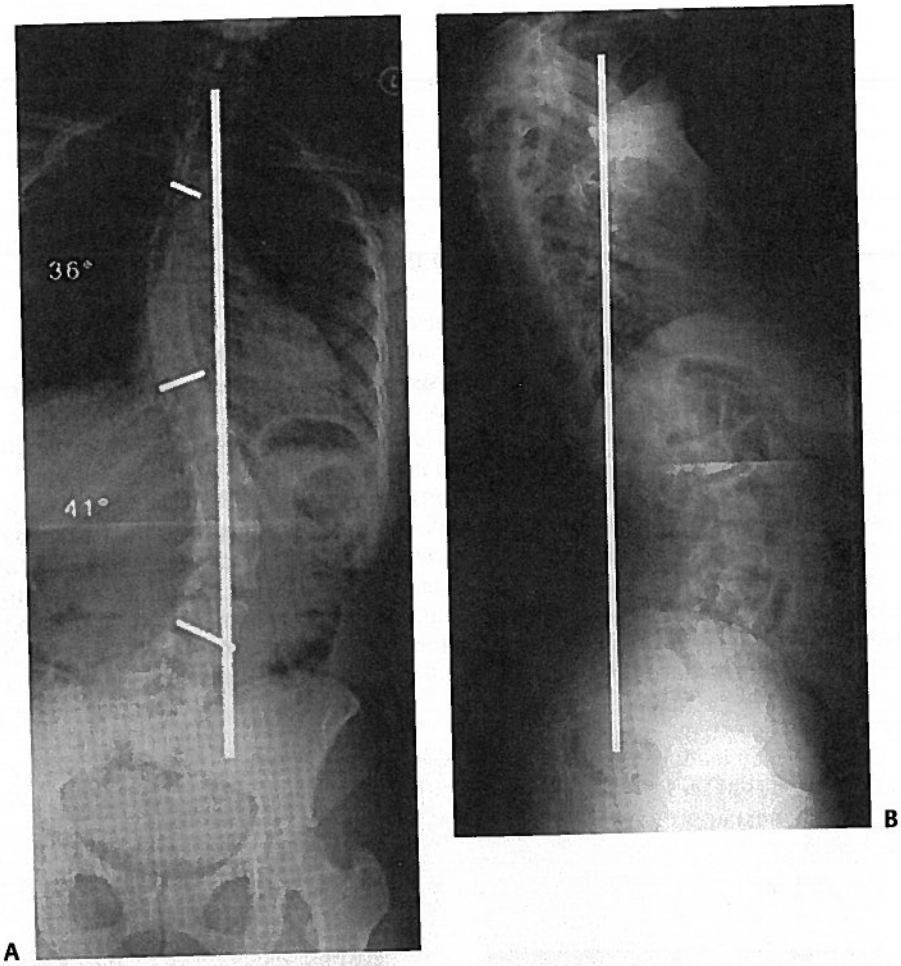

Figure 1–4 A 29-year-old female with previously untreated scoliosis developed progressive back pain with leaning to her left side. Plumb lines drawn on 36″ standing posterior/anterior (PA) and lateral radiographs obtained with the patient's hips and knees extended. **(A)** Coronal view shows C7 to be 44 mm to the left of the center of the sacrum; radiograph demonstrates a right thoracic dextroscoliosis (36 degrees) and a left thoracolumbar levoscoliosis (41 degrees). **(B)** Sagittal view shows the vertical plumb line to be 38 mm dorsal to the posterior aspect of the L5-S1 interspace (by convention, kyphotic angulations are assigned a positive (+) value and lordotic angulations are assigned a negative (−) value; this curve measures −38 mm).

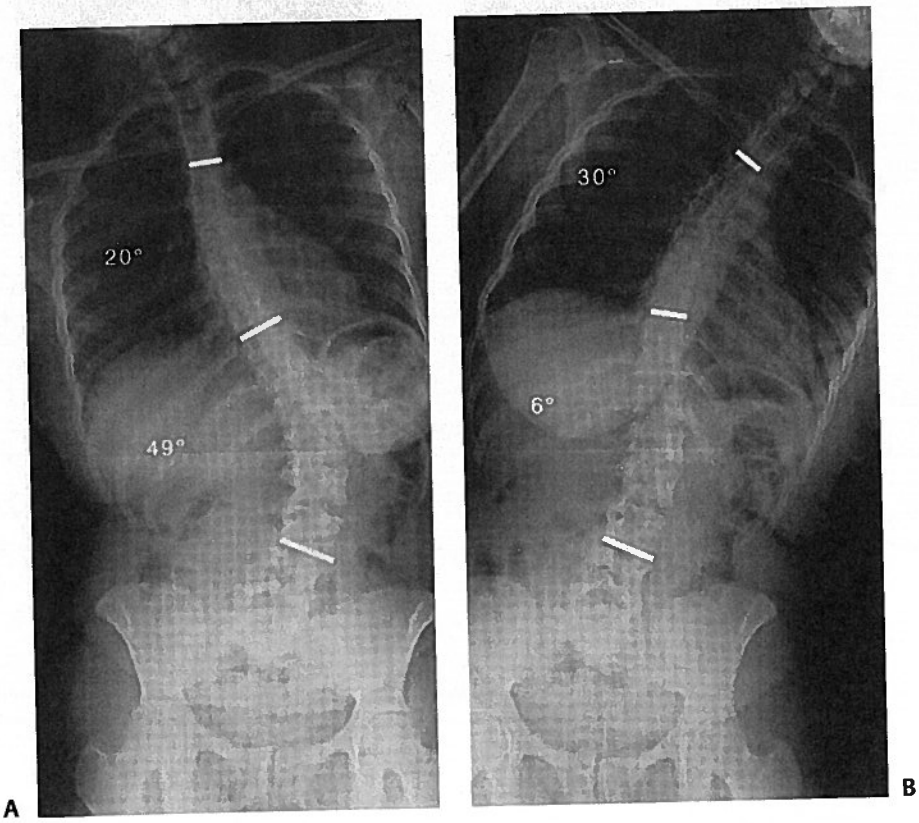

Figure 1–5 Right and left lateral 36″ bending views demonstrate curve flexibility. **(A)** On right bending, the thoracic dextroscoliosis corrects to 20 degrees (T4 to T10 levels). **(B)** On left bending, the thoracolumbar levoscoliosis corrects to 6 degrees (T10 to L3 levels).

Deformity correction procedures, which relied on pure distractive forces, have been recognized to place the C7 vertebra in a positive sagittal location with respect to the sacrum. Doherty first described this phenomenon as "flat-back" syndrome in 1973.[15] Smith has described flat-back syndrome as the symptomatic loss of sagittal plane balance secondary to a loss of normal lumbar lordosis. Symptoms of flat-back syndrome include pain and the need to bend the knees to maintain an upright position.[3] In patients with flat-back, a lumbar lordosis of less than 30 degrees will be associated with anterior decompensation of the spine.[2] Recognition of this flat-back syndrome has led to the development of segmental instrumentation in an attempt to prevent the development of this painful deformity condition.

When sagittal decompensation occurs, there is a need to extend the hips and flex the knees to center the head over the sacrum in a sagittal plane.[3,13] Bernhardt and Bridwell analyzed sagittal plane alignment in normal patients without evidence of deformity. They found average values of thoracic kyphosis measure 36 degrees and of lumbar lordosis measure 44 degrees.[16] Significant variations do occur among normal, nondeformed, patients. In the lumbar spine, 67% of the total lumbar lordosis occurs at the L4-L5 and L5-S1 levels.[16] Recognition of this fact has led many surgeons to attempt to limit the caudal extent of surgical correction to the L4 level. In so doing, preservation of motion at the two lowest segments allows for compensatory mechanisms that are advantageous in preventing sagittal plane imbalance. An overreliance on motion preservation at the L4-L5 and L5-S1 levels may lead to accelerated degeneration of the disks and facet joints at these levels. As such, there is much debate about the most appropriate caudal level at which to end spinal fusions.

General goals in deformity correction include attempting to align the T1 and L1 vertebra with the central sacral line in the coronal plane. Additional goals include attempting to align the T1, L1, and S1 vertebra in the sagittal plane. In patients with double curves, this may not be feasible. Obtaining balance in both the sagittal and coronal planes is the principle goal of deformity correction **(Figs. 1–6 and 1–7)**.

♦ Evaluation of the Spinal Deformity Patient

A detailed history and physical examination is essential in the evaluation of a deformity patient. An emphasis must be placed on the overall general health of the patient to

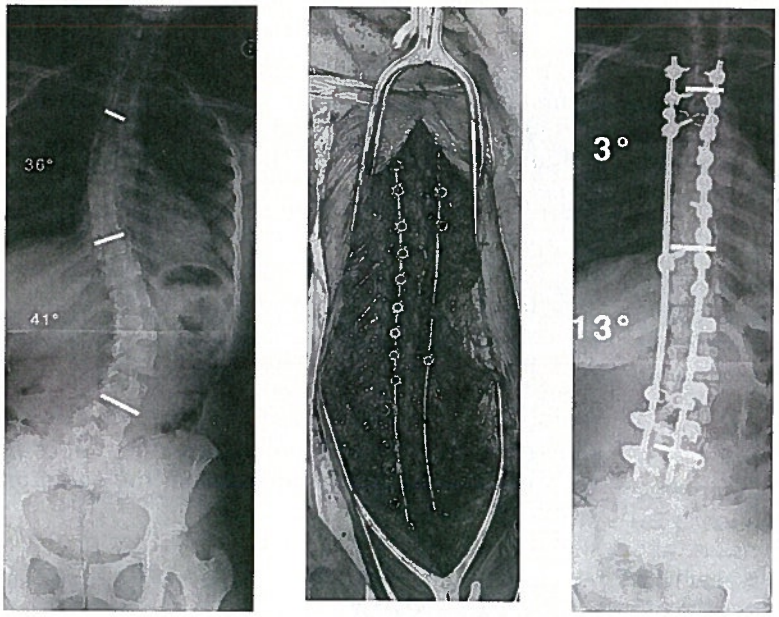

A–C

Figure 1–6 Preoperative **(A)**, intraoperative **(B)**, and postoperative **(C)** views. Intraoperative photograph demonstrates surgical correction using segmental instrumentation from T3 to L4 levels via a posterior only approach. Pedicle screws were used at each vertebral level on the left side and selectively on the right side. Postoperative 36″ standing PA radiograph demonstrates correction of the thoracic curve to 3 degrees, and the thoracolumbar junction curve has been corrected to 13 degrees. Coronal balance is restored.

Figure 1–7 Postoperative 36″ standing lateral radiographs demonstrate preservation of sagittal alignment. The patient was pain free with subjective improvement in her balance, and she no longer had the sensation of leaning.

determine whether he or she will be fit for a major surgical procedure. Historical information focusing on pulmonary function, cardiac function, and bone quality are mandatory. The physical examination begins with a detailed neurologic exam including analysis of motor and sensory modalities. Reflexes, both deep tendon and cutaneous, should be assessed. The presence of long tract signs, upper motor neuron findings indicating spinal cord dysfunction, should be documented.

Physical examination findings specific to spinal deformity patients should also be assessed. The patient is examined in the standing position from both a frontal and lateral vantage point, from posteriorly with forward bending from the waist, and in the prone position. The relative heights of the iliac crests, the shoulders, and the presence or absence of a rib hump should be recorded with notation made of any discrepancies. Coronal plane decompensation is determined by placement of the C7-gluteal plumb line. This is determined by dropping a perpendicular measuring device from the C7 level and recording its location with respect to displacement from the center of the sacrum, which can be approximated as the location of the gluteal cleft. Sagittal plane decompensation is determined by dropping a line from the external meatus of the ears downward with the patient's hips and knees extended. In a patient with normal sagittal balance, this line should intersect the greater trochanter of the femur. Deviations from this location are recorded.

Radiographic imaging studies are essential to the evaluation of the spinal deformity patient. The standard plain film radiograph images include a 36″ by 14″ standing x-ray performed in the PA and lateral views. These x-rays are obtained from 72″ away from the patient and must be obtained with the hips and knees fully extended to accurately assess coronal and sagittal balance.[2,3,5,11,13,14] Lateral bending views on 36″ films are also valuable adjuncts in the evaluation.[5,11] The determination of curve flexibility is important in the preoperative evaluation.[5] Lateral flexion and extension views are also beneficial in the initial assessment. This is particularly the case with curves that involve the lumbar spine. If neurologic findings are present, a magnetic resonance (MR) image is indicated.[11] In patients who are unable to undergo MR imaging, a myelogram with a post-myelogram computed tomography (CT) scan may be used as a substitute. Dual-energy x-ray absorptiometry (DEXA) allows for an assessment of bone density. This study is particularly useful in adult deformity patients who may have diminished bone stock. Diskography is not overly valuable in the evaluation of the spinal deformity patient.

In nearly all deformity patients, a trial of conservative treatment is indicated prior to consideration of surgical intervention.[4,11,14] Conservative treatment regimens are valuable in optimizing the patient's conditioning in preparation for surgery. The patient should be encouraged to strive to achieve an ideal body weight, which oftentimes includes a weight-loss regimen. This weight control may be useful at the time of surgery as well as in the postoperative period. As smoking is known to worsen fusion results, a smoking cessation program should be completed by all patients who are smokers prior to any spinal fusion surgeries. Physical therapy is an integral part of conservative treatment, and in most deformity patients, this will focus on the use of extension-based exercises.[3] Patients with a significant spondylolisthesis may be unable to perform extension-based exercises and are more appropriately given a flexion-based regimen. Diagnostic and therapeutic use of injections including nerve root blocks, facet injections, and epidural injections may be valuable in the adult deformity patient evaluation.[11]

The most important determination in the evaluation of a spinal deformity patient is whether the patient has an adequate level of fitness to undergo major reconstructive surgery. Additionally, the expectations of the patient for the surgical procedure must be reasonable. Likewise, the expectations of the surgeon must be within reason. Overall satisfaction with a spinal deformity surgery will be directly related to realistic and reasonable expectations on the part of both the surgeon and the patient.

♦ Indications for Adult Spinal Deformity Surgery

The most common indication for adult spinal deformity surgery is significant curve-related pain. This may be axial back pain, radicular pain, or a combination.[4] The presence of documented curve progression and spinal decompensation are also indications.[4,14] Korovessis et al. have analyzed risk factors for progression of lumbar curves. They determined that curves greater than 30 degrees, greater than a 33% apical vertebral rotation, greater than 6 mm of lateral listhesis, and poor seating of the L5 vertebra on the S1 vertebra are risk factors for curve progression in the lumbar spine.[17] Although not as common as is seen in the adolescent population, the presence of significant deformity that is unacceptable to the adult patient can be an indication for surgery.[11] In the adolescent population, curve progression and cosmesis are the most common indications for deformity surgery. Finally, the presence of pulmonary compromise has been suggested as an indication for deformity surgery.[4,11] In reality, for curves less than 90 degrees in the coronal plane, pulmonary compromise rarely occurs as a result of spinal deformity. Bake et al. performed a 20-year follow-up study of lung function in adult idiopathic scoliosis patients. They found that untreated adult scoliosis patients showed no difference in pulmonary function compared with normal changes resulting from the aging process alone.[18]

♦ Operative Treatments

These will be discussed throughout this textbook. Specific details for the assorted conditions are included in each chapter.

♦ Postoperative Considerations

Upon arrival to the recovery room, an immediate neurologic evaluation is completed and plain film portable radiographs are obtained. If neurologic deterioration has occurred, consideration for an immediate return to the operating room to remove all hardware should be entertained.[2] This is particularly true if any concern existed about the possibility of overdistraction with a potential stretching of the spinal cord. Evoked potential monitoring, performed intraoperatively, will usually be able to alert the surgeon of this event prior to leaving the operating room. Alternatively, if no change in evoked potentials occurred during the surgery, an immediate advanced neuroimaging study, such as an MRI or a CT-myelogram, may be obtained to rule out mechanical spinal cord compression.

Thromboembolic stockings and sequential compression devices are continued throughout the postoperative period, and early aggressive respiratory treatment is administered.[11] The use of patient-controlled analgesia is beneficial for maintaining patient comfort. Physical therapy is begun in the early postoperative period. After suction drains are removed, on approximately the third postoperative day, we routinely obtain CT scan examinations to allow for an accurate assessment of the location of all spinal implants as well as to assess the sagittal and coronal balance.[19] A custom-fitted thoracolumbosacral orthosis (TLSO). Brace may be worn for 3 months postoperatively. After the TLSO brace has been fitted, standing 36″ plain film radiographs are obtained to assess sagittal and coronal alignment. Nonsteroidal anti-inflammatory drugs are avoided in the postoperative period, as Dimar et al. have demonstrated adverse affects on spinal fusions with the use of these agents.[20] Postoperative intravenous antibiotics are typically maintained until the suction drains have been removed.

Enteral nutrition is begun as soon as possible postoperatively. If patients are unable to receive enteral nutrition in the immediate postoperative period, consideration for administration of hyperalimentation should be raised. Emami et al. demonstrated a benefit to using hyperalimentation with staged surgical procedures.[2] Similarly, Lapp et al. found that postoperative total parenteral nutrition led to fewer complications and less postoperative nutritional depletion in patients with staged surgical procedures.[21] If evidence of a deep vein thrombosis or pulmonary embolus is detected, placement of a Greenfield filter is preferable to systemic anticoagulation in the early postoperative period. Routine clinical and radiographic follow-up, including 36″ standing PA and lateral radiographs, are obtained at 6 weeks, 3 and 6 months, and 1 and 2 years. Additional follow-up evaluations may be added as deemed necessary.

♦ Results and Complications

In spinal deformity surgery, it is neither practical nor feasible to attempt to separate results from complications. These two categories are directly comingled. The ultimate determination of success with deformity surgery is patient satisfaction. Bradford et al. have stated that overall patient satisfaction is ~90% in adult deformity surgery.[11] Using the Scoliosis Research Society's outcome measurement tool, numerous investigators have determined that patients are somewhat or extremely satisfied with their outcome between 76% and 92% of the time.[2,13,22,23] An additional valuable assessment of patient satisfaction is the determination of whether a patient would undergo the same treatment again for the same result. Again using the Scoliosis Research Society's outcomes tool, the percentage of patients who would undergo the same treatment again varies between 74% and 92%.[2,13,22] Albert et al. evaluated adult patients who had undergone deformity surgery using the SF-36 outcomes measurement tool. The SF-36 is a validated outcomes tool that is not specific for spinal surgery. In their review, they found that there was a statistically significant increase in physical function, social function, pain relief, and perceived health in adult patients after deformity surgery.[24] Dickson et al. compared outcome results with adult scoliosis patients treated surgically versus a second group treated with nonsurgical care. These investigators demonstrated a significant decrease in pain and fatigue in the surgically treated group.[25] Pain is seldom totally relieved after an adult deformity surgery.[6,11] As evidenced with generally good long-term patient satisfaction outcomes, substantial improvement of the preoperative pain is frequently appreciated.

The determination of a successful fusion after deformity surgery is extremely difficult. The presence of spinal implants often impedes an accurate radiographic evaluation of fusion. The gold standard for determining successful spinal fusion has traditionally been direct operative inspection. The exploration of a major deformity surgery has significant morbidity in and of itself, and as such, operative reexploration is usually reserved for patients with a high degree of suspicion for a pseudarthrosis. Even the results of direct operative inspection can be flawed. Deckey et al. found that the intraoperative appearance of a solid fusion may be erroneous. They found four patients (14% of their study group) whose operative inspection appeared to demonstrate a solid fusion but who were subsequently determined to have had a pseudarthrosis.[26]

Postoperative radiographic imaging can provide direct or indirect evidence of a failed fusion or a pseudarthrosis. The presence of implant breakage or a curve progression of greater than 5 degrees in the postoperative follow-up period is highly suggestive indirect evidence of a pseudarthrosis. Although it is infrequently observed, direct radiographic evidence of a pseudarthrosis is the presence of a lucent line traversing a fusion mass. As with many forms of spinal surgery, it is likely that spine surgeons underestimate the true pseudarthrosis rate in deformity surgery. Because indirect radiographic evidence of a pseudarthrosis is the most commonly used method of detecting fusion failure, it is probable that some instances of pseudarthrosis are overlooked. The clinical significance of this is unclear. Because the goals of adult deformity surgery *are* to achieve a balanced spine, pain relief, and no progression of deformity, if these goals are achieved, patient satisfaction will be high regardless of the actual fusion success rate.

Curve correction measurements postoperatively in adult deformity patients tend to be less than those achieved with adolescent deformity corrections. In adults, curve correction percentages typically vary between 34% and 43% for coronal plane correction.[2,22] These values translate to between 20 degrees and 26 degrees of correction. As the curves in adult patients are typically more rigid, lesser degrees of curve correction are acceptable. Overcorrection of a coronal curve can lead to sagittal plane decompensation and a poor patient outcome. As has been previously stated, the goal of adult deformity surgery is to achieve a balanced spine rather than an absolute amount of curve correction.

Complication rates in spinal deformity surgery are high. Overall complication rates are ~33%.[2,6] Because of the presence of more rigid curves and the presence of more medical comorbidities, complication rates are higher in adults than in adolescents undergoing deformity surgery.[4–6,10–12] Lapp et al. found a statistically significant increase in complication rates in smokers when compared with nonsmokers.[21]

Complications can typically be divided into those that occur early versus late complications. Early complications occur in the first month and include the development of postoperative neurologic deterioration, which occurs in 2% of patients.[2,22,27] Postoperative wound infections may be either superficial or deep. Deep wound infection rates vary between 1% and 8% and require surgical revision.[2,11] Perioperative mortality is fortunately rare; however, Lapp et. al. reported a 2% death rate.[27] Other complications that may be observed in the early postoperative period include dural tear with cerebral spinal fluid (CSF) leak, deep vein thrombosis and pulmonary embolus, urinary tract infection, pneumonia, and an assortment of cardiovascular sequelae due to the significant fluid shifts that occur in the perioperative period.

Late complications are events that generally occur 1 month or more from the time of surgery. Pseudarthrosis has already been discussed. Pseudarthrosis may manifest itself as fusion failure or implant failure, curve progression, or a clinically worsening pain syndrome. Implant prominence may occur after posterior instrumentation in thin patients.[28,29] In these scenarios, consideration for removal of the spinal implants is often entertained. Spinal implant removal has its own morbidity, and Deckey et al. found that removal of long spinal posterior instrumentation in adults led to a loss of correction, to pain, and to further surgery in an unacceptable percentage of patients.[26] Late complications may also occur above or below the actual instrumented segment. Junctional kyphosis typically occurs immediately cephalad to an instrumented spinal fusion. This has been documented in 2% of adult deformity patients.[2,22] Junctional kyphosis is more likely to occur if the construct terminates at the apex of the normal thoracic curvature, at the thoracolumbar junction, or when hooks are used as the superior-most fixation component. Degeneration of the adjacent segment immediately caudal to the spinal instrumentation construct may occur. This has been documented in 10% of patients whose fusions terminated at the L5 level.[22] The surgeon must weigh the risks versus benefits of fusing to the sacrum versus stopping the fusion short of this level. This decision is made on an individualized case-by-case basis.

♦ Future Developments

There has been a progressive evolution in strategies to treat spinal deformity. Some surgical advances have already enjoyed widespread usage, and others may be on the horizon. The use of pedicle screw in both the thoracic and lumbar spine has distinct advantages with respect to the degree of fixation that is able to be achieved. Pedicle screw usage in the lumbar spine has been widespread for more than 30 years, and there has been an increasing use of thoracic pedicle screws during the past decade.[19] Concern remains about the safety of the use of thoracic pedicle screws, which have the potential for neurologic catastrophe if malpositioned.

Electrical stimulation to enhance bone fusion has been commonly used in degenerative spine conditions. The electrical stimulation may be delivered via an external orthosis or via an internally implanted stimulator. The use of these devices in spinal deformity has not been widely accepted to date. These electrical stimulators may also further increase the cost of the surgical procedure.

In recent years, fusion adjuncts have been developed that hold great promise. The use of bone morphogenetic proteins (BMP) *have* been shown to increase fusion rates in short segment fusions. These BMPs have not yet been FDA approved for use in dorsal deformity procedures; however, some surgeons have used BMPs in an "off-label" application with excellent early fusion results. At present, the extremely high cost of BMPs used at multiple segments appears to be a nearly prohibitive factor in their use for long segment deformity fixations.

The newest current boom in spinal surgery is the use of minimally invasive techniques. Performing surgeries through tubular retractors allows for diminishing the approach-related morbidity. It is clear that screws may be safely placed percutaneously and longitudinal rods may be connected to these. By avoiding dissection of the paraspinal musculature, improvements in the postoperative pain results have been impressive. This technology has been implemented for predominantly single and two-level constructs, and the future will determine if minimally invasive techniques may eventually be able to be expanded for use in adult spinal deformity surgeries.

Motion-preservation constructs have theoretical appeal. Already, anterior alone surgery with staples and motion-preserving longitudinal connectors has been performed in adolescents. What role, if any, these motion-preservation procedures will play in the treatment of deformity patients is unclear at the present time.

♦ Conclusion

Adult spinal deformity patients more frequently present with pain and neurologic conditions when compared with adolescents with deformity. There is a significant learning curve for surgeons treating patients with spinal deformity.

This learning curve needs to be overcome with extensive study of anatomy and instrumentation techniques as well as with "hands-on" experience under the guidance of an experienced deformity surgeon. The primary goals of deformity surgery include obtaining balance in both the sagittal and coronal planes. Pain relief and obtaining a solid fusion that will resist further deformity are additional, significant goals. A secondary goal, of lesser significance, is the absolute amount of curve correction achieved in these patients. Patient satisfaction with well-performed surgery remains high especially if sagittal and coronal balance is acceptable. As this field began in the 1960s, it is certain that progressive improvements in techniques and instrumentation will enable us to continue to improve the outcome results in patients with spinal deformity in the years to come.

References

1. Harrington PR. Treatment of scoliosis. Correction and internal fixation by spine instrumentation. J Bone Joint Surg Am 1962;44: 591–610
2. Emami A, Deviren V, Berven S, Smith JA, Hu SS, Bradford DS. Outcome and complications of long fusions to the sacrum in adult spine deformity: luque-galveston, combined iliac and sacral screws, and sacral fixation. Spine 2002;27(7):776–786
3. Smith JA. Adult deformity: management of sagittal plane deformity in revision adult spine surgery. Orthopaedics. 2001;12(3):206–215
4. Slosar PJ. Indications and outcomes of reconstructive surgery in chronic pain of spinal origin. Spine 2002;27(22):2555–2563
5. Deviren V, Berven S, Kleinstueck F, Antinnes J, Smith JA, Hu SS. Predictors of flexibility and pain patterns in thoracolumbar and lumbar idiopathic scoliosis. Spine 2002;27(21):2346–2349
6. Takahashi S, Delecrin J, Passuti N. Surgical treatment of idiopathic scoliosis in adults: an age-related analysis of outcome. Spine 2002;27(16): 1742–1748
7. Weinstein SL, Ponseti I V. Curve progression in idiopathic scoliosis. J Bone Joint Surg Am 1983;65(4):447–455
8. Moe JH, Lonstein JE. Moe's textbook of scoliosis and other spinal deformities. Philadelphia: WB Saunders; 1995.
9. Berven S, Deviren V, Demir-Deviren S, Hu SS, Bradford DS. Studies in the modified Scoliosis Research Society Outcomes Instrument in adults: validation, reliability, and discriminatory capacity. Spine 2003;28(18): 2164–2169
10. Buttermann GR, Glazer PA, Hu SS, Bradford DS. Anterior and posterior allografts in symptomatic thoracolumbar deformity. J Spinal Disord 2001;14(1):54–66
11. Bradford DS, Tay BK, Hu SS. Adult scoliosis: surgical indications, operative management, complications, and outcomes. Spine 1999;24(24): 2617–2629
12. Shapiro GS, Taira G, Boachie-Adjei O. Results of surgical treatment of adult idiopathic scoliosis with low back pain and spinal stenosis: a study of long-term clinical radiographic outcomes. Spine 2003;28(4): 358–363
13. Berven SH, Deviren V, Smith JA, Emami A, Hu SS, Bradford DS. Management of fixed sagittal plane deformity: results of the transpedicular wedge resection osteotomy. Spine 2001;26(18): 2036–2043
14. Eck KR, Bridwell KH, Ungacta FF, et al. Complications and results of long adult deformity fusions down to l4, l5, and the sacrum. Spine 2001; 26(9):E182–E192
15. Doherty JH. Complications of fusion in lumbar scoliosis. J Bone Joint Surg Am 1973;438:14–16
16. Bernhardt M, Bridwell KH. Segmental analysis of the sagittal plane alignment of the normal thoracic and lumbar spines and thoracolumbar junction. Spine 1989;14(7):717–721
17. Korovessis P, Piperos G, Sidiropoulos P, Dimas A. Adult idiopathic lumbar scoliosis. A formula for prediction of progression and review of the literature. Spine 1994;19(17):1926–1932
18. Bake B, Larsson S, Nachemson A. Lung function in adult idiopathic scoliosis: a 20 year follow up. Thorax 1991;46(7):474–478
19. Heary RF, Bono CM, Black M. Thoracic pedicle screws: postoperative computerized tomography scanning assessment. J Neurosurg 2004; 100(4):325–331
20. Dimar JR II, Ante WA, Zhang YP, Glassman SD. The effects of nonsteroidal anti-inflammatory drugs on posterior spinal fusions in the rat. Spine 1996;21(16):1870–1876
21. Lapp MA, Bridwell KH, Lenke LG, Baldus C, Blanke K, Iffrig TM. Prospective randomization of parenteral hyperalimentation for long fusions with spinal deformity: its effect on complications and recovery from postoperative malnutrition. Spine 2001;26(7):809–817
22. Edwards CC II, Bridwell KH, Patel A, et al. Thoracolumbar deformity arthrodesis to L5 in adults: the fate of the L5–S1 disk. Spine 2003; 28(18):2122–2131
23. Jackson RP, Simmons EH, Stripinis D. Incidence and severity of back pain in adult idiopathic scoliosis. Spine 1983;8(7):749–756
24. Albert TJ, Purtill J, Mesa J, McIntosh T, Balderston RA. Health outcome assessment before and after adult deformity surgery. A prospective study. Spine 1995;20(18):2002–2005
25. Dickson JH, Mirkovic S, Noble PC, Nalty T, Erwin WD. Results of operative treatment of idiopathic scoliosis in adults. J Bone Joint Surg Am 1995;77(4):513–523
26. Deckey JE, Court C, Bradford DS. Loss of sagittal plane correction after removal of spinal implants. Spine 2000;25(19):2453–2460
27. Lapp MA, Bridwell KH, Lenke LG, et al. Long-term complications in adult spinal deformity patients having combined surgery: a comparison of primary to revision patients. Spine 2001;26(8):973–983
28. Betz RR, Harms J, Clements DH III, et al. Comparison of anterior and posterior instrumentation for correction of adolescent thoracic idiopathic scoliosis. Spine 1999;24(3):225–239
29. Bridwell KH. Spinal instrumentation in the management of adolescent scoliosis. Clin Orthop Relat Res 1997;335:64–72

Chapter 2

Imaging Modalities for Spinal Deformities

Daniel K. Resnick and John Sandin III

There are several spinal imaging modalities available to the spine surgeon. These imaging modalities may be used to provide diagnostic information, as part of a preoperative evaluation, intraoperatively, and as a means to follow patients after surgery. Different imaging modalities have different strengths. For example, plain films will not demonstrate a compressive lesion of the cauda equina in a patient with an ependymoma. Magnetic resonance imaging (MRI) is more sensitive for the detection of soft tissue structures affecting the nerves or spinal cord. Conversely, plain films are much more appropriate for the diagnosis and management of spinal deformity (such as scoliosis or spondylolisthesis), and the use of dynamic images, bending, or flexion and extension provides further information regarding spinal mobility and stability. Computed tomography (CT) provides exquisite bony detail and is often useful for preoperative planning. For example, the use of CT to measure the size of the C2 pars interarticularis prior to attempting placement of a C1-C2 transarticular screw helps to prevent screw placement likely to produce a vertebral artery injury. Computer-aided navigation technologies allow the use of preoperative or intraoperative imaging for the intraoperative localization of hidden structures during surgery. These techniques are used to place instrumentation and to immediately assess the position of implants after placement. Some imaging modalities, such as diskography and dynamic radiographs, provide functional information in addition to anatomical detail.

The purpose of this chapter is to provide an overview of the more commonly employed imaging modalities in spinal surgery. The relative strengths and weaknesses of each modality will be discussed and illustrated in the context of a clinical example.

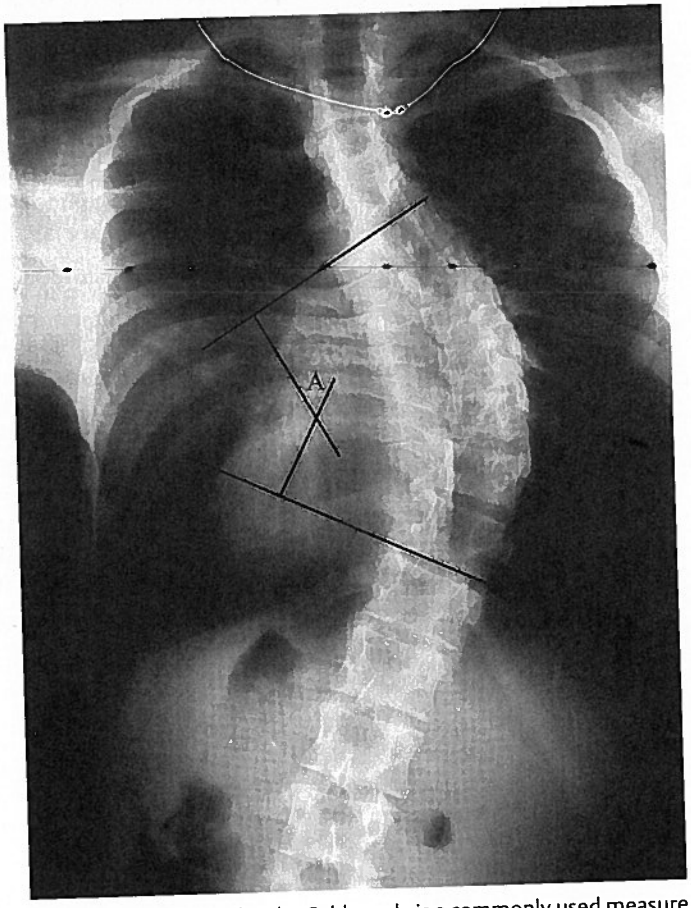

Figure 2–1 Cobb angle. The Cobb angle is a commonly used measure for the determination of global or regional spinal deformity. It is measured by drawing lines parallel to the superior end plate of the most tilted rostral vertebral body and to the inferior end plate of the most tilted caudal vertebral body. Perpendicular lines are drawn, and the angle (*A*) formed is the Cobb angle.

♦ Plain Films

Plain radiographs are relatively inexpensive, readily available, and probably the best imaging tool for the assessment of spinal deformity. The addition of dynamic images allows for the assessment of ligamentous integrity and for the assessment of spinal rigidity when corrective procedures are contemplated. The disadvantages of plain radiographs are the use of ionizing radiation and relatively poor anatomical resolution compared with other imaging modalities.

Scoliosis describes a deformity of the spine with deformation in the coronal and sagittal planes associated with a substantial rotatory component as well. Plain radiographs are commonly used to measure the degree of deformity, and studies are repeated over time to assess for progression of deformity. Coronal plane deformity is measured using the Cobb angle, defined as the intersection between lines drawn perpendicular to the upper end plate of the most tilted cephalad vertebrae and the lower end plate of the most tilted caudal vertebrae[1] **(Fig. 2–1)**. The Cobb angle has been found to have a reasonable inter- and intraobserver reliability, with the vast majority of measurements made on a given set of films being within 4 to 8 degrees.[2,3] The use of automated measuring techniques may improve accuracy and reliability even further.[4] The use of repeated films in the assessment of patients with scoliosis does expose young patients to ionizing radiation. There have been several studies that have suggested a higher risk of cancer in patients with scoliosis as opposed to similar patients without scoliosis. Most authors attribute this increased risk to the radiation received as part of the radiographic monitoring of these patients.[1,5,6]

Spondylolisthesis, or the relative movement of one vertebral body on another, is another type of deformity frequently detected, assessed, measured, and followed with plain radiographs **(Fig. 2–2)**. Multiple grading systems have been proposed to describe the degree of deformity associated with spondylolisthesis. The most commonly used measurement is the Meyerding grading system.[7] Meyerding assigned grades of slippage based on the percentage of slip noted relative to the caudal vertebral body. Grade 1 slips refer to a slip of 1 to 25% of the caudal vertebral body. Slips of 26 to 50% are referred to as grade 2, 51 to 75% as grade 3, and 76 to 100% as grade 4. Complete spondyloptisis is referred to as grade 5.[7]

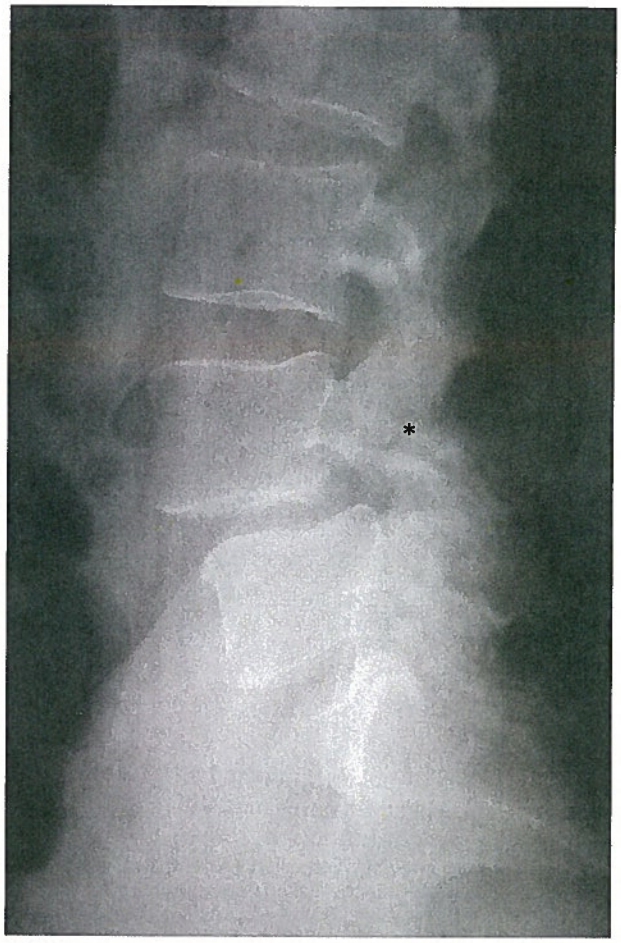

Figure 2–2 Spondylolisthesis. Plain films are an excellent tool for demonstrating sagittal plane deformity as well as scoliosis. The Cobb technique may also be employed to measure regional kyphosis or lordosis. This film demonstrates a translational deformity at L4-L5 due to spondylolytic (*asterisk*) spondylolisthesis. Degrees of spondylolisthesis are often graded using the Meyerding classification system (see text). This patient has a slip that is borderline between a grade 1 and a grade 2.

Plain films are also useful for the evaluation of traumatic deformity of the spine. Plain radiographs are a useful screening tool for injury to the spine and can provide information regarding both bony anatomy and ligamentous integrity when dynamic images are included. Information derived from dynamic plain films regarding the ligamentous integrity of the spine may also be useful in the setting of degenerative disease, where "unstable" segments are considered for fusion

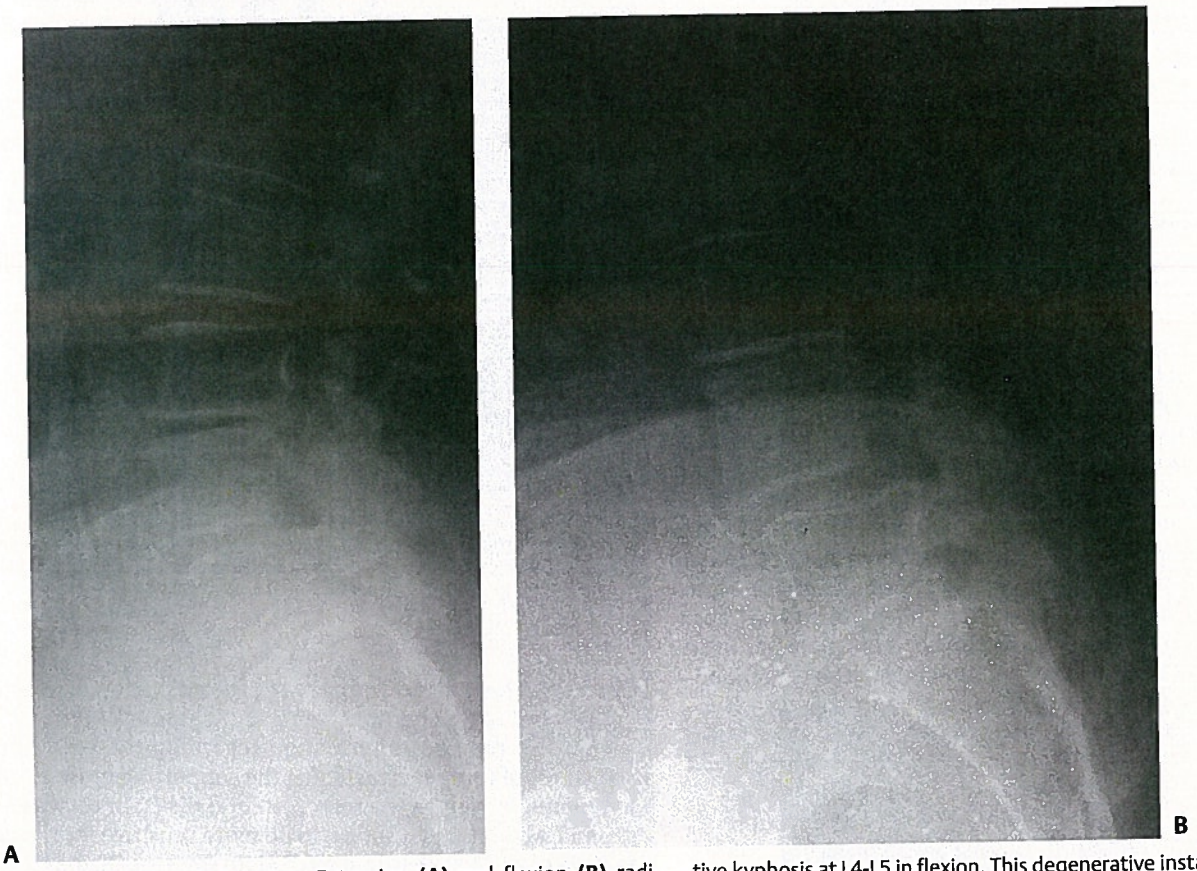

Figure 2–3 Dynamic imaging. Extension **(A)** and flexion **(B)** radiographs allow for the determination of ligamentous integrity in awake cooperative patients. This patient with neurogenic claudication and lumbar stenosis associated with spondylolisthesis demonstrates a relative kyphosis at L4-L5 in flexion. This degenerative instability may influence decisions regarding the necessity for and technique used to achieve a lumbar fusion at the time of decompression.

(Figs. 2–3A and 2–3B). The precise definition of instability of the lumbar spine is not universally agreed upon[8,9]; however multiple authors have described the use of radiographic instability as an important determinant of surgical technique.[10,11]

Static radiographs of the spine are commonly employed to assess the success or failure of bony fusion after surgery for spinal deformity. The accuracy of static radiographs is not sufficient to allow for the definitive determination of fusion **(Fig. 2–4)**. Several authors have reported case series of patients who were believed to have achieved a successful fusion based on static plain radiographs but who were later found to have a pseudarthrosis and vice versa.[12,13] The addition of flexion and extension radiographs or thin cut CT improves the accuracy of radiographic determination of fusion success.[12,13]

In summary, plain radiographs are very useful for the assessment of spinal deformity as they may provide a wide field of view and allow for the determination of spinal alignment and balance. Scoliosis, spondylolisthesis, and malalignment of the spine due to trauma or degenerative disease are often well demonstrated by plain films. Plain films do deliver ionizing radiation and do not usually provide the degree of anatomical detail associated with axial imaging techniques (see below). Plain films are not generally useful for the detection of soft tissue structures, unless such structures affect the bony spine. Finally, static plain films alone are probably not sufficient for the determination of fusion success.[12]

♦ Computed Tomography

CT provides excellent anatomical detail of the bony spine. The use of CT as a diagnostic tool is especially useful in trauma, where the sensitivity of CT for detecting fractures or subtle changes in alignment is superior to that of plain films[14–16] **(Fig. 2–5)**. CT is also very useful for the preoperative evaluation of patients considered for instrumentation of the spine. The size and shape of prospective screw fixation points can be accurately assessed. This information may be especially useful in assessing the feasibility of pedicle screw placement in the thoracic spine, where some pedicles may not be large enough to accommodate a reasonably sized pedicle screw, especially when significant corrective forces are anticipated. This knowledge allows for planning of alternative fixation techniques.[17] Similarly, preoperative evaluation of the bony anatomy of the C2 vertebral body is extremely valuable, as the location of the vertebral artery foramen in relationship to the pedicle or pars interarticularis can be assessed prior to attempted screw placement.[18] CT-based intraoperative navigation systems, as well as newer intraoperative CT devices, extend the utility of CT imaging. Depending on the anatomical region considered and the technique used for screw placement, accuracy of screw placement may be improved through the use of such intraoperative navigation devices.[19–21]

Figure 2–4 Plain films for fusion assessment. This patient underwent an anterior lumbar interbody fusion 6 months prior to this radiograph. The patient is pain free. It is not possible to determine if a bony fusion has occurred based on this image. The accuracy of plain films for the determination of fusion is only ~60%, and the importance of obtaining radiographs as a routine follow-up in asymptomatic patients may be questioned.

♦ Magnetic Resonance Imaging

MRI is probably most often used to evaluate the spinal cord and nerve roots. MRI is the only noninvasive imaging modality that provides direct visualization of the neural elements. Patients with signs or symptoms of neurological dysfunction, unexplained spinal deformity, or persistent complaints of pain despite normal radiographic imaging should undergo MRI **(Fig. 2–6)**. The use of MRI in the assessment of patients with adolescent scoliosis is generally reserved for patients with atypical symptoms. Atypical symptoms include early onset scoliosis, atypical curves, severe curve (greater than 45 degrees) despite immaturity, rapidly progressive curve, back pain headache, or neurologic abnormalities on examination.[22] Findings associated with atypical symptoms include

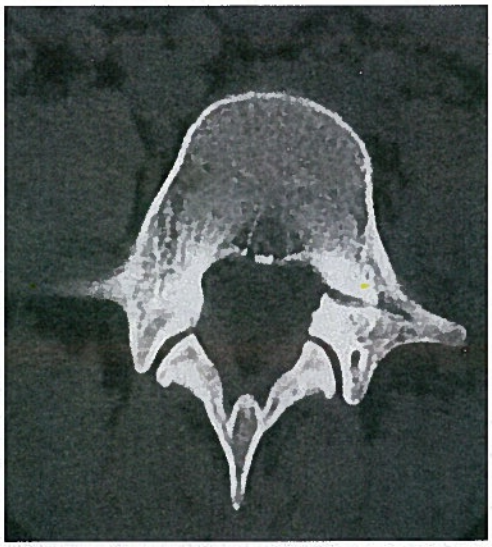

Figure 2–5 Detailed bone anatomy. This axial computed tomography (CT) image through the body of L5 revealed a subtle pedicle fracture not appreciated on plain films. This patient had a long history of low back pain.

Chiari malformation, spinal cord tumors, and congenital spinal cord malformations such as diastematolyelia.[22–30]

MRI also provides information regarding the soft tissue structures of the spine, including the supporting muscles and ligaments as well as the intervertebral disks. In the case of trauma, MRI has been shown to be more sensitive for the detection of soft tissue injury than plain films or CT.[14–16,31] MRI is also more sensitive than CT for the determination of spinal cord compression and the detection of hematoma and may provide prognostic information regarding the potential for recovery after spinal cord injury[14,32] **(Fig. 2–7)**.

Figure 2–6 Magnetic resonance imaging (MRI) and soft tissues. This patient with nonspecific low back pain underwent MRI after the failure of medical management to control his symptoms. The MR image reveals an intradural extramedullary tumor in the lower thoracic spine. Plain films were completely normal. This meningioma was resected uneventfully.

A B

Figure 2–7 Magnetic resonance imaging (MRI) and spinal cord injury. This patient suffered a thoracic fracture dislocation. Although the bony injury is well demonstrated on computed tomography (CT) **(A)**, ongoing compression of the spinal cord is clearly demonstrated by the MR image **(B)**.

MRI also can provide information regarding the health of the intervertebral disk and the potential contribution of disk degeneration to low back pain. Disk dehydration, Modic changes, "high intensity zones," and disk space collapse are all well visualized on MRI[33] **(Fig. 2–8)**. Some of these degenerative changes may correlate with the provocation of pain with lumbar diskography.[34] The occurrence of degenerative changes on MRI must be considered with some caution, however, as many asymptomatic patients will also exhibit abnormal findings on MRI.[35–38]

♦ Other Modalities

Myelography

Myelography, often combined with CT, is a valuable tool for imaging of the spinal cord, nerve roots, and adjacent structures. Plain radiographic images are produced after the injection of radiopaque contrast dye into the subarachnoid space **(Fig. 2–9)**. The dye outlines the spinal cord and nerve roots, providing a "negative" image of the neural elements. Although its role as a routine imaging modality has been supplanted by MRI, myelography is still useful for imaging patients who cannot have an MRI (usually due to an implanted device such as a pacemaker) or for patients with equivocal findings on MRI. Myelography can provide excellent anatomical detail, particularly in the foraminal region. Myelography is an invasive procedure, however, and also involves exposure to ionizing radiation.

Diskography

Diskography is a technique involving the injection of radiopaque dye into the nucleus pulposus of the intervertebral disk. Anatomical information regarding the internal structure of the disk is revealed and may be quantified using several plain film and CT–based grading systems.[39] Diskography is most frequently used as a tool to determine the origin of pain in patients with low back pain thought to be due to degenerative disk disease. Patients are asked to report whether or not injection at a particular level incites typical low back pain. This pain is compared with that elicited by injection at other levels thought to be normal. If a concordant pain response is elicited at a particular level, the test is considered positive. Diskography is associated with a significant rate of false-positive and false-negative examinations and should not be used in isolation as a presurgical screening tool.[34–38] The procedure is invasive and is again associated with exposure of the patient to ionizing radiation.

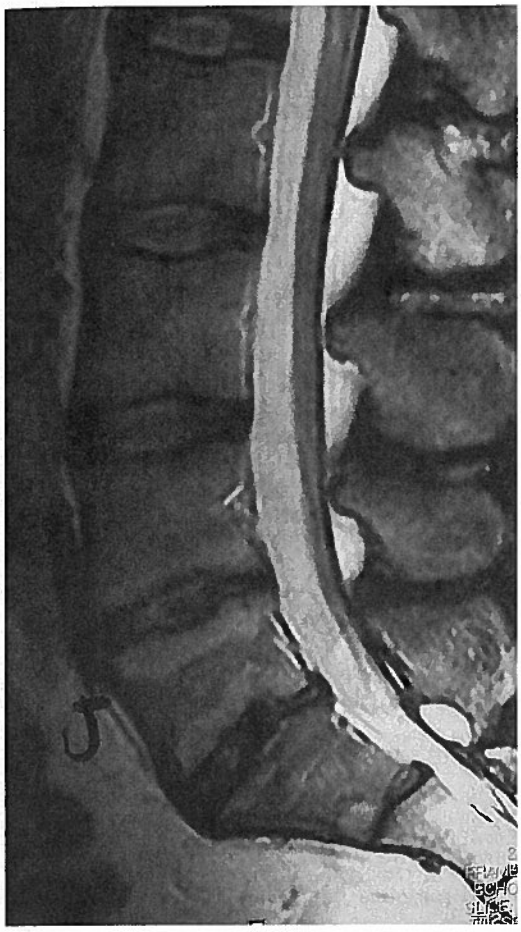

Figure 2–8 Magnetic resonance imaging (MRI) and degenerative disk disease. Many MR findings have been associated with chronic lower back pain. This patient with lower back pain has end-plate edema (Modic changes) and disk dehydration thought to be responsible for his pain.

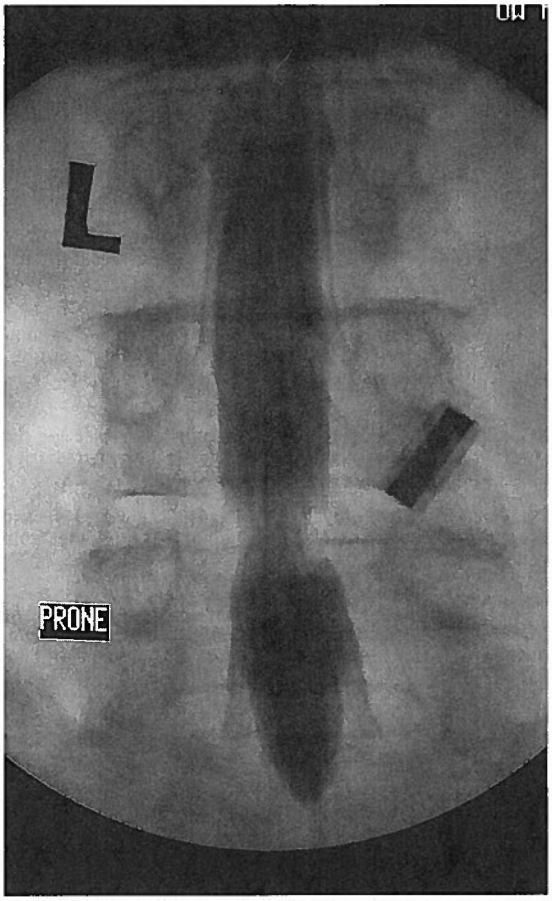

Figure 2–9 Myelogram. A myelogram is a sensitive test for nerve root or spinal cord compression. Dye injected into the intrathecal space is imaged using plain radiographs as well as computed tomography (CT). The "wasp waist" at L4-L5 indicates stenosis. Note the difference in the filling of the nerve root sleeves at the L4-L5 level compared with L3-L4 and L5-S1.

Fluoroscopy

Fluoroscopy is frequently used as an intraoperative adjunct for the guidance of implant placement. Anatomical resolution is comparable or slightly inferior to that achieved with plain radiographs. Fluoroscopy may also be used for dynamic imaging of the spine, in a manner similar to dynamic plain radiographs. Intraoperative computer-aided navigation systems may also be used in combination with fluoroscopy to reduce radiation exposure and to provide multiplanar imaging.[40]

♦ Conclusion

In summary, there are a variety of imaging modalities available for the evaluation of disorders affecting the spine. Depending on the information desired, different modalities may be more or less appropriate for a particular clinical situation. Plain films are useful because they can provide an expansive view of the spine and may be used as a tool to detect, measure, and follow deformity. CT provides excellent and detailed anatomical information regarding a particular region of the spine and is very sensitive for the detection of bony injury. CT is often useful for the preoperative assessment of anatomy when screw fixation techniques are contemplated and is also useful for the postoperative assessment of implant position. MRI is the best imaging modality for evaluating the soft tissue structures of the spine including the spinal cord, nerve roots, intervertebral disk, and spinal ligaments. Myelography, diskography, and fluoroscopy all may provide additional diagnostic information. The appropriate sequence for ordering imaging studies of the spine is to first decide what question is clinically relevant and then to order the particular imaging test most likely to provide the needed information. Imaging studies should not be ordered indiscriminately, as they may have a clinical cost (e.g., ionizing radiation or the need for sedation during MRI) as well as a financial cost. Furthermore, incidental findings diagnosed with inappropriate tests rarely aid in the clinical management of spinal disorders and may cause further harm by directing treatment toward asymptomatic lesions.

References

1. Jaramillo D, Poussaint TY, Grottkau BE. Scoliosis: evidence-based diagnostic evaluation. Neuroimaging Clin N Am 2003;13(2):335–341, xii
2. Carman DL, Browne RH, Birch JG. Measurement of scoliosis and kyphosis radiographs: intraobserver and interobserver variation. J Bone Joint Surg Am 1990;72:328–333
3. Loder RT, Urquardt A, Steen H, et al. Variability in Cobb angle measurements in children with congenital scoliosis. J Bone Joint Surg Br 1995;77:768–770
4. Shea KG, Stevens PM, Nelson M, Smith JT, Masters KS, Yandow S. A comparison of manual versus computer assisted radiographic measurement: intraobserver measurement variability for Cobb angles. Spine 1998;23(5):551–555
5. Levy AR, Goldberg MS, Hanley JA, Mayo NE, Poitras B. Projecting the lifetime risk of cancer from exposure to diagnostic ionizing radiation for adolescent idiopathic scoliosis. Health Phys 1994;66:621–633
6. Morin Doody M, Lonstein JE, Stovall M, Hacker DG, Luckyanov N, Land CE. Breast cancer mortality after diagnostic radiography: findings from the US scoliosis cohort study. Spine 2000;25(16):2052–2063
7. Meyerding HW. Spondylolisthesis. Surg Gynecol Obstet 1932;54:371
8. Hayes MA, Howard TC, Gruel TC, Kopta JA. Roentgenographic evaluation of lumbar spine flexion-extension in asymptomatic individuals. Spine 1989;14(3):327–331
9. Boden SD, Wiesel SW. Lumbosacral segmental motion in normal individuals. Have we been measuring instability properly? Spine 1990;15(6):571–576
10. Yone K, Sakou T. Usefulness of Posner's definition of spinal instability for selection of surgical treatment for lumbar spinal stenosis. J Spinal Disord 1999;12(1):40–44
11. Herkowitz HN, Kurz LT. Degenerative lumbar spondylolisthesis with spinal stenosis. A prospective study compaing decompression with decompression and intertransverse process arthrodesis. J Bone Joint Surg Am 1991;73(6):802–808
12. Brodsky AE, Kovalsky ES, Khalil MA. Correlation of radiologic assessment of lumbar spine fusions with surgical exploration. Spine 1991;16(6 Suppl):S261–S265
13. Blumenthal SL, Gill K. Can lumbar spine radiographs accurately determine fusion in postoperative patients? Correlation of routine radiographs with a second surgical look at lumbar fusions. Spine 1993;18(9):1186–1189
14. Holmes JF, Mirvis SE, Panacek EA, Hoffman JR, Mower ER, Velmahos GC. Variability in computed tomography and magnetic resonance imaging in patients with cervical spine injuries. J Trauma 2002;53(3):524–530
15. Radiographic assessment of the cervical spine in symptomatic trauma patients. Neurosurgery 2002;50(3 Suppl):S36–S43
16. Radiographic assessment of the cervical spine in asymptomatic trauma patients. Neurosurgery 2002;50(3 Suppl):S30–S35
17. O'Brien MF, Lenke LG, Mardjetko S, et al. Pedicle morphology in thoracic adolescent idiopathic scoliosis: is pedicle fixation an anatomically viable technique? Spine 2000;25(18):2285–2293
18. Resnick DK, Lapsiwala S, Trost GR. Anatomic suitability of the C1–C2 complex for pedicle screw fixation. Spine 2002;27(14):1494–1498
19. Ebmeier K, Giest K, Kalff R. Intraoperative computerized tomography for improved accuracy of spinal navigation in pedicle screw placement of the thoracic spine. Acta Neurochir Suppl 2003;85:105–113
20. Laine T, Schlenzka D, Makitalo K, Tallroth K, Nolte LP, Visarius H. Improved accuracy of pedicle screw insertion with computer-assisted surgery. A prospective clinical trial of 30 patients. Spine 1997;22(11):1254–1258
21. Laine T, Lund T, Ylikoski M, Lohikoski J, Schlenzka D. Accuracy of pedicle screw insertion with and without computer assistance: a randomised controlled clinical study in 100 consecutive patients. Eur Spine J 2000;9(3):235–240 discussion 241
22. Morcuende JA, Dolan LA, Vazquez JD, Jirasirkul A, Weinstein SL. A prognostic model for the presence of neurogenic lesions in atypical idiopathic scoliosis. Spine 2004;29(1):51–58
23. Tubbs RS, McGirt MJ, Oakes WJ. Surgical experience in 130 pediatric patients with Chiari I malformations. J Neurosurg 2003;99(2):291–296
24. Schijman E. Split spinal cord malformations: report of 22 cases and review of the literature. Childs Nerv Syst 2003;19(2):96–103
25. Cheng JC, Guo X, Sher AH, Chan YL, Metreweli A. Correlation between curve severity, somatosensory evoked potentials, and magnetic resonance imaging in adolescent idiopathic scoliosis. Spine 1999;24(16):1679–1684
26. Gupta R, Sharma R, Vashisht S, et al. Magnetic resonance evaluation of idiopathic scoliosis: a prospective study. Australas Radiol 1999;43(4):461–465
27. Goldberg BA, Erwin WD, Heggeness MH. Lumbar spine duplication presenting as adolescent scoliosis. A case report. Spine 1998;23(4):504–507
28. Freund M, Hahnel S, Thomsen M, Sartor K. Treatment planning in severe scoliosis: the role of MRI. Neuroradiology 2001;43(6):481–484
29. Cassar-Pullicino VN, Eisenstein SM. Imaging in scoliosis: what, why and how? Clin Radiol 2002;57(7):543–562
30. Suh SW, Sarwark JF, Vora A, Huang BK. Evaluating congenital spine deformities for intraspinal anomalies with magnetic resonance imaging. J Pediatr Orthop 2001;21(4):525–531
31. Hadley MN, Walters BC, Grabb PA, et al. Guidelines for the management of acute cervical spine and spinal cord injuries. Clin Neurosurg 2002;49:407–498
32. Fehlings MG, Roa SC, Tator CH, et al. The optimal radiologic method for assessing spinal canal compromise and cord compression in patients with cervical spinal cord injury. Part II: results of a multicenter study. Spine 1999;24(6):605–613
33. Modic MT, Ross JS. Magnetic resonance imaging in the evaluation of low back pain. Orthop Clin North Am 1991;22:283–301
34. Resnick DK, Malone DG, Ryken TC. Guidelines for the use of diskography for the diagnosis of painful degenerative disk disease. Neurosurg Focus 2002;13(2):E12
35. Carragee EJ, Tanner CM, Yang B, Brito JL, Truong T. False-positive findings on lumbar diskography. Reliability of subjective concordance assessment during provocative disk injection. Spine 1999;24(23):2542–2547
36. Carragee EJ, Paragioudakis SJ, Khurana S. 2000 Volvo Award winner in clinical studies: lumbar high-intensity zone and diskography in subjects without low back problems. Spine 2000;25(23):2987–2992
37. Carragee EJ. Is lumbar diskography a determinate of discogenic low back pain: provocative diskography reconsidered. Curr Rev Pain 2000;4(4):301–308
38. Carragee EJ, Tanner CM, Khurana S, et al. The rates of false-positive lumbar diskography in select patients without low back symptoms. Spine 2000;25(11):1373–1381
39. Sachs BL, Vanharanta H, Spivey MA, et al. Dallas discogram description. A new classification of CT/diskography in low-back disorders. Spine 1987;12(3):287–294
40. Resnick DK. Prospective comparison of virtual fluoroscopy to fluoroscopy and plain radiographs for placement of lumbar pedicle screws. J Spinal Disord Tech 2003;16(3):254–260

Chapter 3

Anesthesia in Spinal Deformity Surgery

Jolie Narang and Ellise Delphin

This chapter reviews the critical considerations and anesthetic practices for major spine surgery. Anesthesia for spine surgery presents challenges regarding positioning, blood loss, and postoperative complications including blindness. Depression, anxiety, and fear are known to contribute to the overall experience of "pain" surrounding the perioperative period.[1]

♦ Preoperative Evaluation

A guide to a preoperative workup based on symptoms, preexisting diseases, and the extent of surgery necessary is outlined in **Fig. 3–1**. Harris et al.[2] investigated the clinical factors associated with unexpected critical care management and

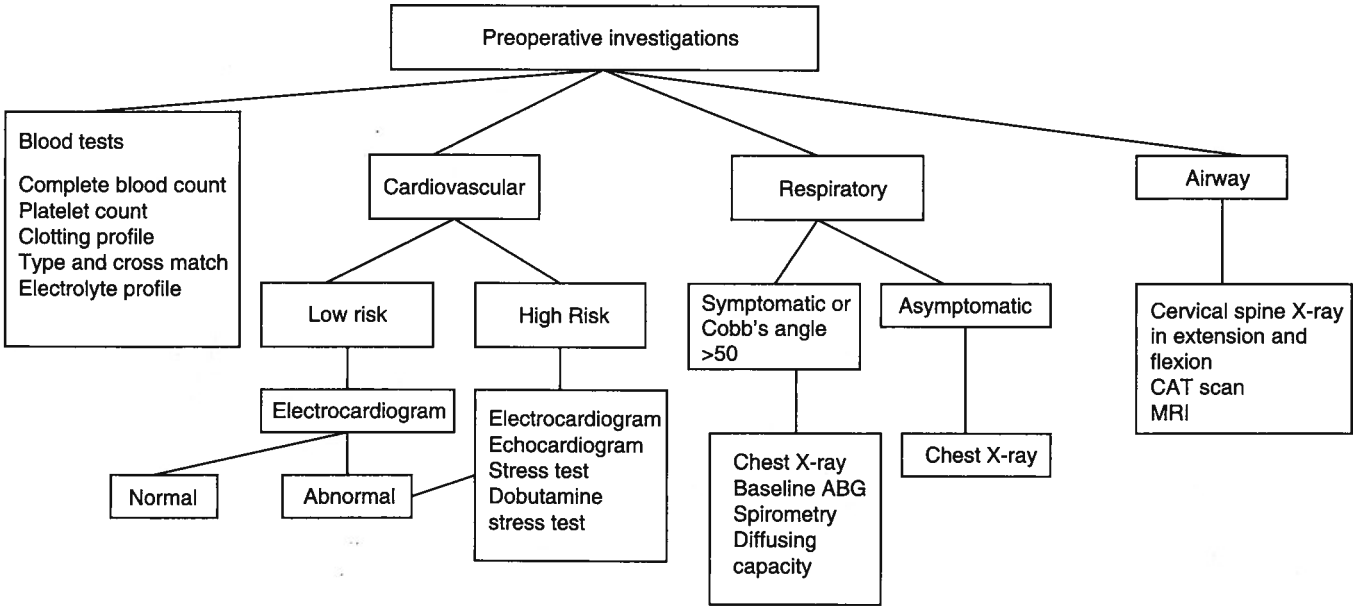

Figure 3–1 Guidelines for preoperative workup prior to spinal instrumentation.

prolonged hospitalization after elective cervical spine surgery in a retrospective, case controlled study of 109 patients. They found that 15% required critical care management in the early postoperative phase. Patients needing critical care had a greater incidence of preexisting myelopathy and a larger extent of decompression (2.38 levels). The presence of pulmonary disease, hypertension, cardiovascular disease, and diabetes mellitus all were associated with the need for critical care management and longer hospitalization. Interestingly, smoking was not associated with the need for postoperative critical care in this study. Thoracic spine surgery involving either or both an anterior and posterior approach, especially when the thoracic cavity is invaded, is often associated with postoperative radiographic abnormalities of the lungs.[3]

♦ Intubation Prior to Cervical Spine Surgery

Figure 3–2 illustrates the decision-making tree for intubation. Whatever decision is made, the patient is well informed about the plan in advance. Recognizing the potential for instability and inserting the endotracheal tube with care, while avoiding spinal movement, appears to be more important than any particular mode of intubation in preserving neurologic function.

Popitz[4] proposes observing the neck posture while the patient is walking and upon sitting (in a neutral relaxed position), noting the fluidity of head and neck movements. A patient with cervical spine pathology may maintain his or her head in a relatively stiff posture due to muscle spasm or bony fusion. Instead of rotating the head toward the examiner, such a patient might rotate the whole upper body. After ascertaining that the patient has no history of neurovascular symptomatology with neck rotation or lateral flexion (as may occur with vertebrobasilar disease), active examination can begin. In patients with an unstable cervical spine, the passive range of motion of the neck should not be examined. The neck is inspected for normal position and midline alignment of the hyoid bone, thyroid cartilage, and the spinous processes. It is also examined for loss of the normal cervical lordosis and for the presence of scoliosis.[4]

Crosby and Lui[5] reviewed 30 years of medical literature, with emphasis on the last 10 years of management of the airway in patients with unstable cervical spines. Relevant papers were selected from anesthetic, orthopaedic, rheumatologic, emergency medicine, and trauma journals. Relevant findings included the high prevalence of cervical spinal instability in trisomy 21 and rheumatoid arthritis and the relatively low incidence after trauma. Their conclusion was that with recognition of the potential for instability, performing intubations with care, while avoiding spinal movement, appeared to be more important than any particular mode of intubation in preserving neurologic function.

Awake Fiberoptic-Guided Intubation

Awake fiberoptic intubation is the technique of choice for an unstable cervical spine, prior history of difficult intubation, or the presence of a halo that complicates maintenance of a good airway. The patient should be premedicated with

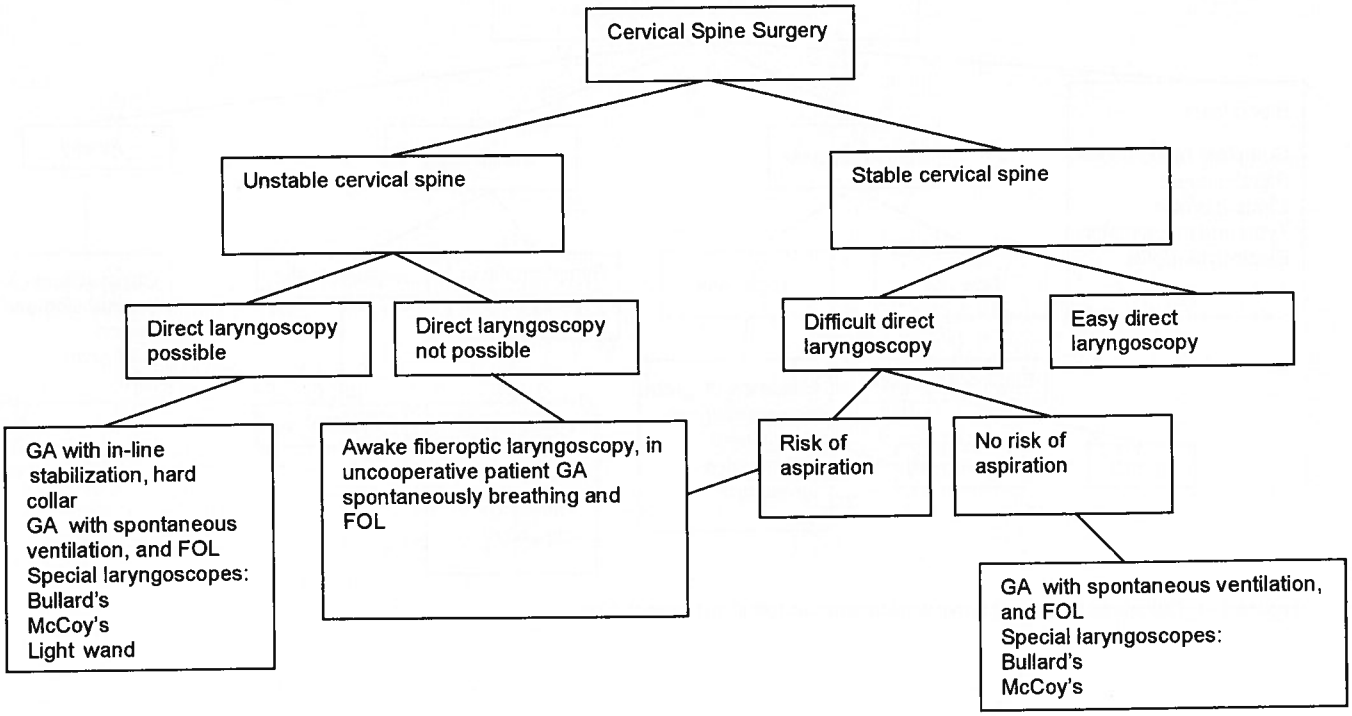

Figure 3–2 Strategy for tracheal intubation in patients with potential cervical spine injuries. FOL, fiberoptic laryngoscopy; GA, general anesthesia.

glycopyrrolate 0.2 mg to dry secretions. The airway is anesthetized with nebulized 4% lidocaine over 20 to 30 minutes to achieve adequate topical anesthesia with good sedation. Supplemental topical anesthesia of the oropharynx can be added with viscous lidocaine gargles and lidocaine ointment applied to the posterior part of the tongue. The nasopharynx can be anesthetized with either cocaine 4% or a combination of neosynephrine and lidocaine packing.

Titration of small amounts of midazolam and fentanyl can provide adequate sedation. Recently, remifentanil or dexmedetomidine have been reported to provide adequate sedation for awake fiberoptic intubations.[6–8]

Unconscious Fiberoptic-Guided Intubation

Patients with unstable spines who are not cooperative or any patient with an unanticipated difficult airway who does not have an increased risk for gastric aspiration can be safely managed by unconscious fiberoptic intubation.

Unconscious Direct Laryngoscopy

All patients whose airway is anticipated to be normal or those with in-line stabilization or with a hard collar in place can be intubated safely after direct laryngoscopy after induction of unconsciousness.

Intubating Laryngeal Mask Airway

Nakazawa[8] et al. investigated the utility of the intubating laryngeal mask airway (ILMA; LMA-Fastrach™, Laryngeal Mask Company, Ltd., Henley on Thames, UK) for blind endotracheal intubation in patients undergoing cervical spine surgery. They found that intubation was successfully achieved in only 82% of cases. All of these patients eventually underwent tracheal intubation using a fiberoptic bronchoscope through the ILMA. The vocal cords were fully viewed with the fiberoptic bronchoscope from the aperture of the ILMA in those cases. Postoperative sore throat and hoarseness occurred in 32.5% and 22.5% of patients, respectively, and, in all cases, these were transient. Three patients exhibited severe pharyngeal edema postoperatively. They recommended awake fiberoptic bronchoscopy as a first choice for patients with cervical spine disease with predicted difficult intubation.

Airway Management in Patients with Rheumatoid Arthritis

Patients with rheumatoid arthritis may have various forms of atlantoaxial subluxation, temporomandibular ankylosis reducing the mouth opening, and chronic cricoarytenoiditis that predispose to acute airway obstruction during intubation and extubation. Direct laryngoscopy should be avoided with known posterior and vertical atlantoaxial subluxations, whereas anterior, lateral, and rotator subluxations can tolerate direct laryngoscopy after stabilization of the neck.[9]

Other Options for Intubation

Different laryngoscope blades have been studied to determine cervical spine movement during direct laryngoscopy. They include Macintosh, Miller, McCoy[10] and Bullard laryngoscopes.[11] Bullard causes significant reductions in radiographic cervical spine extension as compared with the Macintosh blade.

Several techniques have been described for facilitating endotracheal intubation. Saha et al.[12] found the Lighted Intubating Stylet (LIS) device to be significantly faster than the fiberoptic bronchoscope for performing endotracheal intubation in awake patients with cervical spine injuries. Other devices have been tried to minimize cervical spine movement including a newly designed light wand device Trachlight™ (Laerdal, Armonk, New York).

♦ Intraoperative Monitoring

Blood Gas and Blood Pressure Monitoring

An intra-arterial catheter is indicated where there is greater than 20 mL/kg of blood loss expected. Additionally, to minimize intraoperative blood loss, the use of controlled hypotension mandates the use of continuous blood pressure monitoring. Frequent blood gas monitoring for acid-base balance and serial hematocrits is important for controlled hypotension.

For patients having scoliosis surgery with a likelihood of significant blood loss, or for patients in whom hemodynamic changes are especially threatening because of coincident cardiovascular disease, central venous pressure (CVP) monitoring is used. CVP is a direct measure of pressure, not volume. However, pressure is assumed to reflect the ratio of blood volume to vascular compliance, and it is a way to assess "relative blood volume" in patients who are either critically ill or undergoing major surgery. Recently, Munis et al.[13] validated the use of peripheral venous pressure (PVP) as a useful monitor, which correlates highly with changes in absolute blood volume.

Neurophysiologic Monitoring

There are three main methods of neurophysiologic monitoring: the Stagnara wake-up test, somatosensory evoked potentials (SSEPs), and motor evoked potentials (MEPs). A multicenter survey conducted by the Scoliosis Research Society involving more than 51,000 surgeries[14] showed that 0.127% of patients (64) had postoperative neurological deficits in spite of unchanged intraoperative sensory evoked potential (SEPs). In the same study, the rate of true-positive results (0.423%) represented the cases in which SEPs documented but did not prevent (or only partially prevented) a neurologic deficit.

SEP recording relies on the averaging of responses. This delays the acquisition of a reliable signal and could delay the implementation of corrective measures that can be taken in time to reverse an injury to the spinal cord. Because neurogenic motor evoked potentials (NMEPs) can be recorded with fewer averaged trials, they provide a chance for prompt feedback to the surgeon. For this reason, the use of only SEPs for monitoring the functional integrity of the entire spinal cord is no longer considered sufficient.[15]

Pelosi et al.[16] reported MEP and SEP monitoring in 97 patients for spinal orthopaedic operations. The majority of patients

(81%) underwent surgery for correction of spinal deformity. The Stagnara wake-up test appears to add no useful information to combined MEP and SEP monitoring (i.e., there are no false negatives reported with combined SEP/MEP monitoring). Because MEPs can activate the muscles of mastication, use of a bite block or tongue padding is recommended to prevent injury to the tongue and teeth.

Our preference for intraoperative anesthetic management is total intravenous anesthesia (TIVA) with concomitant use of neurophysiologic monitoring.

♦ Anesthetic Management

Stable anesthesia is required so that changes to SEPs or MEPs can be interpreted reliably. A technique involving nitrous oxide 60% and isoflurane less than 0.5 minimum alveolar concentration of potent inhalation agent (MAC) is compatible with SEP monitoring but may make MEP monitoring uninterpretable. Our preference is to combine propofol with an infusion of remifentanil. In clinical trials, where patients received remifentanil for periods up to 16 hours, recovery from anesthesia was rapid, predictable, and independent of the duration of the infusion of remifentanil.[17] In the seven controlled, general surgery studies, extubation occurred in a median of 5 minutes. Remifentanil can also be used for controlled hypotension and is preferred due to its lack of interference with MEPs.

Intraoperative communication with the neurophysiologist is imperative. Sudden cardiovascular instability during anesthesia may result from spinal cord and brain stem reflexes, from mediastinal distortion as a result of surgical manipulation, or more commonly from blood loss, influencing SEP/MEP recordings.

Techniques to Minimize Use of Allogeneic Blood Transfusion

During extensive spinal surgery, blood loss can be considerable with typical losses of 10 to 30 mL/ kg from decorticated bone and disruption of rich vascular networks. The degree of blood loss is associated with: the number of spinal levels fused,[18] body weight, surgery for tumors, and raised intraabdominal pressure in the prone position.[19] A strategy to conserve allogeneic blood transfusion is adopted early at the inception of planned surgery. See **Fig. 3–3** for a strategy for preoperative, intraoperative, and postoperative blood conservation plan.

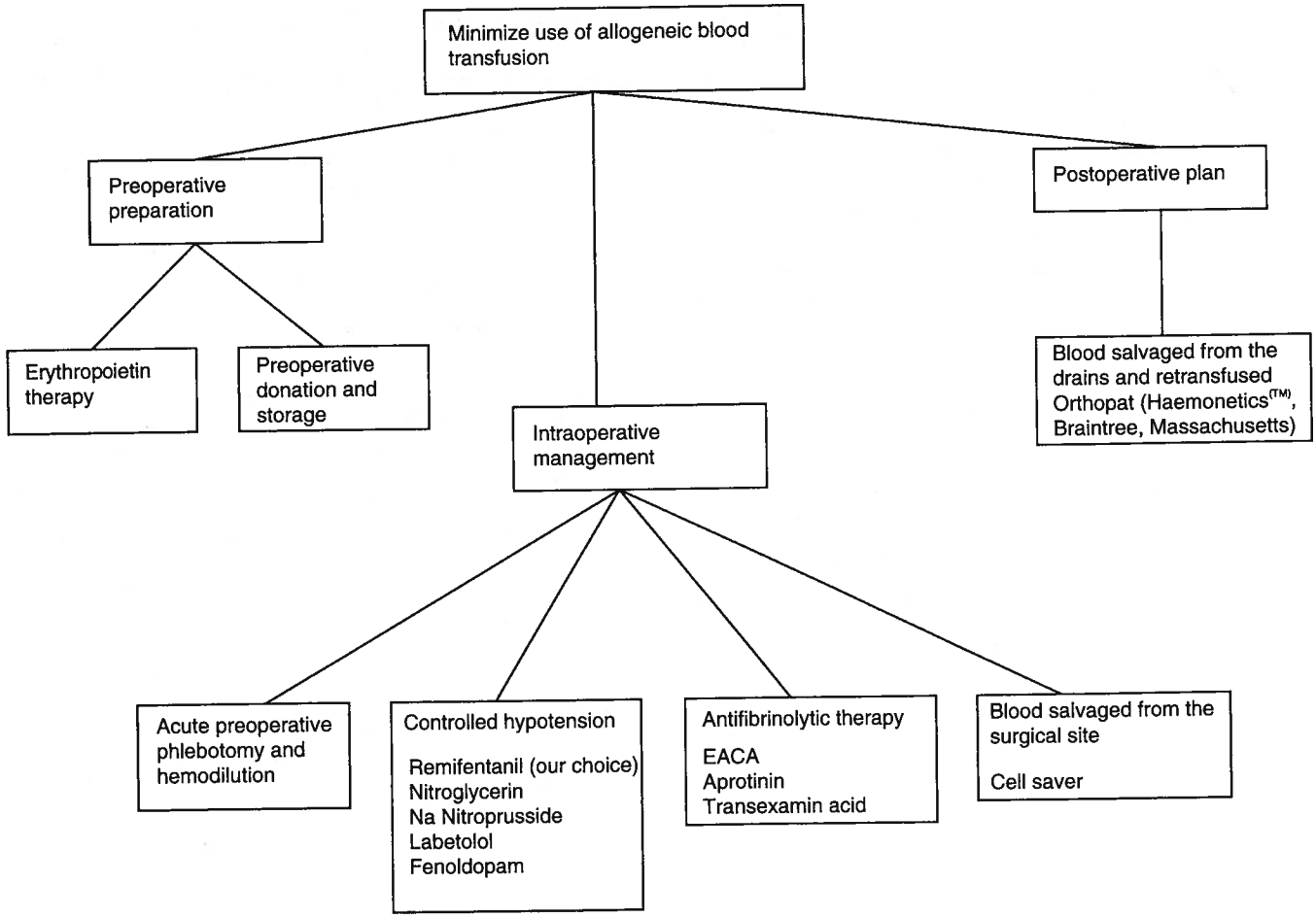

Figure 3–3 Strategies to minimize use of allogeneic blood transfusion.

Preoperative Donation and Erythropoietin

Several strategies can be adopted to conserve transfusion of allogeneic blood as outlined in **Fig. 3–3**. A recent analysis[20] from Europe retrospectively reviewed the hospital charts and blood bank records from all consecutive spine surgery patients who were referred for predonation (PD) of blood. The data were collected from 1995 to 2003. Fifty-four (7%) out of 763 patients referred for PD were rejected, and medical records were available for 680 patients who were grouped into spinal fusion (556; 82%) and scoliosis surgery (124; 18%). Recombinant erythropoietin (EPO) was administered to 120 patients (17.6%). From 1995 to 2003, PD steadily increased from 60 to 209 patients per year. Ninety-two percent of the patients were able to complete PD, 71% were transfused, and almost 80% avoided allogeneic blood transfusion. PD was more effective in fusions (86%) than in scoliosis (47%). Blood wastage was 38%, ranging from 18% for scoliosis to 42% for fusions. EPO improved the preoperative hemoglobin levels.

The authors conclude that despite the limitations of the retrospective study, PD was an excellent alternative to allogeneic transfusion in spine surgery, and the effectiveness of PD could be enhanced if associated with other blood-saving techniques such as EPO.

PD has been shown to reduce the requirement for allogeneic blood by up to 75% in lumbar fusion surgery.[21] Disadvantages of this method include repeated visits for preoperative phlebotomy, wastage of unused blood, high cost, and possible risks of incompatibility because of clerical errors. Autologous blood donations are indeed advantageous in decreasing allogeneic blood usage of patients undergoing fusion, but additional methods of blood conservation (intraoperative salvage and preoperative EPO) seem necessary to diminish the allogeneic blood requirements further, especially in those patients undergoing instrumentation and fusion.

EPO is a 34-kDa glycoprotein whose primary function is the regulation of erythrocyte production. It is essentially lineage-specific in its effects on red blood cells (RBC).[22] The use of EPO to prime for autologous RBC donation has been perceived as a major step toward reducing the risks associated with blood transfusions. The use of EPO preoperatively has been demonstrated to promote an increase in the number of autologous units of blood donated. Shapiro et al.[23] demonstrated that preoperative autologous donation was completed more effectively in the 24 patients receiving EPO studied prospectively. They reported statistically higher hematocrit levels during preoperative autologous donation and perioperatively ($p < 0.005$). Homologous transfusion was decreased by 2.4 units, and hospital stay was 1.8 days shorter in patients receiving EPO in doses of 40,000 U at the time of each predonation over 4 weeks. EPO therapy has also been successfully used in children of median age 15.4 years undergoing corrective spinal surgery to facilitate autologous blood collections.[24]

Intraoperative Strategies

Controlled hypotension has been used for minimizing blood loss in the past. However, a decrease in systemic blood pressure reduces spinal cord perfusion pressure. Additionally, recent published cases describing the occurrence of blindness after spinal surgery have highlighted the potential risks of deliberate hypotension.

Hypotension has been shown to increase the likelihood for neurologic deficits and altered evoked potential signals in both animal and clinical settings. Hypotension may induce spinal cord ischemia even without spinal cord manipulation. Lyon et al.[25] described three patients from their series who experienced a transient loss of MEPs during a period of hypotension and hypovolemia during correction of the spinal deformity. The three patients described in the case report demonstrated loss of MEP signals during major corrective spine surgery. In all cases, MEPs were affected with no significant change in SSEP signals. In two patients, the loss of MEPs occurred at the time of spinal cord manipulation. In one of the patients, the correction was immediately relieved, with simultaneous correction of physiologic factors affecting spinal cord blood flow. After recovery of MEP signals, a modified correction was reapplied without affecting MEPs or SSEPs. The third patient demonstrated a different intraoperative management strategy of raising blood pressure, intravascular volume, and hemoglobin before unloading the distraction. This was based on the belief that mechanical factors (e.g., distraction-induced vasoconstriction, increased spinal cord interstitial pressure) and suboptimal hemodynamic conditions combined to alter the MEPs. This corrected the MEPs without the need for removing hardware. Spinal cord distraction then proceeded without loss of SSEP/MEP.

Hypotensive anesthesia has been used in the past to improve the surgical field and to reduce blood loss during major spinal surgery. Volatile anesthetic agents can be used to induce deliberate hypotension but are contraindicated as they interfere with neurologic monitoring. There are several intravenous agents that can be used to induce and maintain hypotension, including sodium nitroprusside (SNP), nitroglycerin, trimetaphan, esmolol, nicardipine,[26] and fenoldopam.[27] Our preference is the use of controlled infusion of remifentanil to maintain mean arterial blood pressure 10 to 15% below baseline (measured either prior to induction of anesthesia or baseline blood pressure noted during preadmission testing).

Administration of Antifibrinolytic Agents

The antifibrinolytic drugs epsilon aminocaproic acid (EACA), tranexamic acid, and aprotinin have been shown to reduce blood loss and transfusion requirements after prostatectomy, coronary artery bypass grafting, liver transplantation, and total knee replacement.[28] Drugs such as the synthetic lysine analogues tranexamic acid and aminocaproic acid and the protease inhibitor aprotinin have been used to reduce blood loss during spinal surgery. Only aprotinin, however, has been shown to cause a statistically significant reduction in intraoperative blood loss.[29] Urban and colleagues[30] compared aprotinin and EACA with controls and found the aprotinin group had a statistically significant reduction in total blood loss (aprotinin 3628 mL, EACA 4056 mL, control 5181 mL) and transfusion requirements using a half-dose aprotinin regimen.

In contrast with aprotinin, which is a serine protease inhibitor that rapidly neutralizes plasmin, EACA acts as a competitive inhibitor of plasmin by blocking lysine sites on fibrinogen, fibrin, and platelet receptors. Tranexamic acid, an

antifibrinolytic agent that works similarly to EACA, has been used during orthopaedic surgery and shown to have little or no benefit in reducing blood loss or allogeneic blood transfusion needs.[31]

Use of Blood Salvage System

Intraoperative cell salvage (ICS), a form of autologous transfusion, involves the recovery, saline washing, concentration, and reinfusion of shed red cells during surgery. ICS has been available for more than two decades and is commonly used in cardiothoracic and vascular surgery. ICS is a reasonable alternative or additional method of volume/blood management in patients undergoing spine surgery. Surgeons may choose to use cell salvage as the primary method of volume/blood management or as a complementary method to allow the patient to donate less blood before surgery. This method can help to reduce the time expended before surgery for predonation, decrease the need for allogeneic blood and its associated risks, and decreases the cost of wasted units associated with autologous predonation.[32]

However, Siller and colleagues[33] reported no benefit on allogeneic blood exposure or postoperative hematocrit changes in 55 adolescents (intraoperative autologous transfusion group) who underwent posterior instrumentation and fusion for idiopathic scoliosis. The authors therefore concluded that blood requirements for this procedure could be met less expensively and more reliably by merely donating one's own blood. Reitman and colleagues[34] retrospectively reviewed 102 consecutive cases of posterolateral fusion with internal fixation. There were 56 patients in the ICS group and 46 patients in the control group. Hospital, medical, and financial data were analyzed for each patient. The ICS group did require fewer postoperative transfusions; the difference was not as much as expected. They suggested blood requirements could usually be satisfied with predonation of autologous blood in elective fusions for degenerative conditions of the lumbar spine. With contemporary practices of predonation, the use of ICS appears to be neither necessary nor cost-effective during most elective lumbar fusions without unexpected hemorrhage.

Intraoperative cell salvage should be used for patients who have estimated blood loss of more than 1000 mL and cell salvage red cell volumes returned of greater than or equal to 750 mL. Patients who are estimated to lose less than 1000 mL receive little benefit yet incur substantial costs from intraoperative cell salvage.[35]

Postoperative Reinfusion of Salvaged Blood

Postoperative reinfusion of unwashed, filtered, salvaged blood has been reported after total hip replacement.[36] It was associated with a decreased prevalence of allogeneic transfusion after a total hip replacement among patients for whom preoperatively donated autologous blood was not available. However, postoperative reinfusion did not affect the prevalence of allogeneic transfusion among patients for whom preoperatively donated autologous blood was available after a primary total hip replacement. No data are available after spine surgery.

Positioning

The proposed site of surgery and the nature of surgery determine the patient's position during spinal instrumentation. Pressure points should be identified and padded carefully. Pressure and traction on nerves must be avoided. Thromboembolic precautions including support hose and sequential pneumatic compression devices are often appropriate. Intraoperative x-ray imaging is frequently required. The relevant spinal level must, therefore, be placed away from the central support of a radiolucent operating table.

Prone Position

The prone position, used for posterior cervical spinal surgery, requires neutral neck position, reverse Trendelenburg positioning, and elevation of the legs, usually with pillows. This orientation serves to bring the surgical field to a horizontal position.

Prone position for lumbar spinal instrumentation requires a prone patient with a free abdomen to keep epidural venous pressure low. The patients are placed with hips extended causing a lumbar lordosis with a well-padded, secure support behind the upper thigh to support the patient's weight. A change from the supine to prone position has adverse effects on epidural venous pressure and airway pressure during general anesthesia. Palmon et al.[37] demonstrated that prone positioning during anesthesia results in a decrease in pulmonary compliance that is frame-dependent but that is not affected by body mass index. They compared chest rolls, a Wilson frame, or the Jackson spinal surgery table in 77 patients. Peak airway pressure (at the proximal endotracheal tube), pleural pressure (esophageal balloon), and mean arterial pressure were recorded in the supine position and prone position within 15 minutes of the turn. Dynamic mean (±SD) pulmonary compliance (mL/cm H_2O) decreased when turning from the supine to the prone position in all three body mass groups when using chest rolls or the Wilson frame. The dynamic pulmonary compliance was not altered in patients positioned on the Jackson table.

Wadsworth et al.[38] evaluated the cardiovascular effects of four different prone positions: on two pillows, on a vacuum mattress, on two props with a support, and in the knee-chest position, in 20 healthy awake volunteers. They concluded that of the four positions used, the knee-chest position causes the greatest decrease in cardiac index (20%) and recommended its use with caution in the high-risk patient.

The relationship of intraabdominal pressure changes to blood loss was examined with a rectal balloon pressure catheter during spinal surgery. It was found that blood loss tended to increase with an increase in intraabdominal pressure in the narrow pad support width of the Wilson frame.[39]

Lateral Decubitus Position

An anterior approach to the thoracic spine is often achieved via a thoracotomy with the patient supported in a lateral position. A double lumen endobronchial tube or a Univent tube can be used to allow deflation of one lung for surgical access. A vacuum mattress that can be molded to the patient's anatomic features greatly facilitates maintenance of a stable lateral position.

Postoperative Complications

Complications from Positioning

Blindness: Postoperative visual loss (PVL) is a devastating and poorly understood injury. Although rare, there are certain operative procedures, especially spinal surgery in the prone position, in which the incidence is significant. Ischemic optic neuropathy (ION), which affects the anterior or posterior portions of the optic nerve, is the most common cause of PVL. Visual loss may also be caused by retinal arterial occlusion and cortical blindness. Awakening with visual impairment is a catastrophic post anesthetic complication.[40]

Roth[41] reported an overall incidence of eye injury in nonocular surgery of 0.056% in a study in which data were collected prospectively and then analyzed retrospectively. The most common eye injury reported was corneal abrasion. Cucchiara et al.[42] reported an overall incidence of corneal abrasion of 0.17% in a large prospective study of 4652 neurosurgical patients. There is a greater incidence of corneal abrasion in patients operated on while in the prone position for lumbar laminectomy compared with other neurosurgical procedures. Taping the eyes closed or applying ointment did not affect the incidence of corneal abrasion. Two other considerably smaller prospective studies of 76 and 127 adult patients found no corneal abrasions and no advantage in applying ointment rather than taping the eyes closed.

Blindness occurred in only one patient in Roth's series, and reports of this outcome have been rare. Blindness involves damage to the posterior segment of the eye (retina or optic nerve) or may be related to damage to the visual cortex. Mechanisms possibly responsible for these injuries include compression, hypotension, hypoxia, and anemia.

Recently, Cheng et al.[43] studied the effect of prone positioning on intraocular pressure (IOP) in anesthetized patients. Results showed IOP in the prone position (27 ± 2 mm Hg) was significantly higher than both supine ($p < 0.05$) and baseline ($p < 0.05$) conditions. This study represents an initial attempt to elucidate a probable mechanism for the recently recognized problem of visual loss after spine surgery. The authors concluded that the prone position increases IOP in the anesthetized patient, suggesting that a concurrent drop in MAP could be deleterious to the eye by reducing perfusion pressure (MAP minus IOP).

Thirty-seven patients who experienced visual loss after spine surgery were reviewed by Myers[44]and were identified through a survey of the members of the Scoliosis Research Society and a review of the literature. All the records were reviewed in an attempt to identify preoperative and intraoperative risk factors and to assess the likelihood of recovery. Surgery included instrumented posterior fusion in 92% of the cases, with an average operative time of 410 minutes and blood loss of 3500 mL. Most cases had significant intraoperative hypotension, with a mean drop in systolic blood pressure from 130 to 77 mm Hg. However, comparison with a matched group of patients with no visual symptoms showed no differences in the hematocrit or blood pressure values. Visual loss occurred because of ischemic optic neuropathy, retinal artery occlusion, or cerebral ischemia. Eleven cases were bilateral, and 15 patients had complete blindness in at least one eye. Most deficits were permanent.

The author concluded that blindness after spine surgery is more common than has been recognized previously and that most cases were associated with complex instrumented fusions. Lee and Lam[45] reported unilateral blindness after prone lumbar spine surgery.

Meralgia Paresthetica

Injuries to the lateral femoral cutaneous nerve, also known as meralgia paresthetica, may cause pain and therefore result in restriction of activity. Compression of the nerve by disk herniation, retroperitoneal tumors, and external pressure around the anterior superior iliac spine are among the more common causes. Injury to the lateral femoral cutaneous nerve was found to be a common complication during spine surgery and occurs in 20% of the patients.[46] Neuropathy of this nerve is usually associated only with hypoesthesia, but in some patients it may cause pain and dysesthesia in the anterolateral aspect of the thigh. Compression neurapraxia is most probably the cause of injury in patients undergoing operation on frames (Hall-Relton frame). In those positions, in fact, the posts supporting the pelvis can compress the nerve at the exit below the anterior superior iliac spine.

Prolonged Critical Care Management

In patients undergoing decompressive cervical surgery for degenerative disease, the following factors have been linked to the need for unanticipated, postoperative critical care and longer hospitalization: multilevel decompression, preexisting myelopathy, pulmonary disease, cardiovascular disease, hypertension, and diabetes mellitus.[2] Intraoperative fluid management in spine surgery has been found to have predictive value for postoperative intensive care unit (ICU) length of stay (LOS). Nahtomi-Schick et al.[47] divided 103 adult patients into three groups: those who did not require ICU care, those requiring 1 day of ICU care, and those requiring more than 1 day. Significant variations in the type and complexity of the operations limited the comparison between the study groups. Patients with longer ICU LOS, however, required more transfusion with blood products and fluid replacement with crystalloids intraoperatively.

A retrospective review[48] for the occurrence of perioperative complications of 1223 thoracic and lumbar anterior spinal fusions performed from 1969 through 1992 showed risk of a complication was 11.5%. Risk was increased for patients over age 60 years, for women, and for patients with multiple preexisting health problems. Serious complications, such as death (0.3%), paraplegia (0.2%), and deep wound infection (0.6%), were rare.

The prevalence of deep venous thrombosis after posterior spinal surgery is from 0.3 to 15.5%.[49] Screening for thromboembolism after spinal surgery can be done by venography, which is the gold standard for the detection of deep venous thrombosis. Recently, venous ultrasonography has gained increasing popularity in detecting thrombosis.

Prolonged Intubation

The decision to provide a period of postoperative artificial ventilation should be made and explained to the patient before

surgery commences. Patient and surgical factors suggest the need for postoperative ventilation. Patient factors include the presence of a preexisting neuromuscular disorder, severe restrictive pulmonary dysfunction with a low preoperative vital capacity, a congenital cardiac abnormality, right ventricular failure, and obesity. Surgical factors include a prolonged procedure, surgical invasion of the thoracic cavity, and major blood loss. Frequently, it is necessary only to provide artificial ventilation for a few hours in the postoperative care unit until hypothermia and metabolic derangements have been corrected.

Anesthesia for Spinal Instrumentation in Pediatric Population

Scoliosis is defined as a simple lateral curvature of the spine in the coronal plain.

The initial evaluation of the patient should include a thorough history, complete physical and neurologic examinations, and roentgenograms of the spine. If there is history of any use of aspirin-containing products or nonsteroidal anti-inflammatory agents, they should be discontinued before surgery because these medications may increase blood loss during surgery. Birth control pills should be discontinued 1 month before surgery because they have been shown to increase the possibility of thrombophlebitis in the postoperative period.

Pulmonary function studies usually are indicated in patients with paralytic scoliosis or those with idiopathic or congenital scoliosis who have severe curves or significant kyphosis or lordosis greater than 50 to 60 degrees as measured by the Cobb method.[50]

Many studies have suggested the need for pulmonary function tests for adolescent idiopathic scoliosis (AIS). It has been stated that pulmonary function tests are an essential part of preoperative evaluation of patients with scoliosis to determine the surgical risk. Although it is recognized that postoperative pulmonary complications are likely in patients with muscular dystrophy, cerebral palsy, severe congenital scoliosis, and infantile-onset idiopathic scoliosis, few studies have reported on the incidence of postoperative pulmonary complications in patients with AIS. In one recent study,[51] performance of a thoracoplasty was the only risk factor for postoperative pulmonary complications in patients undergoing posterior spinal fusion. There was no correlation between deterioration of preoperative pulmonary function and the risk of postoperative pulmonary complications. The authors of the study concluded that performance of preoperative pulmonary function tests in patients with moderate adolescent idiopathic scoliosis who are scheduled for posterior spinal fusion is not necessary.

Perioperative Techniques for Pain Management

Perioperative pain management of patients includes the use of epidural, patient-controlled analgesia (PCA), and regional techniques by anesthesiologists. Regional analgesic techniques include intercostal, paravertebral, and plexus blocks and local anesthetic infiltration of incisions by the surgeon. A multimodal analgesic approach is recommended for the management of perioperative pain. The literature supports the administration of more than one analgesic agent that each act by different mechanisms via a single route for providing superior analgesic efficacy with equivalent or reduced adverse effects. Unless contraindicated, the pharmacologic management should include a nonsteroidal anti-inflammatory drug (NSAID). There is a significant opioid-sparing effect with cyclooxygenase-2 inhibitors (COXIBs) celecoxib and rofecoxib when used in conjunction with PCA morphine after spinal fusion surgery.[52] Ketorolac, the only parenteral NSAID available in the United States, is often used in the perioperative setting. It is recommended to use smaller doses of ketorolac intravenously at 6-hour intervals to minimize the side effects, which include gastrointestinal and operative site bleeding. Doses as small as 7.5 mg every 6 hours as a supplement to PCA are effective.[53]

Patient-controlled epidural analgesia (PCEA) is viable and provides excellent postsurgical analgesia in adults. Subsequent to the study, serious questions about the inhibitory effects of NSAIDs on spinal fusion have been raised by data reproduced by Dimar et al.[54] in rats and in human beings by Deguchi.[55] Clinically, the widespread use of NSAIDs in the postoperative period after spinal fusion has been revised. Our preference is to use PCA for control of acute postoperative pain after spinal instrumentation.

Continuous epidural infusion of bupivacaine/opioid has been used as the principal postoperative analgesic in young patients using an epidural catheter placed intraoperatively.[56] Recently, Gottschalk and colleagues reported the use of continuous postoperative infusion of 0.1% ropivacaine using an epidural catheter placed intraoperatively by the orthopaedic surgeon resulted in significant reduction of pain scores, reduced requirement of parenteral opioids, and a higher patient satisfaction after major lumbar spinal surgery.[57]

Epidural catheters can be used safely and effectively to control postoperative pain after anterior instrumentation and spinal fusion for adolescent scoliosis.[58] Side effects of epidural techniques include somnolence, delayed respiratory depression, pruritus, urinary retention, nausea and vomiting, and accidental removal of catheters. Hered et al. reported Horner's syndrome as a potential complication of spinal fusion in combination with epidural analgesia by indwelling catheter.[59] The greatest concern of neuraxial techniques after spine surgery is the potential risk of infection related to the epidural catheter. However, there are no reports of infectious complications related to the regional anesthetic technique.

Reuben et al.[60] reported 60 patients having cervical spine fusion with iliac crest bone graft to determine whether local application of morphine on the ilium reduced postoperative pain. Three groups were studied: 5 mg morphine or saline infiltrated over the harvest site and 5 mg intramuscular morphine. Pain was assessed with PCA and by numeric rating scale for both the iliac and cervical areas for 24 hours after surgery. A 1-year follow-up of pain at the iliac site was recorded. Application of morphine over the ilium donor site resulted in less 24-hour morphine use: 34 mg compared with placebo saline (64 mg) or intravenous morphine (60 mg). Iliac pain ratings were significantly lower after 2 hours. One-year chronic iliac donor site pain was 5% for the morphine-iliac infiltration group but 33% in the placebo and 37% in the intramuscular morphine group. This well-conducted study demonstrates the value of interrupting nociception.

Quality of Recovery

There is no accepted criterion that can serve as a definitive standard of quality of recovery. Leslie et al.[61] recently studied the quality of recovery from anesthesia in neurosurgical patients. The investigators used a QoR-40 score that was developed by Myles et al.[62,63] to measure quality of recovery from anesthesia. They found that 92 spinal surgery patients reported pain scores similar to those of 100 cranial surgery patients, but their pain was more persistent. Surgery was not always able to relieve pain (particularly back pain) or restore function, and spinal surgery patients generally score lower on measures of quality of life and have lower functional capacity and higher rates of depression than other patients.

♦ Conclusion

Spinal surgery presents several challenges to the anesthesiologist. Patients are now undergoing major spinal surgery for conditions such as malignancy, scoliosis, and trauma, which would not have been contemplated a few years ago. Great strides in techniques for monitoring the spinal cord, advances in anesthesia techniques, and improved surgical techniques have reduced the postoperative neurologic morbidity. The anesthesiologist has an important role to play in facilitating the use of these new techniques. A multidisciplinary approach to achieve the most favorable care of patients is the primary objective.

References

1. Casey KC, Bushnell MC, eds. Pain Imaging. Seattle, WA: International Association Study of Pain Press; 2000.
2. Harris OA, Runnels JB, Matz PG. Clinical factors associated with unexpected critical care management and prolonged hospitalization after elective cervical spine surgery. Crit Care Med 2001;29:1898–1902
3. Jules-Elysee K, Urban MK, Urquhart BL, Susman MH, Brown AC, Kelsey WT. Pulmonary complications in anterior-posterior thoracic lumbar fusions. Spine J 2004;4(3):312–316
4. Popitz MD. Anesthetic implications of chronic disease of the cervical spine. Anesth Analg 1997;84(3):672–683
5. Crosby ET, Lui A. The adult cervical spine: implications for airway management. Can J Anaesth 1990;37:77–93
6. Machata AM, Gonano C, Holzer A, et al. Awake nasotracheal fiberoptic intubation: patient comfort, intubating conditions, and hemodynamic stability during conscious sedation with remifentanil. Anesth Analg 2003;97(3):904–908
7. Neidhart G. [Fiberoptic intubation during remifentanil propofol sedation.] Anaesthesist 2001;50(4):242–247. [in German]
8. Nakazawa K, Tanaka N, Ishikawa S, et al. Using the intubating laryngeal mask airway (LMA-Fastrach™) for blind endotracheal intubation in patients undergoing cervical spine operation. Anesth. Analg 1999; 89(5): 1319–1321
9. Macarthur A. Rheumatoid cervical joint disease–a challenge to the anaesthetist. Can J Anaesth 1993;40(2):154–159
10. MacIntyre PA, McLeod AD, Hurley R, Peacock C. Cervical spine movements during laryngoscopy: comparison of the Macintosh and McCoy laryngoscope blades. Anaesthesia 1999;54:413–418
11. Hastings RH, Vigil AC, Hanna R, Yang B, Sartoris DJ. Cervical spine movement during laryngoscopy with the Bullard, Macintosh and Miller laryngoscopes. Anesthesiology 1995;82:859–869
12. Saha AK, Higgins M, Walker G, Badr A, Berman L. Comparison of awake endotracheal intubation in patients with cervical spine disease: the lighted intubating stylet versus the fiberoptic bronchoscope. Anesth Analg 1998;87(2):477–479
13. Munis JR, Bhatia S, Lozada LJ. Peripheral venous pressure as a hemodynamic variable in neurosurgical patients. Anesth Analg 2001;92(1): 172–179
14. Nuwer MR, Dawson EG, Carlson LG, Kanim LE, Sherman JE. Somatosensory evoked potential spinal cord monitoring reduces neurologic deficits after scoliosis surgery: results of a large multicenter survey. Electroencephalogr Clin Neurophysiol 1995;96:6–11
15. Owen JH, Sponseller PD, Szymanski J, Hurdle M. Efficacy of multimodality spinal cord monitoring during surgery for neuromuscular scoliosis. Abstract. Spine 1995 Jul 1;20(13):1480–1488
16. Pelosi L, Lamb J, Grevitt M, Mehdian SMH, Webb JK, Blumhardt LD. Combined monitoring of motor and somatosensory evoked potentials in orthopaedic spinal surgery. Clin Neurophysiol 2002;113: 1082–1091
17. Maheswaran AM, ed. Remifentanil Hydrochloride, 16 edition. Mosby's Drug Consult. St. Louis: Mosby, Inc; 2006
18. Zheng F, Cammisa FP Jr, Sandhu HS, et al. Factors predicting hospital stay, operative time, blood loss, and transfusion in patients undergoing revision posterior lumbar spine decompression, fusion, and segmental instrumentation. Spine 2002;27:818–824
19. Park CK. The effect of patient positioning on intraabdominal pressure and blood loss in spinal surgery. Anesth Analg 2000;91:552–557
20. García-Erce JA, Muñoz M, Bisbe E, et al. Predeposit autologous donation in spinal surgery: a multicentre study. Eur Spine J 2004;13(Suppl 1): S34–S39
21. Cha CW, Deible C, Muzzonigro T, Lopez-Plaza I, Vogt M, Kang JD. Allogeneic transfusion requirements after autologous donations in posterior lumbar surgeries. Spine 2002;27(1):99–104
22. Hoffman R, Benz E, Shattil S, Forie B. Hematology: Basic Principles and Practice, 4th ed. Churchill Livingstone; 2005
23. Shapiro GS, Boachie-Adjei O, Dhawlikar SH, Maier LS. The use of epoetin alfa in complex spine deformity surgery. Spine 2002;27(18):2067–2071
24. Franchini M, Gandini G, Regis D, Gironcoli M, Cantini M, Aprili G. Recombinant human erythropoietin facilitates autologous blood collections in children undergoing corrective spinal surgery. Transfusion 2004;44:1122–1124
25. Lyon R, Lieberman JA, Grabovac MT, Hu S. Strategies for managing decreased motor evoked potential signals while distracting the spine during correction of scoliosis. J Neurosurg Anesthesiol 2004;16(2):167–170
26. Bernard JM, Passuti N, Pinaud M. Long-term hypotensive technique with nicardipine and nitroprusside during isoflurane anesthesia for spinal surgery. Anesth Analg 1992;75:179–185
27. Tobias JD. Fenoldopam for controlled hypotension during spinal fusion in children and adolescents. Paediatr Anaesth 2000;10:261–266
28. Murkin JM, Shannon NA, Bourne RB, Rorabeck CH, Cruickshank M, Wyile G. Aprotinin decreases blood loss in patients undergoing revision or bilateral total hip arthroplasty. Anesth Analg 1995;80: 343–348
29. Lentschener C, Cottin P, Bouaziz H, et al. Reduction of blood loss and transfusion requirement by aprotinin in posterior lumbar spine fusion. Anesth Analg 1999;89:590–597
30. Urban MK, Beckman J, Gordon M, et al. The efficacy of antifibrinolytics in the reduction of blood loss during complex adult reconstructive spine surgery. Spine 2001;26:1152–1156

31. Neilipovitz DT, Murto K, Hall L, Barrowman NJ, Splinter WM. A randomized trial of tranexamic acid to reduce blood transfusion for scoliosis surgery. Anesth Analg 2001;93:82–87

32. Shander A. Surgery without blood. Crit Care Med 2003;31(12 Suppl):S708–S714

33. Siller TA, Dickson JH, Erwin WD. Efficacy and cost considerations of intraoperative autologous transfusion in spinal fusion for idiopathic scoliosis with predeposited blood. Spine 1996;21:848–852

34. Reitman W, William C, Sassard W. The cell saver in adult lumbar fusion surgery: a cost-benefit outcomes study. Spine 2004;29(14):1580–1583

35. Goodnough LT. Intraoperative salvage in patients undergoing elective abdominal aortic aneurysm repair: an analysis of cost and benefit. J Vasc Surg 1996;24(2):213–218

36. Ayers DC, Murray DG, Duerr DM. Blood salvage after total hip arthroplasty. J Bone Joint Surg Am 1995;77(9):1347–1351

37. Palmon SC, Kirsch J, Depper JA, Toung TJK. The effect of the prone position on pulmonary mechanics is frame-dependent. Anesth Analg 1998;87(5):1175–1180

38. Wadsworth R, Anderton JM, Vohra A. The effect of four different surgical prone positions on cardiovascular parameters in healthy volunteers. Anaesthesia 1996;51:819–822

39. Park CK. The effect of patient positioning on intraabdominal pressure and blood loss in spinal surgery. Anesth Analg 2000;91:552–557

40. Roth S. Postoperative visual loss: still no answers—yet. Anesthesiology 2001;95(3):575–577

41. Roth S. Eye injuries after nonocular surgery. A study of 60,965 anesthetics from 1988 to 1992. Anesthesiology 1996;85(5):1020–1027

42. Cucchiara RF, Black S. Corneal abrasion during anesthesia and surgery. Anesthesiology 1988;69:978–979

43. Cheng MA. The effect of prone positioning on intraocular pressure in anesthetized patients. Anesthesiology 2001;95(6):1351–1355

44. Myers MA. Visual loss as a complication of spine surgery. A review of 37 cases. Spine 1997;22(12):1325–1329

45. Lee LA, Lam AM. Unilateral blindness after prone lumbar spine surgery. Anesthesiology 2001;95(3):793–795

46. Mirovsky Y, Neuwirth M. Injuries to the lateral femoral cutaneous nerve during spine surgery. Spine 2000;25:1266–1269

47. Nahtomi-Shick O, Kostuik JP, Winters BD, et al. Does intraoperative fluid management in spine surgery predict intensive care length of stay? J Clin Anesth 2001;13(3):208–212

48. Faciszewski T, Winter RB, Lonstein JE, et al. The surgical and medical perioperative complications of anterior spinal fusion surgery in the thoracic and lumbar spine in adults: a review of 1223 procedures. Spine 1995;20:1592–1599

49. Oda T, Fuji T, Kato Y, et al. Deep vein thrombosis after posterior spinal surgery. Spine 2000;25:2962–2967

50. Canale ST, ed. Campbell's Operative Orthopaedics, 10th ed. St. Louis: Mosby; 2003

51. Vedantam R, Crawford AH. The role of preoperative pulmonary function tests in patients with adolescent idiopathic scoliosis undergoing posterior spinal fusion. Spine 1997;22(23):2731–2734

52. Reuben SS, Connelly NR. Postoperative analgesic effects of celecoxib or rofecoxib after spinal fusion surgery. Anesth Analg 2000;91(5): 1221–1225

53. Reuben SS, Connelly NR, Lurie S, et al. Dose-response of ketorolac as an adjunct to patient-controlled analgesia morphine in patients after spinal fusion surgery. Anesth Analg 1998;87:98–102

54. Dimar JR II, Ante WA, Zhang YP, Glassman SD. The effects of nonsteroidal anti-inflammatory drugs on posterior spinal fusions in the rat. Spine 1996;21:1870–1876

55. Deguchi M, Rapoff AJ, Zdeblick TA. Posterolateral fusion for isthmic spondylolisthesis in adults: a study of fusion rate and clinical results. J Spinal Disord 1998;11:459–464

56. Shaw BA, Watson TC, Merzel DI, et al. The Safety of continuous epidural infusion for postoperative analgesia in pediatric spine surgery. J Pediatr Orthop 1996;16(3):374–377

57. Gottschalk A, Freitag M, Tank S, et al. Quality of postoperative pain using an intraoperatively placed epidural catheter after major lumbar spinal surgery. Anesthesiology 2004;101(1):175–180

58. Lowry KJ, Tobias JD, Kittle D, et al. Postoperative pain control using epidural catheters after anterior spinal fusion for adolescent scoliosis. Spine 2001;26:1290–1293

59. Hered RW, Cummings J, Helffrich R. Persistent Horner's syndrome after spinal fusion and epidural analgesia. Spine 1998;23:387–390

60. Reuben SS, Vieira P, Faruqi S, Verghis A, Kilaru PA, Maciolek H. Local administration of morphine for analgesia after iliac bone graft harvest. Anesthesiology 2001;95(2):390–394

61. Leslie K. Quality of recovery from anesthesia in neurosurgical patients. Anesthesiology 2003;99(5):1158–1165

62. Myles P, Hunt J, Nightingale C, et al. Development and psychometric testing of a quality of recovery score after general anesthesia and surgery in adults. Anesth Analg 1999;88:83–90

63. Myles P, Weitkamp B, Jones K, Melick J, Hensen S. Validity and reliability of a post-operative quality of recovery score: The QoR-40. Br J Anaesth 2000;84:11–15

Chapter 4

Intraoperative Neuromonitoring in Spinal Deformity Surgery

Daniel M. Schwartz and Anthony K. Sestokas

Early detection of iatrogenic neurologic injury during surgery for spinal deformities is a key step to reducing the incidence and severity of sensorimotor sequelae. After its description in 1973,[1] the Stagnara "wake-up" test became the gold standard in many centers for assessing neurologic integrity after the application of corrective forces to a rigid spinal implant. Although this simplified method of assessing motor function has withstood the test of time, it is not without limitations. These include but are not limited to the potential for patient extubation, venous air emboli, false-negative results, poor patient cooperation and cognition during testing. Perhaps the greatest shortcoming of the wake-up test is that it is performed at a single point in time during surgery; namely, after correction.[2] This means that spinal cord injury occurring before correction goes undetected until the time of the wake-up test. The temporal delay between the time of insult and that of detection by a wake-up test not only interferes with reliable identification of the specific surgical maneuver responsible for the injury but also delays intervention to facilitate injury reversal. Moreover, clinical manifestation of spinal cord injury does not always present in a tightly time-locked manner to correction of the spinal deformity. When clinical manifestation of injury is delayed, it can be missed by the wake-up test.

Given the limitations associated with the wake-up test, intraoperative neurophysiologic monitoring (IONM) of spinal cord function has become standard-of-care in many leading pediatric and adult spine centers. Beginning with the use of somatosensory evoked potentials (SSEPs) almost three decades ago, and including the more recent use of transcranial electric motor evoked potentials (TceMEPs) and electromyography (EMG), IONM now makes it possible to assess the functional integrity of the dorsal sensory and ventral motor spinal cord tracts and nerve roots essentially in real-time, from anesthesia induction to emergence.[2,3–6]

Despite its overwhelming success in many major university spine centers, however, IONM has not yet achieved the status of "standard-of-care." This lack of universal acceptance has been attributed to several factors, including but not limited to, cost considerations, the poorly understood role of IONM and its indications by many in the surgical community, and lack of highly qualified and experienced IONM personnel, both on the professional and technical levels.

This chapter presents an overview and update of neuromonitoring during surgery for spinal deformities. Topics include descriptions of the anatomical and physiologic basis for each specific neurophysiologic monitoring technique, the pathophysiology of neurophysiologic signal change, and the influence of anesthesia on neurophysiologic responses.

♦ Neurophysiologic Monitoring Techniques

Somatosensory Evoked Potentials

SSEPs have been used to monitor scoliosis surgery since the pioneering paper by Nash and co-workers almost three decades ago.[7] SSEPs are elicited by stimulating a peripheral nerve; typically, the posterior tibial or peroneal nerve in the lower extremity or the ulnar or median nerve in the upper **(Fig. 4–1A).** Lower extremity SSEPs permit monitoring of the entire length of the spinal cord, brain stem, and cerebral hemispheres, whereas upper extremity SSEPs monitor only the cervical segment of the spinal cord and cephalad.

The ascending sensory volley triggered by posterior tibial or peroneal nerve stimulation enters the spinal cord through dorsal sacral and lumbar nerve roots at several segmental levels (S1-L4) and may ascend the spinal cord via multiple pathways. The general consensus is that the dorsal or posterior column spinal pathways are the primary sites of mediation for the SSEP.[8–11] Other pathways such as the dorsal spinocerebellar and

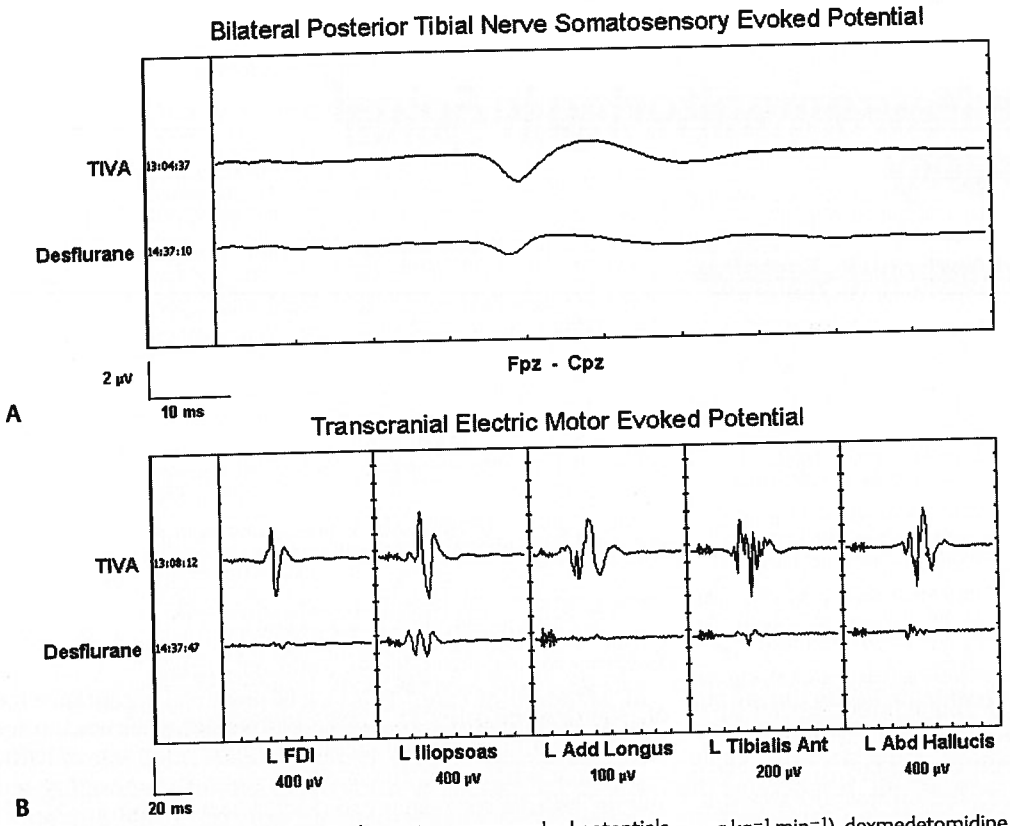

Figure 4–1 **(A)** Comparison of cortical somatosensory evoked potentials (SSEPs) to bilateral stimulation of the posterior tibial nerves recorded using a total intravenous anesthetic (TIVA) regimen (*upper trace*) versus 1.6% desflurane (*lower trace*). TIVA maintained with constant infusion of propofol (60 $\mu g\ kg^{-1}\ min^{-1}$), dexmedetomidine (0.2 $\mu g\ kg^{-1}\ h^{-1}$), and remifentanil (0.6 $\mu g\ kg^{-1}\ min^{-1}$). **(B)** Comparison of transcranial electric motor evoked potentials (TceMEPs) recorded from the same patient as in **Fig. 4–1A** using TIVA (*upper row of traces*) versus desflurane (*lower row of traces*).

anterolateral tracts may also contribute to the early SSEP responses that are used for monitoring spinal cord function.[12–14]

Upon ascending the spinal cord, the neural signal enters the medullary nuclei in the brain stem. Because there are no synapses in the ascending pathway until the medullary nuclei, SSEPs recorded up to the level of the lower brain stem predominantly reflect the integrity of peripheral nerve fibers and spinal cord white matter.

Beyond the medullary nuclei, the neural pathway mediating the SSEP continues as the internal arcuate fiber system, which crosses the brain stem and ascends as the medial lemniscal pathway, projecting to the thalamus. There is another synaptic junction in the thalamus that in turn projects to sensorimotor cortex where additional synaptic interaction may occur.

Transcranial Electric Motor Evoked Potentials

TceMEPs are neuroelectric events recorded from descending motor pathways, including the corticospinal tract (CST), spinal cord interneurons, anterior horn cells, peripheral nerves, and skeletal muscles after transcranial application of a high-voltage electrical stimulus **(Fig. 4–1B).** Although motor evoked potentials can also be elicited to transcranial magnetic stimulation, the technical challenges associated with this method preclude its routine use in the operating room.[15]

CST axons project from cortex through the internal capsule to the caudal medulla. Here, the fibers decussate and descend into the lateral and anterior funiculi of the spinal cord. In contrast with ascending spinal cord axons that mediate SSEPs, descending CST axons that mediate TceMEPs enter the spinal cord gray matter where they interact with spinal interneurons. The axons go on to synapse with α motor neurons that innervate peripheral muscle. Lateral CST fibers that synapse in the cervical segment of the spinal cord are arranged medially, followed laterally by fibers that synapse in the thoracic, lumbar, and sacral regions, respectively.[15,16]

TceMEPs mediated by the CST can be recorded from the spinal epidural or subdural space via a catheter-type electrode or from peripheral musculature using needle electrodes. Responses recorded from the epidural space are led by a D-wave triggered by direct depolarization of CST cells. In awake or lightly anesthetized patients, the D-wave is followed by a series of I-waves triggered indirectly via cortical synapses.[17] Descending cortical volleys then summate temporally and spatially to excite spinal α motor neurons that project to skeletal muscles, triggering compound muscle action potentials. Intraoperative monitoring of D-waves has particular value during excision of intramedullary spinal cord tumors; however, the need to place a recording electrode either percutaneously or through a laminotomy precludes routine use in most spine centers, particularly for cervical surgery. It is both easier and preferable to record myogenic motor responses from upper and lower extremity peripheral muscle for most spine procedures.

H-Reflex and F-Response

H-reflexes and F-responses can be recorded intraoperatively to supplement transcranial motor evoked potentials in the rapid detection of acute spinal shock. Both H-reflexes and F-responses aid in the intraoperative assessment of highly integrated spinal cord systems responsible for the control of complex motor behavior. As such, they provide a model for understanding the mechanisms of spinal cord pathophysiology.[18,19]

Severe acute spinal cord injury can lead to spinal shock that manifests as suppression of H-reflexes and F-responses secondary to hyperpolarization of caudal motor neurons within seconds of the insult.[20–22]

Despite having many advantages over TceMEPs, including fewer anesthesia-related constraints, H-reflexes and F-responses tend to be highly variable across patients and seem to be recordable, at least in our experience, in only approximately 60 to 70% of pediatric cases and probably less than 40% of adults. Yet, these responses serve as an excellent cross-check and backup to TceMEPs when they can be obtained.

Neurogenic Descending Evoked Potentials

Among the most controversial techniques used to monitor spinal cord function during scoliosis surgery is the neurogenic descending evoked potential. This potential is recorded over lower extremity peripheral nerves (e.g., at the popliteal fossa) in response to transosseous (spinous process, lamina) or epidural electrical stimulation of the spinal cord. Initially, it was thought to be mediated by spinal motor tracts.[23]

Because of its technical simplicity and robustness in the presence of most anesthetic agents, including neuromuscular blockade, the so-called neurogenic "motor" evoked potential (NMEP) became highly popular in IONM for more than a decade. Unfortunately, its early promise as a measure of motor pathway integrity has not been realized. Numerous studies have shown that both the neurogenic descending evoked potential and SSEP are mediated by common spinal cord pathways. That is, the neurogenic response is not a motor evoked potential but rather a descending potential mediated by antidromic activation of afferent somatosensory spinal cord pathways.[24–30] Despite the disappointing evidence that the NMEP reflects sensory rather than motor pathway function, its use should not be dismissed entirely. There are rare occasions where it is not possible to record an SSEP, TceMEP, or H-reflex, and yet, epidural stimulation at the rostral thoracic level elicits a descending neurogenic potential that is recordable over the popliteal fossa.[30]

Electromyography

Because SSEPs are neither sensitive nor specific in identifying injury to individual spinal nerve roots, owing to their multiple-nerve root mediation, spontaneous electromyography (spEMG) is used to detect mechanical trauma to specific spinal nerve roots during decompression, hook or screw insertion, removal of bony fragments, tumor resection, distraction, or traction. Microtrauma to a spinal nerve root results in ion depolarization, and the resultant neural volley triggers contraction of muscle innervated by that specific nerve root. Abrupt traction of a spinal nerve root or mechanical contact by a surgical instrument will elicit intermittent EMG "burst" or sustained EMG "train" activity. Gradual traction may elicit smaller or even no responses.

Transpedicular screw fixation has become an accepted adjuvant to corrective spine surgery. Because the pedicle is intimate with adjacent neural element (i.e., nerve root), the margin of error for proper screw placement is small, carrying potential morbidity (e.g., radicular pain, motor weakness) associated with incorrect screw placement.[31–33]

Stimulus-evoked electromyography (stEMG) is a quick, simple, safe and effective method for detecting pedicle wall violation during and after pedicle screw fixation.[34–42] The technique involves applying an electrical stimulus of known intensity to the pedicle screw head or, in the case of poly-axial screws, the hexagonal port or shaft, and recording EMG activity from muscles innervated by nerve root adjacent to the pedicle. If the pedicle wall is fractured, the nerve root will depolarize at a much lower applied current (<7.0 mA) than if the wall is intact, causing muscle contraction that is recorded as an EMG response **(Figs. 4–2A and 4–2B).**

A chronically compressed and/or irritated nerve root might have thickened dura or fewer/smaller functional fibers available for depolarization. Alternatively, it can be demyelinated, have axonal degeneration, or be ischemic. These conditions result in higher depolarization threshold, which could affect the efficacy of stimulated EMG for detection of cortical perforation. Because a chronically compressed root can show a depolarization threshold of 6 mA to direct stimulation rather than the normal 1 to 3 mA, it is important to adjust the screw stimulation intensity criterion for detection of a pedicle breach. This adjustment is determined empirically by having the surgeon directly stimulate the most pathologic root to determine its threshold.[4,43]

Brachial Plexus Monitoring

A tangential benefit of neuromonitoring during surgery for spinal deformity is the ability to use SSEPs and/or TceMEPs to identify impending brachial plexopathy or ulnar nerve neuropathy secondary to malpositioning of the patient. Intermittent monitoring of ulnar nerve SSEPs recorded either directly from the brachial plexus (Erb point) or cervical spine is highly effective in identifying emerging brachial plexopathy or ulnar neuropathy[2,3–5,44,45] **(Fig. 4–3).** TceMEPs recorded over deltoid, extensor carpi radialis, and first dorsal interosseous muscles can also provide early warning of emerging brachial plexus or peripheral nerve injury.

♦ Pathophysiology of Evoked Potential and Electromyography Changes

By convention, all evoked potentials are evaluated in terms of measured amplitude (voltage), latency (ms), and morphology (shape). To be accurate, interpretation of any change in these parameters must be considered relative to known or presumed underlying pathophysiologic processes. Otherwise,

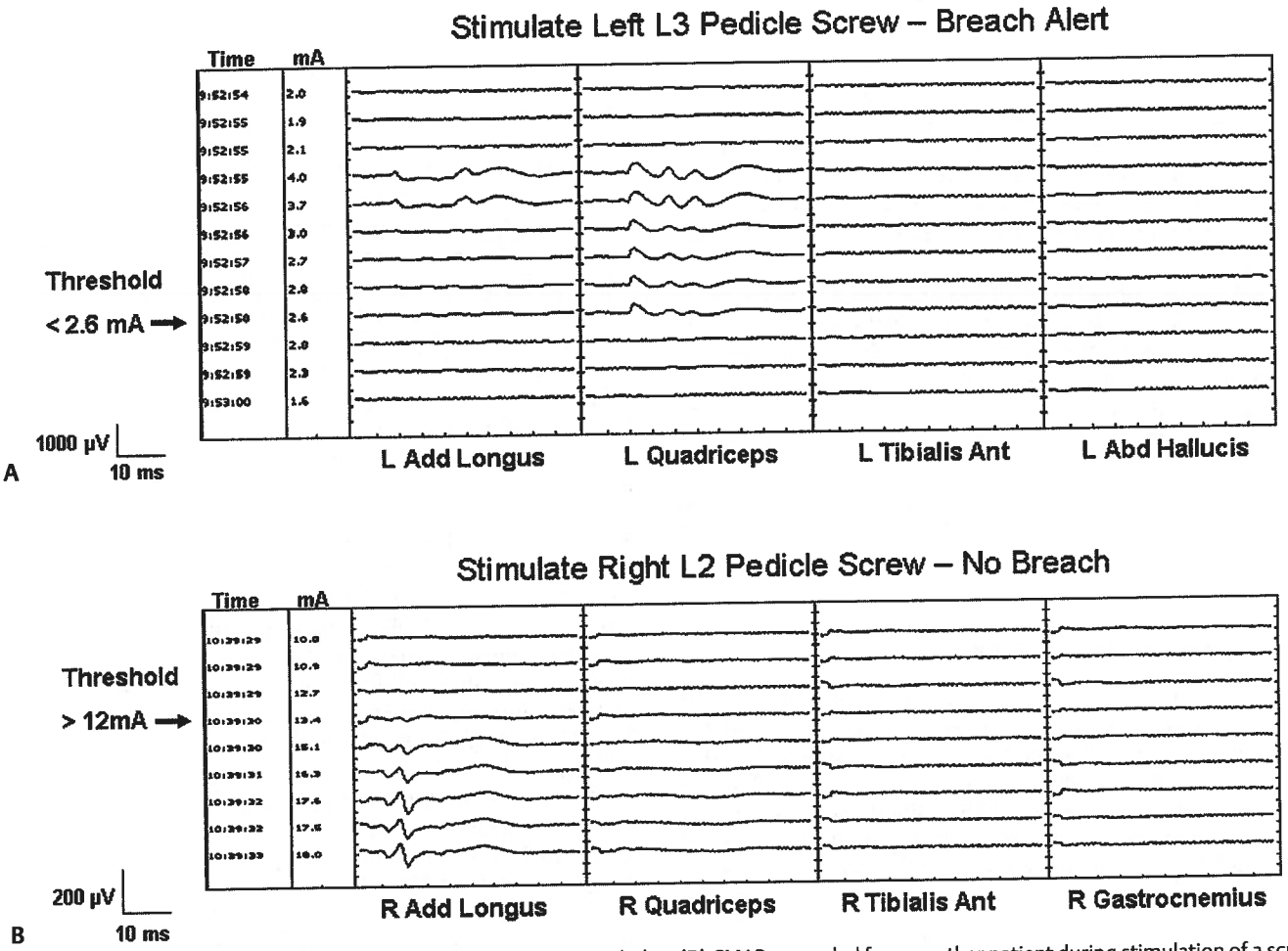

Figure 4–2 **(A)** Compound muscle action potentials (CMAPs) recorded during stimulation of a screw in the left L3 pedicle. Stimulation threshold for the left quadriceps muscle innervated by the L3 spinal nerve root is less than 2.6 mA, consistent with a medial breach of the pedicle wall. **(B)** CMAPs recorded from another patient during stimulation of a screw in the right L2 pedicle. Stimulation threshold for the right adductor longus muscle innervated by the L2 spinal nerve root is greater than 12 mA, consistent with an intact pedicle wall.

interpretation will be subjected to false-positive or false-negative error.

In spinal surgery for scoliosis correction, neurologic complications usually are secondary to mechanical (e.g., contusion) and/or ischemic insult. Neural injury in these situations always presents as a loss of evoked potential amplitude. Evoked potential latency almost never changes in the absence of an amplitude loss, other than for reasons associated with increased concentration of inhalational or intravenous anesthetic agents, lowering of core body or limb temperature, or perhaps hypercarbia. Hence, the oft-quoted 10% latency prolongation rule commonly used to define a significant SSEP change creates an inordinate number of false-positive alerts.

If injury occurs, whether due to contusion or ischemia, a cascade of physiologic change involving sodium, potassium, and calcium channels occurs. This cascade causes blockage of axonal transmission while leading ultimately to an uncoupling of oxidative phosphorylation, thereby precluding ATP production.[46,47] The net result is loss of cellular function and structural integrity, which manifests as a drop in evoked potential amplitude, not a prolongation of latency.[3,4,7,43]

Contusions to the spinal cord often result in a transient spinal cord conduction block and thus marked amplitude suppression (50 to 75%) of SSEPs and/or TceMEPs that should resolve within approximately 15 to 20 minutes. Recovery from such change is usually aided by increasing mean arterial blood pressure (MAP) to promote improved spinal cord perfusion, as well as temporary cessation of further surgical maneuvers. More serious concussive injury, such as that caused by an uncontrolled surgical instrument (e.g., osteotome) or a thoracic pedicle screw migrating to the spinal cord, will obliterate both sensory and motor evoked potentials entirely.[5,47,48]

Spinal cord ischemia most often is due to (1) stretching of critical spinal cord vascular supply during corrective maneuvers or placement of a cervical strut graft, (2) prolonged hypotension, and/or (3) vascular insufficiency associated with ligation of anterior segmental arteries.[5,49,50] Speed of corrective maneuvers also seems to play a role in developing myelopathy. This is particularly important as it relates to hemodynamic management of the patient. Slow corrective maneuvers combined with maintenance of mean arterial blood pressure near normal promote tissue accommodation to

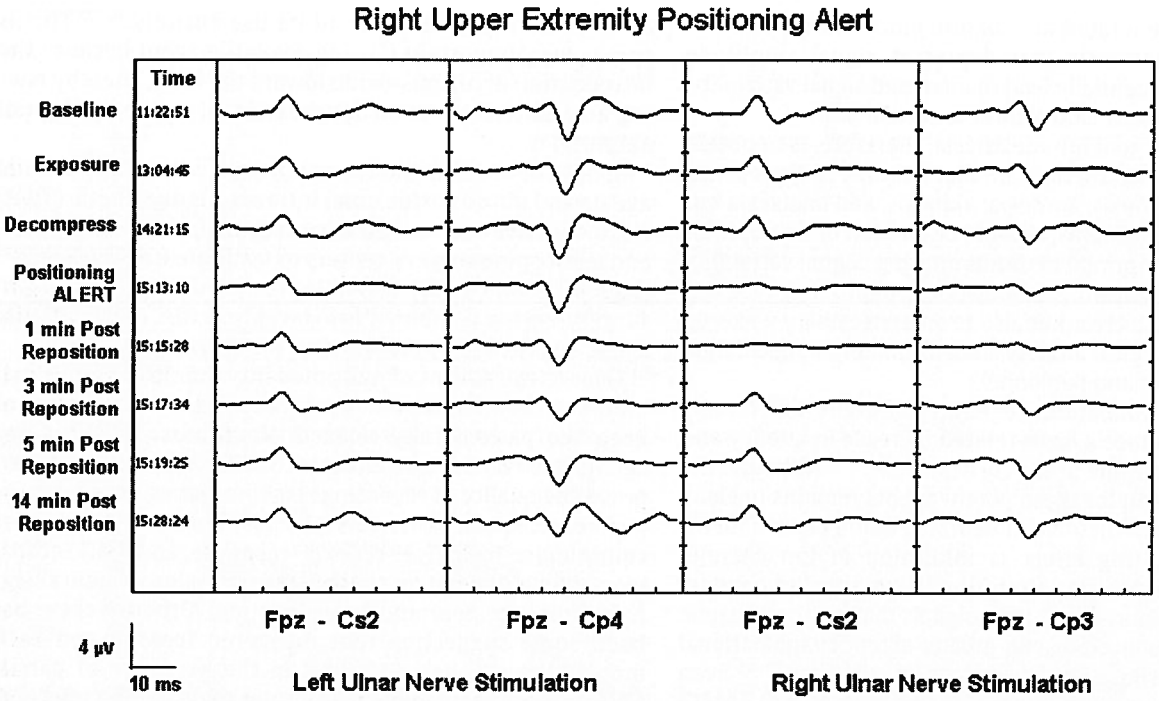

Figure 4–3 Right ulnar nerve somatosensory evoked potential (SSEP) attenuation consistent with ulnar nerve compression, presenting several hours after initial positioning of the patient for posterior spinal surgery. Responses resolved within 5 minutes of repositioning the arm.

applied elongation while compensating for changes in spinal cord perfusion pressure.[5] Prolonged hypotension, whether induced or systemic, can be a predisposing factor for spinal cord vascular injury.[5,50] To minimize risk of spinal cord ischemia, it is prudent to avoid hypotension once the spine is exposed. TceMEPs are particularly sensitive to blood pressure changes and can be used quite effectively for titration; however, the spinal cord will withstand much of a hypotensive state **(Fig. 4–4)**.

Because the vascular supply to regions of the spinal cord subserving somatosensory and motor function is different, SSEPs and TceMEPs can show differential sensitivity to ischemic spinal cord insult. The posterior column sensory pathways that mediate the SSEP are supplied by the posterior spinal arteries, whereas the anterior two thirds of the spinal cord, including regions mediating the TceMEP, are fed by the anterior spinal artery. It is entirely possible, therefore, to have selective loss of an SSEP with complete sparing of motor function as was reported nearly two decades ago by Schubert et al.[51] Conversely, loss of motor function with sparing of SSEPs can occur after selective compromise of the vascular supply from the anterior spinal artery, as in the case of anterior spinal artery syndrome.[52,53]

Spinal shock after acute spinal cord injury is characterized in part by transient depression of spinal cord reflexes below the level of injury and is thought to involve heightened presynaptic inhibition and hyperpolarization of the spinal motor neurons.[54,55] The H-reflex and F-response, respectively, seem to be exquisitely sensitive to these changes. As a result, they may actually disappear prior to a loss of TceMEPs, thereby serving as an early harbinger of neurologic disaster. In those cases where they can be recorded successfully, the H-reflex and F-response can serve as useful adjuncts to TceMEPs and SSEPs; however, the poor reliabilty of these responses, particularly in adults who often present with complex medical issues, precludes their routine use and hence limits their overall value.

Spinal nerve roots are susceptible to injury via two mechanisms. Mechanical injury can occur to the proximal portions of the dorsal and ventral roots, where they divide into rootlets and minirootlets.[56] The nerve root becomes susceptible to mechanical injury at the site of this division because the axons are enclosed by a thin root sheath, cerebrospinal fluid, and meninges, and lack the protective covering of epineurium and perineurium that is present in peripheral nerve.[57] There also seems to be an area of hypovascularity between the proximal and middle third of the dorsal and ventral roots, making them susceptible both to mechanical and ischemic insult.[58] If there is microtrauma leading to mechanical or metabolic irritation of the nerve root, such as with pedicle screw impingement, the root will depolarize, resulting in an action potential that ultimately gives rise to the release of acetylcholine and depolarization of the motor end plate of innervated muscle fiber. This microtrauma can be identified, both visually and acoustically, by monitoring electromyographic activity, as was discussed previously.

♦ Effects of Anesthetics on Neurophysiologic Signals

The success of intraoperative neuromonitoring is highly dependent on anesthetic management. Essentially, all anesthetic agents depress synaptic function, both in brain and spinal cord gray matter.[59] As a result, neurophysiologic signals that

traverse or are generated at synaptic junctions are also depressed. Any anesthetic that depresses signal amplitude excessively will potentially lead to increased signal variability, interpretive ambiguity, and clinical uncertainty.[60]

The underlying goal for anesthesia, therefore, is to obtain and maintain an anesthetic state that not only is appropriate for achieving hypnosis, amnesia, akinesis, and analgesia but also allows for continuous, reliable evaluation of neurophysiologic signals for optimal neuromonitoring. Signal variability resulting from alterations in anesthetic depth may lead not only to interpretive error but also to an unnecessary wake-up test, increased surgical anxiety, and, ultimately, surgical mistrust of IONM data and personnel.

In general, all inhalational agents (isoflurane, desflurane, sevoflurane) produce a dose-related increase in latency and reduction in amplitude of the cortical SSEP.[61–63] Although the exact sites of action for these potent agents remains unclear, the gases appear to dissolve in neuronal blood plasma membrane. The resulting effect is inhibition of ion channel function with significant alteration in synaptic and axonal transmission.[59] Neurophysiologic signals that rely on synaptic function are influenced to a far greater extent by inhalational agents than are those not dependent on synapses.[61–63] Even at steady state, low end-tidal concentrations (0.25 to 0.5 MAC) of inhalational agent, neurophysiologic response amplitude not only can become highly unstable and variable but also in many instances may be either too small to detect significant change or completely obliterated.[64,65]

The effect of potent anesthetics is much smaller on the subcortical SSEP recorded over cervical spine than on its cortical counterpart and is minimal on spinal epidural or peripheral responses. In the past, when the only modality monitored was the SSEP, it was possible to avoid the adverse effects of inhalational anesthesia simply by recording a subcortical potential in the presence of muscle relaxation.[66,67]

The depressive effects of volatile anesthetics on the excitability of motor pathways that mediate TceMEPs is of particular significance today, given the ascendant role of TceMEPs for intraoperative monitoring of spinal cord function. Unfortunately, as has been the historical case with SSEP monitoring, considerable controversy exists about the degree to which volatile agents depress myogenically recorded TceMEP amplitudes.[15,68–73]

TceMEP amplitude depression in the presence of a volatile anesthetic is due to the blocking of synaptic transmission at the cortical and spinal anterior horn cell levels.[59] Evidence to support this conclusion comes from comparison of anesthetic effects on motor signal transmission in the presence and absence of synapses. D-waves, which are generated and recorded prior to encountering synapses in the anterior horn, remain relatively unaffected by therapeutic concentrations of inhalational agent. In contrast, the H-reflex, which is mediated by a monosynaptic pathway through the anterior horn, is amplitude suppressed by 30 to 50% under similar anesthetic conditions, suggesting inhibition at the α motor neuron level.[74,75]

In contrast with ongoing controversies about the effects of volatile anesthetic gases on SSEPs and myogenic TceMEPs, there seems to be general consensus that the effects of nitrous oxide on cortical SSEP and TceMEP amplitudes are sufficiently great to avoid its use entirely.[76–80] This is particularly important if using a volatile agent because the introduction of nitrous-oxide lowers the MAC, thereby having an additive effect on suppression of evoked potential amplitudes.

In light of the difficulties encountered with use of volatile agents and nitrous oxide, total intravenous anesthetic (TIVA) regimens have been adopted in many high-volume pediatric and adult spine surgery centers to facilitate IONM[15,50,72,80–83] **(Figs. 4–1A and 4–1B).** If TIVA is precluded, one should begin surgery with a combined low-level (e.g., 0.3 MAC) volatile agent, augmented by combination intravenous drugs.

Prior to the advent of multimodality monitoring of spinal motor tract and nerve root function, it was commonplace to keep the patient fully relaxed. Neuromuscular blocking agents have no adverse effect on SSEPs and may in fact improve the quality of recordings by eliminating myogenic interference. In contrast, neuromuscular blockade (NMB) does compromise TceMEP, H-reflex, F-response, and EMG recordings, which depend on reliable transmission of neural signals across the neuromuscular junction. Although there has been some suggestion that myogenic TceMEP and EMG monitoring can be conducted in the presence of partial NMB,[84–86] there are many reasons not to do so. The effects of NMB can vary between the upper and lower extremities, between the left and right sides of the body, and between muscles within single limbs, making it difficult if not impossible to maintain a homogeneous state of partial NMB throughout the body. When combined with the difficulty of maintaining a constant state of partial NMB across time and the interactive effects that volatile and intravenous anesthetics have with the pharmacodynamics and pharmacokinetics of nondepolarizing relaxants, the uncertainty introduced to IONM decision-making by use of partial NMB can be significant.

Surprisingly little is known about the influence of anesthesia on spinal cord blood perfusion and metabolism as compared with that of the brain. During spine surgery, stretching of the spinal cord vascular supply or mechanical compression of the spinal cord from tumor tissue, herniated disk, boney displacement, and the like can compromise spinal cord perfusion pressure, thereby reducing spinal cord blood flow (SCBF). When coupled with the uncertain influences of anesthesia on SCBF, it becomes particularly important to be vigilant of the patient's systemic blood pressure during spine surgery to ensure adequate spinal cord perfusion. There is experimental evidence to suggest that moderate hypotension can produce irreversible paralysis in a partially compressed, albeit functionally intact spinal cord, whereas minimal hypotension can decrease spinal cord blood flow and electrical transmission.[87] IONM data provide convincing evidence of the relationship between mean arterial pressure and spinal cord perfusion[88–92] **(Fig. 4–4).**

Because blood flow to the spinal cord may not be as autoregulated as that to the brain, the spinal cord may be more predisposed to ischemic injury when stressed during hypotension. In some circumstances, prolonged systemic or deliberate hypotension could lead to spinal cord vascular injury.[5] Hence, there is justification to maintain the patient's

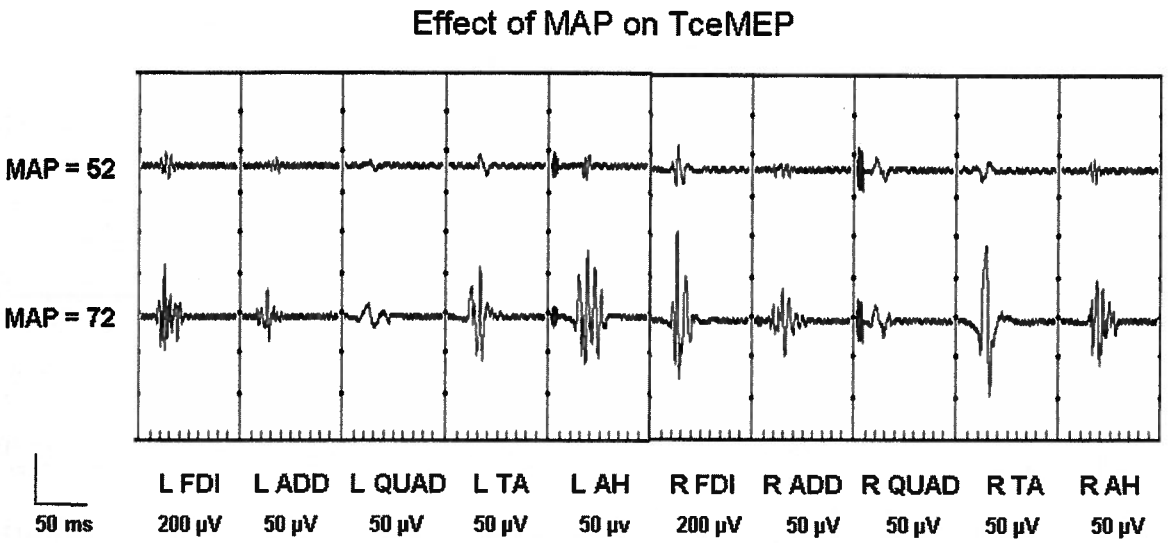

Figure 4–4 Comparison of transcranial electric motor evoked potentials (TceMEPs) recorded with mean arterial pressure at 52 mm Hg (*top row of traces*) and 72 mm Hg (*lower row of traces*). TceMEP attenuation during the period of reduced systemic blood pressure is consistent with decreased blood flow to the spinal cord. Muscle abbreviations: FDI, first dorsal interosseous; ADD, adductor longus; QUAD, quadriceps; TA, tibialis anterior; AH, abductor hallucis.

intraoperative MAP at or above that when awake. Maintenance of MAP in the mid 60 mm Hg range during the early part of surgery is usually adequate to control blood loss. After exposure, elevation of MAP above 70 mm Hg facilitates spinal cord perfusion during the application of corrective forces. If TceMEP amplitudes decrease significantly, however, the first interventional step should be to raise the MAP to 90 mm Hg. In most instances, this will restore amplitudes to baseline values. A similar approach has been described for prevention of spinal cord vascular injury during cervical spine surgery.[52]

♦ Conclusion

Recent advances in IONM provide improved sensitivity to iatrogenic injury during corrective surgery for spinal deformity. A multimodality approach to IONM based on a solid understanding of the pathophysiology of neurophysiologic signal change and anesthesia influences on monitored signals facilitates early detection of evolving injury and timely intervention and prevention of permanent neurologic deficits.

References

1. Vauzelle C, Stagnara P, Jouvinroux P. Functional monitoring of spinal cord activity during spinal surgery. Clin Orthop Relat Res 1973;93: 173–178
2. Schwartz DM, Drummond DS, Schwartz JA, et al. Neurophysiological monitoring during scoliosis surgery: a multimodality approach. Semin Spine Surg 1997;9:97–111
3. Schwartz DM, Sestokas AK, Turner LA, Morledge DE, DiNardo AA Jr, Beacham SG. Neurophysiological identification of iatrogenic neural injury during complex spine surgery. Semin Spine Surg 1998;10: 242–251
4. Schwartz DM, Wierzbowski LR, Fan D, Sestokas AK. Surgical neurophysiologic monitoring. In: Vaccaro A, Betz R, Zeidman S, eds. Principles and Practices of Spine Surgery. Philadelphia: Mosby; 2003: 115–126
5. Drummond DS, Schwartz DM, Johnston D, Farmer J. Neurological injury complicating surgery. In: Dewald R, ed. Spinal Deformities: The Comprehensive Text. New York: Thieme Medical Publishers; 2003: 615–625
6. MacDonald DB, Al Zayed Z, Khoudeir I, Stigsby B. Monitoring scoliosis surgery with combined multiple pulse transcranial electric motor and cortical somatosensory-evoked potentials from the lower and upper extremities. Spine 2003;28:194–203
7. Nash CL Jr, Lorig RA, Schatzinger LA, Brown RH. Spinal cord monitoring during operative treatment of the spine. Clin Orthop Relat Res 1977;126:100–105
8. Cohen AR, Young W, Ransohoff J. Intraspinal localization of the somatosensory evoked potential. Neurosurgery 1981;9:157–162
9. Cusick JF, Myklebust J, Larson SJ, Sances A Jr. Spinal evoked potentials in the primate: neural substrate. J Neurosurg 1978;49:551–557
10. Larson SJ, Sances A Jr, Christenson PC. Evoked somatosensory potentials in man. Arch Neurol 1966;15:88–93
11. Macon JB, Poletti CE, Sweet WH, Ojemann RG, Zervas NT. Conducted somatosensory evoked potentials during spinal surgery. Part 2: clinical applications. J Neurosurg 1982;57:354–359
12. York DH. Somatosensory evoked potentials in man: differentiation of spinal pathways responsible for conduction from the forelimb vs hindlimb. Prog Neurobiol 1985;25:1–25
13. Powers SK, Bolger CA, Edwards MS. Spinal cord pathways mediating somatosensory evoked potentials. J Neurosurg 1982;57:472–482

14. Simpson RK Jr, Blackburn JG, Martin HF III, Katz S. Peripheral nerve fiber and spinal cord pathway contributions to the somatosensory evoked potential. Exp Neurol 1981;73:700–715

15. Gugino L, Schwartz DM. Monitoring motor evoked potentials. Welwyn Garden City, Hertfordshire, UK: Digitimer Ltd.; 2002

16. Amassian VE, Stewart M, Quirk GJ, Rosenthal JL. Physiological basis of motor effects of a transient stimulus to cerebral cortex. Neurosurgery 1987;20:74–93

17. Amassian VE. Animal and human motor system neurophysiology related to intraoperative monitoring. In: Deletis V, Shils JL, eds. Neurophysiology in Neurosurgery. San Diego, CA: Academic Press; 2002: 3–24

18. Leppanen R, Maguire J, Wallace S, Madigan R, Draper V. Intraoperative lower extremity reflex muscle activity as an adjunct to conventional somatosensory-evoked potentials and descending neurogenic monitoring in idiopathic scoliosis. Spine 1995;20:1872–1877

19. Leis AA, Zhou HH, Mehta M, Harkey HL III, Paske WC. Behavior of the H-reflex in humans following mechanical perturbation or injury to rostral spinal cord. Muscle Nerve 1996;19:1373–1382

20. Leis AA, Kronenberg MF, Stetkarova I, Paske WC, Stokic DS. Spinal motoneuron excitability after acute spinal cord injury in humans. Neurology 1996;47:231–237

21. Barnes CD, Joynt RJ, Schottelius BA. Motoneuron resting potentials in spinal shock. Am J Physiol 1962;203:1113–1116

22. Walmsley B, Tracey DJ. The effect of transection and cold block of the spinal cord on synaptic transmission between Ia afferents and motoneurons. Neuroscience 1983;9:445–451

23. Owen JH, Bridwell KH, Grubb R, et al. The clinical application of neurogenic motor evoked potentials to monitor spinal cord function during surgery. Spine 1991;16:S385–S390

24. Su CF, Haghighi SS, Oro JJ, Gaines RW. "Backfiring" in spinal cord monitoring. High thoracic spinal cord stimulation evokes sciatic response by antidromic sensory pathway conduction, not motor tract conduction. Spine 1992;17:504–508

25. Leppanen RE, Madigan R, Sears C, Maguire J, Wallace S, Captain J. Intraoperative collision studies demonstrate descending spinal cord stimulated evoked potentials and ascending somatosensory evoked potentials are mediated through common pathways. Abstract. Clin Neurophysiol 1999;16:170

26. Toleikis JR, Skelly JP, Carlvin AO, Burkus JK. Spinally elicited peripheral nerve responses are sensory rather than motor. Clin Neurophysiol 2000;111:736–742

27. Deletis V. The 'motor' inaccuracy in neurogenic motor evoked potentials. Clin Neurophysiol 2001;112:1365–1366

28. Leppanen RE. Faces of spine care. From the electrodiagnostics lab. Descending neurogenic evoked potentials. Spine J 2004;4:713–716

29. Poncelet L, Michaux C, Balligand M. Motor evoked potentials induced by electrical stimulation of the spine in dogs: which structures are involved? Electroencephalogr Clin Neurophysiol 1995;97:179–183

30. Schwartz DM, Drummond DS, Ecker ML. Influence of rigid spinal instrumentation on the neurogenic motor evoked potential. J Spinal Disord 1996;9:439–445

31. Matsuzaki H, Tokuhashi Y, Matsumoto F, Hoshino M, Kiuchi T, Toriyama S. Problems and solutions of pedicle screw plate fixation of lumbar spine. Spine 1990;15:1159–1165

32. Weinstein JN, Spratt KF, Spengler D, Brick C, Reid S. Spinal pedicle fixation: reliability and validity of roentgenogram-based assessment and surgical factors on successful screw placement. Spine 1988;13:1012–1018

33. West JL III, Ogilvie JW, Bradford DS. Complications of the variable screw plate pedicle screw fixation. Spine 1991;16:576–579

34. Calancie B, Lebwohl N, Madsen P, Klose KJ. Intraoperative evoked EMG monitoring in an animal model. A new technique for evaluating pedicle screw placement. Spine 1992;17:1229–1235

35. Calancie B, Madsen P, Lebwohl N. Stimulus-evoked EMG monitoring during transpedicular lumbosacral spine instrumentation. Initial clinical results. Spine 1994;19:2780–2786

36. Maguire J, Wallace S, Madigan R, Leppanen R, Draper V. Evaluation of intrapedicular screw position using intraoperative evoked electromyography. Spine 1995;20:1068–1074

37. Glassman SD, Dimar JR, Puno RM, Johnson JR, Shields CB, Linden RD. A prospective analysis of intraoperative electromyographic monitoring of pedicle screw placement with computed tomographic scan confirmation. Spine 1995;20:1375–1379

38. Lenke LG, Padberg AM, Russo MH, Bridwell KH, Gelb DE. Triggered electromyographic threshold for accuracy of pedicle screw placement. An animal model and clinical correlation. Spine 1995;20:1585–1591

39. Darden BV II, Wood KE, Hatley MK, Owen JH, Kostuik J. Evaluation of pedicle screw insertion monitored by intraoperative evoked electromyography. J Spinal Disord 1996;9:8–16

40. Toleikis JR, Skelly JP, Carlvin AO, et al. The usefulness of electrical stimulation for assessing pedicle screw placements. J Spinal Disord 2000;13:283–289

41. Danesh-Clough T, Taylor P, Hodgson B, Walton M. The use of evoked EMG in detecting misplaced thoracolumbar pedicle screws. Spine 2001;26:1313–1316

42. Anderson DG, Wierzbowski LR, Schwartz DM, Hilibrand AS, Vaccaro AR, Albert TJ. Pedicle screws with high electrical resistance: a potential source of error with stimulus-evoked EMG. Spine 2002;27:1577–1581

43. Schwartz DM, Sestokas AK. A systems-based algorithmic approach to intraoperative neurophysiological monitoring during spinal surgery. Semin Spine Surg 2002;14:136–145

44. Schwartz DM, Drummond DS, Hahn M, Ecker ML, Dormans JP. Prevention of positional brachial plexopathy during surgical correction of scoliosis. J Spinal Disord 2000;13:178–182

45. Schwartz DM, Sestokas AK, Albert TJ, et al. Neurophysiological identification of position-induced neurologic injury during anterior cervical spine surgery. J Clin Monit Comput (in press).

46. Branston NM, Symon L. Cortical EP, blood flow, and potassium changes in experimental ischemia. In: Barber C, ed. Evoked Potentials. Baltimore: University Park Press; 1980:527–553

47. Seyal M, Mull B. Mechanisms of signal change during intraoperative somatosensory evoked potential monitoring of the spinal cord. J Clin Neurophysiol 2002;19:409–415

48. Guerit JM. Neuromonitoring in the operating room: why, when, and how to monitor? Electroencephalogr Clin Neurophysiol 1998;106:1–21

49. Bridwell KH, Lenke LG, Baldus C, Blanke K. Major intraoperative neurologic deficits in pediatric and adult spinal deformity patients. Incidence and etiology at one institution. Spine 1998;23:324–331

50. Hilibrand AS, Schwartz DM, Sethuraman V, Vaccaro AR, Albert TJ. Comparison of transcranial electric motor and somatosensory evoked potential monitoring during cervical spine surgery. J Bone Joint Surg Am 2004;86-A:1248–1253

51. Schubert A, Todd MM, Luerssen TG, Hicks GE. Loss of intraoperative evoked responses during dorsal column surgery associated with isolated postoperative sensory deficit. J Clin Monit 1987;3:277–281

52. Zornow MH, Grafe MR, Tybor C, Swenson MR. Preservation of evoked potentials in a case of anterior spinal artery syndrome. Electroencephalogr Clin Neurophysiol 1990;77:137–139

53. Minahan RE, Sepkuty JP, Lesser RP, Sponseller PD, Kostuik JP. Anterior spinal cord injury with preserved neurogenic 'motor' evoked potentials. Clin Neurophysiol 2001;112:1442–1450

54. Calancie B, Broton JG, Klose KJ. Evidence that alterations in presynaptic inhibition contribute to segmental hypo- and hyperexcitability after spinal cord injury in man. Electroencephalogr Clin Neurophysiol 1993;89:177–186

55. Leis AA, Kronenberg MF, Stetkarova I, Paske WC, Stokic DS. Spinal motoneuron excitability after acute spinal cord injury in humans. Neurology 1996;47:231–237

56. Olmarker K. Spinal nerve root compression. Nutrition and function of the porcine cauda equina compressed in vivo. Acta Orthop Scand Suppl 1991;242:1–27

57. Berthold CH, Carlstedt T, Corneliuson O. Anatomy of the nerve root at the central-peripheral transitional region. In: Dyck PJ, Thomas PK, Lambert EH, Bunge R, eds. Peripheral Neuropathy. Philadelphia: W.B. Saunders; 1984:156–217

58. Howe JF, Loeser JD, Calvin WH. Mechanosensitivity of dorsal root ganglia and chronically injured axons: a physiological basis for the radicular pain of nerve root compression. Pain 1977;3:25–41

59. Antognini JE, Carstens EE, Raines DE. Neural Mechanisms of Anesthesia. Totowa, NJ: Human Press; 2003.

60. Schwartz DM, Sestokas AK. The use of neuromonitoring for neurological injury detection and implant accuracy. In: Vaccaro AR, Regan JJ, Crawford AH, Benzel ED, Anderson DG, eds. Complications of Pediatric and Adult Spinal Surgery. New York: Marcel Dekker; 2004:159–172

61. Sloan TB. Evoked potentials. In: Albin MA, ed. Textbook of Neuroanesthesia with Neurosurgical and Neuroscience Perspectives. New York: McGraw-Hill; 1997:221–276

62. Sloan TB. Anesthetic effects on electrophysiologic recordings. J Clin Neurophysiol 1998;15:217–226

63. Sloan TB, Heyer EJ. Anesthesia for intraoperative neurophysiologic monitoring of the spinal cord. J Clin Neurophysiol 2002;19:430–443

64. Zentner J, Albrecht T, Heuser D. Influence of halothane, enflurane, and isoflurane on motor evoked potentials. Neurosurgery 1992;31:298–305

65. Bernard JM, Pereon Y, Fayet G, Guiheneuc P. Effects of isoflurane and desflurane on neurogenic motor- and somatosensory-evoked potential monitoring for scoliosis surgery. Anesthesiology 1996;85:1013–1019

66. Abel MF, Mubarak SJ, Wenger DR, Costello J, Hicks GE. Brainstem evoked potentials for scoliosis surgery: a reliable method allowing use of halogenated anesthetic agents. J Pediatr Orthop 1990;10:208–213

67. Ecker ML, Dormans JP, Schwartz DM, Drummond DS, Bulman WA. Efficacy of spinal cord monitoring in scoliosis surgery in patients with cerebral palsy. J Spinal Disord 1996;9:159–164

68. Haghighi SS, Madsen R, Green KD, Oro JJ, Kracke GR. Suppression of motor evoked potentials by inhalation anesthetics. J Neurosurg Anesthesiol 1990;2:73–78

69. Kalkman CJ, Drummond JC, Ribberink AA. Low concentrations of isoflurane abolish motor evoked responses to transcranial electrical stimulation during nitrous oxide/opioid anesthesia in humans. Anesth Analg 1991;73:410–415

70. Calancie B, Klose KJ, Baier S, Green BA. Isoflurane-induced attenuation of motor evoked potentials caused by electrical motor cortex stimulation during surgery. J Neurosurg 1991;74:897–904

71. Glassman SD, Shields CB, Linden RD, Zhang YP, Nixon AR, Johnson JR. Anesthetic effects on motor evoked potentials in dogs. Spine 1993;18:1083–1089

72. Sloan TB, Rogers JN. Inhalational anesthesia alters the optimal interstimulus interval for multi-pulse transcranial motor evoked potentials in the baboon. Abstract. J Neurosurg Anesth 1996;8:346

73. Burke D, Bartley K, Woodforth IJ, Yakoubi A, Stephen JP. The effects of a volatile anaesthetic on the excitability of human corticospinal axons. Brain 2000;123(Pt 5):992–1000

74. Mavroudakis N, Vandesteene A, Brunko E, Defevrimont M, Zegers de Beyl D. Spinal and brain-stem SEPs and H reflex during enflurane anesthesia. Electroencephalogr Clin Neurophysiol 1994;92: 82–85

75. Zhou HH, Mehta M, Leis AA. Spinal cord motoneuron excitability during isoflurane and nitrous oxide anesthesia. Anesthesiology 1997;86: 302–307

76. Sebel PS, Flynn PJ, Ingram DA. Effect of nitrous oxide on visual, auditory and somatosensory evoked potentials. Br J Anaesth 1984;56:1403–1407

77. Sloan TB, Koht A. Depression of cortical somatosensory evoked potentials by nitrous oxide. Br J Anaesth 1985;57:849–852

78. Kalkman CJ, Traast H, Zuurmond WW, Bovill JG. Differential effects of propofol and nitrous oxide on posterior tibial nerve somatosensory cortical evoked potentials during alfentanil anaesthesia. Br J Anaesth 1991;66:483–489

79. Jellinek D, Platt M, Jewkes D, Symon L. Effects of nitrous oxide on motor evoked potentials recorded from skeletal muscle in patients under total anesthesia with intravenously administered propofol. Neurosurgery 1991;29:558–562

80. Schwartz DM, Schwartz JA, Pratt RE Jr, Wierzbowski LR, Sestokas AK. Influence of nitrous oxide on posterior tibial nerve cortical somatosensory evoked potentials. J Spinal Disord 1997;10:80–86

81. Scheufler KM, Zentner J. Total intravenous anesthesia for intraoperative monitoring of the motor pathways: an integral view combining clinical and experimental data. J Neurosurgery 2002;96:571–579

82. DiCindio S, Theroux M, Shah S, et al. Multimodality monitoring of transcranial electric motor and somatosensory-evoked potentials during surgical correction of spinal deformity in patients with cerebral palsy and other neuromuscular disorders. Spine 2003;28:1851–1855, discussion 1855–1856

83. Schwartz DM, Sestokas AK. Facilitated assessment of unconsciousness from morphologic changes in the bilateral posterior tibial nerve cortical somatosensory evoked potential under total intravenous propofol anesthesia during spine surgery. J Clin Monit Comput 2004;18: 201–206

84. Kalkman CJ, Drummond JC, Kennelly NA, Patel PM, Partridge BL. Intraoperative monitoring of tibialis anterior muscle motor evoked responses to transcranial electrical stimulation during partial neuromuscular blockade. Anesth Analg 1992;75:584–589

85. Lang EW, Beutler AS, Chesnut RM, et al. Myogenic motor-evoked potential monitoring using partial neuromuscular blockade in surgery of the spine. Spine 1996;21:1676–1686

86. Minahan RE, Riley LH III, Lukaczyk T, Cohen DB, Kostuik JP. The effect of neuromuscular blockade on pedicle screw stimulation thresholds. Spine 2000;25:2526–2530

87. Hukuda S, Wilson CB. Experimental cervical myelopathy: effects of compression and ischemia on the canine cervical cord. J Neurosurg 1972;37:631–652

88. Kai Y, Owen JH, Allen BT, Dobras M, Davis C. Relationship between evoked potentials and clinical status in spinal cord ischemia. Spine 1995;20:291–296

89. de Haan P, Kalkman CJ, Jacobs MJ. Spinal cord monitoring with myogenic motor evoked potentials: early detection of spinal cord ischemia as an integral part of spinal cord protective strategies during thoracoabdominal aneurysm surgery. Semin Thorac Cardiovasc Surg 1998; 10:19–24

90. Meylaerts SA, Jacobs MJ, van Iterson V, De Haan P, Kalkman CJ. Comparison of transcranial motor evoked potentials and somatosensory evoked potentials during thoracoabdominal aortic aneurysm repair. Ann Surg 1999;230:742–749

91. van Dongen EP, ter Beek HT, Schepens MA, et al. The relationship between evoked potentials and measurements of S-100 protein in cerebrospinal fluid during and after thoracoabdominal aortic aneurysm surgery. J Vasc Surg 1999;30:293–300

92. MacDonald DB, Janusz M. An approach to intraoperative neurophysiologic monitoring of thoracoabdominal aneurysm surgery. J Clin Neurophysiol 2002;19:43–54

Chapter 5

Anatomical Variants with Spinal Deformity

Christopher M. Bono and William Accousti

Spinal deformity presents several treatment challenges to the spine surgeon. Surgical planning focuses primarily on the methods and maneuvers deemed necessary to correct coronal and sagittal imbalances. These methods iatrogenically alter the spatial relationships of the vertebrae to one another, the head, and the pelvis through corrective forces applied with implanted spinal instrumentation. Various forms are available, including screws, hooks, rods, and plates that can be inserted into the anterior or posterior elements through several different approaches.

Among other factors, the relative safety and efficacy of instrumented correction of spinal deformity is influenced by the acceptability of the implants into or onto the vertebra. In their conception, spinal implants are designed in anticipation of normal anatomy. By definition, however, intervertebral relationships with spinal deformity are not normal. Furthermore, the morphology of the vertebral elements themselves is often abnormal, most characteristically exhibited as side-to-side asymmetry.[1–6] To additionally complicate matters, these anatomical variants can cause deviant relationships of neural and vascular structures to the spinal column.[7–9]

With growing interest in the origin and treatment of spinal deformity, knowledge concerning associated anatomical variants has recently increased. It is the purpose of the authors to review this emerging body of literature. By offering the reader a more thorough understanding of potentially unusual anatomy, the spine surgeon may plan a more effective and safe treatment plan.

♦ Vertebral Body

Scheuermann's Disease

In the thoracic spine, kyphosis normally ranges from 20 to 40 degrees. This is largely the result of gentle anteroposterior wedging of the thoracic vertebral bodies, in contrast with the lumbar spine in which normal lordosis ranging from 40 to 60 degrees is produced primarily by wedging of the disk spaces. By definition, Scheuermann's kyphosis entails at least 5 degrees of kyphosis produced by pronounced sagittal asymmetry of three or more consecutive vertebral bodies (**Fig. 5–1**).

Beyond diagnosing the disorder, the wedging of the vertebral bodies can have important intraoperative implications.

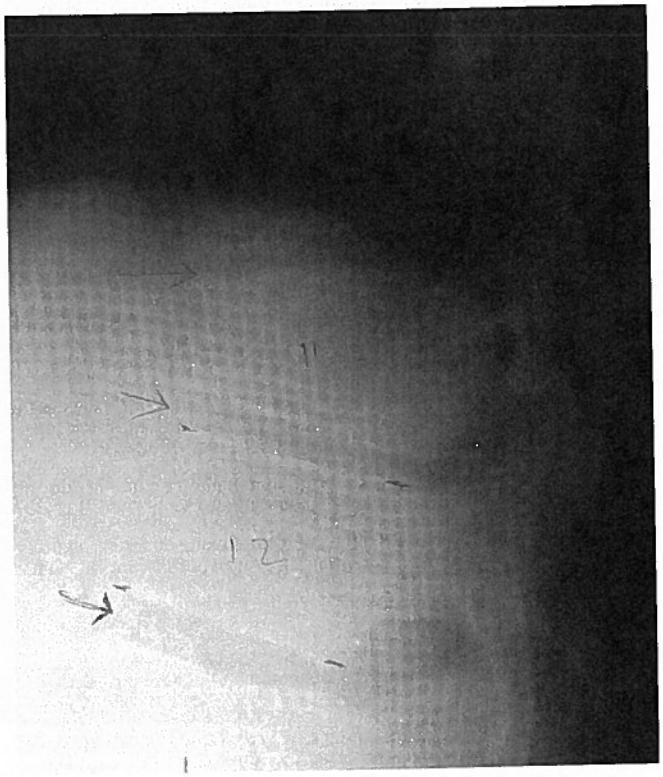

Figure 5–1 Lateral radiograph of a patient with Scheuermann's kyphosis demonstrating the characteristically wedged vertebral bodies.

When sizing and contouring anterior interbody devices, it should be recognized that after the hyperkyphosis has been corrected (usually through a posterior segmental construct), the intervertebral space will ultimately be trapezoidal, being much wider anteriorly than posteriorly.

Though they are not pathognomonic, another common feature of Scheuermann's disease is the presence of end-plate deformities known as Schmorl's nodes. It is believed they represent central herniations of disk into the vertebral body, possibly from weakening of the underlying cancellous bone. They can be readily recognized on plain films as radiolucencies within the vertebra surrounded by varying degrees of sclerotic bone.[10] On magnetic resonance (MR) images, hypointensive (dark) disk material can be seen invaginating the vertebral body through the end plate. Surgically, Schmorl's nodes represent a weakened end plate that may not survive aggressive maneuvers to remove the disk during fusion preparation. Care should be taken to avoid inadvertent curettage of the vertebral body during surgery.

Isthmic Spondylolisthesis

Isthmic spondylolisthesis can be associated with several anatomical variants, such as an elongated pars and incompetent posterior arch. The slipped vertebral body, most commonly L5, can have a trapezoidal shape (**Fig. 5–2**). It has been suggested that this is a reactive change to the inherent instability caused by incompetence of the posterior neural arch.[11] The presence and degree of vertebral body wedging has been correlated with the grade or severity of the slip.[12] The superior aspect of S1 often has an associated deformity in which the end plate is rounded or "domed."[11] It has been suggested that the aberrant morphology can contribute to the propensity of listhesis. In addition to possible prognostic significance, vertebral body malformation can have surgical implications. When performing interbody fusions, either from a posterior or anterior approach, it may be necessary to recontour the opposing end plates to better accept the flat surfaces of a bone graft strut or cage device.

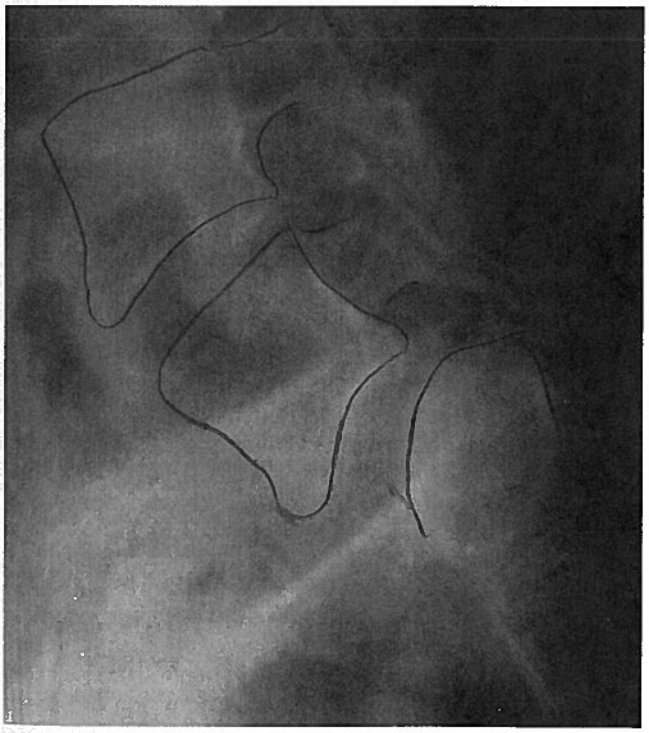

Figure 5–2 Isthmic spondylolisthesis can be associated with a wedge-shaped L5 vertebral body and a domed superior S1 vertebral body. This appears to be more common with high-grade slips.

Idiopathic Scoliosis

Although it is unclear whether it is a cause or effect,[1] morphologic asymmetry exists among and within the individual vertebra of patients with idiopathic scoliosis.[5,6,13] The vertebral body has been demonstrated to exhibit side-to-side asymmetry in patients with right thoracic scoliotic curves.[14,15] This appears to be most pronounced at the apex of the curve.[5] Others have suggested that sagittal asymmetry of the vertebral body also exists, finding that the apical thoracic vertebra can be lordotically wedged with anterior greater than posterior heights.[16] Vertebral body asymmetry may in fact be a secondary effect of spinal deformity. In a longitudinal prospective study, Xiong et al.[14] found that asymmetry tended to regress over a 2-year period after posterior segmental corrective surgery. Intraoperatively, morphological asymmetry of the vertebral body may have implications on insertion of vertebral body screws or interbody grafts.

♦ Ribs

Rib deformities are associated with scoliotic curves. The intimate interaction of the posterior aspects of the ribs, both at the costovertebral and costotransverse junctions, make them obligatorily vulnerable to changes in spinal column alignment. Rib humps are primarily the result of rotation of the vertebral bodies and thus the associated ribs.[17] The intercostal space becomes narrowed on the concave side of the curve; inversely, they are widened along the curve concavity. Because the ribs are not rigidly fixed to the vertebrae, once they have abutted, increasingly severe curves will cause angling of the rib in relation to the vertebrae. This costovertebral angle (**Fig. 5–3**) has been used as an indicator of curve severity. In the minority of cases, the most prominent apical rib is associated with the most rotated apical vertebra; usually, it is either a level above or below.[18] These anatomical considerations may be important when planning rib thoracoplasty or rib head resection.

♦ Pedicles

Pedicle screws have become an increasingly popular method of segmental fixation for spinal deformity correction. Pedicle screws are considered to be somewhat controversial in nondeformed spines; their insertion even more so in the deformed spine. Patients are typically younger, with smaller pedicular

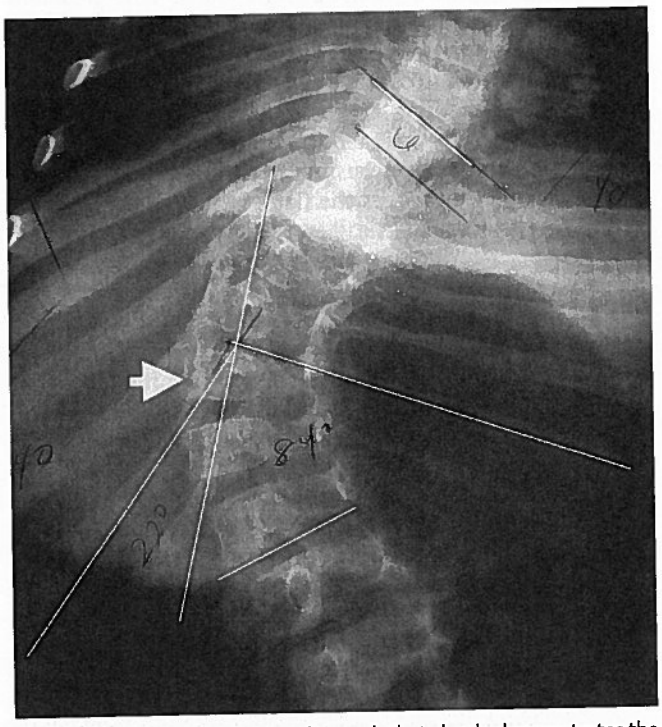

Figure 5–3 Anteroposterior radiograph that clearly demonstrates the differing rib-vertebral angles on either side of the curve in a patient with scoliosis.

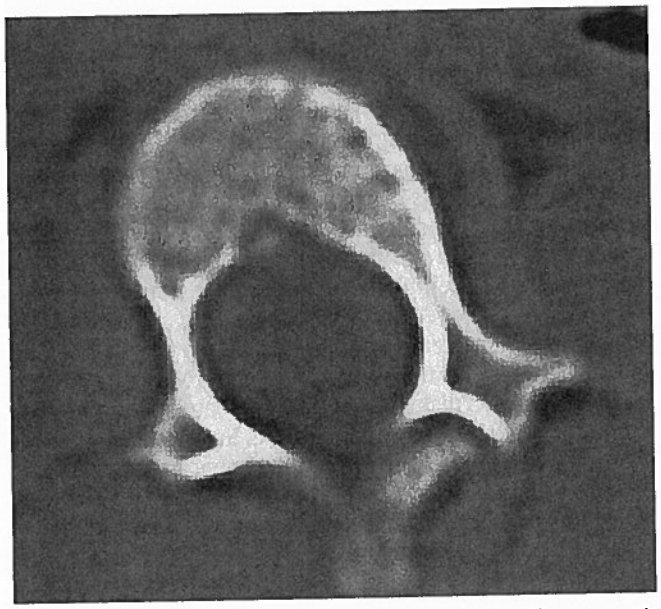

Figure 5–4 Axial computed tomography (CT) image demonstrating pedicle dysplasia (thinning) as well as side-to-side asymmetry.

dimensions that may not be large enough to accept standard-sized implants. To further complicate matters, pedicle morphology can be altered with spinal deformities, most notably idiopathic scoliosis.[2,3,5,6,13,14,19]

In patients with right-sided idiopathic thoracic scoliosis, Liljenqvist et al.[5] found that the pedicles were significantly thinner on the concave side of the curve. Specifically, concave pedicles had transverse endosteal widths (the most useful measurement in relation to pedicle screw containment) measuring between 2.3 mm to 3.2 mm; on the convex side the range was between 3.9 mm to 4.4 mm. In the lumbar spine, the pedicles were roughly symmetric. In a previous study,[6] the same group reported values for the middle (T5-T9) and lower (T10-T12) thoracic spine. The former demonstrated pedicle widths of 2.5 mm to 4.2 mm, whereas the latter ranged from 4.2 mm to 5.9 mm.

With a similar focus, Parent et al.[2] compared pedicle measurements from idiopathic scoliosis patients with dimensionally matched controls. Similar to Liljenqvist's group, they found thinner pedicles on the concave side of thoracic curves. In addition, pedicle length was increased and pedicle height was decreased in scoliotic spines, regardless of the side. Using MRI, Rajwani et al.[13] also compared scoliotic patients with normal controls, finding significantly greater pedicle asymmetry in affected individuals. Interestingly, normal patients exhibited some asymmetry as well, both of pedicle width and length. The longer pedicle in scoliotic or normal cases did not have a side-to-side predilection.

King et al.[19] more closely examined lumbar pedicles, finding them to be relatively symmetric in patients with idiopathic scoliosis. There was, however, a slight trend for larger transverse widths on the concavity (an opposite relationship than that observed in the thoracic spine[2,6]). Although greater than 90% of L3-L5 pedicles were at least 5.5 mm in width, only 34% and 42% of L1 and L2 segments fulfilled this criterion.

These findings suggest that containment of a screw within the bony confines of the pedicle, particularly on the concave side of the apical thoracic segments, may not be anatomically possible in many individuals with idiopathic scoliosis (**Fig. 5–4**). As an alternative technique, O'Brien et al.[4] suggested that lateral cortical screw breakout from a dysplastically narrow pedicle can still be considered contained if one considers the pedicle and rib as one complex. By measuring computed tomography (CT) scans of scoliotic patients, they found that this effective "pedicle-rib" complex ranged from 12.6 mm to 17.9 mm in transverse diameter. Subsequent biomechanical studies have demonstrated comparable pull-out strengths comparing such lateral extrapedicular to standard transpedicular insertion techniques.[20]

Other pedicle variants can be associated with spinal deformity. In some cases, the pedicles can be missing altogether. Villas and Barrios[21] reported a case of absent L2 pedicles in a patient with kyphoscoliosis. Strauss et al.[22] reported a case of absent thoracic pedicles in a patient with spinal deformity. Dysplastically narrowed pedicles can also be associated with isthmic spondylolisthesis, usually of the slipped vertebrae. This can preclude safe and adequate pedicle screw purchase, necessitating proximal extension of the construct.

♦ Spinous Processes

The spinous processes are a useful radiographic and surgical anatomical landmark. A central defect that divides the spinous processes into right and left halves (i.e., mild spina bifida)

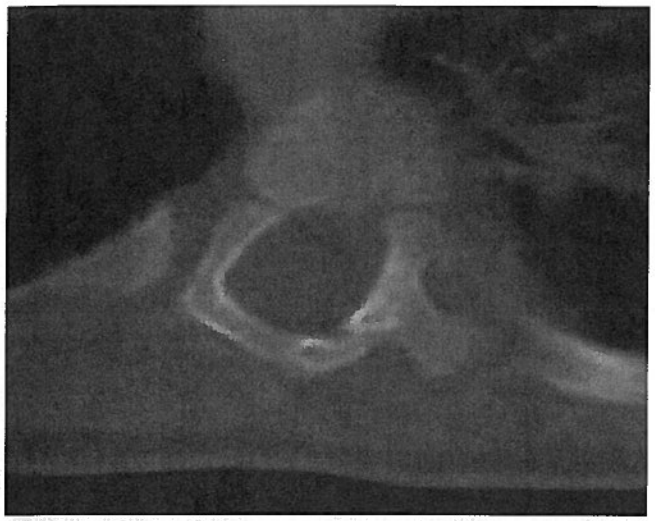

Figure 5–5 Axial CT image of a skeletally immature patient with scoliosis demonstrating that the spinous processes can be deviated from the midline.

is a common associated anomaly with isthmic spondylolisthesis. Kumar et al.[23] highlighted the importance of recognizing such defects preoperatively to avoid inadvertent extrance into the spinal canal or dura during operative exposure.

Spinous processes can be affected with idiopathic scoliosis as well. They frequently are deviated to one side, usually toward the concavity of the curve (**Fig. 5–5**). Recognizing that the spinous processes can be deformed in this manner, Herzenberg et al.[24] compared the amount of angulation measured by the Cobb method versus the "spinous process angle" method, which uses a line connecting the tips of the spinous processes on an anteroposterior radiograph. They found that, because of the medial-lateral deviation of the spinous processes, the latter method tended to underestimate the magnitude of the curve measured by the Cobb method.

♦ Facet Joints

The facet joint is an important stabilizer of the spine, contributing nearly between 20% and 40% of the resistance to torsional and axial compressive loads. The regional orientation of the facet joints allows proportionately more motion in one plane(s) and, conversely, resistance to motion in an other. The coronally oriented articular surfaces in the upper and middle thoracic facet joints allow more lateral flexion, and the sagittally oriented surfaces of the lower thoracic and upper lumbar joint surfaces enable more flexion-extension.

Asymmetric changes of the articular facet surfaces have been documented with idiopathic scoliosis.[3] Parent et al.[3] found that side-to-side area differences of the articular surfaces were greatest at the apex of the deformity. However, there did not appear to be an association with either the concavity or convexity of the curve.

The orientation of the facet joints in the low lumbar spine appears to correlate with the propensity for spondylolisthesis. Several studies have demonstrated that facet joints in patients with degenerative spondylolisthesis are more sagittally oriented. Kim and Lee[25] found that the risk for slip was 2.5 times greater with combined facet angles of less than 78 degrees (from the sagittal plane).

A more coronally oriented facet joint may be a risk factor for, or be the result of, isthmic spondylolisthesis. Miyake et al.[26] found that patients with high-grade spondylolisthesis had more coronally oriented facet joints than controls. They suggested that, with incompetence of the pars, decreased loading of the facet joint over time resulted in abnormal development. A converse causal relationship could not be excluded, however.

Some surgical procedures for low-grade degenerative or isthmic spondylolisthesis can involve motion-sparing techniques, such as dynamic stabilization or pars repair.[27] Preoperative evaluation of the orientation of the facet joints may be important when choosing such a technique over a fusion procedure. Patients with degenerative slips and sagittally oriented facet joints may be better treated with arthrodesis; conversely, patients with isthmic defects and normal to coronally oriented facets may be effectively stabilized by a pars repair.

♦ Spinal Cord

With three-dimensional deformity of the spine, the relationship between the spinal cord and the spinal column can change. Conceptually, the cord can be considered like a rubber band stretched within a long flexible tube. When the tube is perfectly straight, the rubber band will remain in its center. When the tube is bent in one direction, the rubber band, tethered at its proximal and distal ends, will migrate toward the side on the bend. If bent enough, the free space around the rubber band will be exceeded and the tube's walls will contact the rubber band. Clinically, this concept is illustrated in **Fig. 5–6** of a 19-year-old man with hyperkyphosis secondary to Scheuermann's disease. The spinal cord is draped over the posterior vertebral bodies, apparently indented by the protruding disks.

Scoliotic deformities can cause multiplanar deviation of the spinal cord within the canal (**Figs. 5–7A and 5–7B**). Because of its complexity, this relationship has been more extensively studied than sagittal plane deformities. Using MR images, Liljenqvist et al.[5] found the epidural space between the spinal cord and the pedicle to be less than 1 mm on the concave side at the apical vertebra; this space measured between 3 mm and 5 mm on the convex side. Maruta et al.[9] found that axial rotation of the spinal cord had statistically significant correlation with the amount of rotation of the apical vertebra as well as the magnitude of the scoliosis.

These data may have significance to the relative safety of some instrumentation types. The spinal cord appears to be intimately related to the pedicles and spinal canal walls on the concave side of the apical vertebrae. Notwithstanding abnormally narrow transverse pedicle widths, this feature appears to put the spinal cord at particularly high risk with medial cortical breach. Surgical planning may optimally

Figure 5–6 Sagittal magnetic resonance (MR) image demonstrating draping of the spinal cord over the posterior disks in a patient with an 80-degree kyphosis associated with Scheuermann's disease.

avoid placement of screws in this region or perhaps use a lateral extrapedicular screw insertion technique.

♦ Vascular Structures

Aorta

The aorta is intimately related to the anterior elements of the spinal column in the thoracic spine. During anterior surgical approaches, it must be mobilized anteriorly to gain access to the vertebral bodies and disks. During placement of transpedicular screws, the aorta can be at risk with inadvertent penetration of the anterior or lateral vertebral body cortices (**Fig. 5–8**). The relative position of the aorta can be altered in subjects with idiopathic scoliosis. Using CT images, Sevastik et al.[7] found the lateral distance of the aorta to the vertebral body to increase by a mean of 12.9 mm in scoliotic spines compared with normal spines. In contrast, it was on average 11.7 mm closer to the bone in the sagittal plane, which correlated well with the degree of hypokyphosis in patients with scoliosis. The aortovertebral angle was most influenced by vertebral rotation.

Using axial MR images, Sucato and Duchene[8] measured the shortest distance between the aorta and the vertebral body cortex. In general, they found that scoliosis caused the aorta to be positioned more laterally and posteriorly in relation to the vertebral body than control subjects. This was significantly correlated with an increasing Cobb angle. At the apex

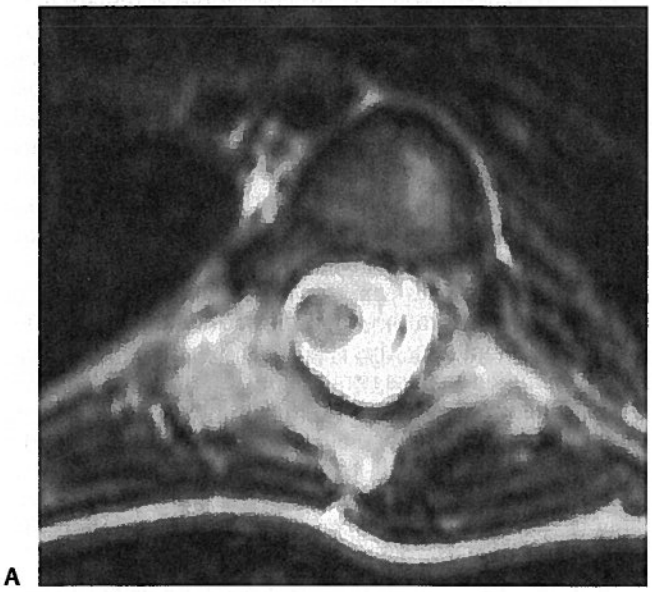

A

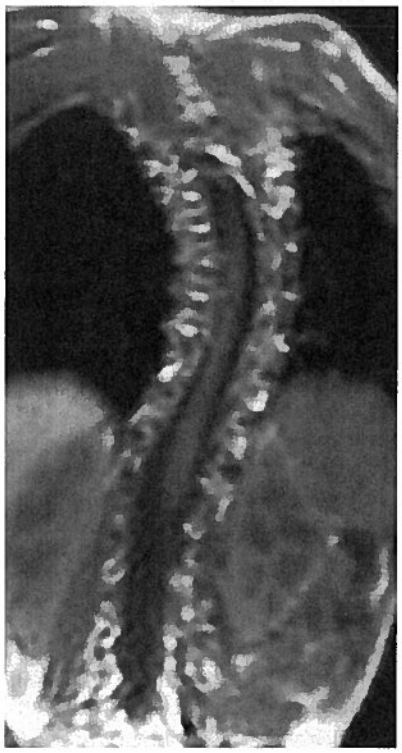

B

Figure 5–7 The spinal cord can be deviated to one side of the spinal canal, as displayed in the axial MR image of a scoliotic patient **(A)**. The spinal cord shifts toward the concave side at the curve apex **(B)**.

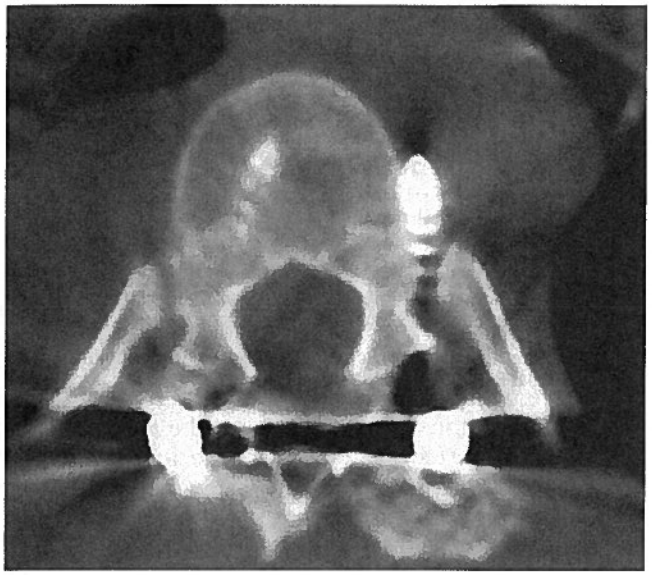

Figure 5–8 Misplaced pedicle screws can endanger the aorta if they penetrate the vertebral body too far laterally.

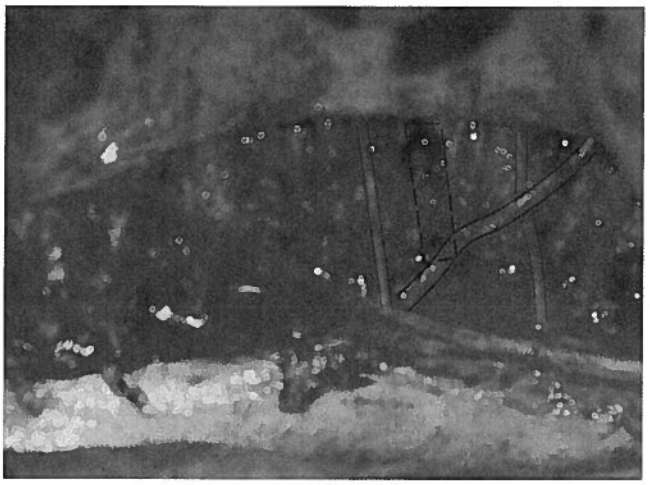

Figure 5–9 With kyphotic deformities, the segmental vessels can take unusual paths. In this intraoperative photograph, one of the segmental vessels (*solid black lines*) can be seen crossing the anterior aspect of the disk space (*dashed line*).

of the curve, however, the average distance at the apex was 1.5 mm greater in patients with idiopathic scoliosis than in those without scoliosis.

Segmental Vessels

With anterior deformity surgery, the segmental vessels need to be identified and in some cases mobilized or ligated. Identifying these vessels relies on an in-depth knowledge of their location. As the relationship of the aorta changes with spinal deformity, so does the anatomy of the segmental vessels. In one study, the ratio of the length of the right (convex)/left (concave) segmental vessels was found to increase in subjects with idioapthic thoracic scoliosis.[7]

Although a published study on the matter could not be found, in the author's experience hyperkyphotic deformities, such as Scheuermann's disease, can also lead to aberrant segmental vessel location. Because the involved vertebral bodies are wedged, the segmental vessels often lie closer to the end plates. Furthermore, once dissected free from the vertebral body to mobilize the aorta, they often obliquely cross the anterolateral aspect of the disk space (**Fig. 5–9**). These features can place them at greater risk during anterior release and diskectomy.

References

1. Porter RW. Idiopathic scoliosis: the relation between the vertebral canal and the vertebral bodies. Spine 2000;25:1360–1366
2. Parent S, Labelle H, Skalli W, deGuise J. Thoracic pedicle morphometry in vertebrae from scoliotic spines. Spine 2004;29:239–248
3. Parent S, Labelle H, Skalli W, Latimer B, deGuise J. Morphometric analysis of anatomic scoliotic specimens. Spine 2002;27:2305–2311
4. O'Brien MF, Lenke LG, Mardjetko S, et al. Pedicle morphology in thoracic adolescent idiopathic scoliosis: is pedicle fixation an anatomically viable technique? Spine 2000;25:2285–2293
5. Liljenqvist UR, Allkemper T, Hackenberg L, et al. Analysis of vertebral morphology in idiopathic scoliosis with use of magnetic resonance imaging and multiplanar reconstructions. J Bone Joint Surg Am 2002;84-A:359–368
6. Liljenqvist UR, Link TM, Halm HF. Morphometric analysis of thoracic and lumbar vertebrae in idiopathic scoliosis. Spine 2000;25:1247–1253
7. Sevastik B, Xiong B, Hedlund R, Sevastik J. The position of the aorta in relation to the vertebra in patients with idiopathic scoliosis. Surg Radiol Anat 1996;18:51–56
8. Sucato DJ, Duchene C. The position of the aorta relative to the spine: a comparison of patients with and without idiopathic scoliosis. J Bone Joint Surg Am 2003;85-A:1461–1469
9. Maruta T, Minami S, Kitahara H, et al. Rotation of the spinal cord in idiopathic scoliosis. J Bone Joint Surg Br 2004;86:220–224
10. Resnick D, Niwayama G. Intravertebral disk herniation: cartilaginous (Schmorl's) nodes. Radiology 1978;126:57–65
11. Hensinger RN. Spondylolysis and spondylolisthesis in children. Instr Course Lect 1983;32:132–151
12. Ulmer JL, Mathews VP, Elster AD, et al. MR imaging of lumbar spondylolysis: the importance of ancillary observations. AJR Am J Roentgenol 1997;169:233–239
13. Rajwani T, Bagnall KM, Lambert R, et al. Using magnetic resonance imaging to characterize pedicle asymmetry in both normal patients and patients with adolescent idiopathic scoliosis. Spine 2004;29:E145–E152
14. Xiong B, Sevastik B, Willers U, Sevastik J, Hedlund R. Structural vertebral changes in the horizontal plane in idiopathic scoliosis and the long-term corrective effect of spine instrumentation. Eur Spine J 1995;4:11–14
15. Xiong B, Sevastik B, Sevastik J, et al. Horizontal plane morphometry of normal and scoliotic vertebrae. A methodological study. Eur Spine J 1995;4:6–10
16. Deacon P, Flood BM, Dickson RA. Idiopathic scoliosis in three dimensions. A radiographic and morphometric analysis. J Bone Joint Surg Br 1984;66:509–512

17. Agostini S, Taglialavoro G, Fabris D, Mammano S, Ferraro C. Relationship between rib hump deformity and vertebral rotation in idiopathic scoliosis. Ital J Orthop Traumatol 1983;9:387–395

18. Erkula G, Sponseller PD, Kiter AE. Rib deformity in scoliosis. Eur Spine J 2003;12:281–287

19. King AG, Mills TE, Chutkan NB, Strohmeyer SE. Lumbar pedicle morphology in adolescent idiopathic scoliosis. Orthopedics 2003;26: 317–320

20. Morgenstern W, Ferguson SJ, Berey S, Orr TE, Nolte LP. Posterior thoracic extrapedicular fixation: a biomechanical study. Spine 2003;28:1829–35

21. Villas C, Barrios RH. Congenital absence of the pedicles and the neural arch of L2. Eur Spine J 1997;6:354–356

22. Strauss ED, Kahanovitz N, Ghelman B. Congenital absence of the thoracic pedicle. A case report. Spine 1983;8:48–49

23. Kumar R, Niall D, Walsh A, Khalilullah K, McCormack D. Spina bifida occulta in isthmic spondylolisthesis: a surgical trap. Eur Spine J 2002; 11:159–161

24. Herzenberg JE, Waanders NA, Closkey RF, Schultz AB, Hensinger RN. Cobb angle versus spinous process angle in adolescent idiopathic scoliosis. The relationship of the anterior and posterior deformities. Spine 1990;15:874–879

25. Kim NH, Lee JW. The relationship between isthmic and degenerative spondylolithesis and the configuration of the lamina and facet joints. Eur Spine J 1995;4:139–144

26. Miyake R, Ikata T, Katoh S, Morita T. Morphologic analysis of the facet joint in the immature lumbosacral spine with special reference to spondylolysis. Spine 1996;21:783–789

27. Roca J, Moretta D, Fuster S, Roca A. Direct repair of spondylolysis. Clin Orthop Relat Res 1989;246:86–91

Chapter 6

The Lenke Classification System of Adolescent Idiopathic Scoliosis

R. Shay Bess and Lawrence G. Lenke

The normal spine is straight in the coronal plane. In the sagittal plane, the thoracic spine averages ~30 degrees of kyphosis (range 10 to 50 degrees, measured from T5 to T12), and the lumbar spine contours to ~55 degrees of lordosis (range 35 to 80 degrees, measured from T12 to S1).[1,2] Scoliosis, classically regarded as a frontal plane curvature, is a three-dimensional deformity, in which the spine deviates from the midline in the coronal plane, and the affected vertebrae rotate maximally at the apex of the curve.[3]

The etiologic classification of scoliosis is broadly categorized as idiopathic, neuromuscular, syndrome related, and congenital. Idiopathic scoliosis, which constitutes ~80% of patients with scoliosis, is defined as a lateral curvature of the spine for which no etiology can be established.[4] Idiopathic scoliosis can be further divided according to the age upon diagnosis. These divisions, as recommended by the Scoliosis Research Society (SRS), include infantile (ages 0 to 2 +11), juvenile (age 3 to 9 +11), adolescent (10 to 17 +11) and adult (≥18 years).[4]

♦ Radiographic Measurements

Several classification schemes exist for describing the patterns of idiopathic scoliotic curves. These schemes evaluate the location and magnitude of each curve to assess different curve patterns thereby facilitating communication among treating physicians, enabling treatment recommendations, and allowing comparison of different treatment methods.

The magnitude of the coronal deviation of a scoliotic curve is measured by the Cobb method as recommended by the Terminology Committee of the SRS (**Fig. 6–1A**).[5] The end vertebrae of the curve are located on standing, long cassette posteroanterior spine radiographs. These vertebrae define the proximal and distal extent of a curve.[6] They are identified as the cranial and caudal vertebrae within the selected curve that are most tilted from the horizontal. The degree of tilt between these two vertebrae defines the Cobb angle. This angle is measured by outlining the superior end plate of the cranial end vertebra and the inferior end plate of the caudal end vertebra. Perpendicular lines are then constructed at right angles to the end plates of the outlined end vertebrae. The angle formed by the intersection of the perpendicular lines defines the Cobb angle of the selected curve. If more than one curve exists, a Cobb angle measurement is made for each curve.

The apex of a curve defines its center.[7] It is the most laterally deviated and most horizontal vertebra or disk of the curve. A single vertebra can often be defined as the apex. If, however, a pair of vertebrae is at the apex, an apical disk is used to define the level of the apex (**Fig. 6–1B**).

Sagittal alignment is measured by the Cobb angle between the perpendiculars to the superior end plate of the proximal vertebra and inferior end plate of the distal vertebra on standing, long cassette lateral spine radiographs. Thoracic kyphosis begins at T1; however, this vertebra is difficult to identify on lateral radiographs, therefore T5 is used as the proximal thoracic vertebra, and T12 is used as the distal vertebra. Lumbar lordosis is measured in the same manner, extending from T12 to S1 (**Fig. 6–1C**).[8]

♦ Classification Schemes for Adolescent Idiopathic Scoliosis

In 1983, King et al. presented a classification system for thoracic adolescent idiopathic scoliosis (AIS).[9] The benefit of this classification scheme included a treatment algorithm based on curve types that allowed surgeons to determine the appropriate curves and vertebral levels for arthrodesis. Five types of curves were described in detail.

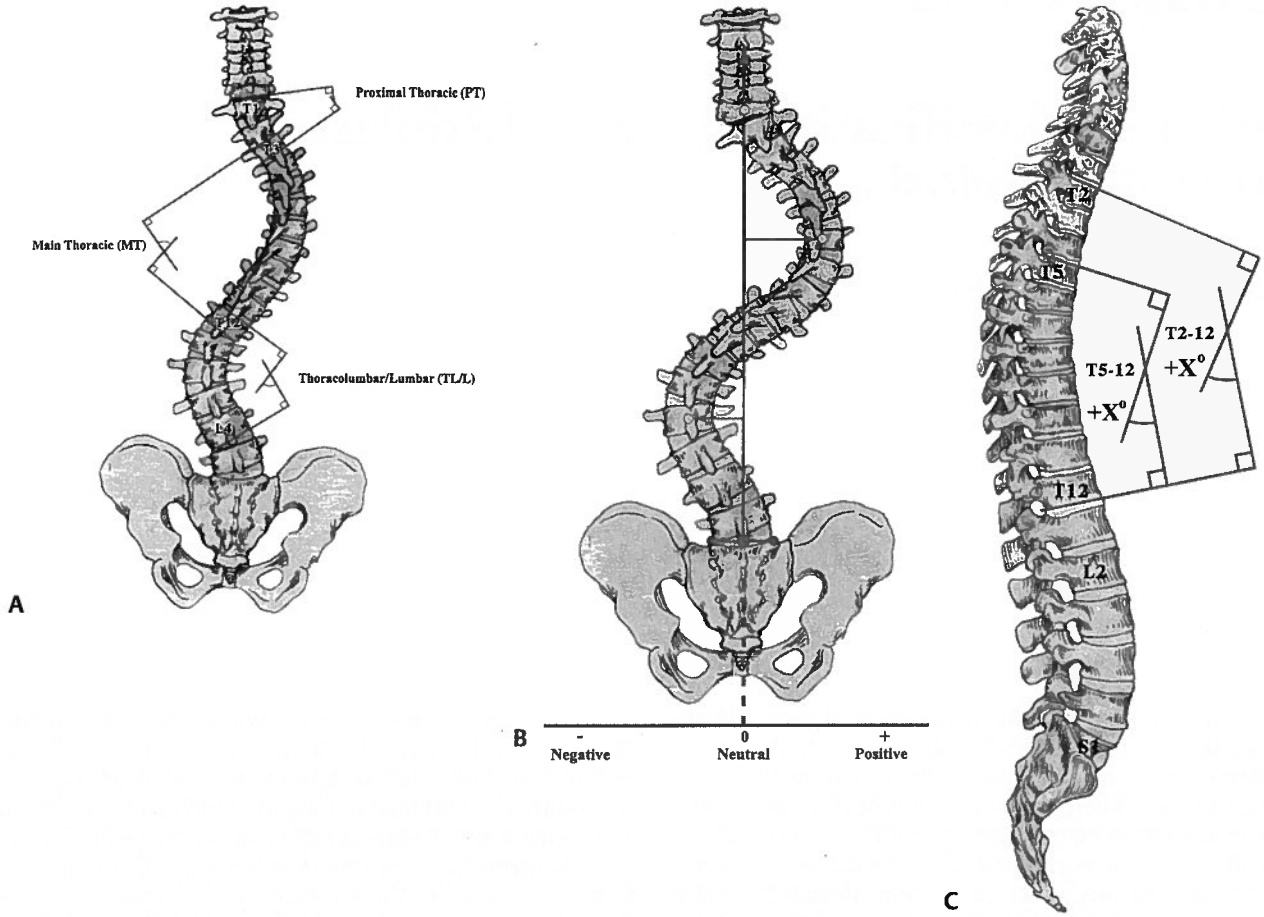

Figure 6–1 **(A)** Cobb measurement of scoliotic coronal plane deviation. Intersecting lines are constructed perpendicular to the superior end plate of the superior end vertebra and the inferior end plate of the inferior end vertebra. The angle subtended by the perpendiculars is the Cobb angle for the selected curve. **(B)** Curve apex. The apex of a curve defines its center. It is the most laterally deviated and most horizontal vertebra or disk of the curve. **(C)** Sagittal alignment. Thoracic sagittal alignment measured by the Cobb angle between the perpendiculars to the superior end plate of T5 and the inferior endplate of T12. (By permission from O'Brien MF, Kuklo TR, Blanke KM, Lenke LG. Spinal Deformity Study Group Radiographic Measurement Manual. Memphis, TN: Medtronic Sofamor Danek; 2004.)

The King system remained the principal classification scheme for thoracic AIS for more than 20 years, guiding evaluation and treatment. However, several limitations of the King system have recently been highlighted. The system is not comprehensive, as only thoracic curves are classified. Consequently, thoracolumbar, lumbar, double, and triple major curves are not included. Additionally, all patients in King's series received Harrington rod instrumentation that solely corrected deformity in the coronal plane. Therefore, the curves were evaluated only in the coronal plane, failing to recognize scoliosis as a three-dimensional deformity and the need to assess sagittal alignment. This approach has guided the operative assessment of scoliosis despite the advent of segmental spinal instrumentation systems that allow surgeons to treat scoliosis as a three-dimensional deformity, facilitating correction in the coronal, sagittal, and axial planes.[10–14] Furthermore, the King system has demonstrated fair-to-poor interobserver and intraobserver validity, reliability, and reproducibility by two independent groups of surgeons in two separate studies.[15,16] In response to these shortcomings, Lenke et al. developed a new classification system for the operative treatment of AIS.[17] This new classification scheme was designed to be

1. Comprehensive and include all types of curves.
2. Two-dimensional, with increased emphasis on sagittal plane alignment.
3. Treatment-based, recommending arthrodesis of necessary curves only, allowing selective fusion when appropriate.
4. Objective, using specified criteria to differentiate individual curve types.
5. Demonstrate good-to-excellent interobserver and intraobserver reliability.
6. Easily understood and clinically practical.

♦ Lenke AIS Classification System

There are three components to the Lenke classification system: curve type, lumbar spine modifier, and sagittal thoracic modifier. Each component is assessed separately and then combined to create a classification triad (**Fig. 6–2**). The classification scheme uses four long cassette radiographs: standing posteroanterior

CURVE TYPE

Type	Proximal Thoracic	Main Thoracic	Thoracolumbar/Lumbar	Description
1	Non-Structural	Structural (Major)*	Non-Structural	Main Thoracic (MT)
2	Structural	Structural (Major)*	Non-Structural	Double Thoracic (DT)
3	Non-Structural	Structural (Major)*	Structural	Double Major (DM)
4	Structural	Structural (Major)*	Structural (Major)*	Triple Major (TM)§
5	Non-Structural	Non-Structural	Structural (Major)*	Thoracolumbar/Lumbar (TL/L)
6	Non-Structural	Structural	Structural (Major)*	Thoracolumbar/Lumbar-Main Thoracic (TL/L-MT)

STRUCTURAL CRITERIA
(Minor Curves)

Proximal Thoracic - Side Bending Cobb ≥25°
- T2-T5 Kyphosis ≥+20°

Main Thoracic - Side Bending Cobb ≥25°
- T10-L2 Kyphosis ≥+20°

Thoracolumbar/Lumbar - Side Bending Cobb ≥25°
- T10-L2 Kyphosis ≥+20°

*Major = Largest Cobb measurement, always structural
Minor = All other curves with structural criteria applied
§Type 4 - MT or TL/L can be major curve

LOCATION OF APEX
(SRS Definition)

CURVE	APEX
Thoracic	T2-T11/12 Disc
Thoracolumbar	T12-L1
Thoracolumbar/Lumbar	L1/2 Disc-L4

Modifiers

Lumbar Spine Modifier	CSL to Lumbar Apex
A	CSL between pedicles
B	CSL touches apical body(ies)
C	CSL completely medial

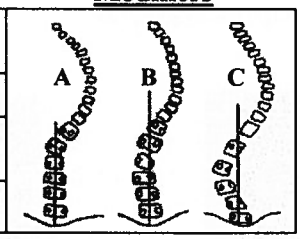

Thoracic Sagittal Profile T5-T12	
– (Hypo)	<10°
N (Normal)	10° – 40°
+ (Hyper)	>40°

Curve Type (1-6) + Lumbar Spine Modifier (A, B, C) + Thoracic Sagittal Modifier (-, N, +)
Classification (e.g 1B+): _____

Figure 6–2 The Lenke Classification System for the operative treatment of adolescent idiopathic scoliosis. (From Lenke LG, Betz RR, Harms J, et al. Adolescent idiopathic scoliosis: a new classification to determine extent of spinal arthrodesis. J Bone Joint Surg 2001;83A:1169. Reprinted by permission.)

and lateral, along with supine left and right side bending. Classification begins by dividing the spinal column into three regions:

1. Proximal Thoracic (PT): apex at T3, T4, or T5.
2. Main Thoracic (MT): apex between T6 and the T11-T12 disk.
3. Thoracolumbar/Lumbar (TL/L): apex between T12 and L1 for thoracolumbar curves, and between the L1-L2 disk and L4 for lumbar curves.

A Cobb measurement of the curve in each region is obtained. Curves are categorized as major or minor. The largest curve is designated the major curve. The smaller minor curves are then established as structural or nonstructural by evaluating curve flexibility and sagittal alignment. Structural curves demonstrate coronal plane rigidity >25 degrees on side-bending radiographs and/or kyphosis ≥20 degrees on sagittal radiographs. Regional kyphosis is measured as follows; PT (T2-T5), MT (T10-L2), TL/L (T10-L2). Six curve types can be assigned according to the identified major and minor structural curves. The defined curve types include (**Table 6–1; Figs. 6–3 and 6–4**):

1. Type 1, Main Thoracic (MT)
2. Type 2, Double Thoracic (DT)
3. Type 3, Double Major (DM)
4. Type 4, Triple Major (TM)
5. Type 5, Thoracolumbar/Lumbar (TL/L)
6. Type 6, Thoracolumbar/Lumbar–Main Thoracic (TL/L-MT)

The MT curve is the major curve in Types 1 to 3. The TL/L curve is the major curve in Types 5 and 6. Either the MT or the TL/L curve can be the major curve for Type 4 curves. On the basis of this classification, spinal arthrodesis should include only the major curve and the structural minor curves.

A lumbar spine modifier is added to assess the degree of lumbar coronal plane deformity. The center sacral line (CSL) is drawn vertically from the midpoint of S1 through the lumbar apical vertebra. When the apex is a disk, the lumbar modifier is determined by the position of the CSL in relation to the vertebra immediately above and below the apical disk. If the CSL passes between the pedicles of the apical lumbar vertebra, a lumbar modifier A is assigned. If the CSL falls between the medial edge of the concave pedicle and the lateral vertebral body, lumbar modifier B is assigned. If the CSL does not touch the lateral edge of the apical lumbar vertebra, lumbar modifier C is assigned. If a distinction between modifiers A and B or between B and C cannot be determined, modifier B should be assigned (**Fig. 6–5**).

Table 6–1 Curve Types in the Lenke Classification System for the Operative Treatment of Adolescent Idiopathic Scoliosis

Curve Type	Description	Characteristic Curve Patterns*			
		Proximal Thoracic	Main Thoracic	Thoracolumbar/ Lumbar	Structural Region of Each Curve Type
1	Main thoracic	Nonstructural	Structural (major)	Nonstructural	Main thoracic
2	Double thoracic	Structural	Structural (major)	Nonstructural	Proximal thoracic, main thoracic
3	Double major	Nonstructural	Structural (major)	Structural	Main thoracic, thoracolumbar/ lumbar
4	Triple major	Structural	Structural (major†)	Structural (major†)	Proximal thoracic, main thoracic, thoracolumbar/lumbar
5	Thoracolumbar/lumbar	Nonstructural	Nonstructural	Structural (major)	Thoracolumbar/lumbar
6	Thoracolumbar/ lumbar-main thoracic	Nonstructural	Structural	Structural (major)	Thoracolumbar/lumbar, main thoracic

Source: From Lenke LG, Betz RR, Harms J, et al. Adolescent idiopathic scoliosis: A new classification to determine extent of spinal arthrodesis. J Bone Joint Surg 2001;83A:1169.

*A structural proximal thoracic curve has a Cobb angle of ≥25 degrees on on side-bending radiographs and/or kyphosis between the second and the fifth thoracic level of at least +20 degrees. A structural main thoracic curve has a Cobb angle of ≥25 degrees on side-bending radiographs and/or kyphosis between the tenth thoracic and the second lumbar level of at least +20 degrees. A structural thoracolumbar/lumbar curve has a Cobb angle of ≥25 degrees on side-bending radiographs and/or kyphosis between the tenth thoracic and the second lumbar level of at least +20 degrees.

†Either the main thoracic or the thoracolumbar/lumbar curve can be the major curve.

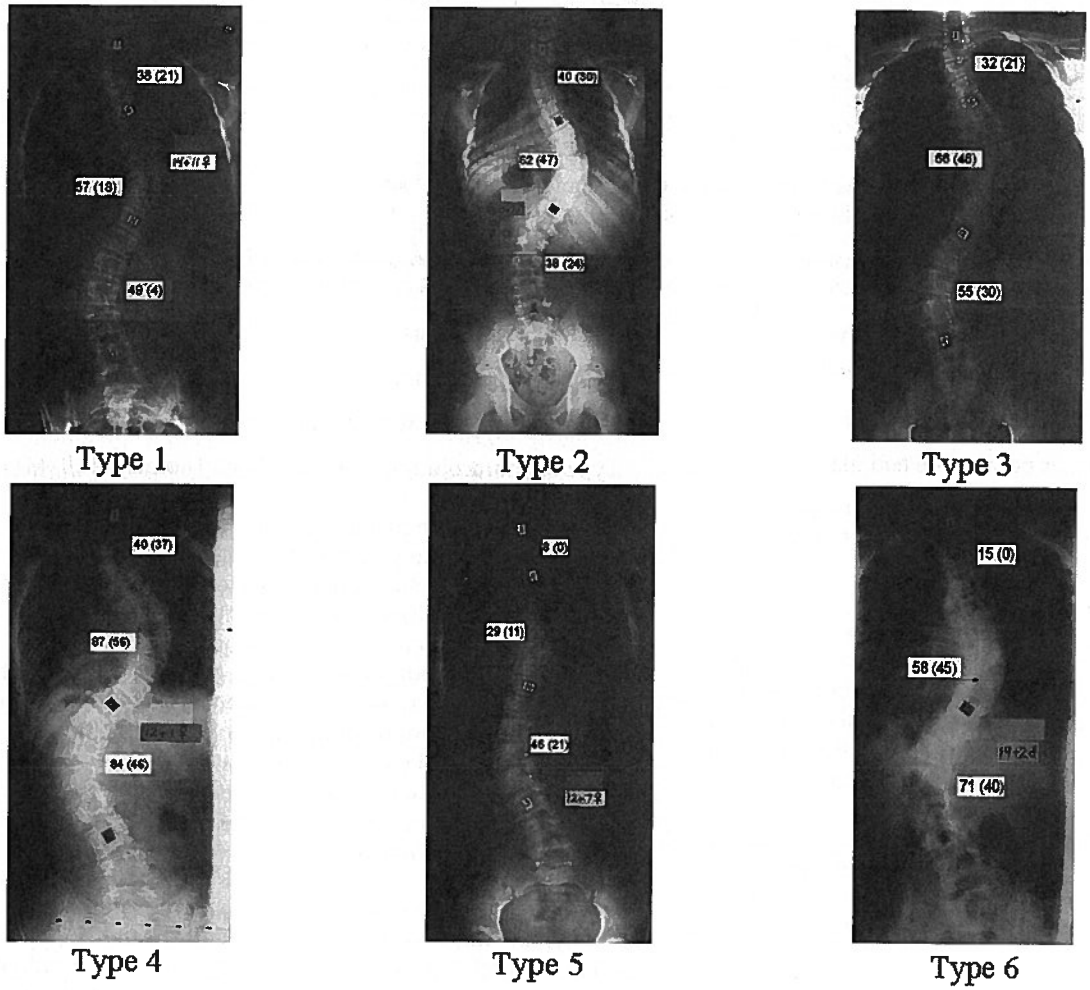

Figure 6–3 Lenke classification system for adolescent idiopathic scoliosis curve Types 1 to 6. The main thoracic curve is the major structural curve unless otherwise specified. Type 1 (MT, main thoracic structural); Type 2 (DT, main thoracic and proximal thoracic structural); Type 3 (DM, main thoracic and thoracolumbar/lumbar structural); Type 4 (TM, proximal thoracic, main thoracic, and thoracolumbar/lumbar structural); Type 5 (TL/L, only thoracolumbar/lumbar structural); and Type 6 (TL/L-MT, thoracolumbar/lumbar major structural, main thoracic minor structural).

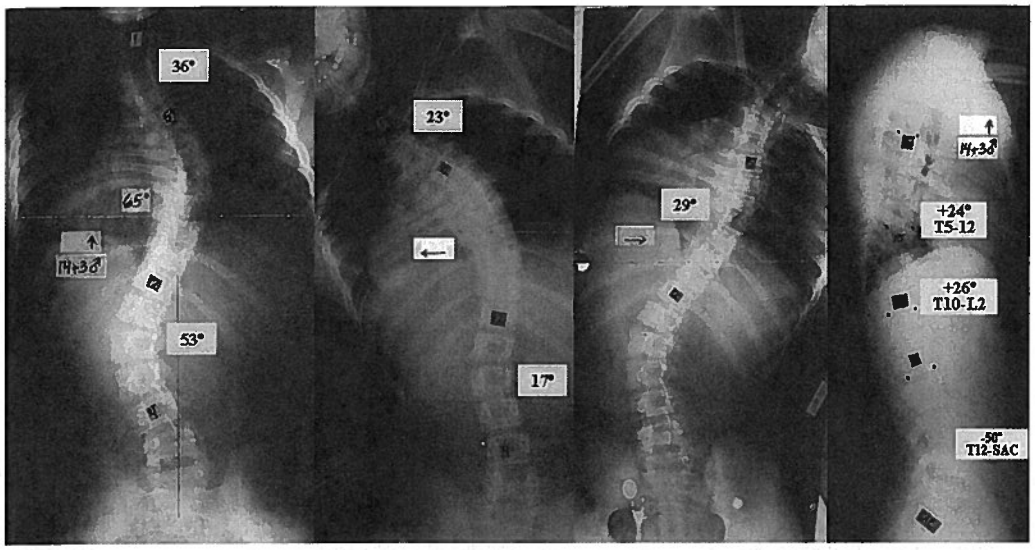

Figure 6–4 Type 3 curve. Evaluation of the preoperative posterior/anterior and side-bending radiographs demonstrate a 65-degree structural main thoracic curve that reduces to 29 degrees on side-bending radiographs. The 53-degree TL/L curve reduces to 17 degrees on side-bending radiographs, giving the initial appearance of a Type 1 curve; however, sagittal alignment demonstrates 26 degrees of kyphosis from T10 to L2, designating a structural TL/L curve and, therefore, a Type 3CN curve.

The third component of the classification system involves assigning a sagittal thoracic modifier based on the T5 to T12 Cobb measurement on the lateral radiograph. Cobb measurements between +10 degrees and +40 degrees are assigned normal (N) thoracic modifier. A minus (−) sign is assigned to hypokyphotic curves <10 degrees, and a plus (+) sign identifies hyperkyphotic curves >40 degrees (**Fig. 6–6**).

The Lenke classification system creates a triad that combines the curve type (1 to 6) with a lumbar spine modifier (A, B, C) and a thoracic sagittal modifier (−, N, +) to create the final classification (e.g., 1AN, **Fig. 6–2**). Forty-two different classifications are possible with this system, not 48, because all Type 5 (TL/L) and Type 6 (TL/L-MT) operative curves carry a lumbar C modifier. Evaluation of curve prevalence found Type 1 (MT) curves in 51% of operative cases; conversely, Type 4 (TM) and Type 6 (TL/L-MT) each accounted for only 3% of operative cases.[18] Five classifications accounted for ~60% of curve types: 1AN, 2AN, 1BN, 5CN, and 1CN. Lumbar modifier A was the most prevalent (41%) followed by modifier B (37%). Normal thoracic kyphosis (N) accounted for 75% of all thoracic modifiers.[18]

Evaluation of the reliability of this system demonstrated good-to-excellent interobserver and intraobserver reliability

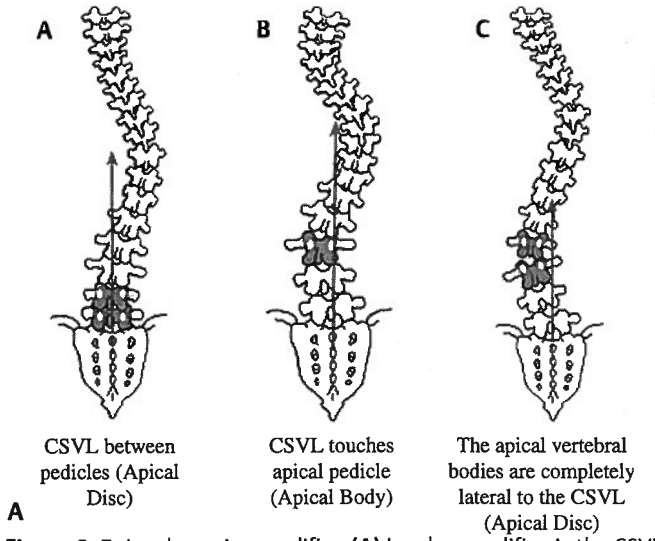

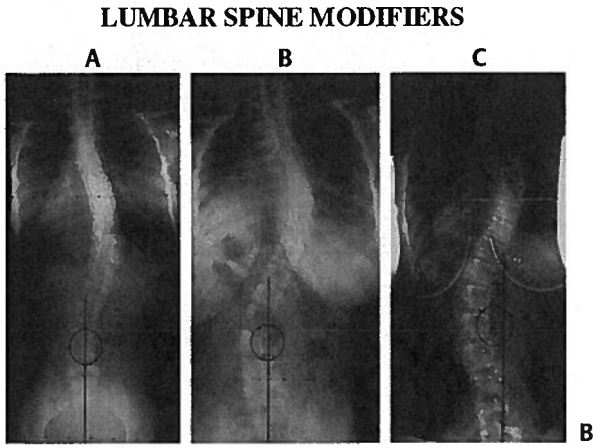

Figure 6–5 Lumbar spine modifier. **(A)** Lumbar modifier A: the CSVL passes between the pedicles of the apical lumbar vertebra. Lumbar modifier B: the CSVL falls between the medial edge of the concave pedicle and the lateral vertebral body. Lumbar modifier C: the CSVL does not touch the lateral edge of the apical lumbar vertebra. If a distinction between modifiers A and B or between B and C cannot be identified, modifier B is assigned. (By permission from O'Brien MF, Kuklo TR, Blanke KM, Lenke LG. Spinal Deformity Study Group Radiographic Measurement Manual. Memphis, TN: Medtronic Sofamor Danek; 2004.) **(B)** Radiographic example of lumbar spine modifiers A to C.

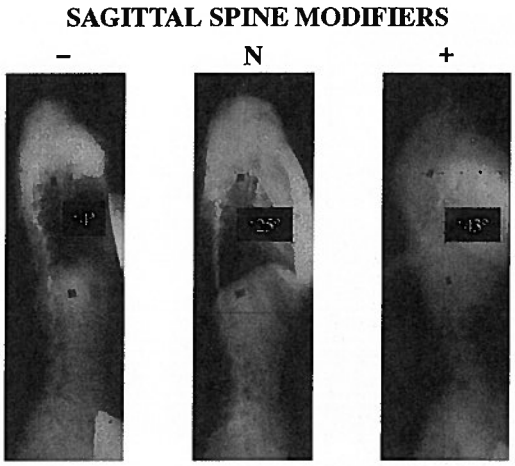

Figure 6–6 Sagittal thoracic modifier. Cobb measurements between +10 degrees and +40 degrees are assigned normal (N) thoracic modifier. A minus (−) sign is assigned to hypokyphotic curves <10 degrees, and a plus (+) sign identifies hyperkyphotic curves >40 degrees.

among the developers of the system as well as within an independent group of Scoliosis Research Society surgeons.[17] This is improved over the fair-to-poor reliability found by the same researchers for the King system.[16]

♦ Operative Treatment of AIS According to Curve Types

A primary goal of the Lenke classification system was that it be treatment-directed, recommending instrumentation and fusion of all appropriate structural curves.[16] In a retrospective analysis of 606 AIS cases treated operatively prior to establishment of the Lenke classification, ~90% of cases followed the guidelines advocated by this system.[18]

Type 1: Main Thoracic Curves

Type 1 curves are the most prevalent operative curve types.[18] Treatment options include either anterior or posterior fusion of the main thoracic curve. Posterior instrumentation has been the gold standard for more than four decades and is appropriate for arthrodesis of the main thoracic curves with any lumbar or sagittal modifier. The posterior approach is advantageous in several situations including: patients with a normal or hyperkyphotic (+) sagittal modifier; patients with a large body habitus that would benefit from a dual posterior rod construct; patients with compromised pulmonary function that would benefit from not violating the chest wall; and for surgeons who are most familiar with the posterior approach for spinal fusion (**Fig. 6–7**).[19–24]

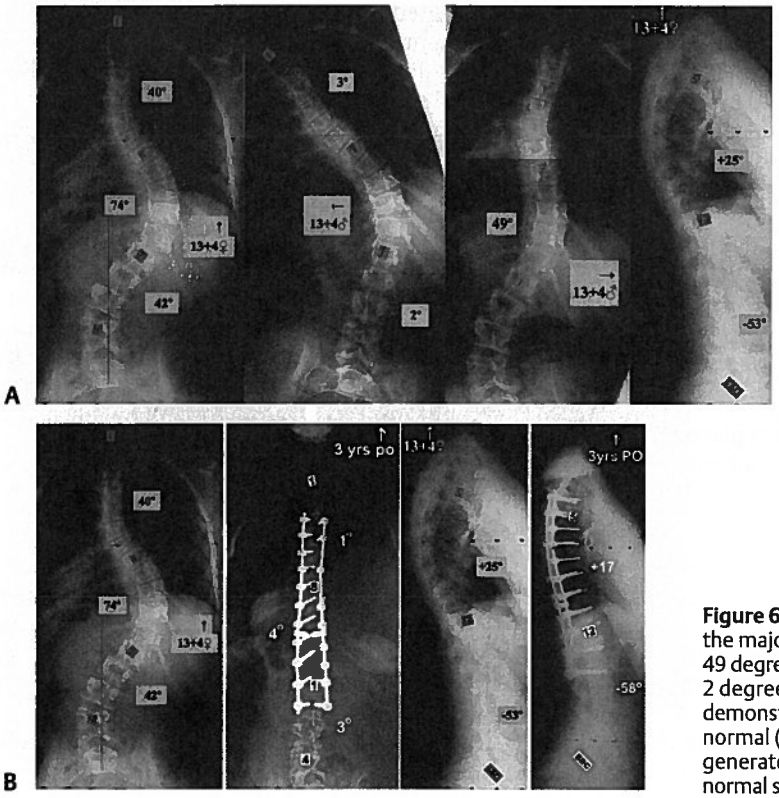

Figure 6–7 Type 1AN curve. **(A)** Preoperative radiographs demonstrate the major MT curve measures 74 degrees on standing PA and bends to 49 degrees. The nonstructural PT and TL/L curves bend to 3 degrees and 2 degrees, respectively. The CSVL through the lumbar apical vertebra demonstrates lumbar spine modifier A. The sagittal thoracic modifier is normal (25 degrees). **(B)** Isolated posterior spinal fusion from T4 to L2 generated 97% correction in the coronal plane and maintenance of a normal sagittal contour.

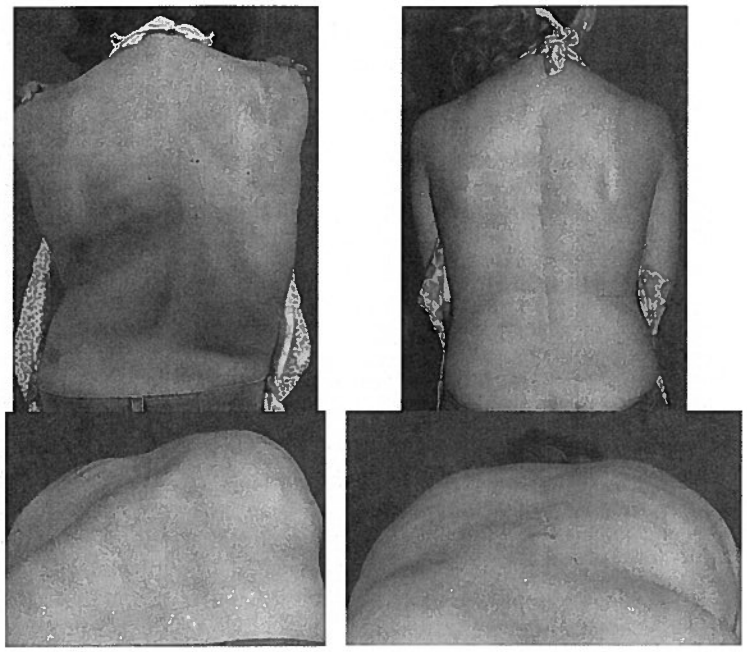

C

Figure 6–7 *(Continued)* **(C)** Comparison of preoperative and 3-year postoperative clinical photographs show elimination of the thoracic rib hump and restoration of shoulder and truncal balance.

Ideal candidates for an anterior approach to a Type 1 curve include patients with a hypokyphotic (−) sagittal modifier; patients with a lumbar C modifier to optimize spontaneous lumbar curve correction; skeletally immature patients who are at risk for crankshaft; and in cases where an anterior approach may spare one to three fusion levels by stopping at the thoracic lower end vertebra.[25–27] Anterior arthrodesis may be performed via an open approach using a single or dual rod construct or endoscopically with a single screw/single rod construct (**Fig. 6–8**).[28]

Anterior release and fusion combined with posterior instrumentation and fusion for Type 1 curves is not performed as frequently because the three-column purchase and strong corrective forces obtained by posteriorly placed pedicle screws often obviate the need for an anterior release.

Type 2: Double Thoracic Curves

Double thoracic curves require posterior instrumentation and fusion of the proximal and main thoracic curves.[29,30] The preoperative size and rigidity of the PT curve and the balance of the shoulders clinically determine if posterior instrumentation begins at T2 or T3. The lowest instrumented vertebra is determined by the distal region of the MT curve and by the lumbar modifier position (**Fig. 6–9**).[30]

Type 3: Double Major Curves

Type 3 curves require posterior instrumentation and fusion of both the MT (major curve) and the TL/L (structural minor curve) regions. The majority of Type 3 curves have a lumbar C modifier due to complete apical deviation from the midline of both the MT and TL/L curves. Thoracolumbar kyphosis between the MT and TL/L regions is variable and must be taken into account to optimize sagittal alignment when instrumenting these curves (**Fig. 6–10**).

Type 4: Triple Major Curves

Triple major curves are uncommon, representing ~3% of operatively treated curves.[18] All three curves are structural, and either the MT or the TL/L curve can be major. Arthrodesis of all three structural regions is necessary, most commonly with posterior instrumentation and fusion (**Fig. 6–11**). Rarely, a preliminary anterior release and fusion of a large, stiff, and/or kyphotic MT or TL/L curve is required.

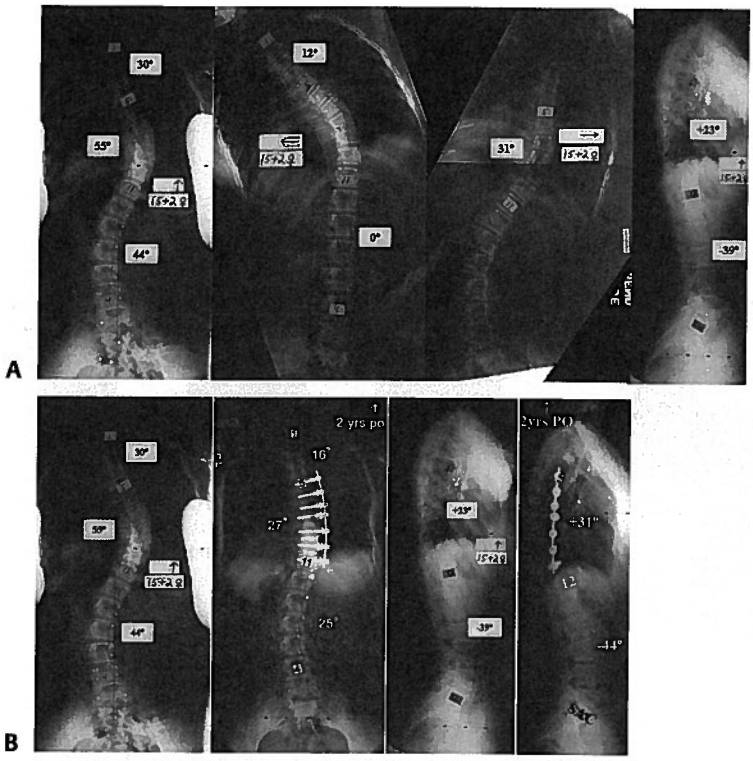

Figure 6–8 Type 1BN curve. **(A)** Preoperative radiographs demonstrate the major MT curve measures 55 degrees on standing PA and bends to 31 degrees. The nonstructural PT and TL/L curves bend out to 12 degrees and 0 degrees, respectively. The CSVL through the lumbar apical vertebra demonstrates lumbar spine modifier B. The sagittal thoracic modifier is normal (23 degrees). **(B)** Endoscopic instrumentation of the end vertebrae from T5 to T11 achieved 28 degrees of correction and maintenance of normal sagittal alignment.

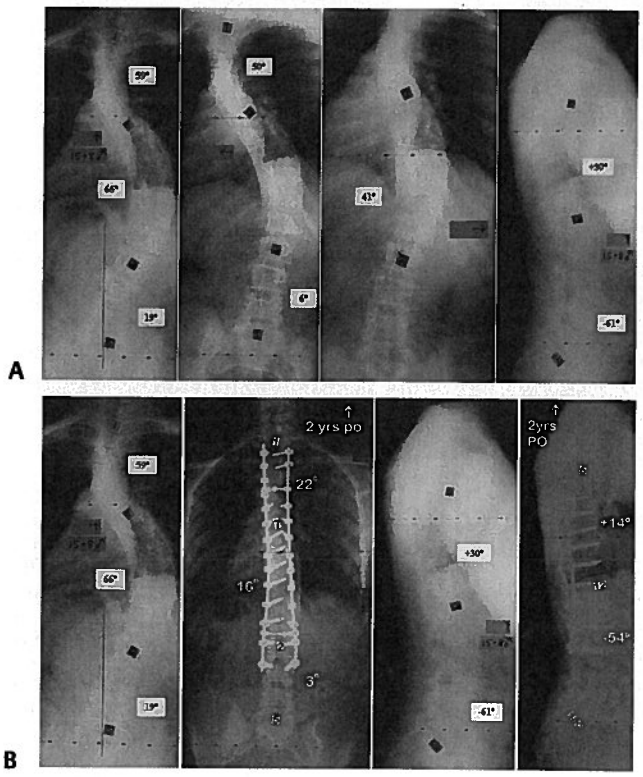

Figure 6–9 Type 2AN curve. **(A)** Preoperative radiographs demonstrate the major MT curve measures 66 degrees on standing PA and bends to 41 degrees. The structural PT curve bends out to 50 degrees. The nonstructural TL/L curve bends out to 6 degrees. The CSVL through the lumbar apical vertebra demonstrates lumbar spine modifier A. The sagittal thoracic modifier is normal (30 degrees). **(B)** Posterior spinal fusion of the PT and MT curves from T2 to L3 achieved correction to 22 degrees and 16 degrees, respectively, whereas fusion of the structural curves allowed spontaneous correction of the lumbar curve to 3 degrees.

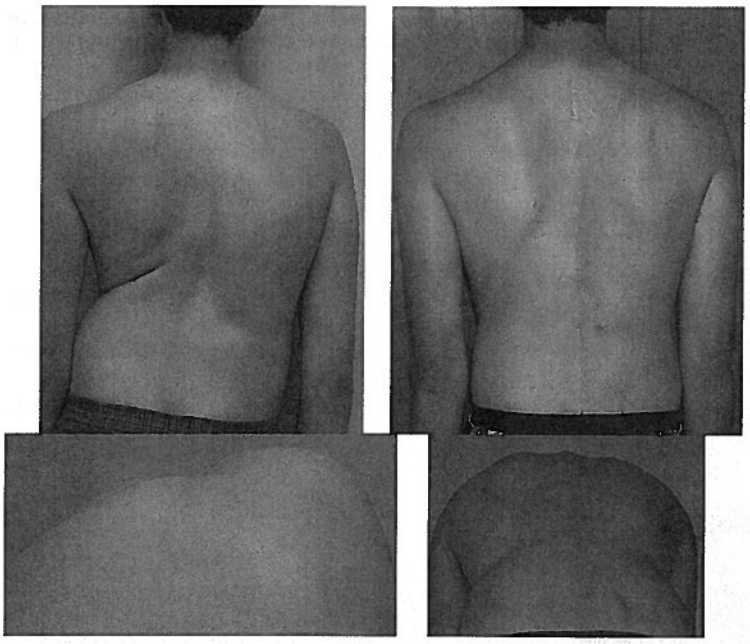

Figure 6–9 (*Continued*) **(C)** Preoperative and postoperative clinical photographs show elimination of the thoracic rib hump and restoration of shoulder and truncal balance.

A

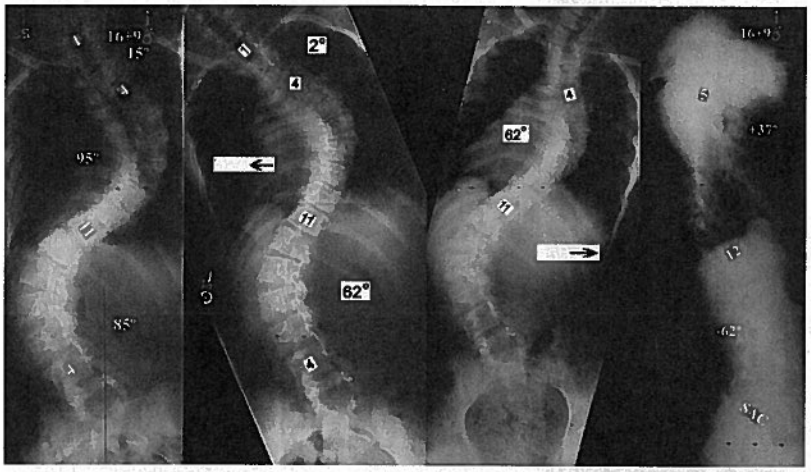

B

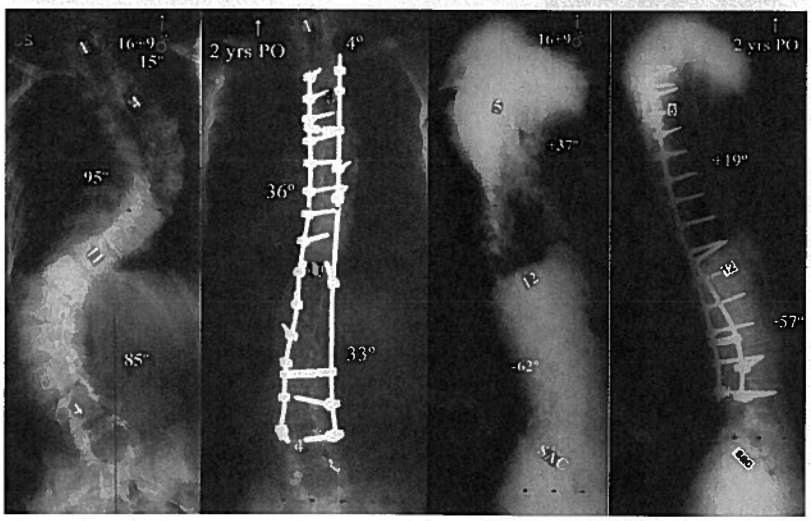

Figure 6–10 Type 3CN curve. **(A)** Preoperative radiographs demonstrate the major MT curve measures 95 degrees on standing PA and bends to 62 degrees. The structural TL/L curve bends to 62 degrees. The nonstructural PT curve bends to 2 degrees. The CSVL through the lumbar apical vertebra demonstrates lumbar spine modifier C. The sagittal thoracic modifier is normal (37 degrees). **(B)** Posterior spinal fusion of the structural MT and TL/L curves from T3 to L4 achieved correction to 36 degrees and 33 degrees, respectively, with spontaneous correction of the nonstructural PT curve to 4 degrees.

(Continued)

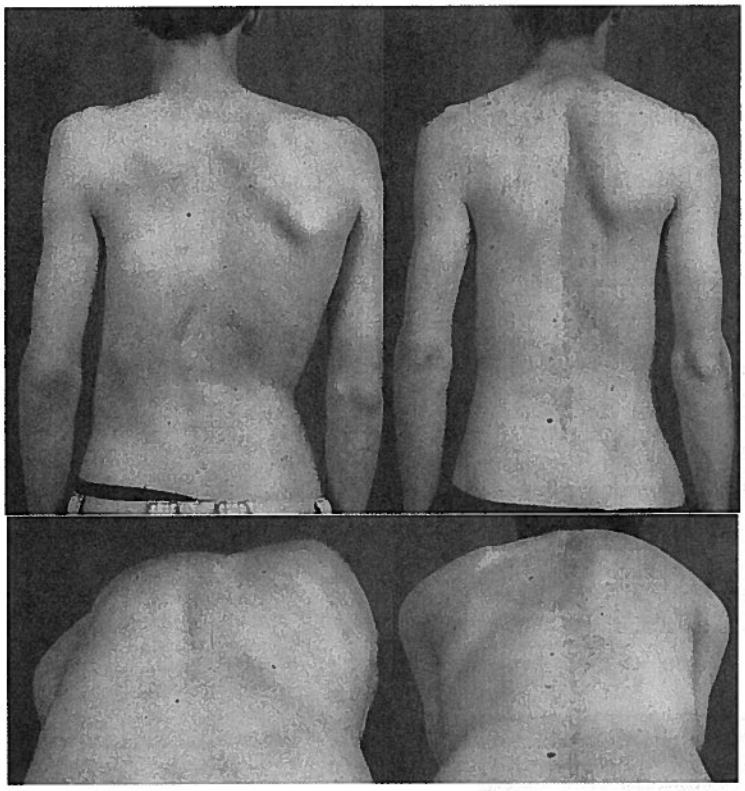

C

Figure 6–10 *(Continued)* **(C)** Preoperative and postoperative clinical photographs show elimination of the thoracic rib hump and restoration of truncal balance.

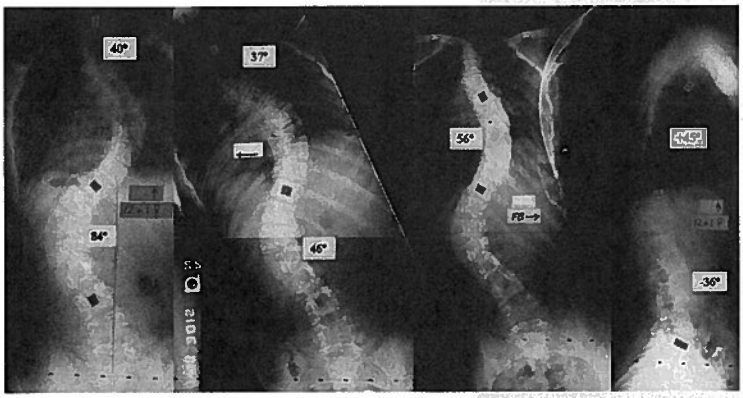

A

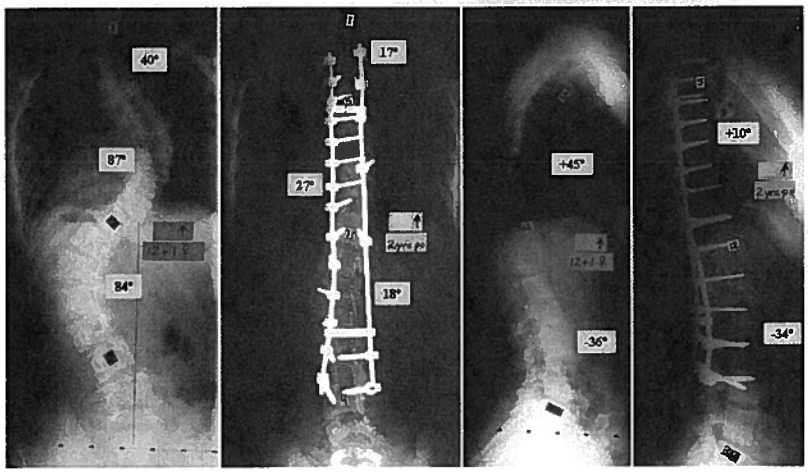

B

Figure 6–11 Type 4C+ curve. **(A)** Preoperative radiographs demonstrate a triple major curve. The major MT curve measures 87 degrees on standing PA and bends to 56 degrees. The structural PT and TL/L curves bends to 37 degrees and 46 degrees, respectively. The CSVL through the lumbar apical vertebra demonstrates lumbar spine modifier C. The sagittal thoracic modifier is hyperkyphotic (45 degrees). **(B)** Posterior spinal fusion from T3 to L4 achieved correction of the PT, MT, and TL/L curves to 17 degrees, 27 degrees, and 18 degrees, respectively. Sagittal balance was restored to 10 degrees with maintenance of lumbar lordosis.

Type 5: Thoracolumbar/Lumbar Curves

Only the TL/L curve is structural in Type 5 curves, allowing selective anterior or posterior fusion of the TL/L region. We use an anterior approach with a dual-rod construct and interbody support to optimize sagittal plane alignment and construct stability (**Fig. 6–12**).

Type 6: Thoracolumbar/Lumbar–Main Thoracic Curves

Type 6 curves have a major TL/L curve and minor MT curve. Both curves require posterior instrumentation and fusion (**Fig. 6–13**).

♦ Conclusion

The benefit of the Lenke classification system to preoperatively categorize adolescent idiopathic scoliosis curve patterns and provide a treatment algorithm has been clearly demonstrated, as a review of the treatment guidelines demonstrate 90% accuracy in predicting fusion levels.[18,31] This system is not perfect, though, as additional factors must be examined when determining the levels of the spine to be instrumented and fused, including the clinical appearance of the patient, the level of skeletal maturity, and the ability to perform isolated fusions of major curves when possible.

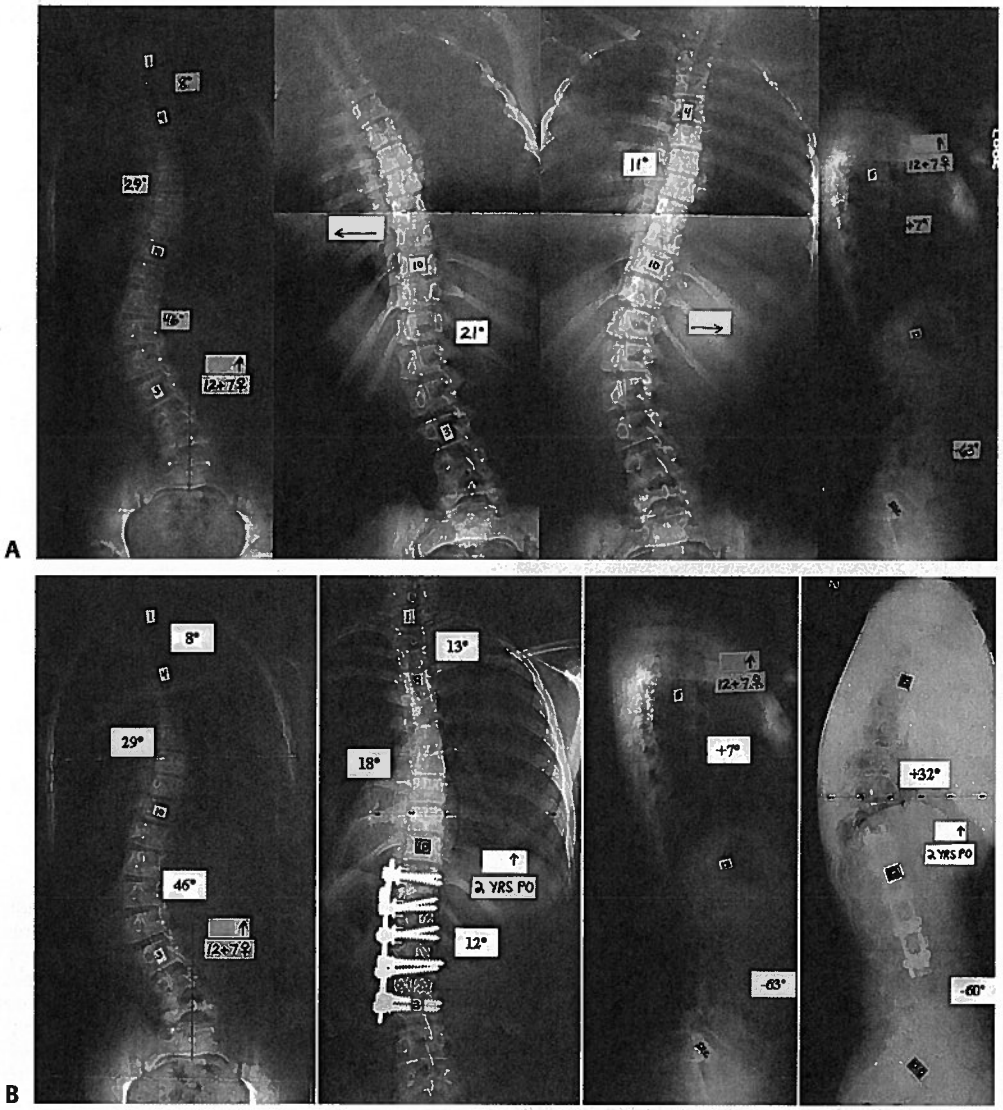

Figure 6–12 Type 5C– curve. **(A)** Preoperative radiographs demonstrate the major TL/L curve measures 46 degrees on standing PA. The nonstructural PT and MT curves bend to 11 degrees and 21 degrees, respectively. By definition, a Type 5 curve carries a lumbar spine modifier C. The sagittal thoracic modifier is hypokyphotic (7 degrees). **(B)** Selective anterior spinal fusion of the TL/L curve from T11 to L3 with a dual-rod construct and interbody support achieved correction to 12 degrees in the coronal plane and restoration of normal sagittal contour.

(Continued)

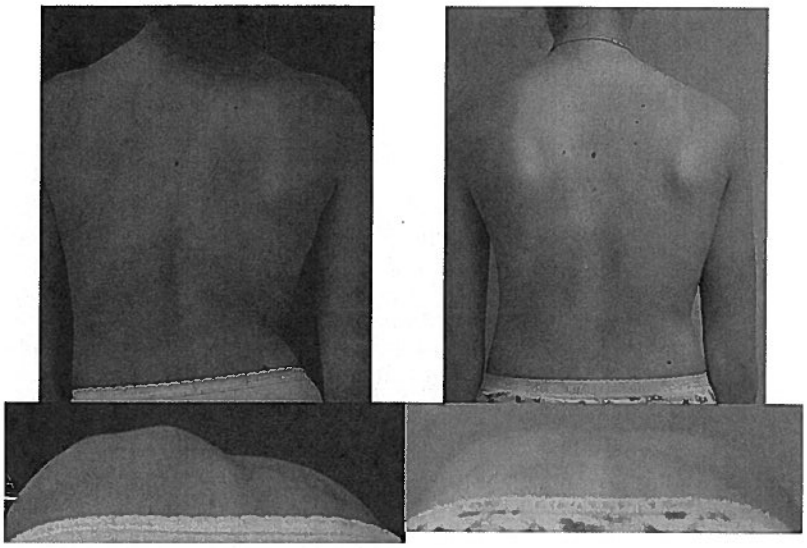

C

Figure 6–12 (*Continued*) **(C)** Preoperative and postoperative clinical photographs show correction of the lumbar hump and restoration of truncal balance.

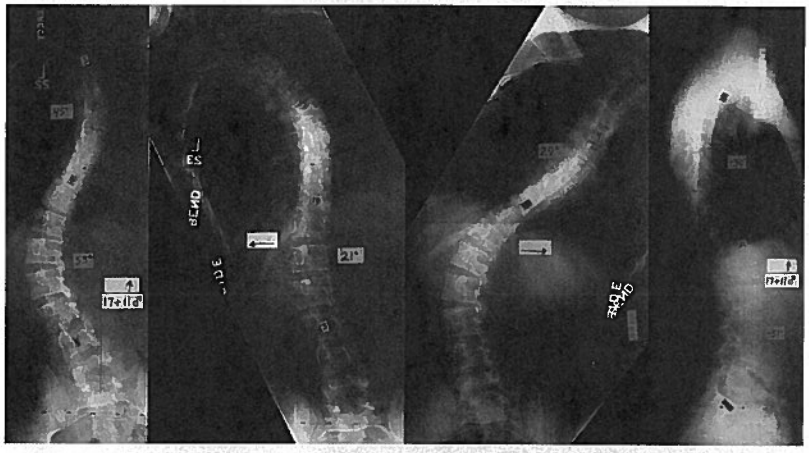

A

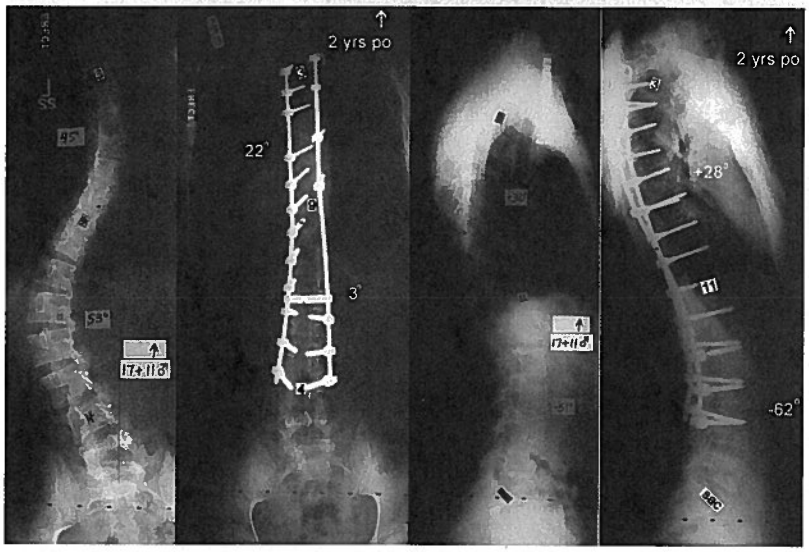

B

Figure 6–13 Type 6CN curve. **(A)** Preoperative radiographs demonstrate the major TL/L curve measures 53 degrees on standing PA and bends to 21 degrees. The minor structural PT curve measures 45 degrees and bends to 29 degrees. By definition, a Type 6 curve carries a lumbar spine modifier C. The sagittal thoracic modifier is normal (30 degrees). **(B)** Posterior spinal fusion of the TL/L curve from T3 to L4 achieved correction of the MT and TL/L curves to 22 degrees and 3 degrees, respectively. Normal sagittal contour is maintained.

Ideally, a classification system for AIS should reflect the current concept of scoliosis as a three-dimensional deformity. An initial attempt was made to integrate a modifier for axial plane deformity in the criteria for a structural curve during creation of the current system. However, due to the difficulty in accurately assessing axial plane deformity on biplanar radiographs, the results were difficult to reproduce and, consequently, this portion of the system was removed.[17] Additionally, biplanar radiographs remain the current standard for the initial evaluation of scoliosis due to the absence of simple, reliable, and universally accepted and available methods for three-dimensional modeling. When methods for three-dimensional analysis of scoliotic deformities become universally available, an axial modifier can be included in the current scheme and will complement the current lumbar coronal and thoracic sagittal plane modifiers.

Since the inception of the Lenke classification system for AIS, achievement of the six goals fundamental to its creation has been demonstrated. The system is comprehensive and includes all types of curves. It is two-dimensional, emphasizing sagittal plane alignment. It is treatment-based, recommending arthrodesis only of necessary curves, allowing for selective fusion. It is objective, using specified criteria to differentiate individual curve types and has demonstrated good-to-excellent interobserver and intraobserver reliability. The high level of interobserver and intraobserver reliability demonstrated by this classification system allows for consistency when organizing operative curve patterns to compare different treatment options for similar curve patterns. This consistency will hopefully provide an objective means to arrive at the optimal treatment for each curve pattern.

References

1. Bernhardt M, Bridwell KH. Segmental analysis of the sagittal plane alignment of the normal thoracic and lumbar spines and thoracolumbar junction. Spine 1989;14:717–721
2. Vedantam R, Lenke LG, Keeney JA, et al. Comparison of standing sagittal spinal alignment in asymptomatic adolescents and adults. Spine 1998;23:211–215
3. Stokes IA, Bigalow LC, Moreland MS. Measurement of axial rotation of vertebrae in scoliosis. Spine 1986;11:213–218
4. Newton PO, Wenger DR. Idiopathic and congenital scoliosis. In: Morrissy RT, Weinstein SL, eds. Lovell and Winter's Pediatric Orthopaedics, Fifth edition. Philadelphia: Lippincott Williams & Wilkins; 2001:677–740
5. Cobb JR. Outline for study of scoliosis. In: Edwards JW, ed. Instr Course Lect. Ann Arbor: The American Academy of Orthopaedic Surgeons, 1948;5:261–265.
6. Freeman BL III. Scoliosis and kyphosis. In: Canale ST, ed. Campbell's Operative Orthopaedics, Tenth edition, Vol. XII. Mosby, St. Louis 2003: chap. 38
7. Ponseti IV, Friedman B. Prognosis in idiopathic scoliosis. J Bone Joint Surg Am 1950;32:381–395
8. Gelb DE, Lenke LG, Bridwell KH, et al. An analysis of sagittal spinal alignment in 100 asymptomatic middle and older aged volunteers. Spine 1995;20:1351–1358
9. King HA, Moe JH, Bradford DS, Winter RB. The selection of fusion levels in thoracic idiopathic scoliosis. J Bone Joint Surg Am 1983;65: 1302–1313
10. Lenke LG, Bridwell KH, Blanke K, et al. Radiographic results of arthrodesis with Cotrel-Dubousset instrumentation for the treatment of adolescent idiopathic scoliosis. A five to ten-year follow-up study. J Bone Joint Surg Am 1998;80:807–814
11. Bridwell KH, Betz R, Capelli AM, et al. Sagittal plane analysis in idiopathic scoliosis patients treated with Cotrel-Dubousset instrumentation. Spine 1990;15:921–926
12. Richards BS, Birch JG, Herring JA, et al. Frontal plane and sagittal plane balance following Cotrel-Dubousset instrumentation for idiopathic scoliosis. Spine 1989;14:733–737
13. Roye DP Jr, Farcy JP, Rickert JB, et al. Results of spinal instrumentation of adolescent idiopathic scoliosis by King type. Spine 1992; 17(8 Suppl) S270–273
14. Shufflebarger HL, Clark CE. Fusion levels and hook patterns in thoracic scoliosis with Cotrel-Dubousset instrumentation. Spine 1990;15:916–920
15. Cummings RJ, Loveless EA, Campbell J, et al. Interobserver reliability and intraobserver reproducibility of the system of King et al. for the classification of adolescent idiopathic scoliosis. J Bone Joint Surg Am 1998;80:1107–1111.
16. Lenke LG, Betz RR, Bridwell KH, et al. Intraobserver and interobserver reliability of the classification of thoracic adolescent idiopathic scoliosis. J Bone Joint Surg Am 1998;80:1097–1106
17. Lenke LG, Betz RR, Harms J, et al. Adolescent idiopathic scoliosis: a new classification to determine extent of spinal arthrodesis. J Bone Joint Surg Am 2001;83:1169–1181
18. Lenke LG, Betz RR, Clements D, et al. Curve prevalence of a new classification of operative adolescent idiopathic scoliosis: does classification correlate with treatment? Spine 2002;27:604–611
19. Lenke LG, Bridwell KH, Baldus C, et al. Ability of Cotrel-Dubousset instrumentation to preserve distal lumbar motion segments in adolescent idiopathic scoliosis. J Spinal Disord 1993;6:339–350
20. Hamill CL, Lenke LG, Bridwell KH, et al. The use of pedicle screw fixation to improve correction in the lumbar spine of patients with idiopathic scoliosis: is it warranted? Spine 1996;21:1241–1249
21. Lenke LG, Bridwell KH, Blanke K, et al. Analysis of pulmonary function and chest cage dimension changes after thoracoplasty in idiopathic scoliosis. Spine 1995;20:1343–1350
22. Vedantam R, Lenke LG, Bridwell KH, et al. A prospective evaluation of pulmonary function in patients with adolescent idiopathic scoliosis relative to the surgical approach used for spinal arthrodesis. Spine 2000;25:82–90
23. Graham EJ, Lenke LG, Lowe TG, et al. Prospective pulmonary function evaluation following open thoracotomy for anterior spinal fusion in adolescent idiopathic scoliosis. Spine 2000;25:2319–2325
24. Bridwell KH, Shufflebarger HL, Lenke LG, , et al. Parents' and patients' preferences and concerns in idiopathic adolescent scoliosis: a crosssectional preoperative analysis. Spine 2000;25:2392–2399
25. Betz RR, Harms J, Clements DH 3rd, et al. Comparison of anterior and posterior instrumentation for correction of adolescent thoracic idiopathic scoliosis. Spine 1999;24:225–239
26. Lenke LG, Engsberg JR, Ross SA, et al. Prospective dynamic functional evaluation of gait and spinal balance following spinal fusion in adolescent idiopathic scoliosis. Spine 2001;26:E330–337
27. Lenke LG, Rhee J. Adolescent scoliosis: anterior surgical techniques for adolescent idiopathic scoliosis. Curr Opin Orthop 2001;12:199–205

28. Sweet FA, Lenke LG, Bridwell KH, et al. Prospective radiographic and clinical outcomes and complications of single solid rod instrumented anterior spinal fusion in adolescent idiopathic scoliosis. Spine 2001;26:1956–1965

29. Lenke LG, Bridwell KH, O'Brien MF, et al. Recognition and treatment of the proximal thoracic curve in adolescent idiopathic scoliosis treated with Cotrel-Dubousset instrumentation. Spine 1994;19: 1589–1597

30. Kuklo TR, Lenke LG, Graham EJ, et al. Correlation of radiographic, clinical, and patient assessment of shoulder balance following fusion versus nonfusion of the proximal thoracic curve in adolescent idiopathic scoliosis. Spine 2002;27:2013–2020

31. Lenke LG, Betz RR, Haher TR, et al. Multisurgeon assessment of surgical decision-making in adolescent idiopathic scoliosis: curve classification, operative approach, and fusion levels. Spine 2001;26: 2347–2353

Chapter 7

Principles of Sagittal Plane Deformity

Stephen L. Ondra and Shaden Marzouk

The spine is a three-dimensional structure that can be defined in coronal, sagittal, and axial planes, and its motion can be described as translation, rotation, or angulation. In the coronal plane, the spine is typically straight except for an infinitesimal right thoracic convexity, which is likely relating to the aorta. Whereas the coronal plane is fairly easily defined, the normal sagittal plane is variable.[1]

These planes define posture. Gait and posture work best when the head and trunk fall over the pelvis. In this position, the bony center of mass falls over the femoral axis balancing the body in an upright posture. The coronal plumb line is drawn from C2 and the sagittal plumb line is usually drawn from C7 to avoid issues with the lateral radiographic quality of the dens. Thoracic kyphosis and lumbar lordosis should be directly proportional to each other,[2] thus balancing the spine. A positive sagittal balance is when the C7 plumb line falls more than 2 to 4 cm in front of the sacrum. Negative sagittal balance is when the C7 plumb line falls behind the sacrum[3] **(Fig. 7–1).**

At birth the spine is kyphotic,[4] and with bipedal locomotion, the spine develops secondary lordotic curves in the cervical and lumbar spine. This allows balanced bipedal locomotion. An intact abdominal wall is also necessary for sagittal balance.[5] Posture changes with age as muscles, tendons, ligaments, nerves, and bones undergo degenerative change.

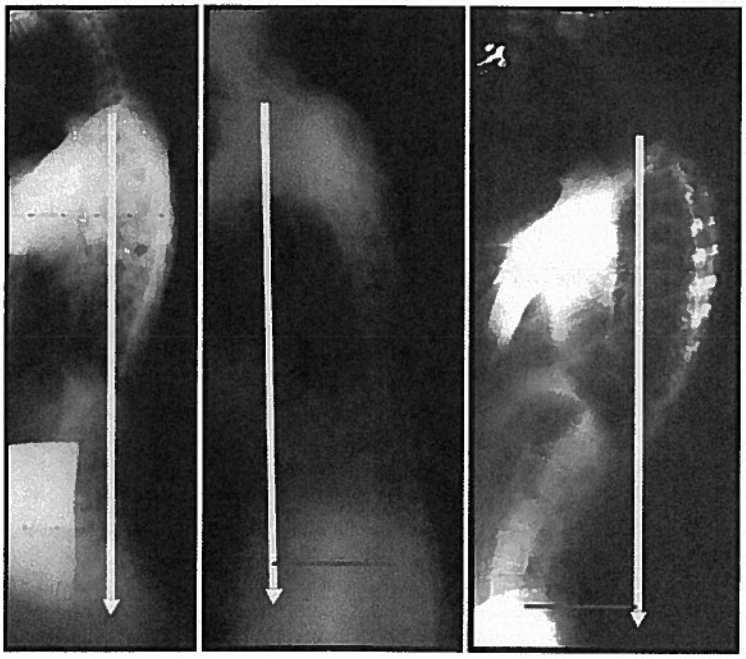

A–C

Figure 7–1 Sagittal alignment of the spine is typically defined as the alignment of C2 and C7 relative to the sacrum. This alignment is considered normal if C7 lies over the sacrum as in **(A).** It is positive if C7 falls more than 2 to 4 cm anterior to the sacrum as in **(B)** and negative if it falls behind **(C).** The relationship of C2 is still not well defined.

We get more cervical lordosis and thoracic kyphosis and less lumbar lordosis with age. This is typically due to osteoporotic wedging of the thoracic vertebrae and a loss of lumbar disk height. Lumbar disks account for the lordosis by not only making up one third of the lumbar height but also by being larger in the front. With degeneration, lumbar disks flatten causing a loss of lordosis. If the spine cannot compensate and adapt to these changes, the hips and legs try to compensate. Iatrogenic alterations to the spine's alignment can accelerate this process. Because the ribs add more rigidity to the thoracic spine, it is harder to change the thoracic curve, making the lumbar spine more vulnerable to alteration, which is often a reduced lordosis. In addition, pelvic angulation has great impact on the lumbar spine. The pelvis and its rotation is the most potent compensatory structure in the spine.

One of the most important functions of the spine is to position the head in space, as well as allow for our bipedal locomotion. The body will attempt to return its center of gravity over the hips through hip extension, knee flexion, and posterior pelvic angulation. Ignoring the sagittal plane can produce accelerated junctional disk degeneration, bone-implant failure, flat back, and pain and degeneration in the sacroiliac, hip, knee, and ankle joints. Attention to sacral inclination is important. Leaving a patient with a vertical sacrum places them at maximum compensation with no reserve to compensate for any new imbalance. It is important that the sacrum be restored to a near normal position of ~40 degrees **(Fig. 7–2)**.

Specifically defined, sagittal balance is the alignment of C7 to the posterior superior aspect of S1 on an upright long cassette radiograph. This line is drawn from the center of C7 and should be plus or minus 2 to 4 cm from the sacral promontory. Sagittal balance is a summary picture of cervical lordosis opposing thoracic kyphosis, which opposes lumbar lordosis. The lumbar lordosis then opposes sacral inclination, and pelvic and hip angulation, to maintain a center of gravity.

The film used to assess sagittal balance is a standing lateral x-ray on a 3-ft-long cassette. The patient stands upright with their arms positioned with the fingers along their clavicle and their head facing forward. The x-ray tube is positioned 6 ft from the patient. Different techniques can deal with the potential for the shoulder and pelvis to obscure the spine. Measurements used to discuss parameters associated with sagittal balance are often drawn by hand directly onto these films, but one can also use specially designed software.[6]

Changes in the joint angles of the lower extremities can change sagittal balance measurements, so it is important to have standardized controls for patient x-ray positioning. This can be especially difficult in the ankylosing spondylitis population, many of who undergo sagittal balance corrective procedures.[7] Tight hamstrings can lead to continued imbalance even after spinal correction. This may have developed as a previous compensatory mechanism.[8] Regardless, proper assessment of sagittal balance requires that the knees be fully extended and the sacrum be in a neutral rotation at 40 degrees.

There are several measurements and terms used when discussing sagittal balance concepts. Kyphosis and lordosis are measured by the Cobb angle, which has been a standard. Observer and film-quality contribution have variability in measurement error of 2 to 3 degrees.[9] The Cobb angle is the angle of the perpendiculars drawn from lines at the top and bottom of a curve in the spine **(Fig. 7–3)**.

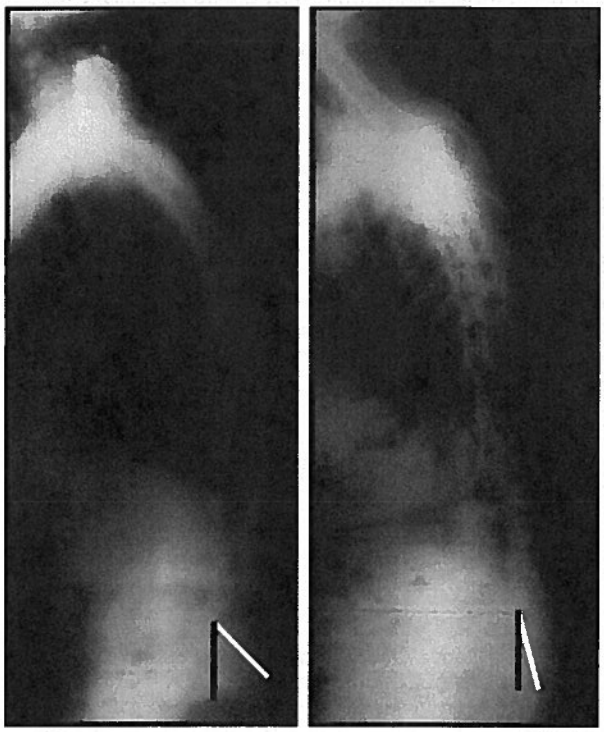

Figure 7–2 The sacral orientation can dramatically affect sagittal balance. **(A)** A normal alignment and **(B)** a maximally compensated vertical alignment.

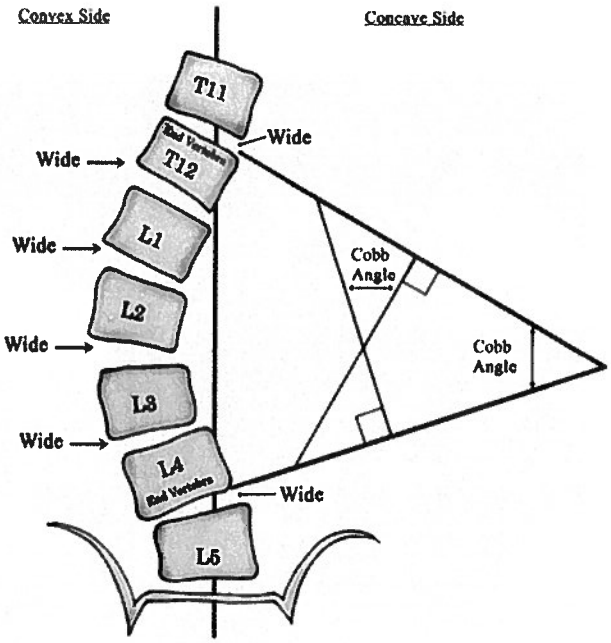

Figure 7–3 The method of Cobb is a method of measuring a curve angle that has inter- and intraobserver validation to 3 degrees of accuracy and is an international standard.

♦ Sacral Slope

The sacropelvic area is key to understanding the forces and responses to sagittal balance problems. Sacral inclination is the angle between the line along the posterior border of S1 and the vertical lateral edge of a lateral standing radiograph. The center sacral line is the vertical line in an AP radiograph that goes through the center of the sacrum, through S1. Pelvic obliquity is the angulation of the pelvis from the horizontal in the frontal plane **(Fig. 7–4)**. Pelvic inclination is the angle from a line drawn from the top of the sacrum to the top of the pubis and a horizontal line perpendicular to the lateral edge of the standing film. This can be altered by hip joint contraction.

Pelvic incidence is the sum of sacral inclination and pelvic tilting.[10] The pelvic incidence appears to be the main axis of the sagittal balance of the spine.[10] Our bipedal standing posture is made possible by hip extension and lumbar lordosis, the latter of which is correlated with the pelvis. The pelvic incidence angle increases until age 10, then it stabilizes.[11]

As mentioned, the pelvic incidence correlates with sacral slope and lumbar lordosis, ensures a good standing position, and is important to sagittal balance. This depends partly on the sagittal anatomy of the sacrum, which is established as children learn to stand and walk. The sacral anatomy of spondylolisthesis patients is similar to that of infants, with more curvature and a larger incidence angle, revealing the sacral bone's integral role to sagittal balance.[12] In addition, the hyperlordosis and horizontally positioned sacrum in isthmic spondylolisthesis causes tensile forces that may result in lysis.[13]

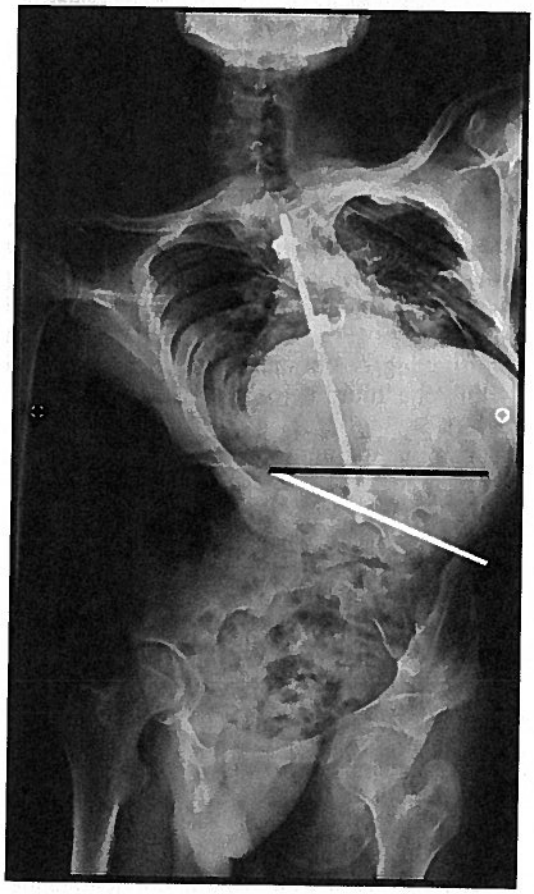

Figure 7–4 The pelvis can have an oblique angle as in this example. It must be determined if the obliquity is the cause of a compensatory curve or if the curve is structural and the pelvic obliquity is itself compensatory. Leg length and bending films can help in this assessment.

♦ Pelvic Tilt and Obliquity

A person's posture may or may not allow them to achieve balance in the sagittal plane. Balance is defined by the C7 plumb line and its relationship to the axis of rotation about the hips, so the position of the hips on the standing x-ray film is important. In normal or congruent sagittal spinopelvic balance, the thoracic kyphosis and lumbar lordosis balance each other. If the loss of lumbar lordosis is not associated with a reduction in thoracic kyphosis, the hips and pelvis try to correct for this, and these patients are in uncompensated balance.[3]

Normal cervical lordosis is 40 degrees ±9.7 degrees. Some feel the occipitocervical junction is in kyphosis and the majority of lordosis occurs between C1 and C2. The lower cervical spine has an average lordosis of 6 degrees. Normal thoracic kyphosis is 20 to 50 degrees. The upper thoracic anatomy is often hard to measure on the 3-ft films, but the kyphotic apex should be at T7 or T8. Although T12-L1 usually is in ~3 degrees of lordosis, it often appears flat.[3]

Lumbar lordosis ranges from 31 to 79 degrees, with the largest component (two thirds) being at L4-S1, and the apex at L3-L4. The degree of variability in this definition depends on whether one measures down to L5 or S1, and that varies depending on physician preference and film quality. In addition, the morphology of L5, sacral inclination, and pelvic characteristics can change the measurement of lumbar lordosis. Maintaining lumbar lordosis is very important and is the basis for the biomechanics of shaping interbody spacers and the lordotic position maintained by the Jackson table. Wedge-shaped cages increase segmental and regional lumbar lordosis, restoring sagittal alignment.[14]

Excessive compensatory lumbar lordosis can cause L5-S1 foraminal stenosis. Reduced lumbar lordosis without a parallel reduction in thoracic kyphosis moves the sagittal plumb line anterior. The spine and hips try to adjust, and if that does not work, the legs try to compensate. Patients can be left in a "jump position" with their hips and knees excessively flexed, and the quality of their adjustment will leave them in an uncompensated or compensated balance.[3] The impact of hip or knee flexion on sagittal balance cannot be ignored. This position is also expensive to the patient in terms of energy usage and the ability to stand and ambulate.

As we age, we develop a more forward sagittal vertical axis with loss of distal lumbar lordosis but without an increase in thoracic kyphosis. The majority of asymptomatic people have maintained their sagittal alignment despite aging. However, if they do not maintain sagittal alignment, it is the loss of distal lumbar lordosis that is more responsible.[15] Sagittal plane correction, particularly in lumbar lordosis, is harder to achieve in the over-50 population.[16]

About two thirds of the total lordosis occurs at L4–L5, L5-S1. The importance of loss of lordosis and its surgical restoration cannot be overemphasized to the practicing surgeon as the majority of degenerative disease and its treatment occurs from L4 to S1. The restoration of lordosis can have a profound impact on the patient long-term. Patients with axial low back pain tend to stand with less distal lumbar lordosis but more proximal lumbar lordosis, a more vertical sacrum, and more hip extension to attempt to compensate themselves into sagittal balance.

Essentially any parameter one uses to measure and characterize the spine, the pelvis, and spinopelvic relations impacts the other. One study featured 300 asymptomatic volunteers who had standing films to measure lumbar lordosis (mean 60 degrees), thoracic kyphosis, T9 sagittal offset (10 degrees), sacral slope (41 degrees), pelvic incidence (55 degrees), pelvic tilt (13 degrees), intervertebral angulation, and vertebral wedging angle from T9 to S1. Sacral slope and pelvic incidence correlated, and lumbar lordosis and sacral slope correlated, as well as the following pairs: pelvic incidence and pelvic tilt, lumbar lordosis and pelvic incidence, and pelvic tilt and thoracic kyphosis. The T9 sagittal offset reflected the spine's sagittal balance and was dependent on pelvic incidence, lumbar lordosis, sacral slope, pelvic tilt, and thoracic kyphosis. The reciprocal balance between these various spinal angular parameters needs to be considered in the discussion and treatment planning of sagittal balance.[17]

The relationship between the shape of the pelvis and lumbar lordosis was studied in 100 asymptomatic subjects on standing films. Pelvic incidence had a mean value of 52 degrees, lumbar lordosis had a mean of 45 degrees, and thoracic kyphosis had a mean of 47 degrees. Lumbar lordosis correlated with pelvic incidence and sacral slope. The spine and pelvis balance around the hip axis to keep the gravity line over the femoral heads.[18] Lumbar lordosis and spinopelvic alignment are closely associated, and those with less lordosis translate their sacropelvis posteriorly, giving the appearance that they are less well balanced over the hips.[19]

The upper spine is also key to sagittal balance. When the chin to eyebrow vertical angle, as measured on patient photos pre- and postcorrection of a kyphotic deformity in ankylosing spondylitis, went from 36 to 2 degrees, lumbar lordosis increased, thoracic kyphosis was stable, and sagittal balance improved.[20]

Causes of sagittal deformity can be degenerative disk and joint disease, postlaminectomy syndrome, ankylosing spondylitis, trauma, and iatrogenic causes like flat back **(Fig. 7–5).** Pedicle subtraction osteotomy (PSO) can be used to restore a more normal sagittal balance when the deformity is fixed.[21] Smith-Petersen osteotomy with or without an interbody spacer can be used for mobile segmental pathology[22] **(Fig. 7–6).**

Through a PSO, the posterior column is shortened and the vertebral body undergoes a wedge resection, which can correct 30 to 40 degrees at a single level. The posterior elements, pedicle, and vertebral body are resected. The vertebral body wedge resection involves the posterior lateral corner, lateral cancellous bone, lateral wall wedge, central cancellous wedge, and posterior wall. This can be done in the lumbar and thoracic spine. This can accomplish a two-plane correction, can be done at a prior laminectomy site, and allows for one approach—posterior—for correction of a fixed deformity **(Fig. 7–7).** Preoperatively, one should calculate the degrees of correction, the optimum location, and thus the number of osteotomies needed **(Figs. 7–8 and 7–9).**

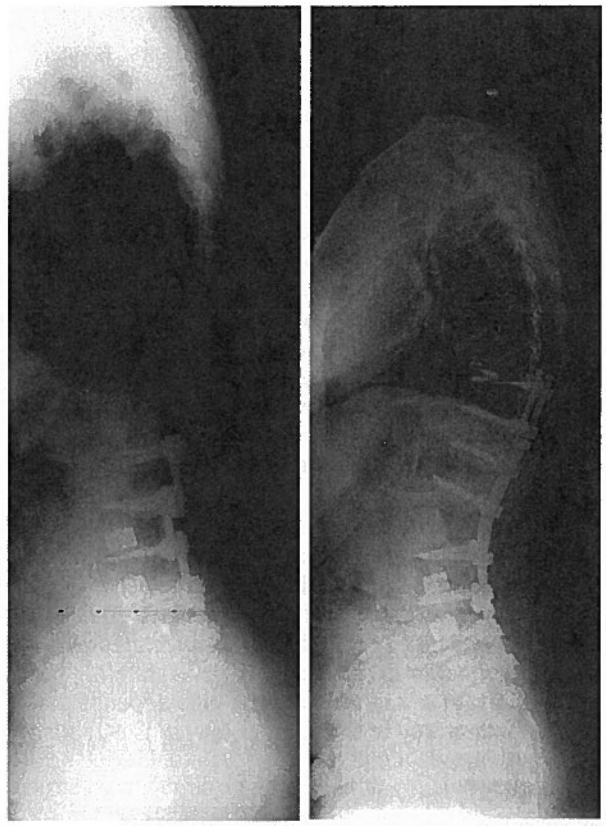

Figure 7–5 (A) Latrogenic flat back caused by leveling of the lumbar disks in a multilevel posterior lumbar interbody fusion (PLIF). This resulted in a loss of the normal lumbar curvature and a disabling positive sagittal balance. This was treated with **(B)** a pedicle subtraction osteotomy.

Complications can include neurological injury (4 to 5%), cerebrospinal leak (up to 7.4%), pseudoarthrosis (10 to 22%), usually from the lack of interbody grafts supporting the osteotomy site, inadequate correction (5 to 11%), and complication necessitating revision (5 to 7.4%).[23]

Flat back is all too commonly an iatrogenically driven cause for the loss of sagittal balance. This was classically associated with Harrington instrumentation extending into the lower lumbar spine. Today it is most commonly associated with lumbar degenerative constructs that do not restore or account for lumbar lordosis **(Figs. 7–6A and 7–6B).** Other causes of flat back are pseudoarthrosis, postoperative loss of correction, thoracolumbar kyphosis, adjacent level disease, or hip flexion contractures.

Restoration of sagittal balance is the philosophy behind many modern procedures. Reducing a high-grade spondylolisthesis[24] that is functionally a focal kyphotic deformity is an example. Slip reduction leads to improved focal and global

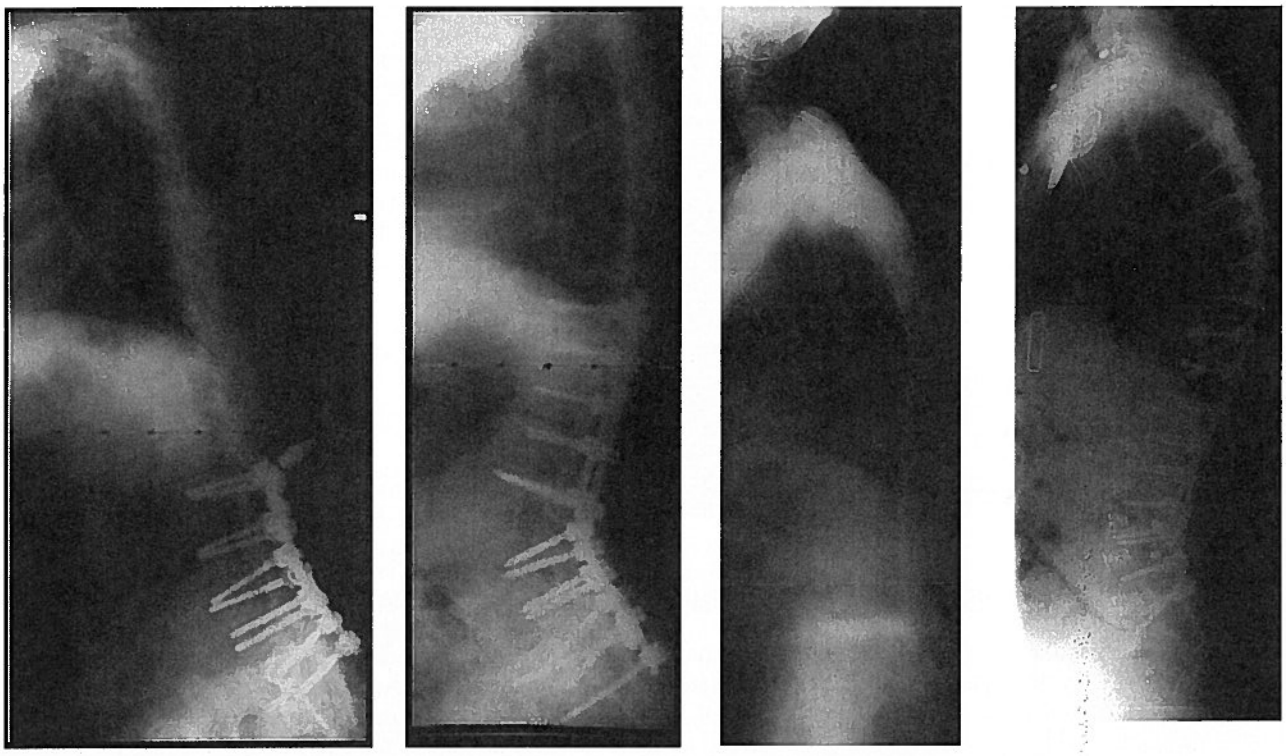

A-D

Figure 7–6 Fixed sagittal deformity, such as an iatrogenic flat back, is most easily corrected by a pedicle subtraction osteotomy, shown in the pre- and postoperative images in **(A)** and **(B)**. Flexible deformity with preservation of the disk spaces can be effectively treated with a pedicle subtraction osteotomy or it can be treated with Smith-Petersen posterior osteotomies and an anterior release and grafting (pre- and postoperative images **[C]** and **[D]**).

alignment. It is associated with improved outcomes.[24] In any correction, the level of the correction and angle of osteotomy[25] is integral to achieving a positive outcome for the patient. This is true even in pseudoarthrosis repair.[26] Interbody spacers can be designed with sagittal balance in mind. Disk space distraction with a cage restores segmental height, increased neuroforaminal space, and sagittal balance when posterior correction is applied.[27] This is due to the axis of rotation moving forward to the cage allowing posterior shortening to occur.

Advances, such as flexible stabilization systems, which can maintain sagittal balance in varying postures,[28] and next-generation instrumentation,[29] also subscribe to a global as opposed to a "local" philosophy of correction. Even the

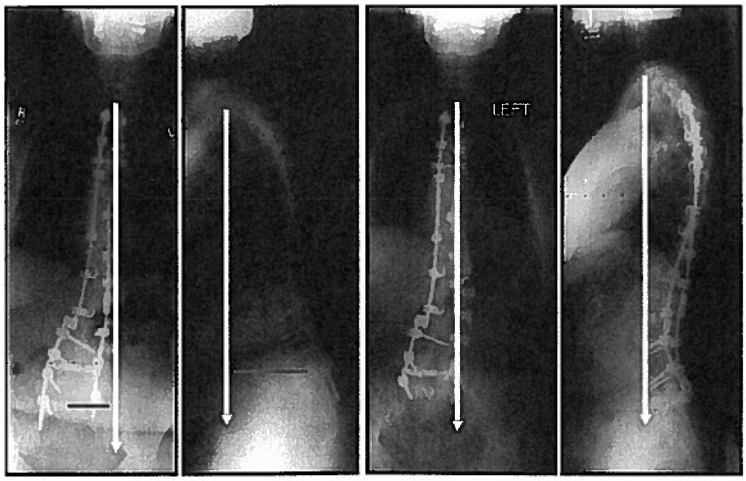

A-D

Figure 7–7 Fixed iatrogenic sagittal and coronal imbalance **(A)** and **(B)** corrected with a single all posterior asymmetric pedicle subtraction (postoperative **[C]** and **[D]**).

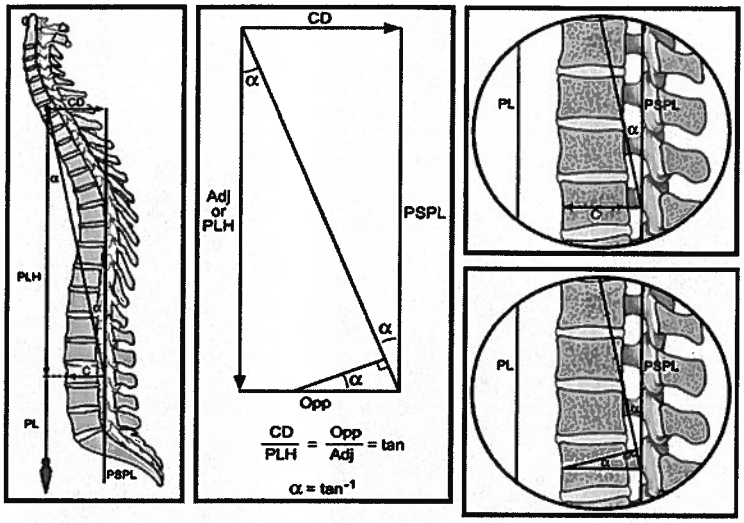

Figure 7–8 Trigonometric calculation of the angle needed for correction. This simple and quick method allows accurate preoperative assessment of the angle needed to reestablish sagittal balance. This can then lead the surgeon to the correct osteotomy, or combination of osteotomy choices, to achieve the goal of sagittal balance.

development of external orthosis is affected by the ideas of sagittal balance.[30]

What does this mean to a practitioner who does not run a specialty deformity practice? How should one evaluate spine patients who do not have a complex deformity but need a possible segmental fusion or decompression? What sorts of diagnostic films should be selected and what terminology applied? More importantly, what solutions are practical, and is a paradigm shift needed to successfully treat spine patients seen in general spine surgical practice?

There is a large and growing body of literature supporting the importance of restoring sagittal balance to the spine. The overreaching message is this: Regardless of the specific surgical method or particular pathology, positive patient outcomes resulted from the restoration of sagittal balance. For example, adults with pain, stenosis, and idiopathic scoliosis had better outcomes in the areas of pain relief, function, and patient satisfaction with the restoration of coronal and sagittal balance.[31] Of these, sagittal balance restoration has the most important and direct relationship to patient pain and functional improvement. Failure to restore sagittal alignment is also correlated with poor patient outcomes. It can also lead to adjacent segment deterioration due to the need to compensate above a reconstruction. Attention to focal and global sagittal restoration can then lead to improved short- and long-term outcomes. It decreases adjacent segment strain and preserves compensatory reserve in the spine.[32]

Complex deformity patients are normally a subspecialty referral, and sagittal balance is a natural part of their treatment planning. The aforementioned questions are already considered in this population. In the larger scope of things, spinal fusions, though fairly common among general spine surgeons, are not always considered within the framework of sagittal balance. Unsuccessful outcomes, including continued pain, adjacent level disease, accelerated degenerative change, pseudoarthrosis, and hip and knee changes, may then ensue. Certainly, those patients need to be reevaluated with attention to the global balance of their spines, using the 36-in. x-ray films and measurement parameters (like the C7 plumb line and knowledge of the normal Cobb angles) discussed in this chapter. The reason for their outcome may be sagittal imbalance, and osteotomy techniques as well as fusion extension may be needed. More importantly, we encourage any patient being considered for a

A-D

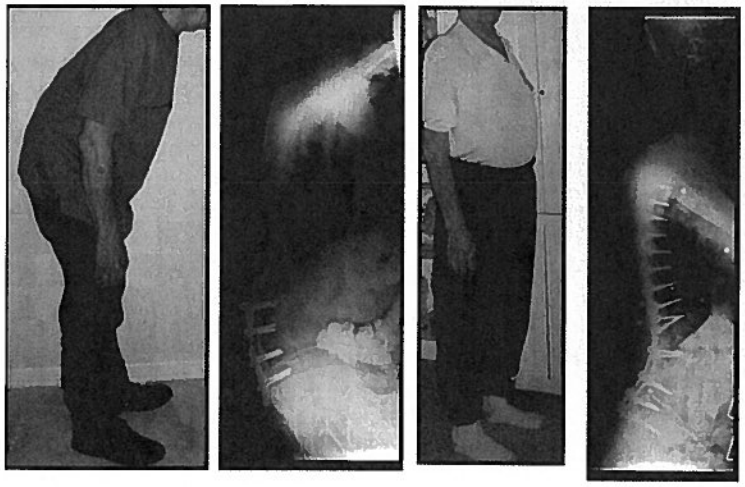

Figure 7–9 Iatrogenic flat back with lumbar kyphosis and gross sagittal imbalance. **(A, B)** The sacral inclination is in negative numbers in an attempt to compensate in these preoperative scans. The calculated angle of correction needed was 72 degrees. This could only be achieved with two pedicle subtraction osteotomies. Preoperative knowledge of the needed correction allowed for **(C, D)** a successful surgical strategy.

reconstruction of any kind to undergo formal alignment assessment with a posture exam and 36-in. x-ray films. In this way, sagittal restoration can be planned in the original procedure.

The paradigm shift will hopefully come that will improve these outcomes by preoperatively evaluating, calculating, and planning for correction of sagittal imbalance within the original operative treatment. The definitions and terms discussed in the first part of this chapter, as well as the overall importance of sagittal balance to our spine patients, is becoming a more common knowledge base among spinal practitioners. This trend will hopefully lead to more comfort with the subject, wider application, and an earlier introduction into training. This could result in a greater awareness that intervention in the spine is not always limited to a particular segment but impacts globally through the entire skeletal structure due to compensatory postures used to achieve and maintain sagittal alignment.

References

1. Stagnara P, De Mauroy JC, Dran G, et al. Reciprocal angulation of vertebral bodies in a sagittal plane: approach to references in the evaluation of kyphosis and lordosis. Spine 1982;7:335–342
2. Bernhardt M. Normal spinal anatomy: normal sagittal plane alignment. In: Bridwell KH, Dewald RL, eds. The Textbook of Spinal Surgery. Philadelphia: Lippincott-Raven; 1997:185–191
3. Knight RQ, Jackson RP, Killian JT, Stanley EA, Lowe T, Winter RB. Scoliosis research society white paper on sagittal plane alignment. Available at www.srs.org/professionals
4. Spivak JM, Giordano CP. Cervical kyphosis. In: Bridwell KH, Dewald RL, eds. The Textbook of Spinal Surgery. Philadelphia: Lippincott-Raven; 1997:1027–1038
5. Lam KS, Mehdian H. The importance of an intact abdominal musculature mechanism in maintaining spinal sagittal balance. Case illustration in prune-belly syndrome. Spine 1999;24:719–722
6. Rajnics P, Pomero V, Templier A, Lavaste F, Illes T. Computer-assisted assessment of spinal sagittal plane radiographs. J Spinal Disord 2001;14:135–142
7. Van Royen BJ, Toussaint HM, Kingma I, et al. Accuracy of the sagittal vertical axis in a standing lateral radiograph as a measurement of balance in spinal deformities. Eur Spine J 1998;7:408–412
8. Hosman AJ, Langeloo DD, de Kleuver M, Anderson PG, Veth RP, Slot GH. Analysis of the sagittal plane after surgical management for Scheuermann's disease: a view on overcorrection and the use of an anterior release. Spine 2002;27:167–175
9. DeSmet AA. Radiographic evaluation. In: DeSmet AA, ed. Radiology of Spinal Curvature. St. Louis: Mosby; 1985:23
10. Legaye J, Duval-Beaupere G, Hecquet J, Marty C. Pelvic incidence: a fundamental pelvic parameter for three-dimensional regulation of spinal sagittal curves. Eur Spine J 1998;7:99–103
11. Mangione P, Gomez D, Senegas J. Study in the course of the incidence angle during growth. Eur Spine J 1997;6:163–167
12. Marty C, Boisaubert B, Descamps H, et al. The sagittal anatomy of the sacrum among young adults, infants, and spondylolisthesis patients. Eur Spine J 2002;11:119–125
13. Rajnics P, Templier A, Skalli W, Lavaste F, Illes T. The association of sagittal spinal and pelvic parameters in asymptomatic persons and patients with isthmic spondylolisthesis. J Spinal Disord Tech 2002;15:24–30
14. Godde S, Fritsch E, Dienst M, Kohn D. Influence of cage geometry on sagittal alignment in instrumented posterior lumbar interbody fusion. Spine 2003;28:1693–1699
15. Gelb DE, Lenke LG, Bridwell KH, Blanke K, McEnery KW. An analysis of sagittal spinal alignment in 100 asymptomatic middle and older aged volunteers. Spine 1995;20:1351–1358
16. Takahashi S, Delecrin J, Passuti N. Surgical treatment of idiopathic scoliosis in adults: an age-related analysis of outcome. Spine 2002;27:1742–1748
17. Vialle R, Levassor N, Rillardon L, Templier A, Skalli W, Guigui P. Radiographic analysis of the sagittal alignment and balance of the spine in asymptomatic subjects. J Bone Joint Surg 2005;87:260–267
18. Vaz G, Roussouly P, Berthonnaud E, Dimnet J. Sagittal morphology and equilibrium of the pelvis and spine. Eur Spine J 2002;11:80–87
19. Jackson RP, Peterson MD, McManus AC, Hales C. Compensatory spinopelvic balance over the hip axis and better reliability in measuring lordosis to the pelvic radius on standing lateral radiographs of adult volunteers and patients. Spine 1998;23:1750–1767
20. Suk KS, Kim KT, Lee SH, Kim JM. Significance of chin-brow vertical angle in correction of kyphotic deformity of ankylosing spondylitis patients. Spine 2003;28:2001–2005
21. Potter BK, Lenke LG, Kuklo TR. Prevention and management of iatrogenic flatback deformity. J Bone Joint Surg Am 2004;86-A:1793–1808
22. Bridwell KH. Osteotomies for fixed deformities in the thoracic and lumbar spine. In: Bridwell KH, Dewald RL, eds. The Textbook of Spinal Surgery. Philadelphia: Lippincott-Raven; 1997:821–836
23. Booth KC, Bridwell KH, Lenke LG, Baldus CR, Blanke KM. Complications and predictive factors for the successful treatment of flatback deformity (fixed sagittal imbalance). Spine 1999;24:1712–1720
24. Boachie-Adjei O, Do T, Rawlins BA. Partial lumbosacral kyphosis reduction, decompression, and posterior lumbosacral transfixation in high-grade isthmic spondylolisthesis: clinical and radiographic results in six patients. Spine 2002;27:E161–E168
25. Van Royen BJ, De Gast A, Smit TH. Deformity planning for sagittal plane corrective osteotomies of the spine in ankylosing spondylitis. Eur Spine J 2000;9:492–498
26. Berven S, Kao H, Deviren V, Hu S, Bradford D. Treatment of thoracic pseudoarthrosis in the adult: is combined surgery necessary? Clin Orthop Relat Res 2003;411:25–31
27. Steffen T, Tsantrizos A, Fruth I, Aebi M. Cages: designs and concepts. Eur Spine J 2000;9:S89–S94
28. Mulholland RC, Sengupta DK. Rationale, principles and experimental evaluation of the concept of soft stabilization. Eur Spine J 2002;11:S198–S205
29. Benli IT, Akalin S, Kis M, Citak M, Aydin E, Duman E. Frontal and sagittal balance analysis of late onset idiopathic scoliosis treated with third generation instrumentation. Kobe J Med Sci 2001;47:231–253
30. Labelle H, Dansereau J, Bellefleur C, Poitras B. Three-dimensional effect of the Boston brace on the thoracic spine and rib cage. Spine 1996;21:59–64
31. Shapiro GS, Taira G, Boachie-Adjei O. Results of surgical treatment of adult idiopathic scoliosis with low back pain and spinal stenosis: a study of long-term clinical radiographic outcomes. Spine 2003;28:358–363
32. Kawakami M, Tamaki T, Ando M, Yamada H, Hashizume H, Yoshida M. Lumbar sagittal balance influences the clinical outcome after decompression and posterolateral spinal fusion for degenerative lumbar spondylolisthesis. Spine 2002;27:59–64

Chapter 8

Principles of Coronal Plane Deformity

Moe R. Lim, Joon Y. Lee, and Todd J. Albert

Correction and preservation of truncal balance is a critical component in the surgical treatment of spinal deformities. Since the recognition of iatrogenic flat-back syndrome, recent discussions have largely been directed at imbalance in the sagittal plane. This chapter will focus on the surgical correction of imbalance in the coronal plane.

Spinal decompensation or imbalance is caused by the inability or loss of ability of the normal portion of the spine to compensate for a structurally abnormal primary deformity. The primary deformity can be of any origin—idiopathic, congenital, neuromuscular, post-traumatic, and so forth. In cases where the primary deformity is not severe and the normal portions of the spine (above and/or below the primary deformity) are able to form a compensatory curve, the spinal axis remains balanced with the head centered over the sacrum. In cases where the primary deformity is so severe that the remainder of the spine is unable to fully compensate, an imbalance occurs. An imbalance will also result in cases where, due to age-related changes, the normal portion of the spine becomes structurally abnormal or loses its ability to keep pace with the progressive primary deformity.

Patients with coronal plane deformities often have associated sagittal and axial plane deformities. Although this chapter brings attention to the surgical restoration of coronal balance, we stress that the coronal plane deformity should not be evaluated or treated in isolation but in the context of the accompanying sagittal and axial plane deformities.

The majority of spinal deformity literature highlights the amount of correction of Cobb angle magnitudes. Although correction of the primary deformity is important, the amount of correction obtained should be secondary to the achievement of coronal and sagittal balance. Balanced nonprogressive deformities in the coronal plane are usually well tolerated by patients. It is when the spine becomes unbalanced that symptoms arise.

Coronal imbalance is of primary concern in five categories of spinal deformity: adolescent idiopathic scoliosis with major thoracic-compensatory lumbar curves, adult idiopathic scoliosis, degenerative scoliosis, congenital scoliosis, and complex rigid multiplanar deformities. The surgical restoration of coronal balance for each of these categories will be discussed.

♦ Clinical Evaluation of Coronal Balance

The evaluation of a patient with a spinal deformity begins with a detailed history. The onset of the deformity and prior treatments are necessary details to elicit. It is important to determine whether pain is associated with the deformity and whether the pain is axial or related to neural compression. Axial pain in spinal deformity can be related to muscle fatigue, degenerative disk disease, or facet arthrosis. The patient with symptomatic spinal imbalance (coronal or sagittal) will usually experience fatigue-related axial pain. Dissatisfaction with appearance is a common complaint. Patients with coronal imbalance may also experience a sensation of unequal leg lengths (even though measured leg lengths are equal) and an uneven pelvis during sitting and standing. Many patients with mild coronal imbalance can be asymptomatic, however. The amount of coronal imbalance that is tolerated prior to onset of symptoms is not well defined.

Coronal imbalance can be readily recognized with careful physical examination. The patient is asked to stand straight and is viewed from four directions. From the front and back views, the shifting of the trunk and relative heights of iliac crests and shoulders are noted. A plumb line is dropped from the palpable spinous process of C7 (or T1). The deviation of the plumb line from the gluteal cleft denotes the amount of clinical imbalance **(Fig. 8–1)**. From the side views, signs of sagittal imbalance such as loss of lumbar lordosis or hip/knee flexion are noted. The patient is then asked to forward bend and is viewed again from four directions to look for thoracic hump and lumbar asymmetry. Lateral bending in the standing

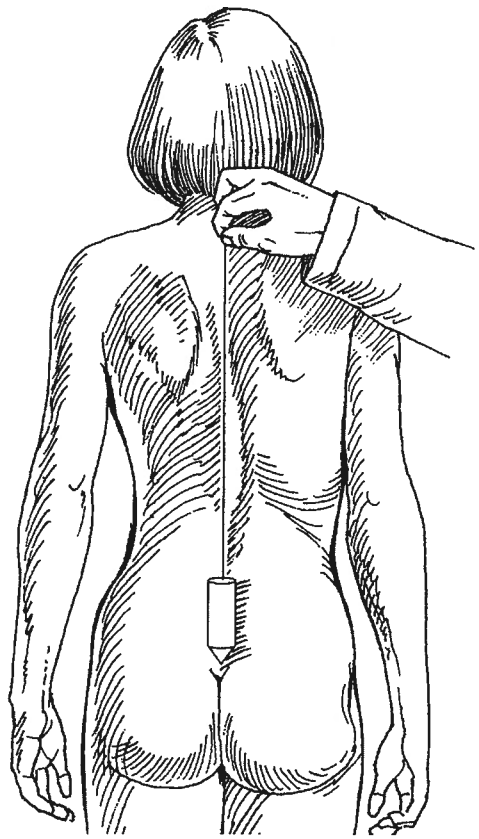

Figure 8–1 A plumb line is dropped from the palpable spinous process of C7 (or T1). The deviation of the plumb line from the gluteal cleft, measured in centimeters, denotes the amount of clinical imbalance. (From Albert TJ, Vaccaro AR. Physical Examination of the Spine. New York: Thieme, 2005, with permission.)

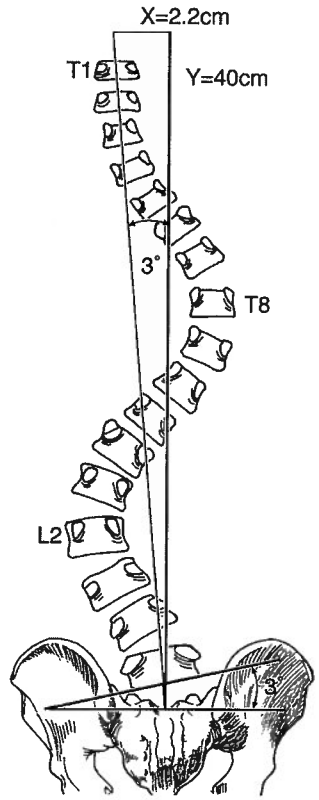

Figure 8–2 A lumbosacral fractional curve creates an uneven foundation for the entire spine. For example, in a patient with an uncompensated lumbosacral fractional curve of 3 degrees and an average spinal column length of 40 cm, a coronal decompensation of 2.2 cm would result.

position can give the surgeon a sense of how flexible the curves are and whether pain or radicular symptoms are reproduced. The remainder of the clinical evaluation is completed with a thorough neurologic examination.

♦ Radiographic Evaluation of Coronal Balance

To assess spinal deformity, standing posterior-anterior and lateral views of the entire spine are viewed on long 36-in. cassettes. Cobb angle magnitudes of all curves are measured. Pelvic obliquity in the standing or sitting positions is determined. To evaluate shoulder balance, the horizontal tilt of T1 and the clavicle angle should be measured. The clavicle angle is formed by the intersection of the horizontal line and the tangential line connecting the highest two points of each clavicle. This angle has been shown to correlate best with shoulder balance.[1] If present, the lumbosacral fractional curve is important to evaluate. A lumbosacral fractional curve creates an uneven foundation for the entire spine. If not compensated by another fractional curve, a curve of only a few degrees can lead to coronal imbalance. For example, in a patient with an uncompensated lumbosacral fractional curve of 3 degrees and an average spinal column length of 40 cm, a coronal decompensation of 2.2 degrees would result **(Fig. 8–2)**.

To determine if a coronal plane deformity is balanced, a vertical plumb line is drawn from the spinous process or midbody of C7 (or T1) toward the floor. In a coronally balanced spine, this line should pass within 1 cm of the center of the sacrum or the spinous process of S1. The amount of lateral deviation of this line away from the middle of the sacrum (measured in centimeters, toward the left or the right) denotes the radiographic coronal imbalance **(Fig. 8–3)**. Alternatively, some authors report coronal imbalance as trunk shift. To measure trunk shift, the center sacral line (CSL) is constructed as a vertical line extended cephalad from the spinous process of S1. A second vertical plumb line is constructed from the midbody of C7 or T1 toward the floor. The horizontal distance between these two lines denotes the trunk shift.

Bending views to assess the flexibility of the primary and compensatory curves are mandatory for preoperative planning. Some surgeons prefer supine left and right bending views, whereas others prefer push-prone techniques.[2] The push-prone film is obtained by placing the patient prone on a 36-in. cassette. A firm medial translational force is applied to the portion of the torso that corresponds with the apex of the primary curve. Counterforces are then applied to the

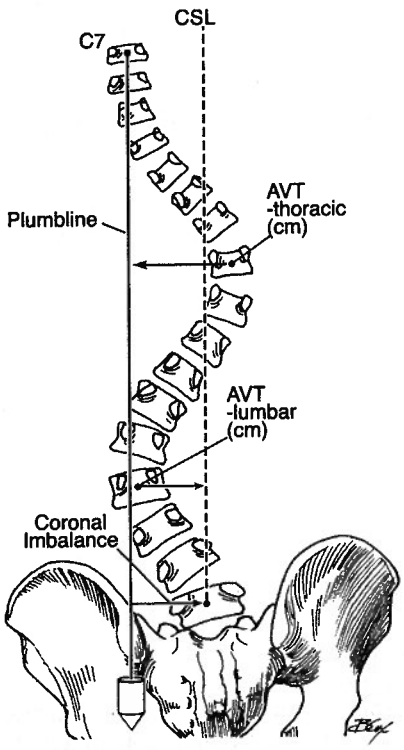

Figure 8–3 To determine if a coronal plane deformity is balanced, a vertical plumb line is drawn from the spinous process or midbody of C7 (or T1) toward the floor. The amount of lateral deviation of this line away from the middle of the sacrum (measured in centimeters, toward the left or the right) denotes the radiographic coronal imbalance. The central sacral line (CSL) is constructed as a vertical line extended cephalad from the spinous process of S1. The apical vertebral translation (AVT) is the distance of the apical vertebra of the thoracic curve from the plumb line and lumbar curve from the CSL.

opposite side of the body in the axilla and pelvis by an assistant to create a three-point corrective force.

Also to assist with preoperative planning, the neutral, stable, and apical vertebrae are identified on the standing and bending films. The stable vertebrae is the segment most closely bisected by the CSL. The neutral vertebrae are the nonrotated vertebrae at the caudal extent of the curvature. It is usually the segment just proximal to the stable vertebrae. The apical vertebrae have the greatest translation from the midline for each curve. The magnitude of translation and rotation of each apical vertebra are noted. As each of the clinical categories of coronal imbalance are discussed, the role of these radiographic findings in the surgical decision-making process will be described.

♦ Coronal Balance in Adolescent Idiopathic Scoliosis

In a subset of adolescent idiopathic scoliosis patients with thoracic and lumbar double curves, the thoracic curve is the primary deformity whereas the lumbar curve is merely compensatory. For this type of curve (previously classified as King-Moe II, now known as Lenke 1B and Lenke 1C; **Fig. 8–4**), King and Moe found that arthrodesis of only the thoracic curve with Harrington distraction instrumentation resulted in excellent outcome.[3] Postoperatively, the nonfused compensatory lumbar curve spontaneously corrected itself to balance the remaining fused thoracic curve. This accomplished the primary goal of a balanced spine with the fusion mass centered over the pelvis while minimizing the number of lumbar levels needed to be fused. King and Moe remarked that the caudal extent of fusion should include the stable and rotationally neutral vertebrae to ensure the achievement of a balanced stable spine.[3,4]

In the late 1980s, modern segmental instrumentation was introduced. This brought an initial wave of excitement because of the ability of the newer instrumentation systems to exert powerful derotational and translational corrective forces. However, when King and Moe's principles of selective thoracic fusion were applied to these curves using modern segmental instrumentation, postoperative coronal decompensation resulted in as many as 20% of patients.[5] Since the

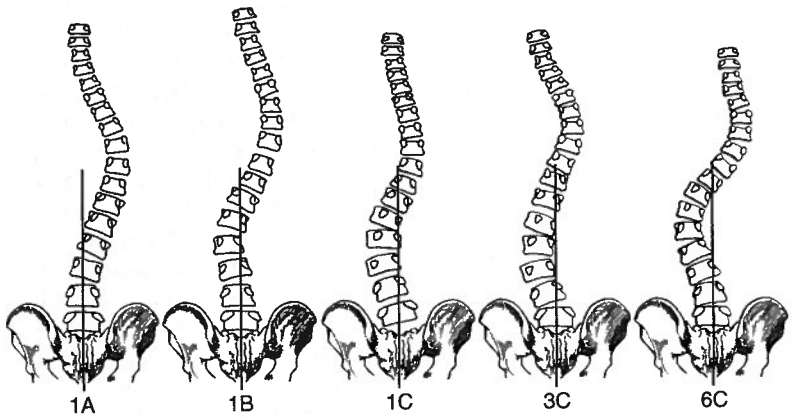

Figure 8–4 To avoid postoperative coronal imbalance in thoracic and lumbar double curves, it is first critical to correctly identify the curve patterns suitable for selective thoracic fusion. A thoracic and lumbar double-curve pattern may be classified as either Lenke Type 1, 3, or 6 curves.

emergence of this problem, several factors have been cited as causative, including incorrect identification of curve patterns, lumbar curve magnitude or stiffness, relative position and rotation of the apical vertebrae, use of "derotational" maneuvers, overcorrection of the thoracic curve, and choice of fusion levels. Various authors have made conflicting recommendations regarding the proper management of these curve patterns.

To avoid postoperative coronal imbalance in thoracic and lumbar double curves, it is first critical to correctly identify the curve patterns suitable for selective thoracic fusion. A thoracic and lumbar double-curve pattern may be classified as either Lenke Types 1, 3, or 6 **(Fig. 8–4)**. Lenke Type 6 curves are thoracic and lumbar double curves where the lumbar curve is the major curve (i.e., having the largest Cobb angle measurement). Lenke Type 6 curves should not be considered for selective thoracic fusion. In Lenke Type 1 and Type 3 curves, the thoracic curve is the major curve. Lenke Type 1A curves (formerly classified as King-Moe III) are thoracic-only curves where the lumbar vertebrae do not cross the midline and the CSVL falls between the lumbar pedicles up to the stable vertebrae. Lenke Type 1A curves are readily recognized and can undergo selective thoracic fusion with no problems of postoperative coronal imbalance. Lenke Types 3A and 3B are extremely uncommon and will not be considered here.[6] Therefore, in all practicality, when faced with a major thoracic and minor lumbar double curve, we are left to consider categorizing the curve as either Lenke Type 1B, 1C, or 3C.

Lenke Types 1B and 1C are the so-called false double-major curves where the thoracic curve is structural and the lumbar curve is only compensatory. Lenke Type 3C curves, on the other hand, are the so-called true double-major curves where both the thoracic and lumbar curves are structural. To distinguish between Lenke Types 1B/1C and Lenke Type 3, side-bending films are required. If the lumbar curve has a persistent Cobb angle of >25 degrees on side-bending films and/or if there is >20 degrees of kyphosis from T10 to L2, the lumbar curve is considered structural. The presence of a structural lumbar curve distinguishes a Lenke 3C from a Lenke 1B/1C. Lenke Types 1B/1C are amenable to selective thoracic fusion, and fusion of both the thoracic and lumbar curves should be strongly considered in Lenke Type 3C. Lenke Types 1B and 1C can be distinguished from each other by the lumbar modifier. In lumbar modifier B, the CSVL falls between the concave pedicle and the lateral margin of the lumbar apical vertebral body, whereas in lumbar modifier C, the CSVL falls medial to the lateral margin of the lumbar apical vertebral body. Both Lenke Types 1B and 1C are amenable to successfully balanced selective thoracic fusion.

After identification of the curve type as Lenke 1B or 1C, the specific characteristics of the curves should be determined to assess the risk of postoperative coronal decompensation after selective thoracic fusion. On the coronal standing radiograph, the magnitudes of the thoracic and lumbar curves, the rotation of the thoracic and lumbar curves using Nash-Moe criteria, and the translational distance of the apices of the curves from the plumbline (thoracic curve) and the CSVL (lumbar curve) can be measured. If the ratio of the thoracic to lumbar curve magnitude is >1.2, the ratio of the thoracic to lumbar apical vertebral rotation is >1.0, and the ratio of the thoracic to lumbar apical vertebral translation is >1.2, selective thoracic fusion can be performed successfully. If any or all of these ratios are less than 1, both the thoracic and lumbar curves should be instrumented. In Lenke and Bridwell's report that defined these guidelines,[7] there was a 50% incidence of postoperative coronal imbalance when these criteria were not met. In contrast, there was no postoperative coronal decompensation when these guidelines were followed.

Once the proper curve has met the strict criteria for selective thoracic fusion, it is critical to apply appropriate instrumentation principles intraoperatively. In posterior selective thoracic fusion, it is safest to fuse to the stable vertebrae. King and Moe's classic criteria of fusing to the neutral and stable vertebrae have been shown to still be valid with use of modern instrumentation.[8] Compressing between the stable and neutral vertebrae with a claw configuration on the concave correcting rod may help avoid coronal decompensation.[9] "Derotation" maneuvers should be avoided. Thompson et al.,[10] using pre- and postoperative CT for rotation assessment, found that derotation of the thoracic curve transmitted the rotational forces into the lumbar curve, potentially reducing the lumbar curve's ability to spontaneously correct. The use of pure translational maneuvers, instead of rotation, has been shown to prevent postoperative coronal imbalance.[11]

In posterior selective thoracic fusion, it is important to avoid overcorrecting the thoracic curve beyond the flexibility of the lumbar curve. Historically, the maximal thoracic correction that could be obtained with use of Harrington instrumentation was only moderate. This was serendipitous because the moderate amount of thoracic correction could be compensated by the flexibility of the unfused lumbar curve. When powerful modern third-generation instrumentation was used, however, the greater correction of the thoracic curve exceeded the "spontaneous correctability" of the lumbar curve that was necessary to maintain balance. Therefore, with use of modern instrumentation, the amount of intraoperative thoracic correction should be limited. Dobbs et al. have developed guidelines to help determine how much to correct the thoracic curve to optimize long-term coronal balance.[12] They found that spontaneous lumbar curve correction and excellent long-term balance was achieved when the thoracic correction was limited to mimic the Cobb measurement on the preoperative push-prone film.

Selective thoracic fusion may also be performed by an anterior approach. The anterior approach has several advantages over the standard posterior approach. In the anterior approach, fusion is carried to the end vertebrae of the Cobb measurement of the thoracic curve. Thus, in comparison, in the posterior approach where fusion is ended at the stable vertebrae, one or two caudal levels can be saved. This can often spare the lumbar spine from fusion entirely. In addition, postoperative coronal imbalance has not been a problem with the anterior approach. This may be related to the fact that the corrective forces used in the anterior approach involve convex compression forces instead of the concave distractive forces used in the posterior approach. Convex compression theoretically lifts up the lower thoracic spine, pulling up the concavity of the lumbar curve, and translating it to the midline. This mechanism of curve correction also allows the surgeon to attempt maximal thoracic correction without worry of postoperative decompensation.[13]

In a retrospective review comparing 70 anterior and 53 posterior selective thoracic fusions (Lenke Types 1A, 1B,

and 1C curves), anterior instrumentation yielded greater thoracic curve correction (58% vs. 38%) and greater spontaneous lumbar curve correction (56% vs. 37%) Posterior thoracic correction was intentionally limited, however, to avoid decompensation. In the anterior group, there was one postoperative coronal decompensation attributed to fusing one level short of the end Cobb vertebra. In the posterior group, there were three cases of mild to moderate decompensation that did not require further surgical intervention.[13] When choosing between anterior or posterior selective thoracic fusion, the aforementioned advantages of the anterior approach must be weighed against the potential for vascular injury, pulmonary compromise, and kyphogenic properties of the anterior approach.[14]

Careful preoperative planning is the key to avoiding postoperative coronal imbalance in selective thoracic fusion of Lenke 1B/1C major thoracic compensatory lumbar curves. Once coronal imbalance has occurred, however, treatment is difficult and may require extension of fusion. If the imbalance is mild and asymptomatic, no treatment other than monitoring for progression may be needed. If the imbalance is more severe or progressive, then bracing of the lumbar component may be attempted. If bracing fails, then extension of fusion to include lumbar curve and the distal stable vertebra may be necessary. Alternatively, if the coronal imbalance is recognized prior to the consolidation of fusion, the instrumentation can be adjusted to reduce the thoracic correction. All the instrumentation between the thoracic curve end vertebrae can be removed to allow the thoracic spine to return to some of its original deformity and restore coronal balance.[15]

♦ Coronal Balance in Adult Idiopathic Scoliosis

With increasing age, disk degeneration, facet arthrosis, stabilizing osteophytes, and dehydration of the soft tissue supportive structures lead to loss of flexibility of the spine. Because of the increased stiffness of the aging spine, preoperative and postoperative coronal and sagittal plane imbalance is more problematic in adults than in adolescents.[16]

Postoperative imbalance in adult scoliosis is most commonly related to improper selection of fusion levels. The stable and neutral vertebra should be included in the caudal and cephalad extents of the fusion, just as in adolescent idiopathic scoliosis. If instrumentation is stopped proximal to the neutral and/or stable vertebrae, or if significant tilt (>15 degrees) of the end vertebra remains, progressive decompensation and deformity caudal to the fusion may occur. Other causes of postoperative coronal imbalance in adult scoliosis include failure to fuse all structural curves, overcorrection of the thoracic curve beyond the flexibility of the lumbar curve, and failure to address a large fractional lumbosacral curve. The surgeon must also pay special attention to pelvic obliquity and leg-length discrepancy and their effects on coronal balance.[17]

In addition to paying special attention to the achievement of coronal balance, several other key principles should be kept in mind when treating adult scoliosis. To decide between posterior only and combined anterior-posterior approaches, consider curve magnitude, curve flexibility, and balance. Patients with lumbar curves are more likely to benefit from anterior surgery with structural grafting than those with thoracic curves. Patients with kyphotic segments are more likely to benefit from anterior release or strut grafting than those with lordotic segments. In the sagittal plane, fusion should extend into areas of lordosis to avoid junctional kyphosis. Fusions may also need to be extended distally to treat degenerated painful segments that otherwise would not be included for deformity correction. Patients with severe imbalance and stiff large curves may benefit from more aggressive procedures such as osteotomies or spinal shortening vertebral column resection procedures.[18,19]

Single Thoracic Curves (Lenke Type 1)

In adults, moderate balanced single thoracic curves less than 70 degrees are best managed with posterior spinal fusion and instrumentation. Curves greater than 70 degrees, however, may present with coronal and sagittal imbalance. In this group of patients, a combined anterior release with posterior instrumentation and fusion will likely produce better curve correction and achievement of balance. For more severe curves greater than 90 degrees with significant coronal imbalance (> 4 to 5 cm), more drastic measures in form of multiple osteotomies or spinal shortening procedures such as a vertebral column resection may be necessary.[20]

Thoracolumbar and Lumbar Curves (Lenke Type 5)

Flexible mild to moderate thoracolumbar and lumbar curves (less than 50 degrees) in a relatively young patient are best treated with anterior correction, fusion, and anterior segmental instrumentation.[21] The advantages of the anterior-only approach include less blood loss, improved correction, fewer levels of fusion, and a lower nonunion rate. During preoperative planning, attention must be directed at the lumbosacral junction to look for a fixed fractional curve. The correction of the thoracolumbar or lumbar curve can lead to an iatrogenic coronal imbalance in the presence of a significant nonflexible fractional curve (> ~15 degrees).

A posterior-only or combined anterior-posterior approach is indicated in thoracolumbar/lumbar curves that require decompression for stenosis or radiculopathy. A combined anterior-posterior approach is indicated in patients with rigid unbalanced deformities (> ~50 degrees, > ~2 cm imbalance). Anterior column support, in the form of structural femoral ring allografts packed with cancellous autograft, can be useful in the lower lumbar and lumbosacral spine to restore lordosis and protect the posterior construct until fusion occurs.[20]

Double Thoracic and Lumbar Curves (Lenke Types 3 and 6)

Balanced curves less than 60 degrees in the thoracic and lumbar areas can be treated with posterior-only fusion and instrumentation. In more severe curves associated with coronal or sagittal imbalance, a combined anterior-posterior approach is necessary. Anterior release and arthrodesis of the lower thoracic and lumbar spine is followed by posterior instrumentation and fusion.[20]

Lumbosacral Fractional Curves

If possible, fusion to the sacrum is avoided in adult scoliosis to preserve the last motion segment. However, to achieve coronal balance in the presence of a significant lumbosacral fractional curve with lumbar scoliosis, fusion to the sacrum is indicated. The significance of the fractional curve can be determined by its magnitude (>15 degrees) and flexibility (achieving balance on bending films, ability of the disk to open both ways on bending films).

Fusion should also extend to the sacrum when there is low back pain secondary to L5-S1 degenerative disk disease that is confirmed by MRI and/or diskography. Fusion to the sacrum can be avoided if the L5-S1 disk height is maintained, the L5 vertebrae is seated low in the pelvis, there is no stenosis at that segment, there is no posterior column deficiency, and, most importantly, the spine can be balanced without fusion to the sacrum.[22]

Successful arthrodesis to the sacrum requires a combined anterior-posterior approach to maximize fusion rate, restore lordosis, and prevent implant failure. Anterior structural allografts at L4-L5 and L5-S1 can be shaped in a trapezoidal fashion to provide optimal correction of coronal plane deformity as well as restore lordosis. Pedicle screw fixation alone into the sacrum is acceptable in short fusions of three- or four-level degenerative curves. However, high failure rates have been reported with longer constructs due to the long lever arm and excessive forces concentrated at the lumbosacral junction. In this situation, four-point fixation into the sacrum and pelvis is necessary (sacral pedicle screws and either iliac screws or rods).[17,20]

♦ Coronal Balance in de Novo Degenerative Scoliosis

Patients with de novo degenerative scoliosis present with radicular and stenosis symptoms related to neural compression from rotatory subluxation and facet hypertrophy. The characteristic radiographic findings are lateral tilt at L4-L5 and rotatory subluxation at L3-L4 **(Fig. 8–5)**. An upper and lower lumbar curve often coexist. A subset of patients have coronal and/or sagittal imbalance. The characteristic sagittal plane deformity is loss of lumbar lordosis.[23]

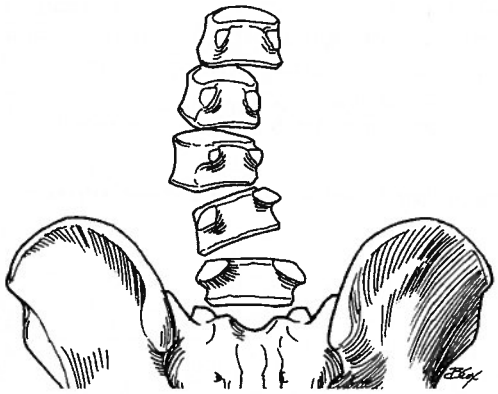

Figure 8–5 The characteristic radiographic findings of degenerative scoliosis are lateral tilt at L4-L5 and rotatory subluxation at L3-L4.

Treatment of degenerative scoliosis is based on patient symptoms, curve magnitude, curve flexibility, degree of instability, and presence of coronal or sagittal imbalance. Conservative therapy is reserved for small curves with no imbalance, no instability, and mild symptoms of neurogenic claudication. Decompression alone may suffice if the stenosis symptoms are severe but there is minimal deformity and no rotatory subluxation. Decompression with posterior fusion and instrumentation is used to treat moderate curves (>35 degrees) with severe symptoms, subluxation 0 to 5 mm, minimal imbalance (<2 cm), and moderate flexibility. In performing posterior fusion in this patient population, a lordosing table should be used to avoid exacerbation of the associated sagittal flat back.[19,24]

Decompression with combined anterior-posterior fusion and posterior instrumentation is necessary in severe stenosis due to large rigid curves with imbalance and subluxation >5 mm. Vertebral column resection may be needed in stiff severe unbalanced deformities where one vertebra (usually L2 or L3) is completely subluxated out from the levels above and below.[19,24]

In keeping with the general principles of deformity surgery, fusions in degenerative scoliosis should also begin and end with the neutral and stable vertebrae. Fusion should not end next to a level with a rotatory subluxation. It is usually not possible to end the fusion at L3 or L4 due to their involvement in the pathologic process. The fusion may be stopped at L5 if there is a normal L5-S1 disk on MRI, normal sagittal balance, no substantial listhesis or fractional curve at L5-S1, and good evidence of a hyperstable L5-S1 segment (L5-S1 disk buried below the intercristal line, large transverse processes, or partial sacralization of L5).[19,25]

In addressing the sagittal plane deformity in degenerative scoliosis, lumbar lordosis cannot be created simply by shortening the posterior column. Because posterior column shortening leads to a decrease in foraminal size and subsequent worsening of stenosis symptoms, anterior structural support is often used in this patient population. The anterior strut grafts reduce rotatory subluxation and lordose the spine via a ligamentotaxis effect and increase foraminal cross-sectional diameter. Structural allografts in the anterior column are loaded in compression and incorporate well into the adjacent vertebral bodies.[19,26]

♦ Coronal Balance in Congenital Scoliosis

In patients with congenital scoliosis, coronal imbalance is often more problematic than the magnitude of the curvatures themselves. In addition to the intrinsic deforming characteristics of the various anomalies, the location of the anomaly plays a key role in determining whether the spine can balance itself. A hemivertebra in the thoracic spine may elicit compensatory curves above and below it, allowing the spinal axis to remain well balanced. However, the same hemivertebra at the lumbosacral junction may cause severe coronal imbalance and subsequently lead to a large structural compensatory thoracolumbar curve and pelvic obliquity.

To treat congenital scoliosis effectively, the relative potentials for deformity progression of the various congenital defects

should be considered. Surgery is indicated in curves with proved progression or in curves with characteristic anomalies known to inevitably progress (e.g., unilateral unsegmented bar with a contralateral hemivertebra). The goals of surgery are to arrest the progression of the congenital curve and also to avoid worsening of the compensatory curves and associated imbalance.

Posterior spinal fusion is sufficient treatment for many congenital curves. The entire curve should be fused. Additional anterior fusion may be beneficial to prevent crankshaft phenomenon. However, the risk of cord ischemia from an anterior approach is higher in patients with congenital scoliosis. The addition of instrumentation only modestly increases correction, may not increase fusion rates, and increases the risk of neurologic injury.

Significant progressive unbalanced curves caused by a hemivertebra are best treated by hemivertebra excision, especially if the hemivertebra is located in the lumbosacral spine. A lumbosacral hemivertebra provides the strongest indication for excision because it has the strongest negative impact on spinal balance, and it is the safest level to excise. In the presence of spinal imbalance, in-situ fusion or unilateral convex posterior in-situ fusion is inappropriate because it creates no potential for spontaneous correction over time, may not control the deformity, and may increase the risk of pseudarthrosis. Hemivertebra excision may be performed by sequential anterior-posterior, simultaneous anterior-posterior, or posterior-only approaches. In a posterior-only approach, the hemivertebra's posterior elements are first resected. The spinal cord or dural sac is usually deviated to the concave side of the curve, allowing exposure of the body. The vertebral disks above and below the hemivertebra and the vertebral body of the hemivertebra are curetted out, and a compression device then is applied to the convex side of the curve.[27] Although hemivertebra excision carries higher risk of blood loss and neurologic injury than other procedures, it is necessary in situations where other less-invasive procedures cannot achieve adequate balance[28–33] **(Fig. 8–6)**.

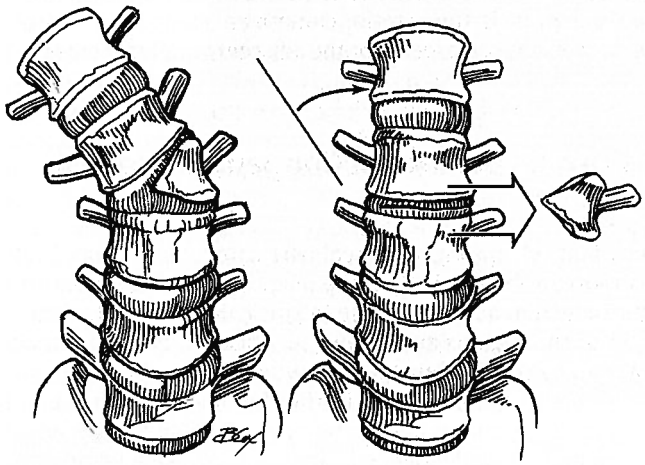

Figure 8–6 In a posterior-only hemivertebra excision, the hemivertebra's posterior elements are first resected. The spinal cord or dural sac is usually deviated to the concave side of the curve, allowing exposure of the body. The vertebral disks above and below the hemivertebra and the vertebral body of the hemivertebra are curetted out, and a compression device then is applied to the convex side of the curve

♦ Coronal Balance in Complex Severe Multiplanar Deformities

Rigid complex unbalanced spinal deformities are most commonly caused by iatrogenic post-scoliosis fusions and congenital scoliosis (before and after fusion). Coronal and sagittal imbalance often coexists. Patients with isolated sagittal plane rigid deformities (as seen in ankylosing spondylitis or iatrogenic flat-back syndrome) can be treated effectively with posterior osteotomies such as the Smith-Petersen osteotomies or the pedicle subtraction/decancellation osteotomies.[34,35] However, a more aggressive approach with multiple vertebral osteotomies or spinal shortening procedures is often necessary in rigid multiplanar deformities.

Posterior Vertebral Osteotomies

Posterior column Smith-Petersen osteotomies alone are unlikely to be successful in correcting the coronal component of complex multiplanar deformities. However, three-column pedicle subtraction osteotomies can be performed with asymmetric resection of the vertebral body and cortex to achieve simultaneous sagittal and coronal correction. More bone is resected in the convexity than the concavity of the curve to correct the coronal component **(Fig. 8–7)**. The posterior osteotomies have the advantage of sparing the patient a sequential anterior-posterior approach. However, these biplanar osteotomies are extremely technically challenging.

Anterior/Posterior Vertebral Osteotomies

Rigid biplanar deformities can be successfully corrected by single or multilevel anterior/posterior wedge osteotomies.[36] The anterior portion of the diskectomy/osteotomy is approached from the convex side. The foramen and disk spaces are localized and a convex-based wedge of osteocartilaginous tissue is resected. Using the foramen as a guide, the remaining bone and posterior vertebral cortex is removed. Posteriorly, pedicle screws are placed prior to the osteotomies. The exposed tips of the transverse processes are used as landmarks above which convex-based wedge osteotomies are performed. The edges of the osteotomy site are undercut in the midline and laterally in the foraminal region to prevent neural impingement during the osteotomy closure. Correction is obtained by segmental instrumentation using translational and cantilever maneuvers. Multiple levels of osteotomies can be performed as dictated by the deformity. Multilevel osteotomies can be advantageous because less correction is needed at each level, they may reduce focal areas of compression/distraction, and they may restore a more physiologic curvature across multiple vertebral segments.[37]

Vertebral Column Resection

In a select group of patients with rigid, severely imbalanced coronal or multiplanar deformity, adequate balance of the spinal axis cannot be achieved even with multiple anterior/posterior osteotomies. This group is usually composed of neglected fixed congenital disorders, neuromuscular deformities, and

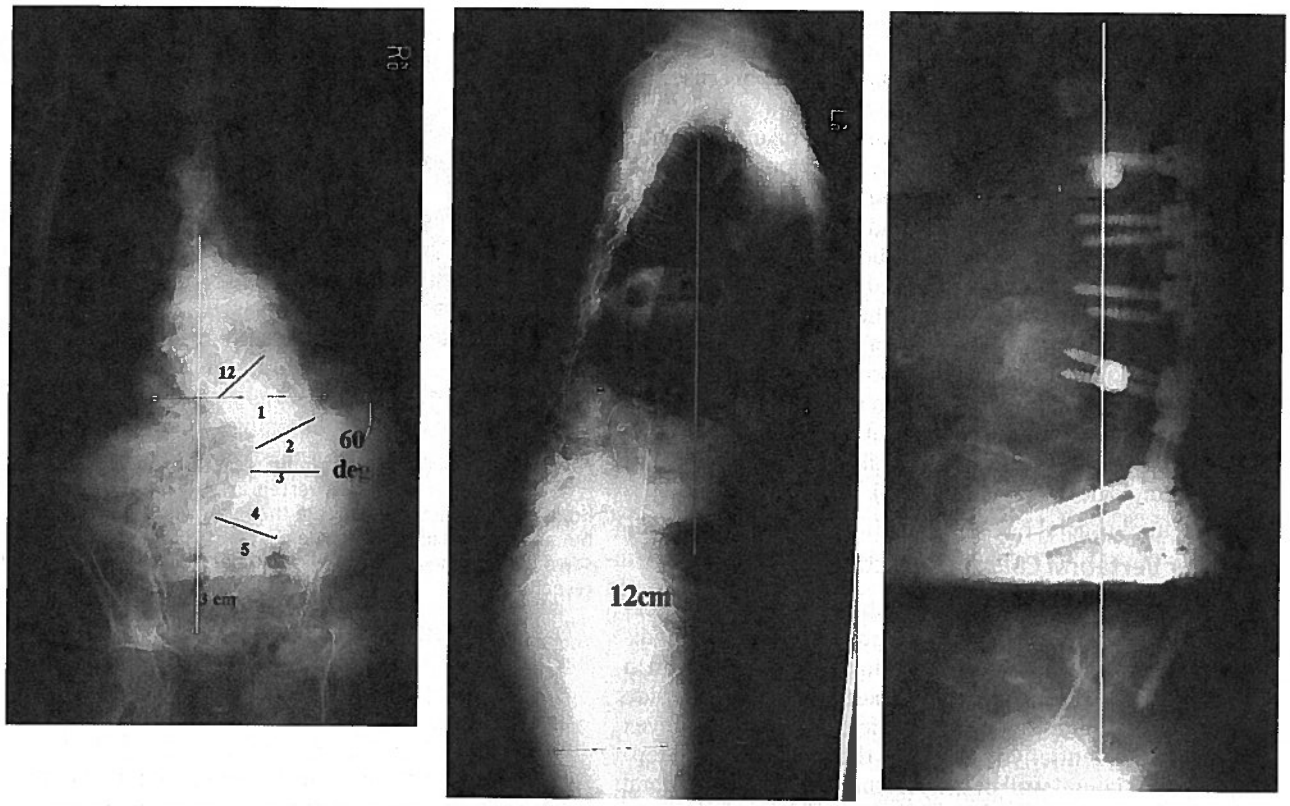

A–C

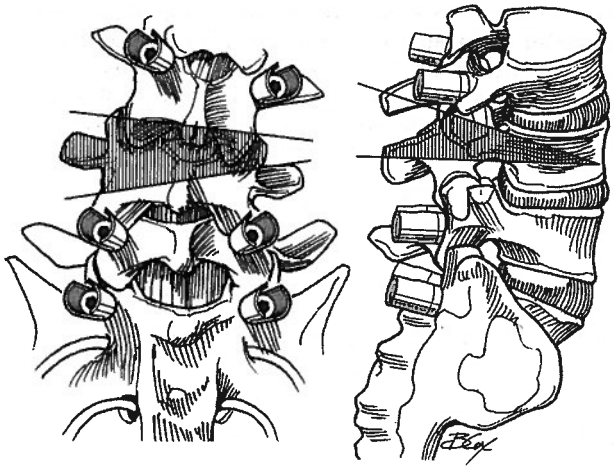

D

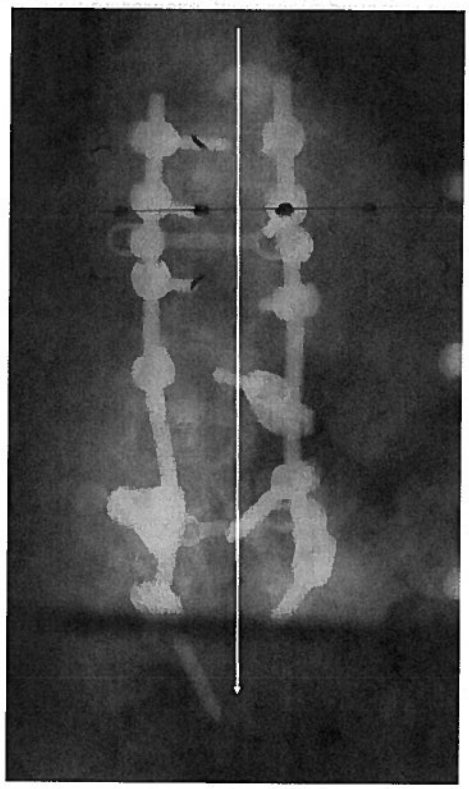

E

Figure 8–7 A biplanar pedicle subtraction osteotomy can be performed at one or more levels to obtain coronal and sagittal balance simultaneously. This procedure is technically demanding but can spare an anterior posterior sequential approach. In this clinical example, a 67-year-old woman who underwent in-situ fusion for scoliosis as a teenager presents with pseudarthrosis and increasing deformity. **(A, B)** Illustration of a 60-degree lumbar curve with 3 cm of coronal imbalance to the left and 12 cm of sagittal imbalance. A biplanar pedicle subtraction osteotomy **(D)** was performed at the apex, resulting in satisfactory coronal and sagittal balance **(C, E).**

patients who were fused at a very young age and developed pseudarthroses or a crankshaft deformity. In these deformities, osteotomies alone cannot achieve balance safely because the distraction forces necessary to achieve correction would likely lead to neurologic injury. For these severe multiplanar deformities, a spinal shortening vertebral body resection procedure is preferable. For the anterior stage of the procedure, the convex side of the deformity is approached and an osteoperiosteal flap is developed over the apical vertebral body. The vertebral body and adjacent pedicles are then removed piecemeal. Morcelized bone is then placed in the defect, and the osteoperiosteal flap is sewn over it. The posterior elements of the apical vertebra are then resected. Rib resections are performed on the convex side as needed. Segmental instrumentation is then placed and corrective maneuvers are performed with intraoperative radiographs to judge balance. Multiple wake-up tests are used to monitor neurologic status[38,39] (**Fig. 8–8**).

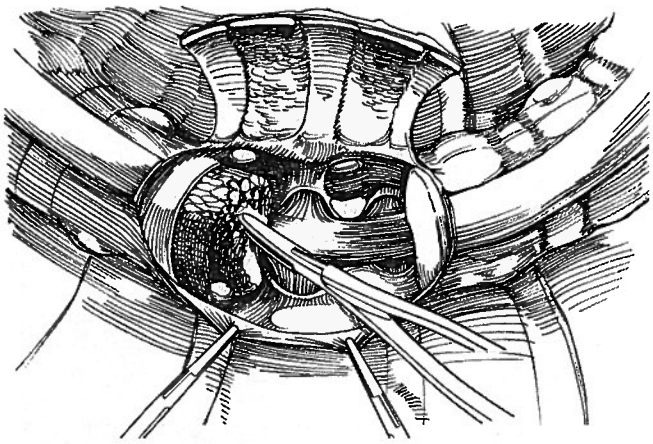

Figure 8–8 In a vertebral column resection, an osteoperiosteal flap is developed over the apical vertebral body anteriorly. The vertebral body, and adjacent pedicles are then removed piecemeal. Morcelized bone is then placed in the defect, and the osteoperiosteal flap is sewn over it. The posterior elements of the apical vertebra are then resected.

Posterior Vertebral Column Resection

Vertebral column resection may also be performed by a posterior-only approach.[40,41] Through a posterior incision, pedicle screw fixation is first placed. Prior to bony resection, a rod contoured to the deformity is fixed to the concave side to stabilize the spine. The posterior elements and the convex pedicle are sequentially resected as the dissection is deepened over the lateral wall of the vertebral body. The vertebral body and disks are then removed piecemeal, progressing medially. The posterior vertebral body cortex is then taken through the vertebral body defect. Once adequate resection is completed on the working side, the stabilizing rod is switched to the working side and the procedure is repeated on the contralateral side. Deformity correction is then performed by replacing the stabilizing rods with precontoured rods. Intraoperative radiographs and wake-up tests are used to monitor correction and neurologic status, respectively.

♦ Conclusion

Correction and preservation of truncal balance is a critical factor in the surgical treatment of spinal deformities. Coronal plane deformities should not be evaluated or treated in isolation but in the context of the accompanying sagittal and axial plane deformities. The amount of correction obtained should be secondary to the achievement of coronal and sagittal balance.

In major thoracic-compensatory lumbar adolescent idiopathic scoliosis, careful curve identification, application of proper instrumentation principles, and avoidance of overcorrection can avert postoperative coronal decompensation after selective thoracic fusion. In adult idiopathic and degenerative scoliosis, the presence of significant coronal or sagittal imbalance necessitates a combined anterior-posterior approach. A rigid lumbosacral fractional curve must also be addressed. In congenital scoliosis, hemivertebrae at the lumbosacral junction have the greatest potential to cause imbalance and can be treated by excision. Rigid complex multiplanar deformities often require technically difficult osteotomies or spinal shortening vertebral column resections to achieve satisfactory spinal balance.

References

1. Kuklo TR, Lenke LG, Graham EJ, et al. Correlation of radiographic, clinical, and patient assessment of shoulder balance following fusion versus nonfusion of the proximal thoracic curve in adolescent idiopathic scoliosis. Spine 2002;27:2013–2020
2. Vedantam R, Lenke LG, Bridwell KH, Linville DL. Comparison of push-prone and lateral-bending radiographs for predicting postoperative coronal alignment in thoracolumbar and lumbar scoliotic curves. Spine 2000;25:76–81
3. King HA, Moe JH, Bradford DS, Winter RB. The selection of fusion levels in thoracic idiopathic scoliosis. J Bone Joint Surg Am 1983;65:1302–1313
4. Moe JH. Methods of correction and surgical techniques in scoliosis. Orthop Clin North Am 1972;3:17–48
5. Bridwell KH, McAllister JW, Betz RR, Huss G, Clancy M, Schoenecker PL. Coronal decompensation produced by Cotrel-Dubousset "derotation" maneuver for idiopathic right thoracic scoliosis. Spine 1991;16:769–777
6. Lenke LG, Betz RR, Harms J, et al. Adolescent idiopathic scoliosis: a new classification to determine extent of spinal arthrodesis. J Bone Joint Surg Am 2001;83-A:1169–1181
7. Lenke LG, Bridwell KH, Baldus C, Blanke K. Preventing decompensation in King type II curves treated with Cotrel-Dubousset instrumentation. Strict guidelines for selective thoracic fusion. Spine 1992;17:S274–S281
8. McCance SE, Denis F, Lonstein JE, Winter RB. Coronal and sagittal balance in surgically treated adolescent idiopathic scoliosis with the King II curve pattern. A review of 67 consecutive cases having selective thoracic arthrodesis. Spine 1998;23:2063–2073
9. Shufflebarger HL, Clark CE. Fusion levels and hook patterns in thoracic scoliosis with Cotrel-Dubousset instrumentation. Spine 1990;15:916–920
10. Thompson JP, Transfeldt EE, Bradford DS, Ogilvie JW, Boachie-Adjei O. Decompensation after Cotrel-Dubousset instrumentation of idiopathic scoliosis. Spine 1990;15:927–931
11. Goshi K, Boachie-Adjei O, Moore C, Nishiyama M. Thoracic scoliosis fusion in adolescent and adult idiopathic scoliosis using posterior translational corrective techniques (Isola): is maximum correction of the thoracic curve detrimental to the unfused lumbar curve? Spine J 2004;4:192–201
12. Dobbs MB, Lenke LG, Walton T, et al. Can we predict the ultimate lumbar curve in adolescent idiopathic scoliosis patients undergoing a selective fusion with undercorrection of the thoracic curve? Spine 2004;29:277–285
13. Lenke LG, Betz RR, Bridwell KH, Harms J, Clements DH, Lowe TG. Spontaneous lumbar curve coronal correction after selective anterior or posterior thoracic fusion in adolescent idiopathic scoliosis. Spine 1999;24:1663–1671; discussion 1672
14. Rhee JM, Bridwell KH, Won DS, Lenke LG, Chotigavanichaya C, Hanson DS. Sagittal plane analysis of adolescent idiopathic scoliosis: the effect of anterior versus posterior instrumentation. Spine 2002;27:2350–2356
15. Arlet V, Marchesi D, Papin P, Aebi M. Decompensation following scoliosis surgery: treatment by decreasing the correction of the main thoracic curve or "letting the spine go." Eur Spine J 2000;9:156–160
16. Balderston RA. Adult thoracic scoliosis. In: Bridwell KH, DeWald RL, eds. The Textbook of Spinal Surgery. Vol. 1. Philadelphia: Lippincott; 1997: chap. 46
17. Lonner BS, Boachie-Adjei O. Adult scoliosis. In: Craig EV, ed. Clinical Orthopaedics. Philadelphia: Lippincott Williams & Wilkins; 1999:379–392
18. Bridwell KH. Selection of instrumentation and fusion levels for scoliosis: where to start and where to stop. Invited submission from the Joint Section Meeting on Disorders of the Spine and Peripheral Nerves, March 2004. J Neurosurg Spine 2004;1:1–8
19. Bridwell KH. Adult deformity: scoliosis and sagittal plane deformities. In: Vaccaro AR, Betz RR, Zeidman SM, eds. Principles and Practice of Spine Surgery. Philadelphia: Mosby; 2003:539–547
20. Bradford DS, Tay BK, Hu SS. Adult scoliosis: surgical indications, operative management, complications, and outcomes. Spine 1999;24:2617–2629
21. Smith JA, Deviren V, Berven S, Bradford DS. Does instrumented anterior scoliosis surgery lead to kyphosis, pseudarthrosis, or inadequate correction in adults? Spine 2002;27:529–534
22. Brown KM, Ludwig SC, Gelb DE. Radiographic predictors of outcome after long fusion to L5 in adult scoliosis. J Spinal Disord Tech 2004;17:358–366
23. Daffner SD, Vaccaro AR. Adult degenerative lumbar scoliosis. Am J Orthop 2003;32:77–82; discussion 82
24. Gupta MC. Degenerative scoliosis. Options for surgical management. Orthop Clin North Am 2003;34:269–279
25. Bridwell KH. Where to stop the fusion distally in adult scoliosis: L4, L5, or the sacrum? Instr Course Lect 1996;45:101–107
26. Molinari RW, Bridwell KH, Klepps SJ, Baldus C. Minimum 5-year follow-up of anterior column structural allografts in the thoracic and lumbar spine. Spine 1999;24:967–972
27. Nakamura H, Matsuda H, Konishi S, Yamano Y. Single-stage excision of hemivertebrae via the posterior approach alone for congenital spine deformity: follow-up period longer than ten years. Spine 2002;27:110–115
28. Deviren V, Berven S, Smith JA, Emami A, Hu SS, Bradford DS. Excision of hemivertebrae in the management of congenital scoliosis involving the thoracic and thoracolumbar spine. J Bone Joint Surg Br 2001;83:496–500
29. Bradford DS, Boachie-Adjei O. One-stage anterior and posterior hemivertebral resection and arthrodesis for congenital scoliosis. J Bone Joint Surg Am 1990;72:536–540
30. Lazar RD, Hall JE. Simultaneous anterior and posterior hemivertebra excision. Clin Orthop Relat Res 1999;364:76–84
31. Holte DC, Winter RB, Lonstein JE, Denis F. Excision of hemivertebrae and wedge resection in the treatment of congenital scoliosis. J Bone Joint Surg Am 1995;77:159–171
32. Ruf M, Harms J. Posterior hemivertebra resection with transpedicular instrumentation: early correction in children aged 1 to 6 years. Spine 2003;28:2132–2138
33. Lubicky JP. Congenital scoliosis. In: Bridwell KH, DeWald RL, eds. The Textbook of Spinal Surgery. Vol. 1. Philadelphia: Lippincott; 1997: chap. 30
34. Bridwell KH, Lewis SJ, Rinella A, Lenke LG, Baldus C, Blanke K. Pedicle subtraction osteotomy for the treatment of fixed sagittal imbalance. Surgical technique. J Bone Joint Surg Am 2004;86-A(Suppl 1):44–50
35. Murrey DB, Brigham CD, Kiebzak GM, Finger F, Chewning SJ. Transpedicular decompression and pedicle subtraction osteotomy (eggshell procedure): a retrospective review of 59 patients. Spine 2002;27:2338–2345
36. Voos K, Boachie-Adjei O, Rawlins BA. Multiple vertebral osteotomies in the treatment of rigid adult spine deformities. Spine 2001;26:526–533
37. Potter BK, Lenke LG, Kuklo TR. Prevention and management of iatrogenic flatback deformity. J Bone Joint Surg Am 2004;86-A:1793–1808
38. Boachie-Adjei O, Bradford DS. Vertebral column resection and arthrodesis for complex spinal deformities. J Spinal Disord 1991;4:193–202
39. Bradford DS, Tribus CB. Vertebral column resection for the treatment of rigid coronal decompensation. Spine 1997;22:1590–1599
40. Suk SI, Kim JH, Kim WJ, Lee SM, Chung ER, Nah KH. Posterior vertebral column resection for severe spinal deformities. Spine 2002;27:2374–2382
41. Shimode M, Kojima T, Sowa K. Spinal wedge osteotomy by a single posterior approach for correction of severe and rigid kyphosis or kyphoscoliosis. Spine 2002;27:2260–2267

Chapter 9

Flexible versus Fixed Spinal Deformity

Sumon Bhattacharjee, Rod J. Oskouian Jr., and Christopher I. Shaffrey

Historically, Min Mehta wrote an "important decrease of scoliotic curve with supine position is a factor in the successful result for orthopedic treatment." The management of spinal deformity has gone through a significant evolution in the past decade. The goal of spinal deformity surgery remains to achieve a stable, well-balanced spine centered over the pelvis, fusing as few motion segments as possible. The balanced spine is created by a close interplay of the patient's spinal anatomy, the biomechanical properties of the spine and its surrounding structures, and the corrective capabilities of surgical techniques and instrumentation. A determination of whether the spinal deformity is fixed or flexible plays a crucial role in the surgical planning and the ultimate type of operative corrective procedure that is selected. Duval-Beaupere and associates assessed factors contributing to the flexibility of neuromuscular scoliosis,[1] and they demonstrated that flexibility included two very different and noncorrelated phenomena: the collapse and the reducibility of the structural curve. They differentiated whether the deformation is greatly reduced in magnitude or disappeared with gravity removed (i.e., a nonstructural curve) or whether the deformity persists and is fixed. They determined reducibility is an elasticity process whereas collapse is a more complex structural process that may predict evolution rate and the effectiveness of treatment. Although the study involved patients with neuromuscular scoliosis, reducibility and collapse are important factors that need to be considered in adult spinal deformity as well. Newer surgical techniques as well as advances in spinal instrumentation have markedly improved the ability to correct spinal deformity, particularly rigid deformity, and correction frequently involves the use of transpedicular instrumentation with or without an anterior release or osteotomy procedure. As the complexity of the surgical procedure increases, the risk for a complication markedly increases particularly in adult patients. To balance surgical benefits and risks, a detailed analysis of the coronal balance, sagittal balance, relative flexibility of all curves, and determination of whether fixed or fused deformity is present is fundamental to effectively treating deformity.

♦ Structural Characteristics of Pediatric and Adult Deformities

There are inherent differences between treating pediatric and adult spinal deformities. In general, adult deformities are more rigid, and there is less compensatory potential in areas adjacent to the deformity. The deformity found in idiopathic adolescent scoliosis (AIS) often will have areas where the deformity is more rigid than others. Determining the relative rigidity with an assessment of structural and nonstructural characteristics of the curve has been used recently as the framework for developing a comprehensive classification of AIS.[2,3] This classification assesses curve magnitude on side-bending radiographs and determines whether structural or nonstructural curves are present in the proximal thoracic, main thoracic, thoracolumbar, and lumbar spine. This system also assesses both the thoracic sagittal profile and a lumbar spine modifier. This classification has been proposed as a template to more accurately describe the true nature of a scoliotic deformity and can potentially serve as a guide to best surgical intervention.[4–6]

Frequently, adult spinal deformity involves abnormalities in both the coronal and sagittal planes. The magnitude of the coronal deformity has not been found to directly correlate with pain. Factors such as lateral vertebral olisthy, L3 and L4 end-plate obliquity angles, loss of lumbar lordosis, and thoracolumbar kyphosis and sagittal balance have been significantly correlated with pain.[7,8] In addition to correlation with symptoms, surgical outcome in adults correlates strongly with obtaining good coronal and sagittal balance. The correction strategy for inducing spinal balance in patients with rigid

deformity depends principally upon the structural characteristics of the curves and the bone quality.

♦ Fixed and Flexible Deformities

A global assessment of spinal deformity is required in all patients. The analysis begins with full-length scoliosis films to determine coronal and sagittal balance. This is complemented with additional radiographic studies including supine full-length radiographs, flexion, extension, and side-bending views, and the use of push-prone, traction, or bolster radiographs to assess flexibility. The specific indications for each of the supplemental radiographic studies will be discussed in more detail later in the chapter. Computed tomography (CT) or CT-myelogram is often needed for evaluation of congenital malformations of the spine or in cases of prior spinal instrumentation and fusion procedures (**Figs. 9–1A to 9–1C**). Magnetic resonance imaging (MRI) studies are indicated in any pediatric patient with any neurologic symptoms, rapid curve progression, atypical curve pattern, early onset scoliosis, congenital malformations, or painful scoliosis (**Figs. 9–2A and 9–2B**).

The determination of whether each sagittal and coronal component of a spinal deformity is fixed or flexible contributes significantly toward the surgical decision-making process. The extent of curve flexibility, whether segments are either congenitally or surgically fused, and the compensatory ability of adjacent segments of the spine all impact the choice of surgical approach, spinal levels fused, and the type of implant selected. The degree of flexibility will determine whether an isolated anterior procedure or posterior procedure will suffice or whether a circumferential approach is considered. A rigid and fixed deformity will also dictate

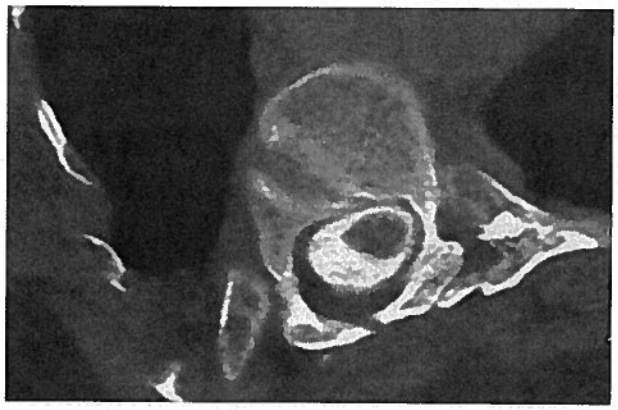

A

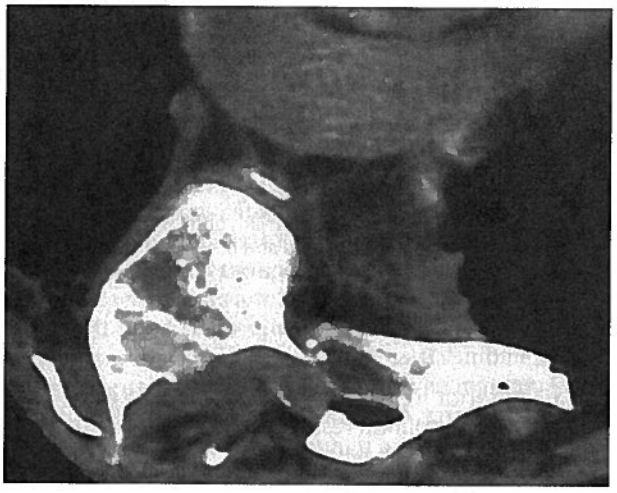

B

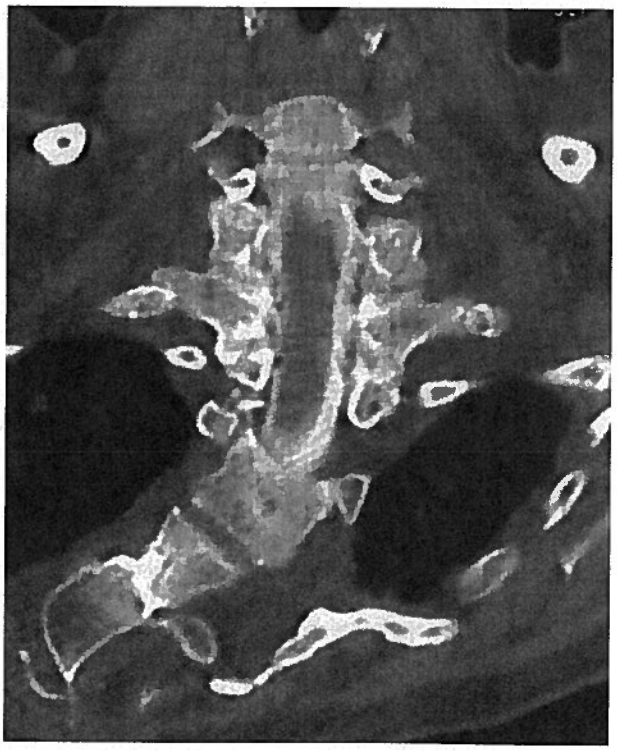

C

Figure 9–1 Computed tomography (CT) scans are invaluable especially in patients with congenital spinal deformities. **(A)** Axial CT of a patient with a complex kyphoscoliotic curve demonstrating the location of the spinal cord on the convexity of the curve with a congenitally small pedicle on one side. **(B)** Another axial CT at the apex of the deformity in a patient with absent pedicles and posterior elements who had severe neuromuscular scoliosis. **(C)** A coronal CT scan of a patient with a severe congenital kyphoscoliotic curve with evidence of fused ribs and a fairly rigid scoliosis.

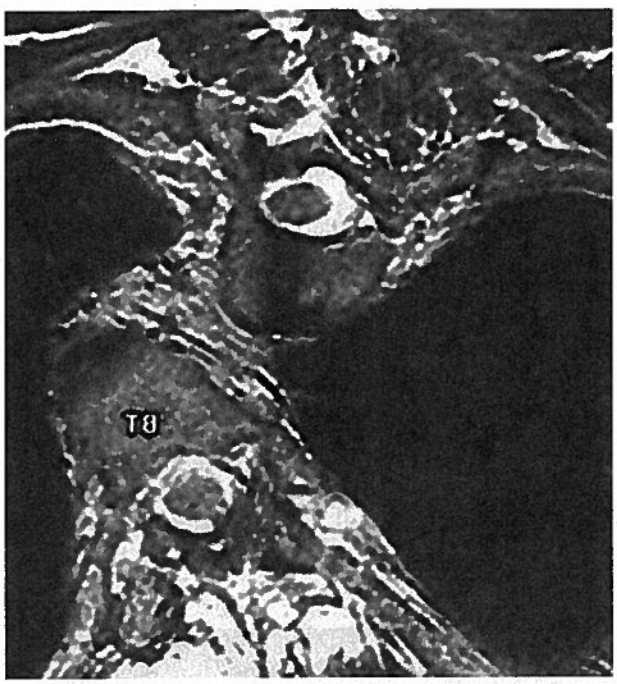

A

B

Figures 9–2 Magnetic resonance imaging (MRI) of the spine is valuable in assessing the location of the spinal cord and other pertinent soft tissue structures. **(A)** This patient had such a severe curve that the spinal cord is seen in one plane at two different levels of the spine. **(B)** In some cases the deformity is so severe that multiple planes must be evaluated prior to locating the spinal cord.

whether an anterior release and fusion, a posterior osteotomy, or vertebral column resection procedure is required to successfully achieve spinal balance.[9–20]

Inherent characteristics of each spinal deformity also should be considered while assessing its flexibility and its role in the overall management scheme.[2] Both curve flexibility and structural characteristics of the vertebrae included in the deformity are major determinant of the ability to achieve deformity correction with a traditional posterior only approach. For instance, an isolated 55-degree main thoracic adolescent idiopathic curve is usually flexible on side-bending films and has almost no secondary degenerative changes. It would be anticipated that following posterior segmental instrumentation an improvement to 25 degrees would be anticipated. Improvement in Cobb angle measurement using modern surgical correction could be expected to exceed 70% for this type of case. However, the treatment of an adult degenerative lumbar curve of similar magnitude would rarely achieve the same amount of correction. The flexibility in an adult curve is usually less as demonstrated by less improvement in curve magnitude on bending radiographs with more superimposed degenerative changes. As illustrated, the management plan for same initial curve magnitudes will be different based on the inherent characteristics of the curves.

Advancements in spinal instrumentation have also contributed toward significant evolution in the management of rigid spinal deformity. Many cases treated in the past with circumferential procedures can now be effectively treated with posterior instrumentation using pedicle screws. Pedicle screws engage all three columns of the spine and permit application of strong corrective forces. Several studies demonstrate both improved correction of spinal deformity with the use of pedicle screws compared with traditional techniques and better three-dimensional spinal realignment.[7,18,19,21,22]

♦ Radiologic Evaluation of the Spinal Deformity: Is It Fixed or Flexible?

The rigidity or the flexibility of the spinal deformity should be evaluated in all curves that are considered for surgical intervention. Certain techniques of radiographic evaluation have advantages over others depending on the curve characteristics and patient compliance. Traction films may be suitable for cooperative pediatric patients with large and prominent coronal curve or proximal thoracic curves.

The use of a bolster placed under the apex of the deformity to maximize postural correction is particularly useful in cases of kyphotic deformity in adolescent or adult patients. This technique permits a better assessment of curve flexibility than can be performed by the patient attempting correction by maximally extending the spine. Literature on radiographic assessment of curve flexibility principally discusses methods of evaluation used in assessing adolescent idiopathic scoliosis and

neuromuscular scoliosis. There is unfortunately little data critically comparing the effectiveness of radiographic methods of determining curve flexibility in the adult spinal deformity patient.

In all cases, the initial assessment involves upright full-length 36-in. × 14-in. scoliosis films with both posterior/anterior (PA) and lateral views. Because curve magnitudes may vary with the elimination of gravity in supine radiographs, these should be considered in adult scoliosis patients. To optimize visualization for the lateral radiograph, "clavicle position," where the patient fully flexes the elbows with the hands in a relaxed fist, wrists flexed, placing the proximal interphalangeal (PIP) joints comfortably up into the supraclavicular fossa, thus passively flexing the humerus forward, produces significantly better overall visualization of critical vertebral landmarks compared with positions where the arm is either straight out or partially flexed.[16] Ideally, the lateral radiograph should visualize C2 to the pelvis including the femoral heads to assess the sagittal balance of the spinal column. Similarly, on the PA view, the margins of the rib cage and the pelvis along with the femoral heads should be clearly visualized. This will facilitate the assessment of the skeletal maturity of a pediatric patient. The visualization of the ribs helps to determine the associated thoracic cage deformity. Both a congenital fusion of the ribs or significant chest wall deformity are associated with rigid or fused spinal segments. After assessing the spinal balance on the sagittal and coronal planes, the Cobb measurements are obtained for each area of the spine (cervical, proximal thoracic, main thoracic, and thoracolumbar/lumbar). The amount of vertebral body rotation at the apex of the coronal curve also determines the rigidity of the curve. The greater the vertebral body rotation, the greater the rigidity of the coronal curve. If the curve and clinical characteristics warrants the possibility of requiring surgical intervention, then the flexibility of the curve should be performed.

Flexibility of the coronal plane deformity is most commonly measured by supine PA left and right lateral bending films. The supine position is recommended so the patient can give a maximal effort without the possibility of falling. This position also eliminates the effect of gravity and will further clarify the flexibility of the deformity. Optimally, the full-length scoliosis films should be used to permit assessment of the flexibility of all areas of the deformity.[1,23] Traction and push-prone radiographs have been used by some deformity surgeons to measure the flexibility of the thoracic and lumbar curves.[24,25] Traction films are also used to determine the flexibility of the primary and compensatory curves and to assess the inherent capability of the curve to correct with traditional spinal instrumentation techniques. This enables the spine surgeon to determine the extent of intraoperative correction maneuvers that will be necessary to achieve spinal balance both in the sagittal and coronal planes. Traction radiographs are performed by the surgeon pulling on the head and neck while countertraction is applied to the lower extremities **(Figs. 9–3A to 9–3E)**.[26]

A push-prone radiograph is performed with patient in a supine position with manual force placed over the apex of the spinal deformity. This radiographic technique can determine both the primary curve flexibility and the compensatory curve response with forceful correction of the primary curve.[25] For this particular curves pattern in a patient with AIS, the push-prone radiograph most accurately predicts the position of the last instrumented vertebrae when treated with anterior spinal fusion and instrumentation. The technique involves translational forces applied at the apex with counterstabilizing forces applied at the axilla and pelvis on the opposite side.

Fulcrum-bending films are similar to bolster films used for kyphosis correction and are advocated by some authors in assessing scoliosis. This method involves placing the patient in the lateral decubitus position and bending over a fulcrum (a radiolucent padded cylinder) so that the spine is passively hinged open. The fulcrum-bending radiograph has been shown to be more predictive of the degree of flexibility and correctability than the lateral-bending radiograph in this group of patients who had segmental spinal instrumentation for correction of idiopathic scoliosis.[27] These films are thought to be more effective in predicting curve responses to surgical intervention. Halo gravity traction is an option for assessing very large curves and rigid curves particularly in patients with severe scoliosis, kyphoscoliosis, and kyphosis. It has been found to be a safe, well-tolerated method of applying gradual, sustained traction to maximize preoperative evaluation and postoperative correction in this difficult population.[28]

♦ Balance and Flexibility Issues Impacting Surgical Management

Assessment of the flexibility and balance of the spine in the sagittal plane is an important aspect of the evaluation of spinal deformity both in children and adults. This evaluation should be performed in all children with kyphosis, congenital malformations of the spine, and in all adults with spinal deformity. There are several causes of kyphosis and kyphoscoliosis in pediatric patients including Scheuermann's disease, congenital malformations, achondroplasia, and neurofibromatosis. There are myriad perioperative and operative factors that can lead to an unsuccessful surgical outcome, including inadequate preoperative kyphosis assessment; inappropriate selection of proximal and/or distal instrumentation and fusion levels; inadequate spinal fixation applied at the ends of the posterior construct where tension forces are greatest; failure of a posterior spinal construct; absence and/or an inadequate performance of an anterior spinal fusion when required either before or after the posterior procedure; and overcorrection of the kyphotic deformity based on the ability of the spine above and below to compensate for the correction. Some corrective procedures carry a significantly higher risk of spinal cord injury; for example, any type of correction of a kyphotic deformity carries a substantially higher risk compared with treatment of scoliosis.[29]

In the pediatric patient, the spine surgeon is required to determine if the kyphosis is postural, or caused secondary to wedging of the anterior vertebral body such as seen in Scheuermann's disease, or caused by a structural abnormality such as a congenital malformation. In a fixed kyphotic deformity secondary to improperly treated fractures or congenital malformation of the spinal column, assessment of its flexibility is essential for surgical planning. These pathologies are best assessed by flexion-extension views both in supine and upright positions. The rigid kyphosis should be further addressed with bolster films. In these patients, a semirigid bolster is placed at the apex of the kyphus to evaluate the extent of its correction **(Figs. 9–4A to 9–4E)**.

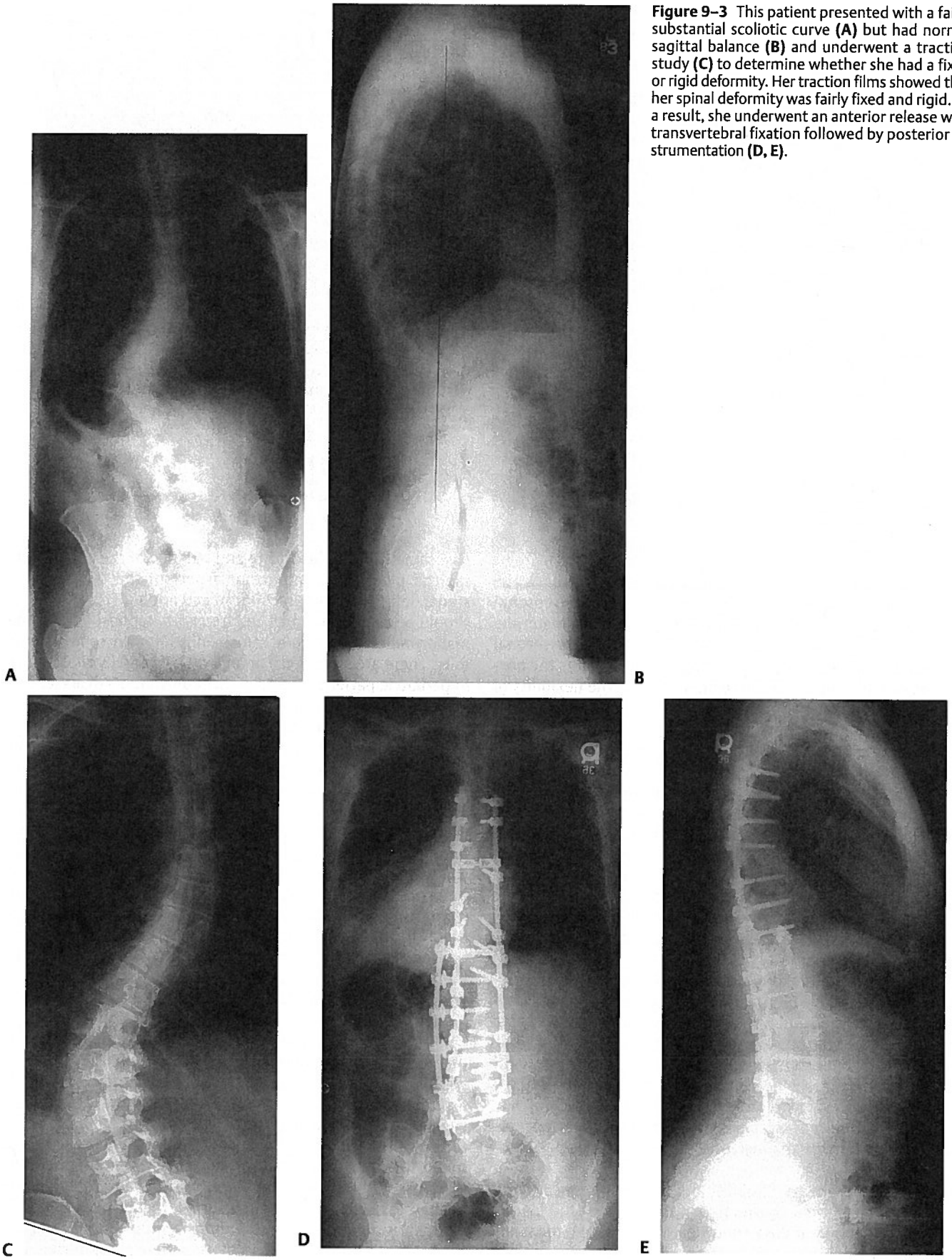

Figure 9–3 This patient presented with a fairly substantial scoliotic curve **(A)** but had normal sagittal balance **(B)** and underwent a traction study **(C)** to determine whether she had a fixed or rigid deformity. Her traction films showed that her spinal deformity was fairly fixed and rigid. As a result, she underwent an anterior release with transvertebral fixation followed by posterior instrumentation **(D, E)**.

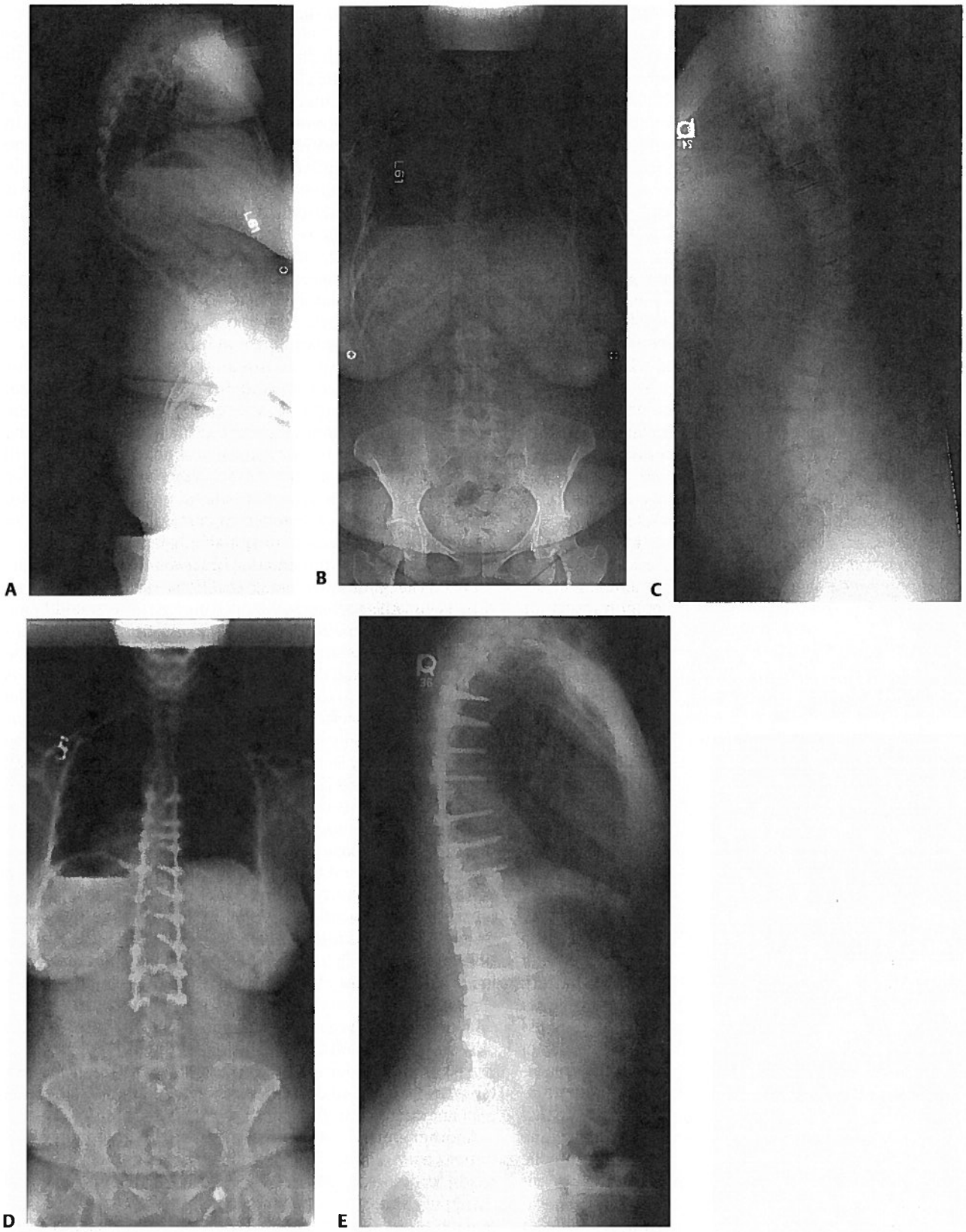

Figure 9–4 (A, B) This 22-year-old patient developed a focal 50-degree post-traumatic kyphotic deformity from a car accident that continued to progress despite bracing. **(C)** When the bolster was placed at the apex of the kyphus to evaluate the extention of its correction, surprisingly, it only corrected by 10 degrees. **(D, E)** As a result, a two-stage procedure was proposed with an anterior release with posterior stabilization and correction.

There has been increasing recognition of the relationship of sagittal imbalance as a contributor to symptoms either before or after surgery. In a recent publication, Glassman and associates have noted that the loss of sagittal balance was the predominant and statistically significant factor associated with patient morbidity.[7,30] The authors found even mildly positive sagittal balance is detrimental and the severity of symptoms increases in a linear fashion with progressive sagittal imbalance.[30]

The preoperative assessment should include an evaluation of cervical and craniocervical deformities particularly in cases of neuromuscular and congenital scoliosis. Assessment of the flexibility should include cervical dynamic radiographs. Several authors have advocated gradual cervical traction in both pediatric and adult patients particularly in cases of rigid but not fixed deformity. The change in spinal alignment after traction should be evaluated by plain radiographs and select cases with a CT scan.

Evaluating whether a deformity has components that are flexible, rigid, or immobile becomes particularly important especially when surgical intervention is contemplated. Realignment of a deformity can be achieved by using the inherent flexibility of the deformity and with additional correction through the stress relaxation characteristics of the connective tissue under continuous loading. In cases where the deformity is too large and/or stiff for stress relaxation to be the principle mode of correction, realignment can be accomplished by other techniques such as facet joint resection, anterior release through annulectomy and diskectomy, osteotomy, or vertebral column resection.[17–19] Thoracic pedicle screws have contributed significantly toward the change in the surgical management of more rigid deformity. The triplanar forces that can be applied by the pedicle screws can address curves that previously required anterior release approaches particularly in the range of 70 to 100 degrees.[31,32] The introduction of endoscopic surgery in AIS patients is a method of achieving anterior correction or anterior releases in patients with thoracic curves while minimizing morbidity compared with an open anterior procedure. Endoscopic release and fusion is an alternative in patients with larger, more rigid curves particularly when thoracic hook constructs are used.[33]

Curve flexibility is used in both classifying and managing adolescent idiopathic scoliosis. The flexibility of the main curve and its compensatory curve defines the curve pattern and determines the extent of fusion and instrumentation required for curve correction. Many authors have discussed using different selection criteria to selectively fuse segments of the major curve so the compensatory curve response after fusion will create a well-balanced spine with a maximum number of residual mobile segments. They have also advocated using the bending films to determine the level of fusion. The disk distal to the last instrumented vertebra should be mobile on the supine bending films in thoracic curves with a prominent thoracolumbar compensatory curve.

Recently, Lenke and associates have classified AIS curves taking into account both coronal and sagittal planes.[6] Bending films were used to define the structural versus the nonstructural nature of the minor curves in the proximal thoracic, thoracolumbar, and lumbar region. The sagittal plane was also considered whether there was hyperkyphosis at the thoracolumbar junction (>20 degrees) or at the proximal thoracic region. The structural versus nonstructural nature of curve aids the surgeon in determining whether to fuse or not to fuse the curve. The curve classification by this method has been shown to have better interobserver reliability than the previous King classification method. In the Lenke classification system, the bending films determine the major curves and structural properties of the curve. The nonstructural (compensatory) curve per this criterion is <25 degrees on bending films. Lenke et al. have used the classification system as a template to perform selective fusion but evaluate the curve ratio, vertebral rotation, and clinical features of the patient to plan the levels of fusion.[2] Clinically, the Lenke classification has been found to be a valuable tool in the selection of fusion levels because it helps the surgeon identify which curves are structural that need fusion and which are nonstructural that do not require fusion.[34] By instrumenting and fusing only the structural curves, this avoids unnecessarily extending the fusion of the nonstructural lumbar or thoracic spine as well as avoiding undercorrection of the structural secondary curves. It still remains to be determined whether only the structural curve needs to be fused or whether extension of the fusion into nonstructural areas is needed in certain circumstances to prevent curve progression or spinal imbalance.[3,35]

Transpedicular instrumentation has revolutionized spine surgery and is beginning to change traditional dictums of scoliosis surgery for AIS, such as spinal instrumentation should begin and end in the stable zone. Pedicle screw instrumentation techniques result in greater corrective forces to be applied to the spine. The improved correction achieved with pedicle screws permits the surgeon to end constructs at a more proximal level in the lumbar spine than was possible with hook-based constructs. This typically results in a one-level shorter fusion even if the disk mobility is not present such as ending at the L3 level instead of the L4 level. In the sagittal plane, however, traditional rules such as the fusion should be extended distally beyond to any junctional kyphosis (cervicothoracic or thoracolumbar) that might be present have not changed.

Burton et al. based the selection of the lower instrumented vertebra on the ability of the vertebra to become completely horizontal on contralateral bend radiographs, and this was termed the caudal foundation vertebra.[36] The caudal foundation vertebra was defined as the first vertebra at or above the lower end vertebra of the lumbar curve that would become centered over the sacrum after the application of torsional reduction loads. The caudal foundation vertebra is based on two criteria: the immediately adjacent disk space wedging is reversed or at least neutralized on convex bending, and the vertebra below it has 15 degrees or less rotation in the transverse plan on convex bending.

Another option for management of thoracolumbar and lumbar curves in AIS is the use of anterior spinal instrumentation techniques. They have been proven effective for spinal fusion of thoracolumbar/lumbar scoliosis over the past several decades.[37] The advantages of an anterior procedure are a shorter fusion and improved correction of the rotational deformity compared with techniques such as Harrington rods or posterior multisegmented hook instrumentation.[12,13] The benefits of anterior instrumentation and fusion with the posterior pedicle screw technique regarding number of levels

fused, spinal alignment, and relative incidence of complication are still being debated.

Scoliotic curves with larger Cobb angles tend to be more rigid both in pediatric and adult patients. Vertebral body rotation and chest wall deformation contribute to the stiffness of the curve. These large curves historically have been managed through combined open anterior and posterior procedures although very few studies have been conducted reporting the treatment strategies. Arlet recently reported on a posterior-only approach with third-generation spinal instrumentation to address curve measuring 70 degrees or greater.[38] The scoliotic deformity in this series had a Cobb angle averaging 78.5 degrees with a flexibility index of 32.5%. Using an adequate posterior release and current segmental instrumentation, they achieved a correction rate of 54%. Suk et al. have recently reported a posterior-only approach with complete vertebrectomy to restore spinal balance in patients with rigid curves greater than 80 degrees. Using this technique, a mean preoperative scoliosis of 109.0 degrees was corrected to 45.6 degrees (59% correction).[18]

An additional alternative for severe, ridged scoliosis is a combined anterior and posterior instrumentation procedure. A recent study recommended combined anterior and posterior instrumentation in rigid curves with a Cobb angle greater than 90 degrees and a flexibility of less than or equal to 30%. For the most severe curves with Cobb angles beyond 100 degrees, they also recommended a three-stage procedure including a posterior release prior to the anterior-posterior instrumentation. These authors achieved an average correction of the primary curve of 67% without any significant loss of correction at the latest follow-up. There were no cases of pseudarthrosis, deep wound infections, or any neurologic complications.[39]

Congenital scoliosis and kyphosis patients often demonstrate significant curve rigidity. These patients often have failures in formation and/or segmentation of the vertebral body or bodies. This inherent structural change of the column makes the deformity rigid and the location, type, and number of congenital anomalies is associated with a fairly well defined risk of progression through the growing years.[40,41] A variety of surgical options have been proposed for the best treatment of congenital scoliosis or kyphosis. The options for the operative treatment of congenital scoliosis include in situ fusion procedures, growth arrest procedures (convex hemiepiphysiodesis), correction by releases and facetectomies with fusion and instrumentation, and correction through osteotomy or segmental vertebral excision. Expansion thoracoplasty and vertical expandable prosthetic titanium rib implantation is a new alternative method for the treatment of thoracic insufficiency syndrome and congenital spinal deformity in children. Although there is relatively limited clinical experience, preliminary results have been encouraging.[42]

Congenital kyphosis and kyphoscoliosis are particularly challenging due to the higher risks of neurologic deficit present with treatment. McMaster and Singh found patients treated after the age of 5 years by a posterior arthrodesis followed by cast application had poor correction and a high incidence of pseudarthrosis that was not significantly improved by the addition of posterior instrumentation. For curves greater than 60 degrees, the most successful results were achieved by an anterior spinal release and arthrodesis with strut graft correction followed by posterior arthrodesis with instrumentation (if possible).[43] A simultaneous anterior and posterior approach through a costotransversectomy has been found to be a challenging but safe, versatile, and effective approach for the treatment of complex kyphotic deformities.[44]

Neuromuscular and paralytic scoliosis is often inherently rigid deformities. In addition, the pelvic obliquity in the neuromuscular patient also contributes to the spinal imbalance and overall morbidity. The pelvic obliquity impairs the ability of these patients to sit in an upright position and they have progressive loss of balance over time. One series used principally a Luque-Galveston wiring technique for treatment of the scoliosis and achieved substantial correction of the deformity. In this series, the major coronal curve measured 72 degrees and improved on best bend or traction view to a curve of 35 degrees. Following Luque-Galveston instrumentation a mean correction of 65% was achieved but the number of complications resulting from surgery was not insignificant.[45] Halo-gravity traction is an option for severe cases of neuromuscular scoliosis as it is for severe cases of congenital and idiopathic scoliosis.

The treatment of Scheuermann's disease is often conservative because the natural history of the disease is in most cases benign. Indications are mostly cosmetic, although pain in the area of the kyphosis occasionally occurs. Management of the kyphotic deformity depends on the magnitude and rigidity of the curve. The use of posterior release procedures and transpedicular instrumentation is changing the treatment of this condition with an increasing use of posterior-only approaches. Lowe has recommended posterior-only correction when the thoracic kyphosis on the hyperextension bolster corrects to less than 50 degrees.[46] Very rigid and large curves still require an anterior release, either done in a conventional or mini-open fashion or through video-assisted thoracoscopic surgery. Lowe recommends anterior release followed by posterior instrumentation procedure in less flexible curves (>50 degrees on hyperextension bolster radiographs).

♦ Fixed and Flexible Deformities in the Adult

Adult scoliosis whether neglected idiopathic or de novo degenerative scoliosis is usually more ridged than AIS, and different treatment strategies are needed compared with AIS. It is not uncommon for these patients to have had prior surgical procedures including spine fusions. Evaluation of the coronal and sagittal balance, the flexibility of the deformity, and the ability of the spine to compensate are all factors that influence the surgical technique. The deformities that are relatively flexible and in good coronal and sagittal balance can be considered for posterior-only treatment. More rigid, fixed, or fused deformities especially when associated with coronal or sagittal imbalance require a more aggressive and technically demanding surgical approach. Surgical options include combined anterior and posterior procedures, spinal osteotomy, or vertebral column resection procedures.[9–11] The complexity of these operations may require that they be staged. Rhee and

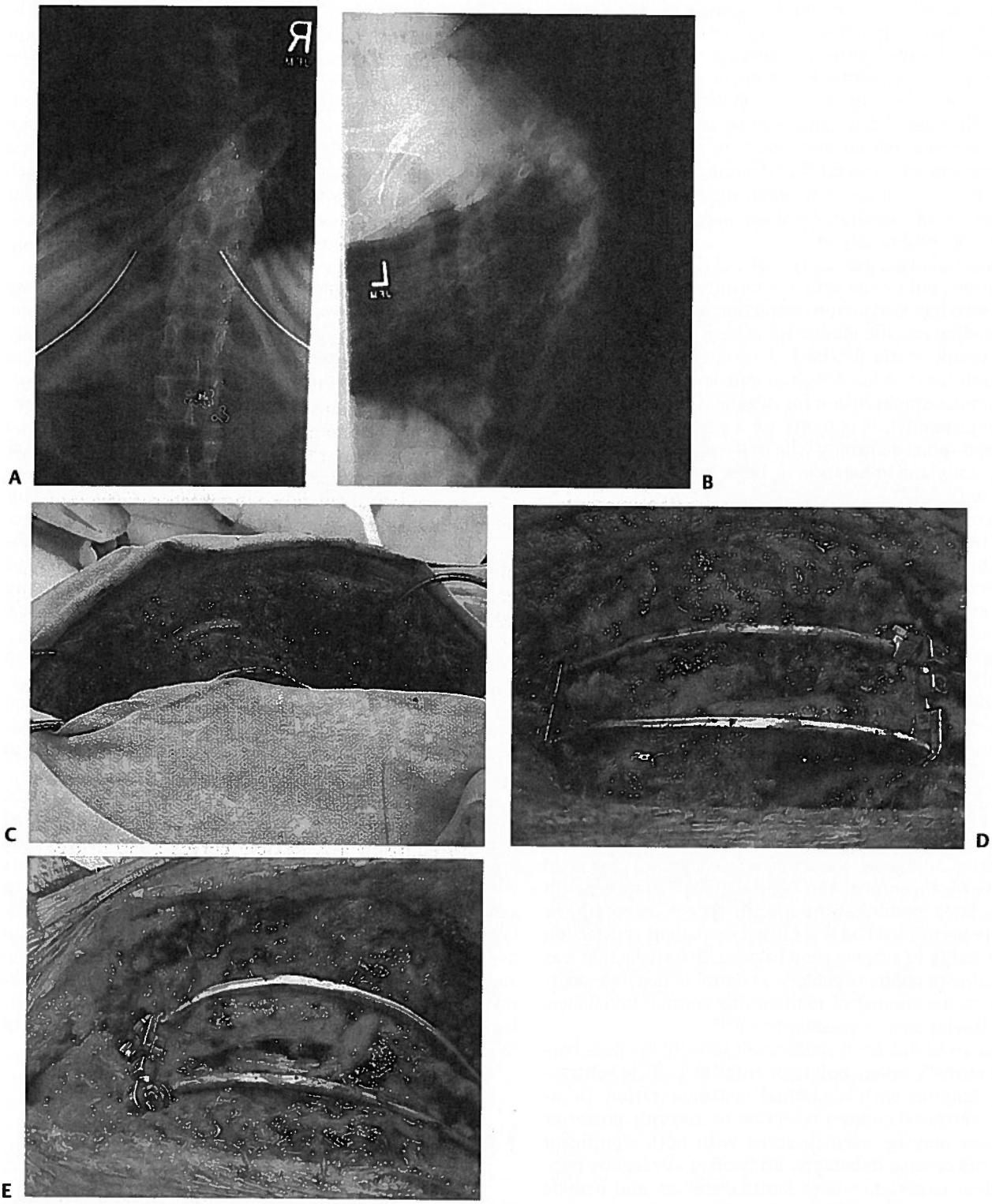

Figure 9–5 This patient had a very severe congenital complex three-column kyphoscoliotic deformity as demonstrated on her anteroposterior (AP) and lateral scoliosis films **(A, B)** as well as a history of Type I neurofibromatosis. She had a previous laminectomy as shown here in an intraoperative photograph **(C)**, and because of the degree of kyphoscoliosis, it was believed that overcorrection would pose too much of a risk in terms of giving her a neurologic deficit or damaging the major vascular structures anterior to the spine (aorta and inferior vena cava). Therefore, the instrumentation **(D)** and vertebrectomy were all done posteriorly through a costotransversectomy approach where a strut graft was also placed **(E)**.

associates recently reported on the strategy of dividing one prolonged, complex, posterior surgery into two smaller posterior procedures staged during one hospitalization. The authors had few surgical complications, no major medical complications, and an excellent outcome in a population known to be at high risk. They stated that staging can be useful in performing complex posterior revision and osteotomy surgery while limiting hemodynamic stresses.[47] Performing a smaller operation on this group of patients requiring demanding procedures may not only be short-lived but may also start a series of higher risk revision surgery.

Fixed sagittal plane deformity is one of the more recognizable entities seen by the spinal deformity surgeon. Several patients who had Harrington distraction rod fusion for scoliosis extending into the lumbar spine have been found to develop a symptomatic flat-back deformity with a positive sagittal imbalance. A fixed sagittal imbalance can also occur after a lumbar spinal fusion for degenerative conditions.[48] Ankylosing spondylitis patients are a subgroup of patients with a fixed spinal deformity who frequently develop prominent sagittal plane imbalance. In 1999, Booth et al. divided patients with flat back into two groups; segmental (Type I) with loss of lumbar lordosis or lumbar kyphosis with maintenance of normal sagittal balance and global (Type II), or classic, flat-back syndrome with a substantial fixed positive sagittal imbalance.[49]

When sagittal imbalance is noted, it is imperative to recognize the source of the deformity and the spinal segment contributing toward the deformity. In patients with ankylosing spondylitis, this imbalance may result from kyphosis at one or several areas. A kyphotic deformity at the cervicothoracic junction can compromise the patient's visual angle. A thoracic or thoracolumbar region deformity can prevent the patient from sitting normally, lying flat, and flexing both their hips and knees to attempt to stand erect. The goal is to correct the kyphosis and establish sagittal plane balance with the least surgical morbidity in these cases.

Correction of sagittal plane imbalance should at the local deformity regain coronal and sagittal global balance. Booth and associates found that the specific type of osteotomy or procedure performed had less impact on patient satisfaction than the ability to achieve good balance. Dissatisfaction was associated with failure to achieve a neutral or negative sagittal balance, developing or maintaining coronal imbalance, and the development of pseudarthrosis.[49]

Treatment of flat-back syndrome typically involves corrective Smith-Petersen, polysegmental, or pedicle subtraction osteotomies with segmental instrumentation. Occasionally, vertebral column resection or anterior-posterior procedures may be used in cases with both significant sagittal and coronal imbalance. Bridwell et al. recently published their experience with Smith-Petersen and pedicle subtraction osteotomies.[50] Both procedures restored spinal balance; however, pedicle subtraction osteotomy was effective in Type II (global) sagittal plane deformity correction with significant shift of the plumb line (>5 cm). The Smith-Petersen osteotomy was limited in patients with Type I sagittal deformities where the plumb line is <5 cm from the posterior aspect of L5-S1 disk space. The pedicle subtraction osteotomy is preferred below the level of the conus in the lumbar spine; however, it can also be performed at the thoracic spine but at increased risk of neurological deficit. Smith-Petersen et al. described and performed the first posterior spinal osteotomy for correction of sagittal deformity.[51] The procedure entails resection of the posterior elements at the desired level of correction with undercutting of the adjacent spinous processes with the sagittal correction achieved through posterior compression with instrumentation. As a general rule, 1 degree of correction can be expected for each millimeter of posterior bone resection.[52] The anterior column lengthening that resulted from the closure of the osteotomy sites caused some associated vascular injury and related complications.

The "egg shell" osteotomy or pedicle subtraction osteotomy is a three-column posterior closing wedge osteotomy hinging on the anterior cortex that addresses sagittal plane deformity correction having a three-column osteotomy. This procedure prevents anterior column lengthening with significant posterior correction. A pedicle subtraction osteotomy requires removal of all posterior elements at the level of the correction including the pedicles and the superior and inferior adjacent facet joints. A posterior wedge of bone is then removed from the vertebral body including removal of the entire posterior and lateral vertebral body walls to allow the desired correction.[53] This is a technically demanding procedure where substantial bleeding can result from the epidural venous plexus and the bleeding cancellous bone.[50] Correction deformity between 30 degrees and 38.8 degrees has been reported with this technique.[9,20]

Patients with global sagittal imbalance of the spine can be effectively treated with a combined anterior and posterior arthrodesis. Berven and associates have reported on 25 consecutive cases of preoperative global sagittal imbalance of at least 5 cm and clinical outcomes were best in cases that resulted in an increase in lumbar lordosis.[10]

In cases where complex three-column deformity exists, vertebral column resection procedures can be considered **(Figs. 9–5A to 9–5E)**. Due to the potential morbidity of the procedure, vertebral column resection should be for patients with fixed sagittal imbalance in addition to degenerative or adult scoliosis with severe coronal plane deformities. Advantages of the procedure include the dramatic correction possible at a single level and the overall shortening of the vertebral column, which relieves tension on anterior neurovascular structures.[53] Several authors have reported excellent correction in both the coronal and sagittal planes with this technique.[14,15]

♦ Conclusion

The goal of spinal deformity correction for both fixed and flexible deformities remains achieving spinal balance. The surgical strategies exploit the inherent characteristics of the individual curve to restore spinal balance. The use of flexibility is one component of the surgical planning; however, the clinical status of the patient, the particular deformity characteristics, and the complications associated with surgical intervention should all be evaluated with equal importance prior to venturing to deformity correction.

References

1. Duval-Beaupere G, Lespargot A, Grossiord A. Flexibility of scoliosis. What does it mean? Is this terminology appropriate? Spine 1985;10:428–432
2. Lenke LG, Betz RR, Haher TR, et al. Multisurgeon assessment of surgical decision-making in adolescent idiopathic scoliosis: curve classification, operative approach, and fusion levels. Spine 2001;26:2347–2353
3. Lenke LG, Betz RR, Harms J, et al. Adolescent idiopathic scoliosis: a new classification to determine extent of spinal arthrodesis. J Bone Joint Surg Am 2001;83-A:1169–1181
4. Lenke LG. Lenke classification system of adolescent idiopathic scoliosis: treatment recommendations. Instr Course Lect 2005;54:537–542
5. Lenke LG, Betz RR, Haher TR, et al. Multisurgeon assessment of surgical decision-making in adolescent idiopathic scoliosis: curve classification, operative approach, and fusion levels. Spine 2001;26:2347–2353
6. Lenke LG, Edwards CC, Bridwell KH. The Lenke classification of adolescent idiopathic scoliosis: how it organizes curve patterns as a template to perform selective fusions of the spine. Spine 2003;28:S199–S207
7. Glassman SD, Berven S, Bridwell K, Horton W, Dimar JR. Correlation of radiographic parameters and clinical symptoms in adult scoliosis. Spine 2005;30:682–688
8. Schwab FJ, Smith VA, Biserni M, Gamez L, Farcy JP, Pagala M. Adult scoliosis: a quantitative radiographic and clinical analysis. Spine 2002;27: 387–392
9. Berven SH, Deviren V, Smith JA, Emami A, Hu SS, Bradford DS. Management of fixed sagittal plane deformity: results of the transpedicular wedge resection osteotomy. Spine 2001;26:2036–2043
10. Berven SH, Deviren V, Smith JA, Hu SH, Bradford DS. Management of fixed sagittal plane deformity: outcome of combined anterior and posterior surgery. Spine 2003;28:1710–1715
11. Berven SH, Hu SS, Deviren V, Smith J, Bradford DS. Lumbar end plate osteotomy in adult patients with scoliosis. Clin Orthop Relat Res 2003; 411:70–76
12. Betz RR, Harms J, Clements DH III, et al. Comparison of anterior and posterior instrumentation for correction of adolescent thoracic idiopathic scoliosis. Spine 1999;24:225–239
13. Betz RR, Shufflebarger H. Anterior versus posterior instrumentation for the correction of thoracic idiopathic scoliosis. Spine 2001;26:1095–1100
14. Boachie-Adjei O, Bradford DS. Vertebral column resection and arthrodesis for complex spinal deformities. J Spinal Disord 1991;4:193–202
15. Bradford DS, Tribus CB. Vertebral column resection for the treatment of rigid coronal decompensation. Spine 1997;22:1590–1599
16. Horton WC, Brown CW, Bridwell KH, Glassman SD, Suk SI, Cha CW. Is there an optimal patient stance for obtaining a lateral 36" radiograph? A critical comparison of three techniques. Spine 2005;30:427–433
17. Shimode M, Kojima T, Sowa K. Spinal wedge osteotomy by a single posterior approach for correction of severe and rigid kyphosis or kyphoscoliosis. Spine 2002;27:2260–2267
18. Suk SI, Chung ER, Kim JH, Kim SS, Lee JS, Choi WK. Posterior vertebral column resection for severe rigid scoliosis. Spine 2005;30:1682–1687
19. Suk SI, Chung ER, Lee SM, Lee JH, Kim SS, Kim JH. Posterior vertebral column resection in fixed lumbosacral deformity. Spine 2005;30:E703–E710
20. Wu SS, Hwa SY, Lin LC, Pai WM, Chen PQ, Au MK. Management of rigid post-traumatic kyphosis. Spine 1996;21:2260–2266
21. Lee SM, Suk SI, Chung ER. Direct vertebral rotation: a new technique of three-dimensional deformity correction with segmental pedicle screw fixation in adolescent idiopathic scoliosis. Spine 2004;29: 343–349
22. Suk SI, Lee SM, Chung ER, Kim JH, Kim SS. Selective thoracic fusion with segmental pedicle screw fixation in the treatment of thoracic idiopathic scoliosis: more than 5-year follow-up. Spine 2005;30:1602–1609
23. Duval-Beaupere G, Robain G. Visualization on full spine radiographs of the anatomical connections of the centres of the segmental body mass supported by each vertebra and measured in vivo. Int Orthop 1987;11: 261–269
24. Engsberg JR, Lenke LG, Hollander KW, et al. Methods to locate center of gravity in scoliosis. Spine 2003;28:E483–E489
25. Vedantam R, Lenke LG, Bridwell KH, Linville DL. Comparison of push-prone and lateral-bending radiographs for predicting postoperative coronal alignment in thoracolumbar and lumbar scoliotic curves. Spine 2000;25:76–81
26. Hamzaoglu A, Talu U, Tezer M, Mirzanli C, Domanic U, Goksan SB. Assessment of curve flexibility in adolescent idiopathic scoliosis. Spine 2005;30:1637–1642
27. Cheung KM, Luk KD. Prediction of correction of scoliosis with use of the fulcrum bending radiograph. J Bone Joint Surg Am 1997;79: 1144–1150
28. Rinella A, Lenke L, Whitaker C, et al. Perioperative halo-gravity traction in the treatment of severe scoliosis and kyphosis. Spine 2005;30: 475–482
29. Lenke LG. Kyphosis of the thoracic and thoracolumbar spine in the pediatric patient: prevention and treatment of surgical complications. Instr Course Lect 2004;53:501–510
30. Glassman SD, Bridwell K, Dimar JR, Horton W, Berven S, Schwab F. The impact of positive sagittal balance in adult spinal deformity. Spine 2005;30:2024–2029
31. Deviren V, Acaroglu E, Lee J, et al. Pedicle screw fixation of the thoracic spine: an in vitro biomechanical study on different configurations. Spine 2005;30:2530–2537
32. Luhmann SJ, Lenke LG, Kim YJ, Bridwell KH, Schootman M. Thoracic adolescent idiopathic scoliosis curves between 70 degrees and 100 degrees: is anterior release necessary? Spine 2005;30:2061–2067
33. Lenke LG. Anterior endoscopic diskectomy and fusion for adolescent idiopathic scoliosis. Spine 2003;28:S36–S43
34. Puno RM, An KC, Puno RL, Jacob A, Chung SS. Treatment recommendations for idiopathic scoliosis: an assessment of the Lenke classification. Spine 2003;28:2102–2114
35. Lenke LG, Betz RR, Clements D, et al. Curve prevalence of a new classification of operative adolescent idiopathic scoliosis: does classification correlate with treatment? Spine 2002;27:604–611
36. Burton DC, Asher MA, Lai SM. The selection of fusion levels using torsional correction techniques in the surgical treatment of idiopathic scoliosis. Spine 1999;24:1728–1739
37. Sanders AE, Baumann R, Brown H, Johnston CE, Lenke LG, Sink E. Selective anterior fusion of thoracolumbar/lumbar curves in adolescents: when can the associated thoracic curve be left unfused? Spine 2003;28:706–713
38. Arlet V, Jiang L, Ouellet J. Is there a need for anterior release for 70–90 degrees masculine thoracic curves in adolescent scoliosis? Eur Spine J 2004;13:740–745
39. Bullmann V, Halm HF, Schulte T, Lerner T, Weber TP, Liljenqvist UR. Combined anterior and posterior instrumentation in severe and rigid idiopathic scoliosis. Eur Spine J 2006; 15:440–448
40. McMaster MJ, Ohtsuka K. The natural history of congenital scoliosis. A study of two hundred and fifty-one patients. J Bone Joint Surg Am 1982;64:1128–1147
41. McMaster MJ, Singh H. Natural history of congenital kyphosis and kyphoscoliosis. A study of one hundred and twelve patients. J Bone Joint Surg Am 1999;81:1367–1383
42. Hell AK, Campbell RM, Hefti F. The vertical expandable prosthetic titanium rib implant for the treatment of thoracic insufficiency syndrome associated with congenital and neuromuscular scoliosis in young children. J Pediatr Orthop B 2005;14:287–293
43. McMaster MJ, Singh H. The surgical management of congenital kyphosis and kyphoscoliosis. Spine 2001;26:2146–2154
44. Smith JT, Gollogly S, Dunn HK. Simultaneous anterior-posterior approach through a costotransversectomy for the treatment of congenital kyphosis and acquired kyphoscoliotic deformities. J Bone Joint Surg Am 2005;87:2281–2289

45. Benson ER, Thomson JD, Smith BG, Banta JV. Results and morbidity in a consecutive series of patients undergoing spinal fusion for neuromuscular scoliosis. Spine 1998;23:2308–2317

46. Lowe TG. Kyphosis of the thoracic and thoracolumbar spine in the pediatric patient: surgical treatment. Instr Course Lect 2004;53:493–500

47. Rhee JM, Bridwell KH, Won DS, Lenke LG, Chotigavanichaya C, Hanson DS. Sagittal plane analysis of adolescent idiopathic scoliosis: the effect of anterior versus posterior instrumentation. Spine 2002;27: 2350–2356

48. Farcy JP, Schwab FJ. Management of flatback and related kyphotic decompensation syndromes. Spine 1997;22:2452–2457

49. Booth KC, Bridwell KH, Lenke LG, Baldus CR, Blanke KM. Complications and predictive factors for the successful treatment of flatback deformity (fixed sagittal imbalance). Spine 1999;24:1712–1720

50. Bridwell KH, Lewis SJ, Edwards C, et al. Complications and outcomes of pedicle subtraction osteotomies for fixed sagittal imbalance. Spine 2003;28:2093–2101

51. Smith-Petersen MN, Larson CB, Aufranc OE. Osteotomy of the spine for correction of flexion deformity in rheumatoid arthritis. Clin Orthop Relat Res 1969;66:6–9

52. Bridwell KH, Lenke LG, Lewis SJ. Treatment of spinal stenosis and fixed sagittal imbalance. Clin Orthop Relat Res 2001;384:35–44

53. Potter BK, Lenke LG, Kuklo TR. Prevention and management of iatrogenic flatback deformity. J Bone Joint Surg Am 2004;86-A: 1793–1808.

Chapter 10

General Medical Issues in Spinal Deformity

Paul K. Kim and Joseph T. Alexander

Age represents an independent risk factor for perioperative morbidity at either extreme of the life span. The low tolerance for blood loss, fluid/electrolyte disturbances, and infection in the elderly population present a particular challenge for the surgeon and anesthesiologist. Advanced age is a marker for postoperative morbidity, as the prevalence of coexisting medical issues increases with age.[1] Higher rates of postoperative bleeding, wound-healing complications, and urinary tract infections in the elderly undergoing spinal operations have been described.[2] In addition, patients over 65 years of age are at a higher risk for atherosclerosis with the potential for limitations in myocardial and renal reserve. Therefore, closer monitoring of vital signs, fluid balance, and serum electrolytes is required.

Obese patients have a greater incidence of serious comorbidities and higher rates of postoperative wound breakdown, seroma formation, and thromboembolic complications. The higher rate of wound complications and infections seen in obese patients often results in the use of large, specialized pressure-relieving mattresses and hospital beds designed to minimize wound breakdown and pressure ulcer development in these patients undergoing major spinal surgery. Optimal postoperative care in these patients includes early mobilization, aggressive pulmonary toilet, and appropriate prophylaxis against deep venous thrombosis (DVT). In patients in whom graduated compression stockings or intermittent pneumatic compression (IPC) devices do not fit, consideration should be given to use of anticoagulation for DVT prophylaxis in the perioperative period. Occasionally, it may be advisable to delay elective spinal operation until the patient loses weight by appropriate measures.

♦ Deep Venous Thrombosis Prophylaxis

DVT prophylaxis is a critical part of perioperative management in patients undergoing spinal surgery. A review of the literature estimates the incidence of DVT in spinal surgery patients to range between 2% and 7%.[3] Several earlier studies reported no significant increase in the incidence of lower extremity DVT after elective spinal surgery with use of elastic compression stockings alone. However, the current general consensus favors use of IPC, based on more recent studies that more clearly demonstrate a significant reduction in the incidence of acute postoperative DVT after elective spinal surgery with perioperative use of IPC.[4] Comparative analysis of several studies has not shown a statistically significant difference in DVT rates when compared by age, sex, blood loss, number of levels fused, length of operation, or duration of bed rest postoperatively.[3]

Anticoagulation with low-molecular-weight heparin (LMWH) for DVT prophylaxis in elective spinal surgery appears to reduce the incidence of postoperative DVT without a significant increase in hemorrhagic complications. One recent study demonstrated a DVT rate of 0.05% and a hemorrhage rate of 0.4% in a series of 1949 spinal surgery patients who were treated with compression stockings and nadroparin subcutaneously within 24 hours postoperatively.[5] The majority of these patients with hemorrhagic complications demonstrated a progressive neurologic deficit. However, most studies evaluating postoperative DVT in the spinal surgery population have lacked adequate design, randomization, and control groups, which has led to the difficulty in defining the efficacy of thromboprophylaxis in spinal surgery patients.

Assessment of the risk of postoperative bleeding versus thrombosis can be challenging in patients with preexisting clinical indications for anticoagulation. Those considered to be of high risk for thrombosis who are likely to require anticoagulation perioperatively include patients with older mechanical heart valves, atrial fibrillation with history of cardioembolism, acute DVT (diagnosed within the past 3 months), and hypercoagulable states, such as factor V Leiden, protein C and S deficiency, lupus anticoagulant, and anticardiolipin antibodies. Intermediate risk patients, defined as

those in whom anticoagulation frequently may be postponed for a few days, include those with DVT diagnosed within the past 3 to 6 months, atrial fibrillation without cardioembolism, history of cerebrovascular stroke without risk factors for cardioembolism, and newer model prosthetic valves in the mitral location. Low-risk patients in whom no anticoagulation is usually required include those with one remote episode of DVT greater than 6 months age, newer prosthetic valves in the aortic location, and atrial fibrillation without multiple risk factors for cardioembolism.

In patients with an acute DVT who are deemed unsafe for anticoagulation postoperatively, placement of an inferior vena cava (IVC) filter remains an alternative treatment option. The value of IVC filters is not well-defined for patients with hypercoagulable states or cardioembolic risk factors. Routine ultrasonographic DVT surveillance ranging from every 72 hours to weekly should be considered in patients with risk factors for venous thromboembolism. If a calf DVT is detected, many recommend continuing surveillance every 3 to 4 days over a 2-week period without medical therapy, unless there is further development/propagation of the clot. However, detection of a proximal DVT should be treated with LMWH and Coumadin (warfarin Sodium) at the time of diagnosis postoperatively or an IVC filter if the surgeon deems anticoagulation to be contraindicated.

♦ Nutrition

Nutrition remains an important issue for patients undergoing major spinal surgery. There is increasing evidence that insufficient caloric intake may not meet the increased metabolic demands brought on by the hypercatabolic state induced by surgery or trauma.[6] This results in significant skeletal and visceral protein depletion. These malnourished patients have increased rates of mortality and morbidity from sepsis, wound complications, and prolonged recuperation. If nutritional inadequacies or malnutrition are identified, a regimen of nutritional supplementation should be started and monitored throughout the postoperative period. In patients who cannot tolerate or meet their caloric needs solely with oral intake, enteral nutrition may be achieved alternatively via feeding tubes. If adequate enteral nutrition is not possible, peripheral or total parenteral nutrition should be considered. In fact, an increasing body of literature is pointing to the use of preoperative enteral and parenteral hyperalimentation in malnourished patients undergoing major surgery as a means of reducing postoperative infection and wound-healing complications, which constitute some of the most common postoperative problems seen in compromised patients undergoing spinal surgery.[6] Also contributing to wound-healing complications is the long-term use of medications such as corticosteroids, immunosuppressive agents, or cytotoxic agents. In addition, renal failure, diabetes mellitus, malnutrition, and other immunocompromising diseases significantly increase susceptibility to infection, which may be caused by common or opportunistic organisms.

♦ Cardiovascular Disease

According to the American College of Cardiology standards, major spine surgery is considered an intermediate- to high-risk surgery due to the length of the procedure and potential fluid shifts involved.[7] Preoperative evaluation should be focused on ensuring that the patient's cardiovascular system is capable of handling anticipated blood loss, fluid loads, and blood pressure swings that are possible during surgery for spinal deformities. Four major factors involved in assessment of cardiac function are the presence of coronary artery disease (CAD), left ventricular dysfunction, symptomatic arrhythmias, and valvular disease. Preoperative evaluation should be focused on these four factors to determine if more extensive evaluation and treatment are indicated.

Evidence of CAD can be manifested as a past myocardial infarction (MI) or angina. However, subtle complaints, such as shortness of breath, chest tightness, radiating arm/neck pain with exertion, or nocturnal dyspnea are highly suggestive of CAD. High-risk groups, such as patients with diabetes mellitus, hypertension, hypercholesterolemia, and those with a strong family history of CAD, should also be treated with a degree of suspicion for CAD. A perioperative MI has a significantly higher mortality rate, up to 37 to 50%, than the mortality from a MI occurring outside the operating room.[8] The risk of perioperative MI is ~1 to 2% in patients undergoing major noncardiac surgery; this risk is nearly doubled in patients with known CAD. In the first 6 months after an MI, the risk of another perioperative MI is dramatically increased, ranging from 4 to 37%. However, after that, the risk of perioperative infarction falls to 4 to 6%, assuming the patient does not suffer an MI later in life.[9] Thus, elective surgery for spinal deformities should ideally be postponed until at least 6 months after a MI to allow for healing of myocardium and optimal medical management.

In the absence of an infarction, the severity and stability of angina is a guide for further workup. The American College of Cardiology guidelines indicate that if a patient's angina has been stable in severity, frequency, and precipitating causes and the patient has had a cardiac evaluation within the past 2 years, further evaluation is not indicated.[7] However, if there has been an increase in the severity or frequency of the patient's angina or if the patient has developed congestive heart failure at any point, further noninvasive testing is warranted to stratify overall cardiac risks. Included in these tests are echocardiography, dobutamine stress echocardiography, dipyridamole thallium imaging, and treadmill stress testing. Based on evaluation of these studies, the cardiologist can determine if the patient should undergo coronary angiography as the definitive test as to whether the severity of the patient's CAD is sufficient to require operative or nonoperative (i.e., coronary stenting or percutaneous transluminal coronary angioplasty) revascularization prior to elective surgery.[10]

Valvular heart disease is most often detected by a murmur on auscultation during the preoperative exam. Aortic stenosis presents the greatest risk intraoperatively and should be evaluated with echocardiography; patients with critical stenosis (valve area ≤ 0.75 cm^2) are at risk for sudden death, whereas severe stenosis is defined as valve area ≤ 1.0 cm^2.[11]

Recommendations for valve replacement surgery usually hinge on whether symptoms of angina, dyspnea, and/or syncope are present. If any of these are present, elective surgery should be postponed until the valve can be repaired. Patients without the above symptoms who demonstrate good exercise tolerance are believed by many cardiologists to be able to tolerate major spinal surgery if appropriate intraoperative management is provided by the anesthesiologist. Mitral stenosis, though less likely to pose life-threatening cardiac complications, is important to address because of potential pulmonary complications.[12] Intraoperative or postoperative pulmonary edema can develop in patients with mild to moderate mitral stenosis if they are allowed to become tachycardic or volume overloaded.

Valvular insufficiencies do not usually carry the same risk potential as stenotic lesions, although they often result in dilated cardiomyopathies leading to congestive heart failure. Aortic insufficiency is associated with three diseases that often present with significant spinal pathology: ankylosing spondylitis, rheumatoid arthritis, and Marfan's syndrome. The spine surgeon should be alerted to this association when evaluating patients with any of these spinal pathologies. In particular, the increased risk of aortic root dilation and dissection in patients with Marfan's syndrome warrants a cardiologist/cardiovascular surgeon referral if not previously addressed. Mitral insuffiency is most commonly the result of mitral valve prolapse, and is associated with Marfan's syndrome and other connective tissue disorders.

In addressing valve lesions during the preoperative evaluation, a common concern is the potential need for endocarditis prophylaxis. Given that the American Heart Association considers spine surgery a "clean" procedure, antibiotic prophylaxis for the prevention of bacterial endocarditis is not recommended.[7] Despite these recommendations, many surgeons prefer to administer antibiotic prophylaxis for secondary procedures involved with the surgery, including endotracheal intubation, urethral catheterization, and gastric tube placement, which involve high-risk areas of the respiratory, genitourinary, and gastrointestinal tracts. Furthermore, there is no distinction made regarding endocarditis prophylaxis for surgery involving spinal deformities related to osteomyelitis or diskitis.

♦ Pulmonary Disease

Patients with mild scoliotic deformities have both reduced efficiency of breathing and abnormal ventilatory patterns that may not be apparent at rest but may affect the ability to engage in strenuous physical activity. Patients with severe curves >60 degrees usually have reductions in lung volumes due to less complete emptying of the lungs by the impaired thoracic cavity. This phenomenon often worsens with increasing thoracic lordosis. In scoliotic curves >100 degrees, patients may have respiratory symptoms at rest, which can lead to respiratory failure if left untreated. In patients with neuromuscular diseases, such as muscular dystrophy and spinal muscular atrophy with spinal deformity, muscle weakness also contributes to reduced lung volumes. Many studies have demonstrated an improvement in the efficiency of ventilation, as estimated by O_2 consumption, after surgical repair of scoliosis and other spinal deformities.[12] Although these improvements have been mainly noted in patients undergoing a posterior approach only in the past, there is an increasing body of literature suggesting similar improvements in pulmonary function without a significant increase in morbidity in those who have undergone anterior approaches as well.[13] With markedly less energy requirements during routine respiration after correction of severe scoliotic deformities, younger patients have been noted to gain weight postoperatively in many cases.

A general rule is if a patient can climb two flights of stairs without shortness of breath, further evaluation of respiratory status is not likely to be necessary. Factors that predispose a patient to postoperative pulmonary complications include long-term cigarette smoking, chronic obstructive pulmonary disease (COPD), acute respiratory infections, and restrictive disorders, such as obesity, pulmonary fibrosis, and neuromuscular/skeletal disease. Patients with one or more of these factors often require a complete pulmonary evaluation as part of a careful preoperative preparation.

Long-term smokers have impaired clearance mechanisms, and many have acquired COPD/chronic bronchitis. As a result, these individuals suffer an almost sixfold increase in pulmonary complications from major spinal surgery.[14] However, at least one study has demonstrated that patients without significant pulmonary disease who have stopped smoking for at least 1 month prior to elective spinal surgery showed the same postoperative complication rate as nonsmokers.[15]

Pulmonary complications in the first postoperative hours after surgery for spinal deformity most commonly result from acute ventilatory failure. The effects of anesthetic agents and muscle relaxants may not have completely worn off, resulting in respiratory muscle weakness. In addition, anterior approaches to the thoracic and lumbar spine have been noted in the past for their higher rate of compromise of pulmonary function leading to increased morbidity. Atelectasis is the most common complication in the first 2 to 3 postoperative days. It results from collapse of the most dependent portion of the lung. Clinical signs include fever and tachypnea with linear densities or frank areas of collapse in dependent portions of the lung. Treatment entails deep breathing/coughing to re-expand unventilated lung segments. Mechanical devices, such as incentive spirometry remain an effective means of achieving adequate ventilation. Mobilization in the immediate postoperative period should be encouraged if there are no contraindications. Pneumonia usually results from inadequately treated atelectasis, airway contamination, or preexisting pulmonary disease. It rarely develops earlier than 4 days after operation unless an unusual event, such as aspiration, has occurred. The diagnosis is made by fever, leukocytosis, increased sputum production, decreased breath sounds or rales on auscultation, and an infiltrate on chest radiographs. The source is almost always bacterial, and antibiotics should be started accordingly for an appropriate course.

Acute pulmonary edema is common in elderly patients with compromised cardiac function or in patients with significant cardiac disease. It typically develops on the second or third postoperative day as third-space fluid is mobilized. Alternatively, it can occur with excessive fluid administration

during surgery or immediately postoperatively if cardiac or renal function is compromised. The diagnosis is made by the presence of tachypnea, tachycardia, shortness of breath, and orthopnea. These symptoms are often accompanied with elevated central venous pressure (CVP), distended neck veins, and/or wet rales in the lung bases. Pink, frothy sputum production may also be present. Chest radiographs may show classic perihilar fluffy infiltrates, cardiac enlargements, prominent pulmonary vascular shadows, and lymphatic congestion in the costophrenic angles, known as Kerley's B lines.

♦ Metabolic Bone Disorders of the Spine: Osteoporosis

Osteoporosis has been defined as a disease characterized by low bone mass, microarchitectural deterioration of bone tissue leading to enhanced bone fragility, and consequential increase in fracture risk.[16] Severe osteoporosis is defined as a bone mineral density (BMD) greater than the 2.5 SD and the presence of a fracture. Risk factors for osteoporosis include cigarette use, low body weight, and decreased hormonal production.

If significant osteopenia or osteoporosis is detected, a metabolic workup is often indicated. One should consider assessment of secondary causes of osteoporosis, including laboratory tests to measure parathyroid hormone (PTH), thyroid stimulating hormone (TSH), calcium, and phosphate. In addition, vitamin D 25-OH should be measured to assess baseline vitamin D levels, and urine N-telopeptide can be checked as a biochemical marker of bone resorption to measure an individual's response to osteoporosis treatment. Additional tests include a chemistry panel, urinary calcium, complete blood count, serum cortisol, osteocalcin, and alkaline phosphatase levels. If a systemic pathologic process is suspected, serum protein electrophoresis and 24-hour urine collection testing for the presence of Bence Jones proteins, as well as sedimentation rate, can be obtained to assess for multiple myeloma or other systemic processes.

Bone densitometry assessment is currently thought by many to be an effective method of assessing the risk of sustaining a fracture due to bone quality. BMD measurements are usually obtained for both the spine and hip, in that vertebral BMD may be falsely elevated in patients with spinal deformities or significant arthritic changes. The hip is often preferable in the elderly, particularly in those with spinal disorders. BMD assessments are helpful in measuring response to treatment, with scans recommended at least twice after initiation of treatment at intervals of ~2 years.[17]

The mainstay of osteoporosis treatment is centered around prevention. Most adults require adequate daily intake of dietary calcium and vitamin D, 1200 to 1500 mg/day and 400 to 800 IU/day, respectively. In addition, regular weight-bearing and strengthening exercises are necessary to reduce falls and fractures. A comprehensive rehabilitation program stressing spine extension and abdominal strengthening exercises, as well as impact-loading activities, such as walking, should be a part of all treatment plans for osteoporotic patients. Several prospective studies have shown that 1 hour of exercise 2 to 3 times a week can increase both BMD in the lumbar spine and total body calcium in postmenopausal women. Moreover, studies have shown a significant correlation between muscle mass and bone mass, suggesting that increased skeletal loading leads to increased bone mass.[18] Conversely, immobilization leads to increased bone resorption. Smoking cessation and limited alcohol intake is also recommended. Pharmacologic options for prevention and/or treatment of osteoporosis include agents that primarily inhibit bone resorption and agents that stimulate bone formation.

Osteoporosis is a leading cause of morbidity and mortality in the elderly. Osteoporotic vertebral compression fractures occur in ~20% of people over the age of 70 years.[19] Consequences of these fractures include pain and, in many cases, progressive vertebral body collapse with resultant spinal deformity manifested as kyphosis and/or scoliosis. Deformity in the osteoporotic spine often creates a biomechanical environment favoring additional fractures. Thus, prevention of progressive spinal deformity or correction of existing deformity is important in reducing adjacent level fracture risk and in preventing consequences of spinal deformity, such as impaired pulmonary function.

Traditionally, acute osteoporotic compression fractures have been treated nonsurgically, except in cases of fractures associated with neurologic compromise or spinal instability. Nonsurgical treatment of most patients with painful vertebral compression fractures includes light activity/bed rest, analgesic medications, antiosteoporotic drugs, and bracing. However, the side effects of nonsteroidal anti-inflammatory drugs (NSAIDs) and narcotics are well-known, and bed rest can lead to overall physiologic deconditioning and acceleration of bone loss. Bracing is typically poorly tolerated by the elderly, is expensive, and may further restrict diaphragmatic excursion. In addition, there is some evidence that rigid external orthoses may produce local osteoporosis in the relatively immobilized portion of the spine.[20]

Surgical treatment of deformities such as kyphosis and scoliosis in the osteoporotic spine can be very challenging given the poor bone quality and difficulties in securing fixation in osteoporotic bone. The propensity for instrumentation failure, such as screw pullout, has led to advancements in technique and instrumentation, such as the use of laminar fixation, multisegmental fixation, and augmentation of pedicle screw purchase through biologic and nonbiologic fillers. Moreover, spinal stabilization in this patient population is often fraught with complications related to the patient's advanced age and frequent comorbidities. Percutaneous interventional techniques have been developed as a minimally invasive and potentially safer alternative to open spinal surgery for painful osteoporosis-related vertebral compression fractures. Over the past decade, vertebroplasty, which involves percutaneous injection of polymethylmethacrylate directly into a fractured vertebral body, has been used to stabilize painful osteoporotic compression fractures with substantial pain relief reported in a majority of patients.[21] Kyphoplasty involves percutaneous insertion of an inflatable bone tamp into a fractured vertebral body. This process allows for elevation of the end plates, thereby restoring vertebral body height and creating

a cavity to be filled with bone void filler. Early results suggest significant relief of pain as well as the potential to improve the height of the collapsed vertebral body and reduce spinal kyphosis.[21]

♦ Pain Management

The significant preexisting pain medication requirements in many patients who undergo spinal surgery for deformity correction presents a formidable challenge in postoperative management. These patients have often developed tolerance as well as chronic dependency to narcotics and require multimodal management of acute postoperative pain. Nevertheless, caution should be used in dosing of narcotics, sedatives, and muscle relaxants in the elderly population to avoid known undesirable side effects, such as lethargy, increased falls, confusion/delirium, and respiratory compromise. On the other hand, one should be mindful of the potential for narcotic withdrawal in patients who are not meeting their chronic, basal narcotic requirements postoperatively. The use of patient-controlled analgesia (PCA) for intravenous opioid delivery is a common and effective method of acute postoperative pain management. There has also been increasing evidence that intrathecal opioid administration provides superior pain control with fewer side effects than peripheral intravenous PCA use after lumbar spinal surgery. Furthermore, several studies have shown intrathecal opioid use to have a low rate of complications associated with its use postoperatively.[22] The use of NSAIDs as an adjunct to narcotics has been found to enhance the pain-relieving effects of opioid use with significant opioid sparing as well, most notably in the first 48 to 72 hours after spinal surgery.[23] As a result, the well-known side effects of opioid use are decreased without an appreciable worsening of postoperative pain. Moreover, cyclooxygenase-II (COX-II) inhibitors have been shown as a viable alternative to conventional NSAIDs in acute postoperative pain management. COX-II inhibitors have the added theoretical benefit of not affecting platelet function or inhibiting osteogenic activity and spinal fusion, which are known actions of conventional NSAIDs. There is conflicting evidence that use of NSAIDs alone postoperatively provides adequate pain relief to the degree demonstrated by opioids. However, the majority of spine surgeons favor the use of narcotics as a primary means of postoperative pain control, with NSAIDs as an adjunct or second- or third-tier therapy in selected patients with refractory pain after major spinal surgery.

♦ Conclusion

The spectrum of medical issues involving patients with spinal deformities is wide and complex. The multitude of coexisting medical conditions in many of these patients requires thoughtful perioperative management to maximize the potential for successful postoperative outcome. Failure to address preexisting and developing medical problems in the perioperative period contributes to worsened postoperative morbidity/mortality in the overwhelming majority of patients undergoing surgery for correction and/or stabilization of a significant spinal deformity.

References

1. Irwin ZN, Arthur M, Mullins RJ, Hart RA. Variations in injury patterns, treatment, and outcome for spinal fracture and paralysis in adult versus geriatric patients. Spine 2004;29(7):796–802
2. Saleh KL. The elderly patient in the post anesthesia care unit. Nurs Clin North Am 1993;28:507–518
3. Catre MG. Anticoagulation in spinal surgery. A critical revieew of the literature. Can J Surg 1997;40(6):413–419
4. Ferree BA, Wright AM. Deep venous thrombosis following posterior lumbar spinal surgery. Spine 1993;18(8):1079–1082
5. Gerlach R, Raabe A, Beck J, et al. Postoperative nadroparin administration for prophylaxis of thromboembolic events is not associated with an increased risk of hemorrhage after spinal surgery. Eur Spine J 2004; 13(1):9–13
6. Nakamura K, Moriyama Y, Kariyazono H, et al. Influence of preoperative nutritional state on inflammatory response after surgery. Nutrition 1999;15(11–12):834–841
7. Eagle KA, Brundage BH, Chaitman BR, et al. Guidelines for perioperative evaluation for noncardiac surgery: report of the American College of Cardiology/American Heart Association Task Force on Practice Guidelines. Circulation 1996;93:1278–1317
8. Stark TW, Levinthal D, Burnett YL. Anesthetic considerations for spinal surgery. In: DeWald RL, ed. Spinal Deformities: The Comprehensive Text. New York: Thieme Medical Publishers; 2003:328–348
9. Shah KB, Kleinman BS, Sami H, et al. Reevaluation of perioperative myocardial infarction in patients with prior myocardial infarction undergoing noncardiac operations. Anesth Analg 1990;71:231–235
10. Badner NH, Knill RL, Brown JE, et al. Myocardial infarction after noncardiac surgery. Anesthesiology 1998;88:572–578
11. Braunwald E. Valvular heart disease. In: Braunwald E, ed. Heart Disease, a Textbook of Cardiovascular Medicine. Philadelphia: W.B. Saunders; 1988:1023–1092
12. Lenke LG. Pulmonary and chest cage physiology. In: DeWald RL, ed. Spinal Deformities: The Comprehensive Text. New York: Thieme Medical Publishers; 2003:126–134
13. Sucato DJ, Elerson E. A comparison between the prone and lateral position for performing a thoracoscopic anterior release and fusion for pediatric spinal deformity. Spine 2003;28(18):2176–2180
14. Moores LK. Smoking and postoperative pulmonary complications. An evidence-based review of the literature. Clin Chest Med 2000;21: 139–146
15. Bluman LG, Mosca L, Newman N, Simon DG. Preoperative smoking habits and postoperative pulmonary complications. Chest 1998;113: 883–889
16. National Osteoporosis Foundation. Physician's Guide to Prevention and Treatment of Osteoporosis. Belle Mead, NJ: Exerpta Medica, Inc.; 1998

17. Dawson EG, DeWald CJ, Nattiv A. Osteoporosis: evaluation and pharmacologic treatment. In: DeWald RL, ed. Spinal Deformities: The Comprehensive Text. New York: Thieme Medical Publishers; 2003: 195–199

18. Pfeifer M, Sinaki M, Geusens P, Boonen S, Preisinger E, Minne HW. Musculoskeletal rehabilitation in osteoporosis: a review. J Bone Miner Res 2004;19(8):1208–1214

19. Riggs BL, Melton LJ. The prevention and treatment of osteoporosis. N Engl J Med 1992;327:620–627

20. Korovessis P, Konstantinou D, Pieros G, et al. Spinal bone mineral density changes following halo vest immobilization for cervical trauma. Eur Spine J 1994;3(4):206–208

21. Phillips FM. Minimally invasive treatments of osteoporotic vertebral compression fractures. Spine 2003;28(15S):S45–S53

22. Joshi GP, McCarroll SM, O'Rourke K. Postoperative analgesia after lumbar laminectomy: epidural fentanyl infusion versus patient-controlled intravenous morphine. Anesth Analg 1995;80(3):511–514

23. Reuben SS, Connelly NR, Lurie S, et al. Postoperative analgesic effects of celecoxib or rofecoxib after spinal fusion surgery. Anesth Analg 2000;91:1221–1225

Chapter 11

Natural History of Spinal Deformity

John E. Lonstein and Amir A. Mehbod

Idiopathic scoliosis is the most common form of scoliosis. The term *idiopathic* is applied when all other causes of scoliosis have been excluded—neuromuscular disorders, congenital malformations, trauma, tumors, or reactive scoliosis such as the curve that develops due to a disk herniation. It develops in a healthy child during growth, and it is divided into three types depending on the age of onset: infantile (birth to age 3), juvenile (age 3 to puberty), and adolescent (after puberty). This chapter reviews the prevalence and natural history of adolescent idiopathic scoliosis (AIS).

♦ Prevalence

Incidence refers to the number of new cases of the disease or disorder in the population per year, whereas prevalence is the total number of the cases of the disease or disorder affecting the population at one time. When discussing scoliosis, studies usually give prevalence rates. The results of school screening programs have shown prevalence rates ranging from 0.3 to 15.3%.[1–4] This large range is reflective of the different detection methods, population screened, and definition of scoliosis. When only curves of greater than 10 degrees are considered, the prevalence is 1.5 to 3.0%.[1,4] The prevalence rate varies with the curve magnitude: 2 to 3% for curves greater than 10 degrees, 0.3 to 0.5% for curves greater than 20 degrees, and 0.2 to 0.3% for curves greater than 30 degrees.[3,5]

♦ Natural History

Once the diagnosis of AIS has been made, options for its treatment include observation, bracing, or surgery. A thorough understanding of the natural history of AIS allows one to make appropriate interventions to alter it in a positive way.

Unfortunately, many of the early long-term natural history studies of idiopathic scoliosis depicted a dismal prognosis. These reports are responsible for the misunderstanding that all types of idiopathic scoliosis will lead to disability from back pain and cardiopulmonary compromise.[6–10] However, these early studies have reported on a mixture of diagnoses including neuromuscular, congenital, infantile, and juvenile scoliosis.

In 1968, Nilsonne and Lundgren[10] reported a 50-year follow-up study of 113 patients with idiopathic scoliosis who were originally seen between 1913 and 1918. The cases were idiopathic, as paralytic and congenital cases were excluded. Ninety percent of the patients were traced, and it was found that 45% had died, with the mortality rate being especially high after the age of 45 years. This mortality rate was twice the rate in the general population, and 60% of the deaths were due to cardiopulmonary disease. Of the surviving patients, 90% had back symptoms and 30% were on disability. Of the females, 76% had never married. The major shortcoming of this study is that no radiographic data was reported, and thus the etiology of these patients' scoliosis is not clear. Many of the cases were probably infantile in onset.

In 1968, in the same journal as the above article,[10] Nachemson[9] presented the results of a 38-year follow-up of 130 patients with untreated scoliosis. There was a 100% increase (or twice the rate) in mortality compared with the general population. If only thoracic curves were considered, the mortality rate was 4 times that of the general population. In addition, 37% had constant back pain, 14% complained of cardiopulmonary symptoms, and 37% claimed disability because of their deformity. No one was employed in an occupation requiring heavy labor. The patients, however, had a mixture of different diagnoses. Only 59 patients (45%) had idiopathic scoliosis, and the remainder included patients with congenital scoliosis, paralytic scoliosis, neurofibromatosis, and scoliosis due

to tuberculosis. In 1992, Pehrsson et al.[11] revisited this patient population and divided the patients into different diagnosis. They found a significantly higher mortality in infantile and juvenile scoliosis but *not* in AIS.

Although these early studies depicted a dismal natural history for patients with AIS, they are of historical interest because little is known about the study population, most importantly the underlying diagnosis. Today, we have a better understanding of the natural history of AIS. For simplicity, the authors like to divide the natural history of AIS into preskeletal maturity and postskeletal maturity. For preskeletal maturity patients, studies have concentrated on the risk factors for progression of the curve, whereas for the postskeletal maturity, studies present both the radiographic and clinical outcomes of the patients.

Natural History Preskeletal Maturity

In the natural history of idiopathic scoliosis, there are three important questions: What percentage of cases progress? Is it possible to predict which curves will progress? What are the effects of untreated scoliosis? The effects of untreated scoliosis are discussed in the postskeletal maturity sections below.

The progression rates defined as 5 degrees or 10 degrees of increase from the time of presentation are fairly well documented. These progression rates vary from 5.2 to 40% (**Table 11–1**).[2,12–15] The factors related to curve progression can be divided into those related to the child's growth potential and factors related to the curve.

It is well-known that scoliosis can progress in the adolescent, especially during the adolescent growth spurt. This relationship between scoliosis and growth was first shown by Duval-Beaupere who studied 560 female scoliosis patients (500 post-polio and 60 idiopathic) with respect to curve progression and growth and compared the findings with the growth of 53 girls without scoliosis.[16] The curves increase at a steady rate during growth until a point called P, when an acceleration of the increase occurred, until a point called R, after which the curve increase plateaued.

Point P coincided with the onset of puberty on the growth velocity graph for girls and boys. In girls, this is marked by the start of breast and pubic hair development, at a Tanner stage 2 or chronological age 10 to 12 years. The growth spurt lasts ~2.5 to 3 years with the point of maximum growth velocity occurring 1 year after the onset of the growth spurt. Menarche, and the appearance of axillary hair, occurs 1.5 to 2 years after the onset of the growth spurt at a mean age of 13 years.[17] In boys, the onset of pubic hair occurs before the onset of the growth spurt. The onset of growth spurt coincides with a Tanner stage 2 or 3 and chronological age 11 to 16 years. The growth spurt is longer in boys, lasting 3.5 to 4 years with peak height velocity occurring at a mean chronological age of 14 years. The appearance of axillary hair and facial hair occur after peak height velocity. All the ages stated are according to a uniform Anglo-Saxon Caucasian population only and cannot be extrapolated for other races. Although the ages do not hold true for other races, the relationship between the maturity landmarks (Tanner stages, peak height velocity, menarche, etc.) and the growth spurt are still accurate.

Point R coincided with a Risser apophyis ossification sign of 4. Risser 4 corresponds with a cessation of spinal growth, and Risser 5 indicates the cessation of height increase.[18]

Lonstein and Carlson[14] studied the magnitude of the curve and the maturity of the child (using Risser sign) to determine the rates of curve progression. For curves of 20 to 29 degrees in an immature child with a Risser sign of 0 or 1, the risk of progression was 68%. On the other hand, for curves of less than 19 degrees in a mature adolescent with a Risser sign of 2 or more, the risk of progression was 1.6%. For smaller curves less than 19 degrees in immature children with Risser sign of 0 or 1, the risk of progression was 22%. In similar fashion, for larger curves 20 to 29 degrees but in mature children with Risser more than 2, the risk of progression was also 22% (**Table 11–2**).

Another clinical factor that has been suggested to be a risk factor for progression is the sex of the child. It is well-known that the prevalence of scoliosis detected on school screening has an approximately equal sex ratio, but those requiring treatment are predominantly female. Although one may expect that studies would show different incidences of progression in girls and boys, this has not been the case as all large series have too few boys to make any statistically significant statement, but some trends can be ascertained.

Soucacos and co-workers in 1998 presented their results of a 5-year prospective study on AIS, evaluating the risk factors of curve progression. A total of 85,622 children were examined for scoliosis in a prospective school screening study. A curve of at least 10 degrees was detected in 1436 children. Each child was followed clinically and radiographically for a mean of 3.2 years. Progression occurred in 14.7%, whereas spontaneous improvement of at least 5 degrees was observed in 27.4% with 9.5% demonstrating complete spontaneous resolution. The following, although not significant, were associated with a high risk of cure progression: sex (girls), curve pattern, maturity (girls before the onset of menses), age (time of pubertal growth spurt), and curve magnitude (greater than or equal to 30 degrees).[19]

Table 11–1 Incidence of Progression of Adolescent Idiopathic Scoliosis

Study	Number of Patients	Progression (%)	Curve Degree
Brooks[2]	134	5.2	–
Rogala[15]	603	6.8	–
Clarisse[13]	110	35	10–29
Bunnell[12]	326	20	<30
Bunnell[12]	326	40	>30
Lonstein[14]	727	23	5–29

Table 11–2 Percentage Risk of Progression Based on Risser Grade and Curve Magnitude at Detection

	Curve Magnitude	
Risser Grade	5–19 degrees	20–29 degrees
0–1	22%	68%
2–4	1.6%	23%

From these studies and more, several risk factors for progression of scoliosis have been found and can be summarized as follows:

1. *Age* The younger the age, the greater potential for growth and progression of the curve with a rapid rise in progression at the onset of adolescent growth spurt.[12–14,19]
2. *Sex* Progression is more common in girls.[12,13,15,19]
3. *Menarche* Progression is less common after menarche.[14,19] In Lonstein's series, 32% of patients with progressive curves and 68% of those with nonprogressive curves had reached menarche by the first visit.[14]
4. *Risser sign* The incidence of progression has been shown to decrease as the Risser sign increases.[12–14]
5. *Curve pattern* Double curves progress more frequently than single curves.[12–14,19]
6. *Curve magnitude* The incidence of progression increases with curve magnitude.[12–14,19,20]

In the preskeletal maturity phase of AIS, it can be concluded that as long as the child is growing, there is a chance for progression of the curve. Again in general, the younger the child and the larger the curve, the greater is the chance of progression. Other variables that may act as risk factors are the sex of the child and the curve pattern. Factors studied but not proved to be of use are family history of scoliosis, rotational prominence, decompensation, and numerous radiographic measurements such as rib vertebral angle difference of Mehta and vertebral rotation as measured by the Pedriolle method.[14]

Natural History Postskeletal Maturity

Just as it is important to understand the natural history of AIS in the growing child and try to alter it in a positive way, it is important to understand the natural history of AIS after skeletal maturity. This will allow one to compare long-term outcomes of treatment and contrast those with the natural history. Many long-term studies have been performed to determine the natural history of AIS well into adulthood, both radiographically and clinically.

A long-term study performed by Collis and Ponseti,[21] from Iowa City, attempted to locate the 358 patients reviewed by Ponseti and Friedman in 1950. They had original and current radiographs of these patients. Not all of the patients were adolescents as their inclusion was patients over age 8 years. They located 215 patients. Three of these patients had spine fusions in adult life, and 17 had died between 1948 and 1968. Thus, 195 patients were included in the analysis. One hundred six patients returned for interviews, physical examinations, and vital capacity measurements. Questionnaires were filled out by 89 patients. The average follow-up was 24 years. Most curves increased after skeletal maturity. Thoracic curves of 60 to 80 degrees progressed the most with an average of 28 degrees increase, whereas those less than 60 degrees showed an average of only 9 degrees of progression. Lumbar curves more than 30 degrees progressed an average of 18 degrees, whereas those less than 30 degrees did not progress. With regard to the clinical outcomes, decreased vital capacity was noted in all thoracic curves greater than 60 degrees. Furthermore, 40% of patients complained of dyspnea, especially in those with thoracic curves of 85 degrees or more. Additionally, 54% of the patients complained of back pain. Unfortunately, only 42% of the original 358 patients could be located, making the follow-up less accurate.

Weinstein and co-workers presented the longer term outcome with 50-year follow-up of the untreated cohort[10] of the Collis and Ponsetti study.[20,,22–26] The radiographic and clinical results were presented in 1981 at 30-year follow-up[26] and was followed by the clinical results at 50-year follow-up in 2003.[25] As in the previous study, there were still 3 patients who had fusions in adult life and there were 36 deaths. This left 117 patients included in the analysis. The radiographic results were based on 102 patients of whom 25 patients had curves less than 30 degrees and 77 patients had curves 30 degrees or more at skeletal maturity. They report that curves less than 30 degrees at skeletal maturity rarely progress, whereas curves greater than 50 degrees tend to progress at an average of 1 degree per year. On the basis of this curve progression, they recommended that "progressive curves reaching 50 degrees at skeletal maturity should be fused."[26] The breakdown of numbers of curves between 30 to 50 degrees and 50 degrees or higher is not clear.[20,26]

With regard to functional outcomes, Weinstein et al. studied the mortality rate, pulmonary functions, back pain, depression, and bodily image.[25,26] In 1981, 161 patients were included in the analysis, and in the more recent study, 117 of those patients were included in the analysis. The mortality rate and the prevalence of back pain and depression were found to be the same as the general population. On the other hand, it was found that having a Cobb angle of greater than 50 degrees at skeletal maturity is a significant predictor of decreased vital capacity and more frequent shortness of breath into adulthood as the curves progressed to reach 80 degrees. Additionally, patients with AIS can develop significant deformity and the cosmetic aspect cannot be overlooked. In general, patients with untreated scoliosis had significantly lower body satisfaction scores when compared with controls, and 32% believed their life had been limited by their scoliosis.

In 1986, Ascani et al.[6] reported on 187 patients with an average follow-up of 33 years. All curves increased after skeletal maturity at an average of 0.4 degrees per year. The rate for different curve magnitudes is not reported, however they state that curve progression was almost double for curves greater than 40 degrees compared with curves less than 40 degrees. Additionally, pain was present in 61%, cardiopulmonary symptoms in 22%, and psychological disturbances in 19%. Although no recommendations were made, they did highlight the fact that curve progression was higher in curves of 40 degrees or more.

More recently in 1988, Edgar and Mehta[8] reviewed fused and unfused patients with idiopathic scoliosis to detect the effect of surgery on the natural history. Out of the 168 patients studied, 77 were managed nonoperatively and 91 had undergone posterior spinal fusions. All but 6 of the unfused patients had AIS, whereas the fused patients consisted of 43 with infantile scoliosis and 48 with AIS. The average Cobb angle at maturity for the unfused patients was 64 degrees and for the fused patients 68 degrees. They reported a significant rate of increase in curves greater than 40 degrees that were not fused

as compared with curves that were fused. Curves greater than 50 degrees increased significantly at an average of 1 degree per year. With regard to pain, the unfused patients suffered from severe back pain significantly more than the fused patients. They concluded that spinal fusion protects the scoliotic spine from further deterioration in adult life and significantly reduces the incidence of major or disabling pain. Again, one must note that they included a mixture of diagnosis in their patient population. Additionally, these curves had on average larger magnitudes, with the average in the 60-degree range. These conclusions may not hold true for smaller curves.

With the knowledge of these natural history studies, one rarely needs to treat small curves of less than 30 degrees with minimal deformity at skeletal maturity. On the other hand, larger curves of 50 degrees or more with significant deformity at skeletal maturity may be candidates for surgical treatment. What about the middle group of patient with curves between 30 and 50 degrees at skeletal maturity? The authors have tried to study this topic and presented their work to the Scoliosis Research Society in 2003. Their goal was to report on the long-term radiographic and clinical outcomes of patients with diagnosis of AIS with curves between 30 and 50 degrees at maturity.

A total of 46 patients were identified with complete radiographic and clinical data. There were 41 females (89%) and 5 males (1%). All patients were followed at least 10 years past skeletal maturity with mean follow-up of 19.5 years (range 10 to 37.8 years). The average age at skeletal maturity was 17 years and at final follow-up was 38 years.

At the time of skeletal maturity, all patients were either Risser 4 (36%) or Risser 5 (64%). The rate of progression was determined as follows: (1) for each individual curve and (2) for curves associated with different curve patterns. When studied individually, the rate of progression, in degrees per year, for each curve was: 0.23 for upper thoracic curves, 0.47 for thoracic curves, and 0.28 for lumbar curves. When the curves were examined in accordance with the curve pattern, the rate of progression, in degrees per year, for the thoracic curve was slightly different but not significant. The average change per year was less than 1 degree in 95% of the patients; the maximum change per year was 1.2 degrees.

Few patients had limitations in functionality as indicated by the SF36, Roland Morris, and Oswestry scores. Two patients had undergone surgery for their spine for degenerative disease.

In summary, the natural history of scoliosis varies according to the etiology, and we have gained insight into the radiographic and clinical outcomes of nonsurgically treated AIS. The main treatments available for AIS are observation, bracing, and surgery. In the preskeletal maturity phase, the main predictors of curve progression are the size of the curve and the growth potential of the child. Recent evidence suggests that the rate of surgery of AIS is not affected by use of bracing[27–29] and therefore one must weigh the risk of surgery with that of curve progression up to the point of skeletal maturity. In the postskeletal maturity period, most curves do not progress significantly, and the clinical outcomes are similar to the general population. Thus, surgical treatment of asymptomatic idiopathic curves in the adult is controversial and should be reserved for patients with symptoms of cardiopulmonary compromise or back pain not responding to nonoperative measures.

References

1. Asher M, Green P, Orrick J. A six-year report: spinal deformity screening in Kansas school children. J Kans Med Soc 1980;81:568–571
2. Brooks HL, Azen SP, Gerberg E, et al. Scoliosis: a prospective epidemiological study. J Bone Joint Surg Am 1975;57:968–972
3. Dickson RA, Stamper P, Sharp AM, et al. School screening for scoliosis: cohort study of clinical course. BMJ 1980;281:265–267
4. Lonstein JE, Bjorklund S, Wanninger MH, et al. Voluntary school screening for scoliosis in Minnesota. J Bone Joint Surg Am 1982;64: 481–488
5. Willner S, Uden A. A prospective prevalence study of scoliosis in Southern Sweden. Acta Orthop Scand 1982;53:233–237
6. Ascani E, Bartolozzi P, Logroscino C, et al. Natural history of untreated idiopathic scoliosis after skeletal maturity. Spine 1986;11:784–789
7. Edgar M. The natural history of unfused scoliosis. Orthopedics 1987;10:931–939
8. Edgar MA, Mehta MH. Long-term follow-up of fused and unfused idiopathic scoliosis. J Bone Joint Surg Br. 1988;70:712–716
9. Nachemson AA. Long-term follow-up study of non-treated scoliosis. Acta Orthop Scand 1968;39:466–476
10. Nilsonne U, Lundgren K. Long-term prognosis in idiopathic scoliosis. Acta Orthop Scand 1968;39:456–465
11. Pehrsson K, Larsson S, Oden A, et al. Long-term follow-up of patients with untreated scoliosis: a study of mortality, causes of death, and symptoms. Spine 1992;17:1091–1096
12. Bunnell W. The natural history of idiopathic scoliosis before skeletal maturity. Spine 1986;11:773–776
13. Clarisse P. Pronostic evoluif des scolioses idiopathiques mineures de 10 degrees a 29 degrees, au periode de croissance. Université Claude Bernard: Lyon, France; 1974
14. Lonstein JE, Carlson JM. The prediction of curve progression in untreated idiopathic scoliosis during growth. J Bone Joint Surg Am 1984; 66:1061–1071
15. Rogala EJ, Drummond DS, Gurr J. Scoliosis: incidence and natural history. A prospective epidemiological study. J Bone Joint Surg Am 1978; 60:173–176
16. Duval-Beaupere G. Pathogenic relationship between scoliosis and growth. In: Zorab P, ed. Scoliosis and Growth. Edinburgh: Churchill Livingstone; 1971:58–64
17. Calvo J. Observations on the growth of the female adolescent spine and its relationship to scoliosis. Clin Orthop Relat Res 1957;10:40–47
18. Zaoussis AL, James JI. The iliac apophysis and the evolution of curves in scoliosis. J Bone Joint Surg Br 1958;40B:442–453
19. Soucacos PN, Zacharis K, Gelalis J, et al. Assessment of curve progression in idiopathic scoliosis. Eur Spine J 1998;7:270–277
20. Weinstein SL, Ponseti IV. Curve progression in idiopathic scoliosis. J Bone Joint Surg Am 1983;65:447–455
21. Collis DK, Ponseti IV. Long-term follow-up of patients with idiopathic scoliosis not treated surgically. J Bone Joint Surg Am 1969;51: 425–445

22. Ponseti I, Friedman B. Prognosis in idiopathic scoliosis. J Bone Joint Surg Am 1950;32A:381–395

23. Weinstein S. Adolescent idiopathic scoliosis: natural history. In: Weinstein S, ed. The Pediatric Spine: Principles and Practice. 2nd edition. Philadelphia: Lippincott Williams & Wilkins; 2001:355–369

24. Weinstein S. Idiopathic scoliosis. Natural history. Spine 1986;11: 780–783

25. Weinstein S, Dolan L, Spratt K, et al. Health and function of patients with untreated idiopathic scoliosis: a 50-year natural history study. JAMA 2003;289:559–567

26. Weinstein SL, Zavala DC, Ponseti IV. Idiopathic scoliosis: long-term follow-up and prognosis in untreated patients. J Bone Joint Surg Am 1981;63:702–712

27. Goldberg CJ, Moore DP, Fogarty EE, et al. Adolescent idiopathic scoliosis: the effect of brace treatment on the incidence of surgery. Spine 2001;26:42–47

28. Spoonamore MJ, Dolan LA, Weinstein SL. Use of the Rosenberger brace in the treatment of progressive adolescent idiopathic scoliosis. Spine 2004;29:1458–1464

29. Vijvermans V, Fabry G, Nijs J. Factors determining the final outcome of treatment of idiopathic scoliosis with the Boston brace: a longitudinal study. J Pediatr Orthop B 2004;13:143–149

Section II

Treatment of Spinal Deformities

Chapter 12

Congenital Scoliosis

Robert B. Winter

♦ Classification and Terminology

Congenital scoliosis is, by definition, a lateral curvature of the spine caused by congenitally anomalous development of the vertebrae. These anomalies are present at birth, although the deformity may not show until later in growth. Congenital kyphosis and lordosis can also develop but will not be discussed in this chapter.

The anomalies can be failures of formation (i.e., a hemivertebra), failures of segmentation (unilateral unsegmented bar), or mixtures of both. Mixed anomalies are by far the most common. The most common failure of formation is a hemivertebra. These can be single, multiple on the same side, one each on opposite sides at different levels (hemimetameric shift), or "tucked" into the spine without curvature (*incarcerated* hemivertebra). They can be *fully segmented,* meaning that there is disk material both above and below the hemivertebra, *semisegmented,* meaning that there is disk material on one side but not the other, or *nonsegmented,* meaning there is no disk on either side.[1]

Defects of segmentation can be symmetrical (total lack of segmentation) creating a *bloc vertebra.* This does not cause deformity except for lack of motion and vertical growth. Asymmetric defects of segmentation cause deformity. If the bar of nonsegmented bone is lateral, a scoliosis will result. If the bar of bone is anterior, a kyphosis will develop. If posterior, a lordosis will develop.

The essence of understanding congenital scoliosis lies in the understanding of the differential in growth of one side of the spine versus the other. If the two sides of the spine are not growing at an equal rate, then deformity will develop. The greater the discrepancy, the more rapid will be the progression and the more severe the deformity **(Fig. 12–1).**

♦ Genetics

On the whole, congenital scoliosis is not a hereditary problem, but a few exceptions do occur. The main testimony to its nonhereditary nature lies with identical twins. Almost always, if one sib of a pair of identical twins has a congenital scoliosis, the other sib will *not* have the problem. This author has had the experience of seeing six pairs of identical twins, and in all six pairs, only one sib had the problem. On the other hand, I treated one family that had three children, all three having congenital scoliosis. The parents were not related, did not have scoliosis (both were x-rayed), and a baby daughter of the oldest sib was also free of problems.

Scientific studies are few. A review of 1250 patients with congenital spine deformities at our center revealed 12 with a first- or second-degree relative with a congenital spine deformity.[2] This was a retrospective study and suffered from a lack of routine radiographs of the relatives. Wynn-Davies of Scotland did a more comprehensive study of the families of 337 patients.[3]

There are isolated reports of families with multiple individuals with congenital spine deformities, but these appear to be primarily in situations where the parents were closely related.

♦ Patient Evaluation

All patients with a congenital spine deformity must have a thorough, total evaluation. The reason for this is not only "good medicine" but also the very high prevalence of anomalies all over the body.[4] In the neural axis, these can include hydrocephalus, Chiari malformation, diastematomyelia, tight filum



Figure 12–1 **(A)** Congenital scoliosis due to a unilateral unsegmented bar. **(B)** Congenital scoliosis due to a fully segmented hemivertebra. From Winter RB. Congenital Deformities of the Spine. New York: Thieme-Stratton Inc.; 1983. Reprinted by permission.

terminale, lipoma, and syringomyelia. The likelihood of one of these problems is ~40%.[5] Abnormalities of the genitourinary system are second in frequency at ~30%.[6] Cardiac anomalies are seen in ~20%.[5] All sorts of other problems are seen including lung agenesis, limb deficiencies, Sprengel's deformity, imperforate anus, T-E fistula, and so forth.

The advent of MRI has allowed for better and safer evaluation of the spine and other structures. The current standard of care is to do MRI in all patients going to surgery for spine deformity, in all patients presenting with a neurologic deficit of any type, and in all patients in whom the routine radiographs suggest an intraspinal anomaly such as a diastematomyelia. Although some physicians advocate an MRI in all congenital spine deformity patients, it is questionable whether the costs and risks of an anesthetic in a small child are justifiable. Needless to say, the responsible physician must do a very careful neurologic examination when the patient is first seen.

The kidneys are usually evaluated by ultrasound, but this is not necessary if an MRI is to be done, because the kidneys can be seen well on the MRI. Neither of these tests image the ureters well, and if there is any suspicion of ureteral stenosis (hydronephrosis on MRI or ultrasound), then an intravenous pyelogram (IVP) is appropriate.

The heart should always be examined for any murmurs, and the heart size and shape can be seen on the spine films. If there exists any concern, then a cardiac consultation is appropriate.

Clinical evaluation of the spine includes the direction of deformity, length of deformity, rotational prominence, stiffness of deformity, shoulder elevation, lateral decompensation, and sagittal profile. Radiologic evaluation includes standing (if old enough) posteroanterior and lateral full-spine views, supine coned-down view of the deformity area (gives a much better view of the nature of the anomalies than does the long-standing views), and bending, fulcrum, or traction views to determine the curve's flexibility or rigidity. Further information about details can often be gained from the MRI, especially whether or not segmentation is complete, and whether or not a growth plate is present. CT scans are rarely necessary **(Fig. 12–2).**

♦ Natural History

The key to understanding the clinical management of patients with congenital scoliosis is to understand the natural history of the various problems. Excellent studies of the natural history are available including Kuhns and Hormel,[7] Winter, Moe, and Eilers,[8] McMaster,[9] and McMaster and Ohtsuka.[10] These are fortunately all in agreement and provide a solid base of evidence.

Various factors must be taken into account when making an analysis of any given situation. These include the current age of the patient, current state of secondary development, sex, nature of the anomalies, and location of the anomalies. The more years of growth remaining, the more likely is progression. If the pubertal growth spurt is yet to occur, the more likely is progression. If it is a girl, the more likely is progression. If the curve is thoracic or thoracolumbar, the more likely is progression.

The most malignant of anomalies is the unilateral unsegmented bar with a contralateral hemivertebra. If located in the thoracic or thoracolumbar spine, there is a progression rate of at least 6 to 10 degrees *per year.* This means that if a 2-year-old child presents to you with a 40-degree curve, it will be at 100 to 140 degrees by age 12! The second most malignant anomaly is the unilateral unsegmented bar. This will progress at almost the same rate **(Fig. 12–3).**

Hemivertebrae, on the other hand, are extremely difficult to predict. Two adjacent hemivertebrae, both of the fully segmented type, has a very bad prognosis, almost equal to a unilateral bar. A single, fully segmented hemivertebra may or may not progress. Only very careful monitoring will give the answer. If it is posterolateral, giving a kyphoscoliosis, the prognosis is much worse. A semisegmented hemivertebra is much less likely to progress, and a nonsegmented hemivertebra almost never progresses **(Fig. 12–4).**

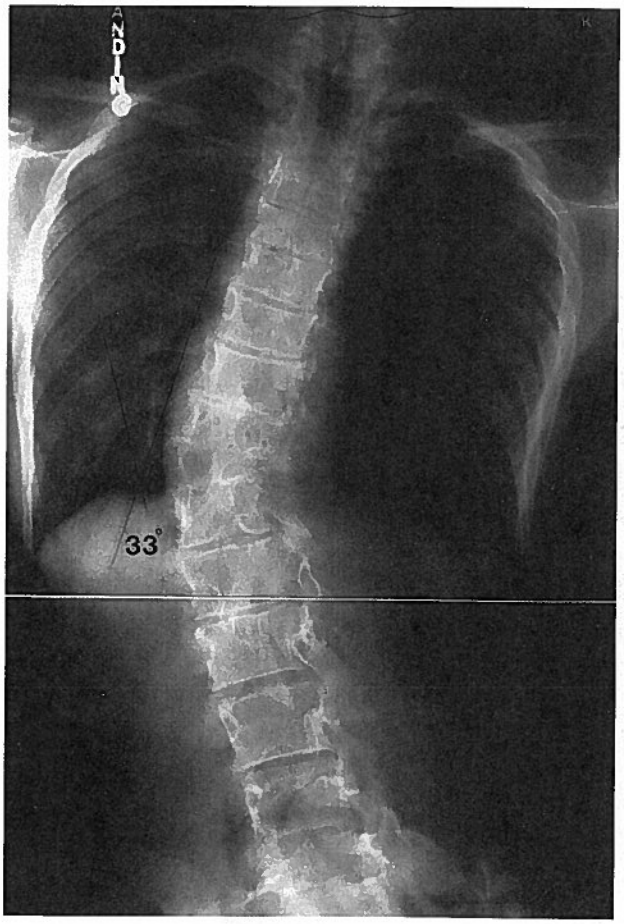

A

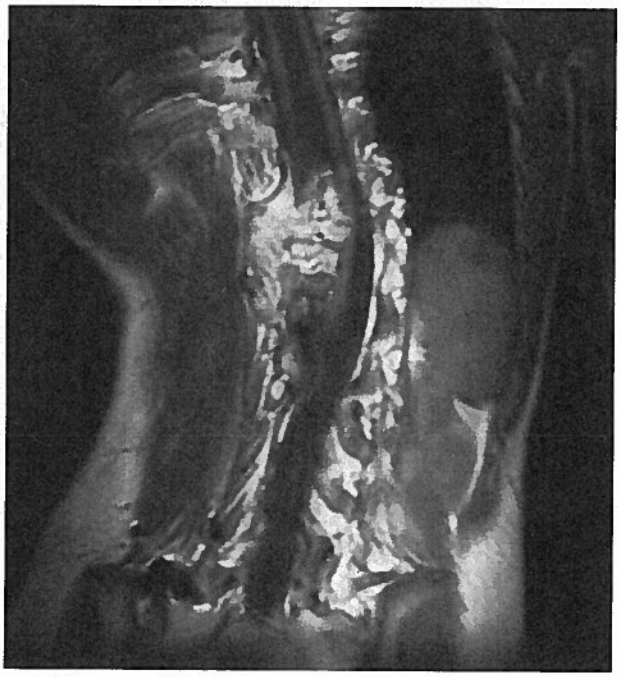

B

Figure 12–2 **(A)** A 12-year-old girl who presented with a 33-degree progressive congenital scoliosis due to mixed anomalies (both formation and segmentation defects). **(B)** A coronal section of her MRI showing a split spinal cord with the two parts passing around a large midline bony mass (diastematomyelia). She was completely normal neurologically.

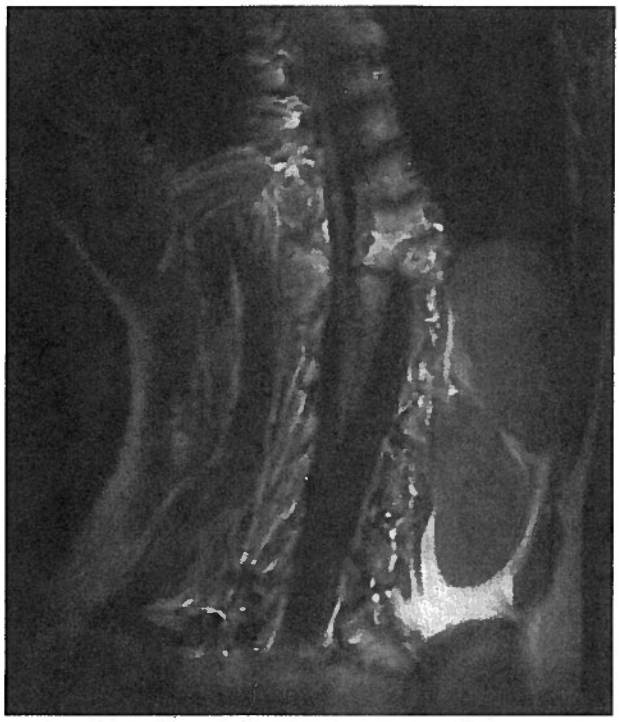

C

Figure 12–2 *(Continued)* **(C)** Another "slice" of her MRI showing the left hemicord and the coming together of the two halves to form a normal conus.

♦ Nonoperative Treatment

Periodic Observation

Periodic observation is one of the most important things we can do. If a patient comes to us with a mild deformity (one not needing immediate brace or surgical treatment), we must follow the patient to determine the evolution of the deformity and its related clinical problems. How often should we see the patient? If in a time of rapid growth (age birth to 4 years and the pubertal growth spurt), the child should be seen every 6 months for both clinical and radiologic evaluation. In the "slow growth" time, visits can be once a year. The neurologic examination should be repeated on each visit, because a child can go from normal to abnormal during that time. Serial photographs can be very helpful, especially for head tilt problems and rib prominence problems. The x-ray should be taken the same way, either standing or supine so that a fair comparison can be made. The x-ray films must be very carefully measured because the congenital spine is not as easy to measure as an idiopathic scoliosis.

The physician must always look at the current film, that past visit film, *and the original film* on every visit. Because there may be only a 6-degree change in a year, that means there will be only a 3-degree change each 6 months, a difference that is easy to overlook. Some surgeons have stated that the measurement accuracy is very poor, but we have found that if great care is taken, the accuracy is equal to that in idiopathic scoliosis.[11]

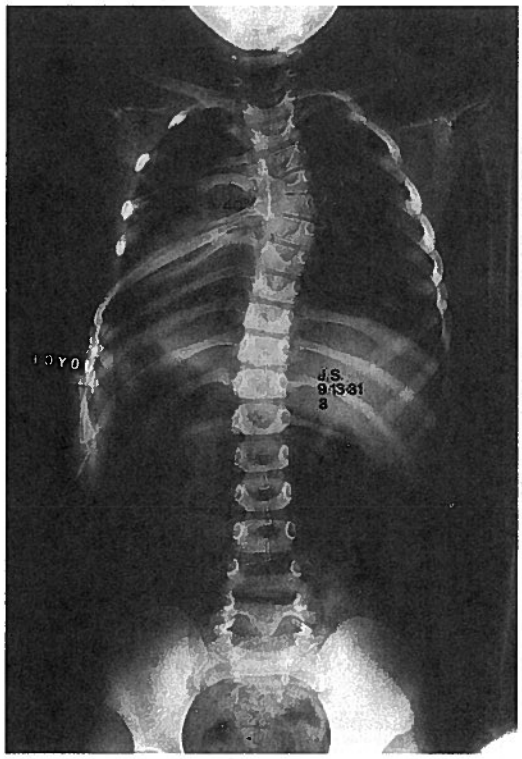

A

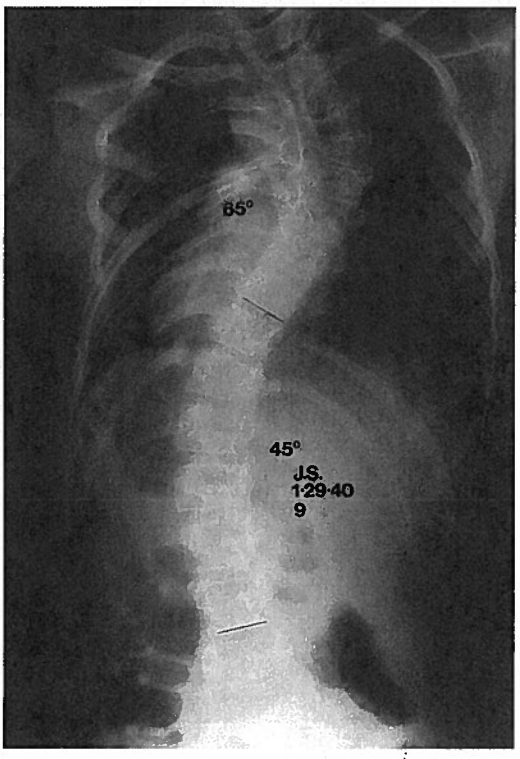

B

Figure 12–3 **(A)** A 3-year-old girl with a 40-degree congenital scoliosis due to a unilateral unsegmented bar at T3-T6. No treatment was given. **(B)** The same patient at age 9; the congenital curve now 65 degrees with a thoracolumbar compensatory curve of 45 degrees.

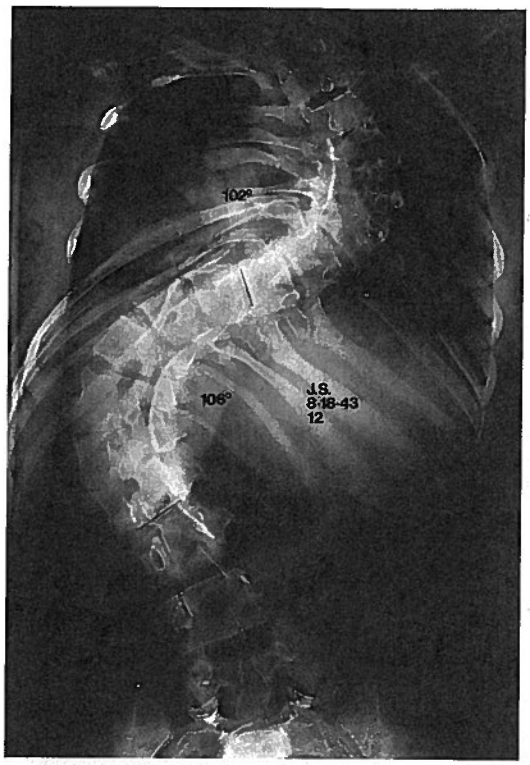

C

Figure 12–3 (*Continued*) **(C)** By age 12, her congenital curve was 102 degrees and the lower compensatory curve 106 degrees. From Winter RB. Congenital Deformities of the Spine. New York: Thieme-Stratton Inc.; 1983. Reprinted by permission.

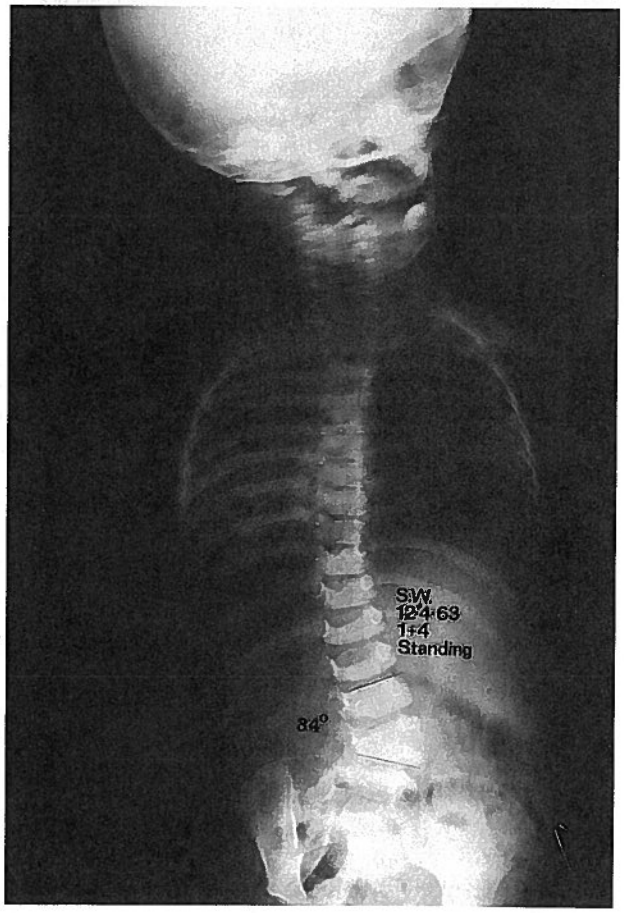

A

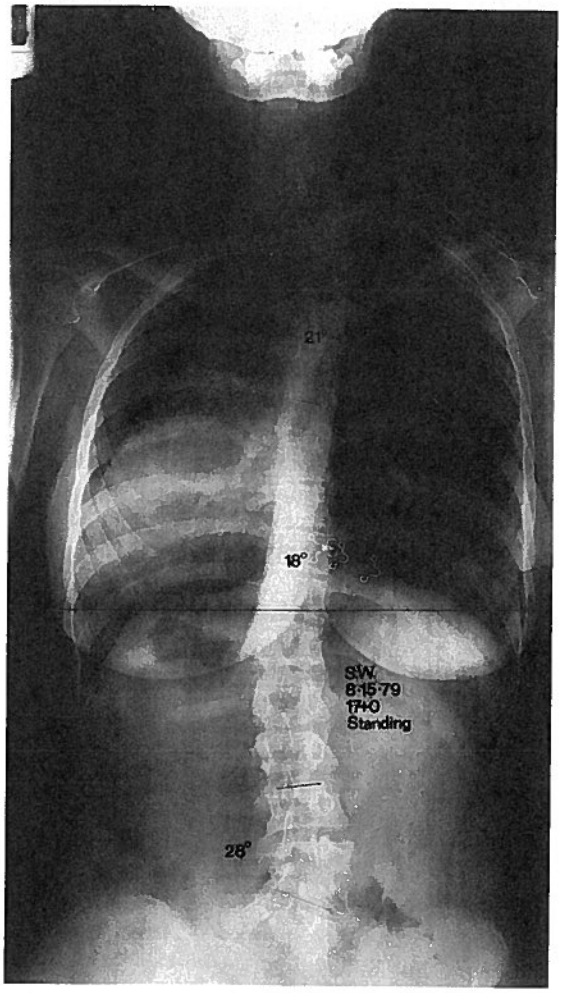

B

Figure 12–4 **(A)** This 1-year-old girl was noted to have a 34-degree lumbar congenital scoliosis due to a semisegmented hemivertebra at L3. Note also the asymmetric development of S1. **(B)** She was followed without any active treatment. At age 17, the lumbar scoliosis measured 28 degrees. From Winter RB. Congenital Deformities of the Spine. New York: Thieme-Stratton Inc.; 1983. Reprinted by permission.

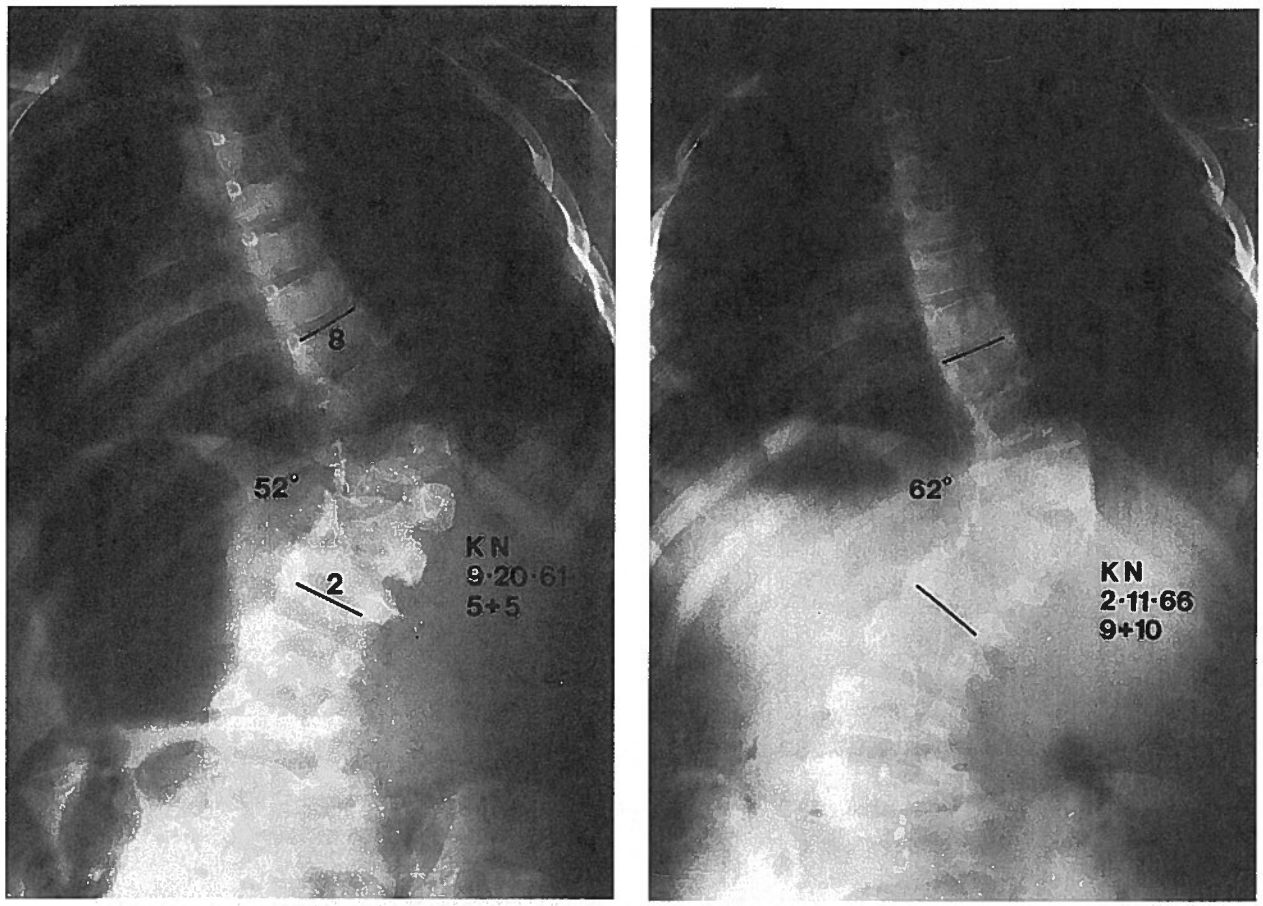

A B

Figure 12–5 **(A)** This 5-year-old girl presented with a 52-degree congenital scoliosis due to a fully segmented hemivertebra at L1 and a semi-segmented hemivertebra at T9, both on the right. Surgical treatment should have been done at this time. **(B)** Despite bracing, the curve increased to 62 degrees by age 9. Surgery is clearly indicated, but what kind would be best, a posterior fusion, a combined anterior and posterior fusion, or hemivertebra excision and fusion?

Periodic observation is thus an important clinical skill and is of great value to the patient. If the curve is definitely not progressing, the patient and family can be reassured they are on a good course. If the deformity is found to be progressive, then both patient and doctor know that there is a problem and positive action should be taken. There is nothing worse than to see a patient who has been allowed to progress without action having been taken.

Orthoses

There are many physicians who say that bracing is totally useless for congenital scoliosis. This is because bracing is *seldom* useful, but that does not mean it is *never* useful. There are situations in which we have successfully braced children with scoliosis but never with congenital kyphosis or congenital lordosis.[12]

Where bracing can be useful is in flexible curves (rare, but possible). These are curves where there are scattered anomalies separated by mobile disks, curves where there are anomalies at the apex but lots of mobile segments above and below the apex, or in curves where the anomalies are at the upper end of the curve, but the lower half of the curve consists of mobile segments. Also should be mentioned the treatment of compensatory curves, curves composed of normal vertebrae and disks, but which can become progressive and severe beyond even the primary curve. Flexibility of a curve is determined both clinically and by fulcrum bend films. Bracing can also be used for correction of lateral decompensation, in which case a trochanteric extension is used on the side to which they are decompensated.

Another use for bracing is for head tilt, usually due to a congenital scoliosis with its apex at the cervico-thoracic junction. In this case, a cervicothoracic lumbosacral orthosis (CTLSO, Milwaukee brace) is used with a lateral head control pad. Thoracic curves should always be treated with a CTLSO to provide maximal thoracic expansion. A TLSO can be used, but only for lumbar curves **(Fig. 12–5)**.

♦ Surgical Treatment

Because a great many patients with congenital scoliosis have a progressive deformity, and because very few of these can be treated orthotically, a large percentage of these patients come to surgery. It is thus relatively easy to say the patient needs

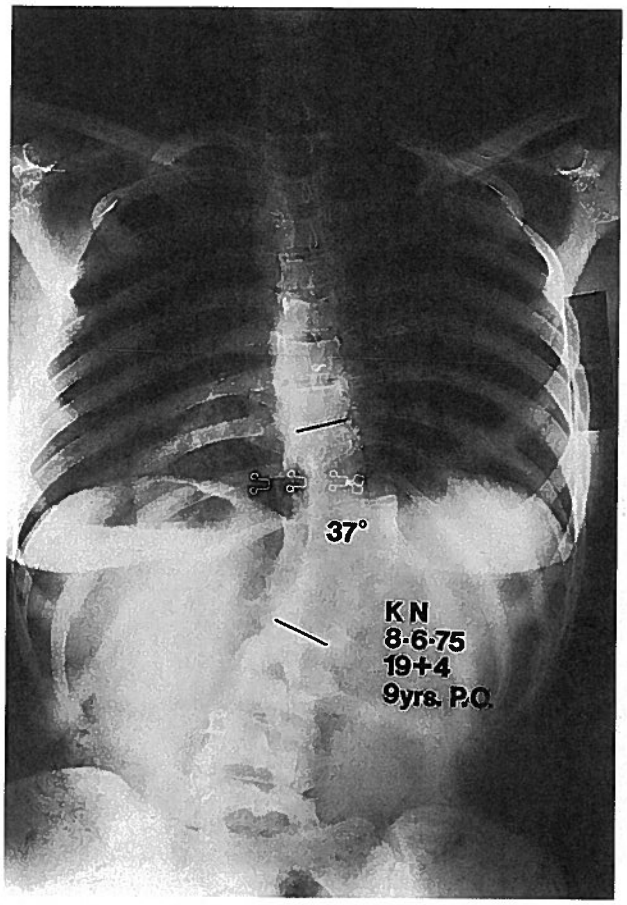

C

Figure 12–5 *(Continued)* **(C)** She had a posterior fusion by Dr. John Moe with cast correction to 37 degrees as seen in this 9-year follow-up image. Hemivertebra excision was not indicated. From Winter RB. Congenital Deformities of the Spine. New York: Thieme-Stratton Inc.; 1983. Reprinted by permission.

surgery, but what type of surgery and when are the big questions. There are five basic types of surgery, all of which have their role. It is the sign of a skilled surgeon that he or she knows which of the procedures is best, and at what age to do it.

Posterior Spinal Arthrodesis

This is the time-tested and classic procedure against which all others must be compared. It can be done either with or without instrumentation, depending on several variables. The appropriate length of fusion is selected based on the preoperative clinical and radiologic evaluation. An MRI should be done if not done previously to detect any hidden dysraphic lesion.

The spine is exposed with great delicacy because the surgeon would not want to fall through any undetected posterior element defect. Any facet joints are excised, the posterior elements decorticated, and autogenous bone graft added. If no instrumentation is used, the wound is closed and a cast or brace applied postoperatively to achieve correction and immobilization.

One indication for posterior-only surgery is the child whose curve appeared or progressed only late in the growth cycle. This would be similar to the adolescent idiopathic patient who is past the pubertal growth spurt and there is no risk of crankshafting. Such a patient would have large enough vertebrae that instrumentation could readily be used.

Another indication is the very young child with a rigid deformity such that there are few growth plates anteriorly. Such a child has little risk of crankshafting so that an anterior procedure would be unnecessary. Such a young child with a rigid deformity would likely have bones so small or anomalies so severe that instrumentation would not be possible. In a major article reviewing a large number of posterior spine fusions, only 5 degrees more correction was achieved with instrumentation than with casting.[13]

Another indication for posterior-only surgery is the child with a cervico-thoracic deformity, usually due to a hemivertebra at the cervico-thoracic junction. Curves in this area do not crankshaft, and anterior surgery is complex. These should have prompt surgery because even a small amount of curvature can produce an unsightly deformity with head tilt and shoulder elevation. Our best results have come with an early posterior fusion, autogenous bone grafting, no instrumentation, and postoperative use of a CTLSO with a trapezius pad and head pad.

Finally, it should be emphasized that surgery for congenital scoliosis carries a higher risk of paralysis than other etiologies of scoliosis. It is the firm belief of this author that hypotensive anesthesia should never be used, and that if instrumentation is to be used, spinal cord monitoring must be done, including motor monitoring. Somato sensory evoked potentials (SSEP) monitoring alone has proved to have too many false negatives **(Fig. 12–5)**.

Combined Anterior and Posterior Arthrodesis

There are two reasons why a surgeon would choose to do a combined anterior and posterior arthrodesis. The first is to achieve better correction and rate of fusion through the removal of disks, and the second is to remove the growth plates to prevent crankshafting. These two desirable goals are, of course, offset by the potential risks of the anterior procedure. As the crankshafting concept has become better understood, its prevention is important because the problem is far better prevented than treated in hindsight.

Studies of the crankshafting problem in congenital scoliosis have been done at several centers. Kesling et al. in 2003 presented the largest and most recent study.[14] It is far less common than in posterior fusion for infantile or juvenile idiopathic scoliosis.

Combined anterior and posterior fusion is usually done under a single anesthetic. Instrumentation may or may not be used, depending on the child's age, bone density, bone anomalies, and availability of pediatric-sized implants. Once again, hypotensive anesthesia should not be used. If implants are planned, then high-quality spinal cord monitoring should be used.

Patients with the highest likelihood of progression (see section on "Natural History") have the strongest discrepancy of growth potential on one side versus the other. They are thus the ones most in need of ablation of the convex anterior growth plates. It is thus perfectly appropriate to do a combined anterior and posterior fusion for a 1-year-old child with a unilateral unsegmented bar with or without a convex hemivertebra. This is a prophylactic or preventive surgery and fully justified in view of the terrible natural history if left untreated.

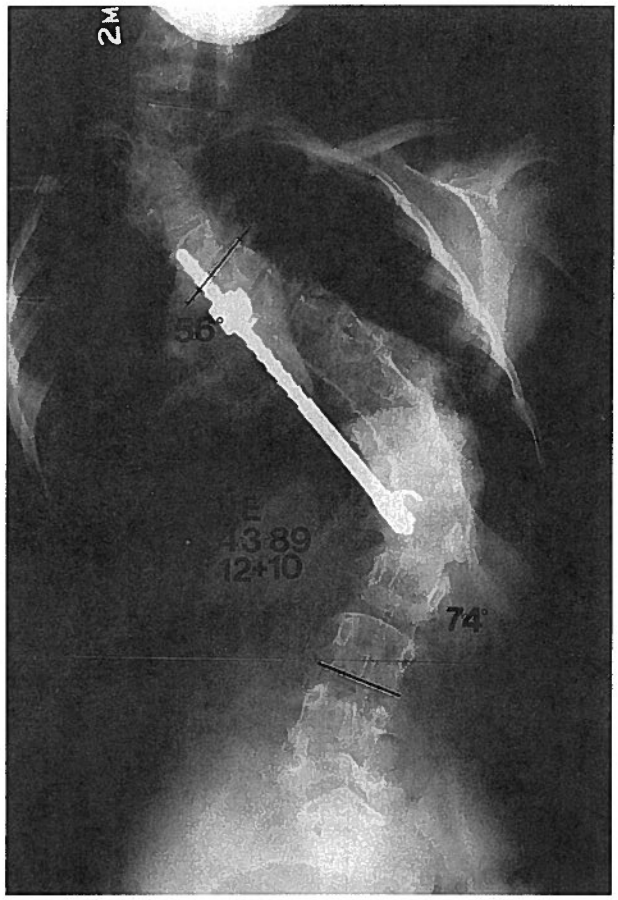

A

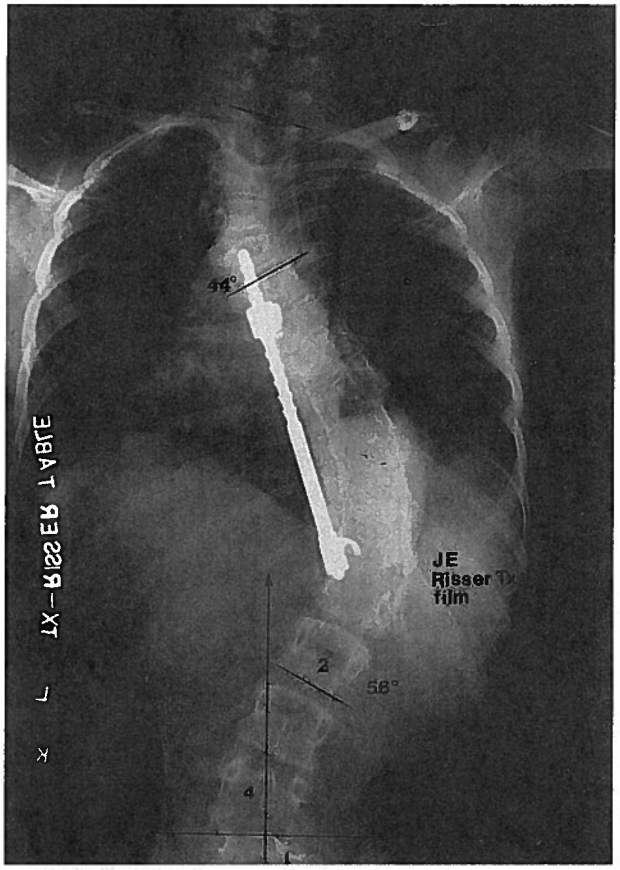

B

Figure 12–6 **(A)** This 12-year-old girl had been operated elsewhere at age 3 for a congenital scoliosis due to a hemivertebra at T10 (posterior fusion with Harrington rod). She presented to this author with curve "adding-on" to L4, crankshafting in the fused area, and a T1-T5 congenital scoliosis due to a hemivertebra at T3 on the left. **(B)** An x-ray image taken on a Risser frame in strong traction showed improvement of the high curve to 44 degrees, the lower curve to 56 degrees, and a nice balancing of her thorax over the pelvis, and level shoulders.

How many degrees of curvature justify surgery? We are accustomed to using 50 degrees as an indication for surgery in adolescent idiopathic scoliosis, but that does not hold true for the congenital spine. In the idiopathic spine we can afford to wait until 50 degrees because we can easily correct the curve to 25 degrees at surgery, a very acceptable amount. The congenital spine is usually quite stiff and we cannot expect to get a 50% correction. Therefore, if we want to end up at 25 degrees, we need to operate when the curve is 30 degrees.

We do not operate when a curve reaches a certain magical number of degrees. We operate when (a) the curve is already unacceptable at first visit, (b) we can predict accurately the natural history and we do not wait for progression, or (c) our careful observational management has detected progression and we wish to stop it from getting worse **(Fig. 12–6).**

Combined Anterior and Posterior Hemiepiphyseodesis and Hemiarthrodesis

This procedure is designed to take advantage of any residual growth tissue in the concavity of the curve. It is thus inappropriate in a patient with a concave unilateral unsegmented bar. The surgeon exposes the anterior extent of the curve (the whole curve must be done, not just the apical segments), removes only the convex half of the disks and end plates, and adds autogenous bone chips or an inlaid rib graft.

Posteriorly, only the convex side is exposed (exposure of the concave side will result in spontaneous fusion), decorticated, and bone graft added. Implants are not customarily used, although on occasion we have used a subcutaneous or subfascial rod in the concavity. A corrective cast is then applied, usually under the same anesthetic. Casting is continued for 6 months, at which time the fusion is usually solid. No external brace or cast is needed thereafter.

This procedure is best done in children under 5 years of age and for curves under 50 degrees. The results have been published by several authors including Marks et al.,[15] Dubousset et al.,[16] and Winter et al.[17] Three outcomes are possible: (a) gradual improvement of the curve, (b) an arthrodesis effect with stopping of progression but no improvement, and (c) failure, as defined by continued progression (usually due to pseudarthrosis or too short an area of fusion) **(Fig. 12–7).**

Hemivertebra Excision and Fusion

Hemivertebra excision is an old procedure, first done by Royle of Australia in 1921. As with most surgeries, the issues are (a) when is it indicated and (b) when is the ideal age?

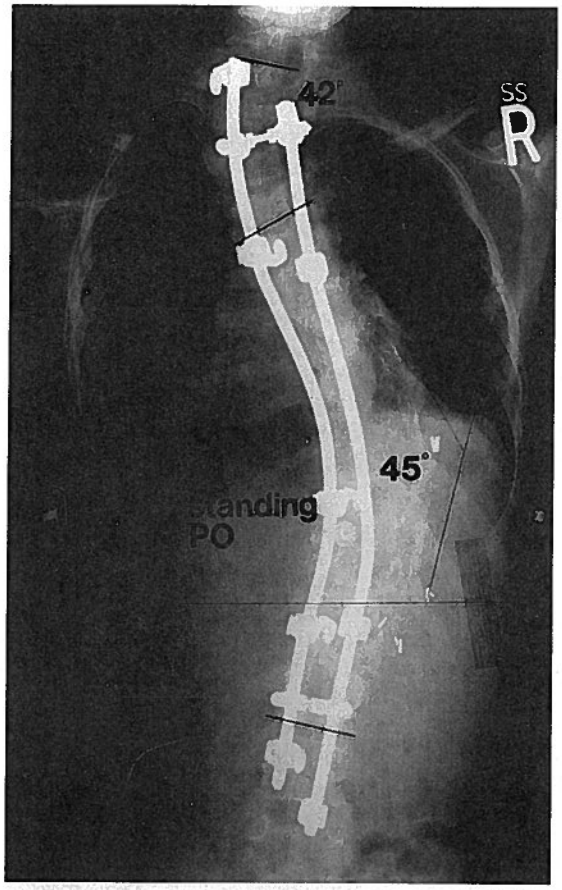

C

Figure 12–6 *(Continued)* **(C)** An anterior multilevel diskectomy and fusion was done from T8 to L2 and under the same anesthetic a posterior fusion from T1 to L4 using a third-generation hook and rod system.

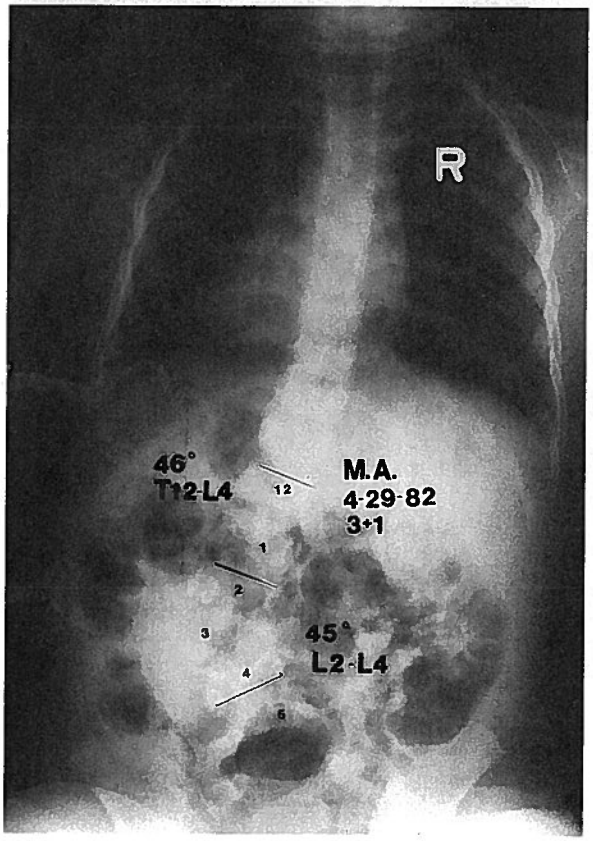

A

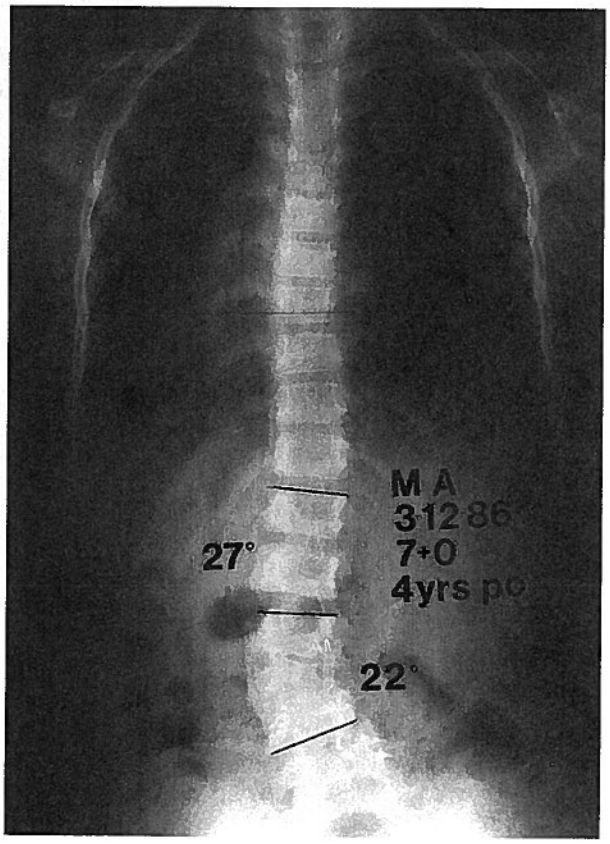

B

Figure 12–7 **(A)** A 3-year-old child with a 45-degree L2-L4 congenital scoliosis due to a left L3 fully segmented hemivertebra. Note the very good torso-pelvic relationship. **(B)** A 4-year follow-up image after a convex hemiepiphyseodesis of L3, L3, and L4. Hemivertebra excision was not necessary.

Recent advances in surgical technique, pediatric-sized implants, and spinal cord monitoring have made the procedure more popular, but there continues to be major disagreement about when the procedure is indicated.

There is little disagreement when it comes to a hemivertebra at the lumbosacral junction, which is producing a progressive lateral deviation of the spine as the hemivertebra grows. Left untreated, these not only cause the lateral deviation, but there will also develop a compensatory curve above which will become structural with time. Thus, the ideal time to do the excision is before this compensatory curve starts to develop.

Another indication is a midlumbar hemivertebra causing a fixed decompensation, which does not correct to midline on lateral bending. In both of these situations, the risks are lower because the surgery is being done at the cauda equina level, not the spinal cord level. A hemivertebra at the thoracolumbar junction, with several good disks below, will not show decompensation and can easily be managed by less risky procedures such as combined anterior/posterior fusion or anterior/posterior hemiarthrodesis and hemiepiphyseodesis **(Fig. 12–7)**.

One recent development is technical: the performance of the excision from posteriorly only using a transpedicular approach rather than the traditional anterior/posterior approach.[18–20] It is easy to take out the pedicle and to decancellate the body of the hemivertebra but not so easy to remove the disks above and below the bone, especially in the concavity. Such surgery should always avoid any retraction of the cord, and it should be done with normotensive anesthesia and with spinal cord monitoring.

It is highly desirable to use some kind of implant to close the wedge, either laminar hooks or pedicle screws. The screws are ideal because they are farther from the midline and hopefully do not invade the spinal canal. Casting until the fusion is solid is needed. If the excision is low in the lumbar spine, a cast with a leg extension is needed.

The neurologic risk must also be considered. Nerve root compression can occur when the two pedicles are brought close to each other. This happened in three cases reported from our center.[21] Nerve root stretch on the opposite side can also occur. Spinal cord injury has also occurred, one case being particularly sad because the patient did not need the procedure in the first place **(Fig. 12–8)**.

Thoracic Expansion Surgery

This is the newest procedure used in certain cases of congenital scoliosis where there are multiple synostoses of the ribs on one side of the thorax. This prevents the normal expansion of the lungs and can lead to severe deformity and early death from pulmonary failure. The procedure was developed by Dr. Robert Campbell of San Antonio, Texas.[22]

The operation consists of an exposure of the concave chest wall, division of the rib synostoses, and insertion of a titanium

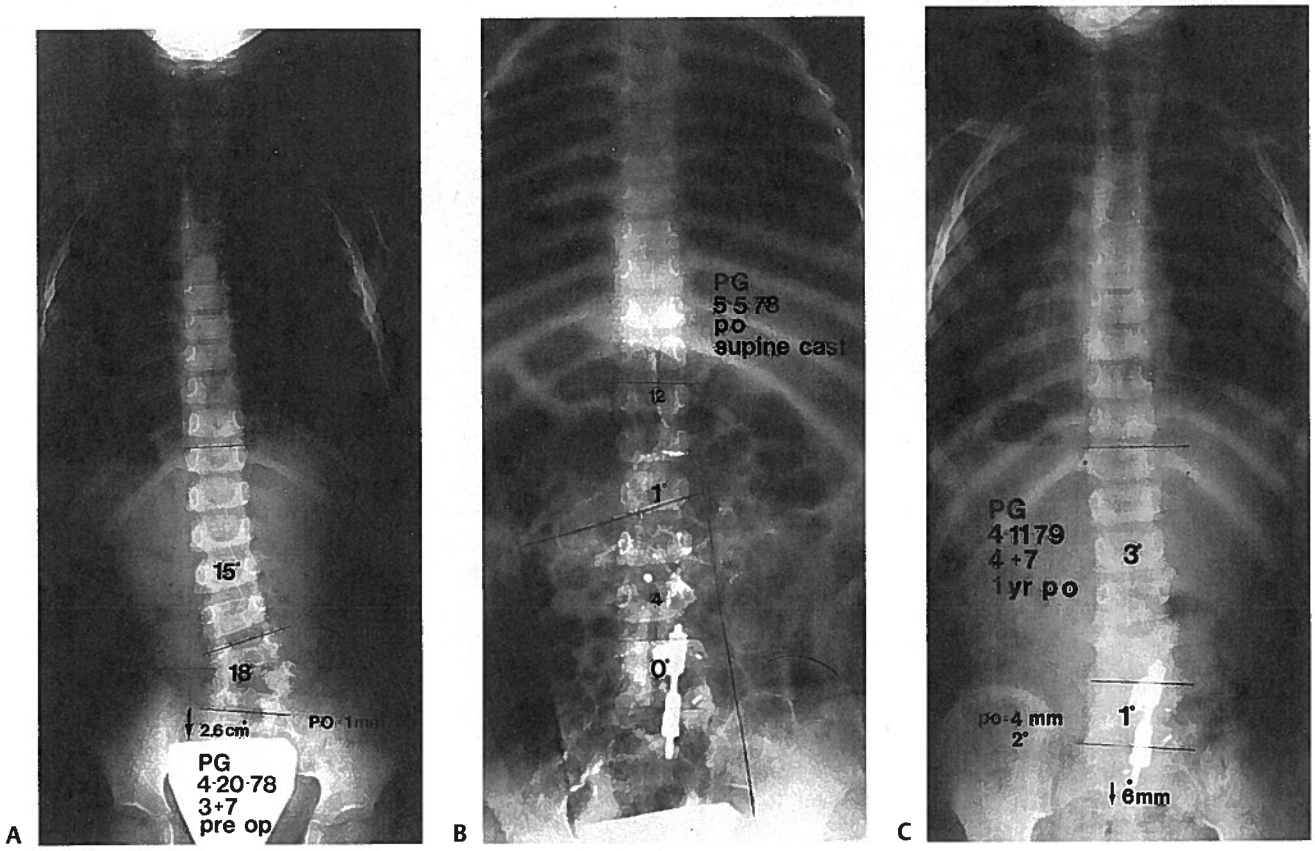

Figure 12–8 **(A)** This 3-year-old girl had a congenital scoliosis and lateral decompensation due to a fully segmented right L5 hemivertebra. **(B)** The hemivertebra was excised via a combined anterior/posterior approach in May 1978. A small Harrington compression rod was used to close the gap. Full correction was obtained. **(C)** At a 1-year follow-up, the fusion is solid and the correction maintained. She was followed until age 18 without any problems.

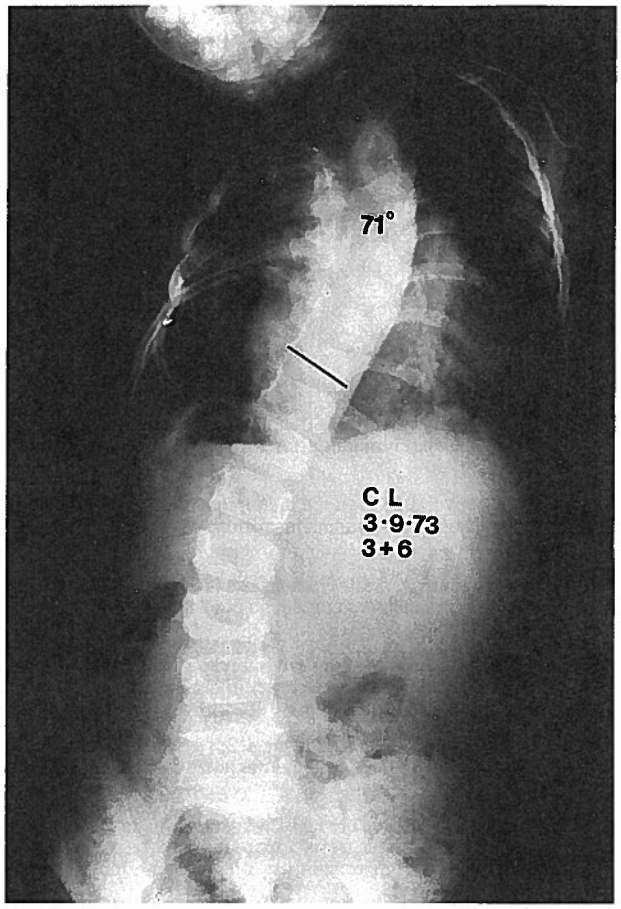

A

B

Figure 12–9 **(A)** This 3-year-old girl presented with a progressive congenital scoliosis of 71 degrees and marked constriction of the left hemithorax due to the scoliosis plus multiple rib synostoses. Vertebral detail is poor on this standing film. **(B)** This supine bend film shows far better bony detail. The arrow points to the medial wall of the unilateral unsegmented bar and is lateral to which a gap in the rib synostoses. This would be an ideal case for an expansion implant plus osteotomy of the unsegmented bar. From Winter RB. Congenital Deformities of the Spine. New York: Thieme-Stratton Inc.; 1983. Reprinted by permission.

implant that attaches to the uppermost ribs and either the lowermost ribs or the upper lumbar spine. This implant can be periodically lengthened, providing increasing thoracic volume. This implant can also have a positive effect on the scoliosis, providing there are some mobile segments within the spine. Just how long the device can be used without spine fusion has yet to be determined, but it stands to reason that if the curvature worsens despite the device, then fusion is indicated.

As of this writing, this implant is still under FDA investigation and not generally available **(Fig. 12–9)**.

◆ Conclusion

Congenital scoliosis is the third most common cause of scoliosis, behind idiopathic scoliosis and neuromuscular scoliosis. It is more complex because the deformities tend to occur at a much younger age, are more variable in their presentation, are associated with many other congenital anomalies, and are usually more rigid. An understanding of the natural history is absolutely critical because many decisions regarding treatment are based solely on natural history. It is often stated that the performance of a combined anterior/posterior arthrodesis in a 12-month-old child is radical surgery. If, however, that child has a unilateral unsegmented bar with a contralateral hemivertebra, such surgery is conservative.

In addition to the specific references included previously, several good general publications are available.[23–25]

I must once again emphasize the importance of a thorough and complete general examination in view of the very high percentages of associated anomalies including the neurological system, the urogenital system, the heart, and other organs.

Surgery is often necessary for congenital scoliosis, and it can be easy to determine when that surgery is indicated, based usually on documented curve progression. What is difficult is to decide which of the five major surgical approaches is most appropriate for the specific patient at the particular age.

In the past, many children were denied appropriate surgery based on the very "old fashioned" concept that surgery should never be done until growth had been completed. Nothing could be further from the truth.

The basic conflict is the need for fusion surgery to stop the relentless progression of the curvature and the desire to allow torso growth. At first, these two goals seem in total contradiction to one another. One must remember, however, that in most situations, the basic problem is that one side of the spine is not growing due to the congenital absence of growth tissue. The fusion then stops the convex growth, thus stopping the curve progression. Although the ultimate torso length may be somewhat short, it will be longer than if the curve is allowed to progress. The continued convex growth does not give torso length at all. It just gives deformity.

References

1. Winter RB. Congenital Deformities of the Spine. New York: Thieme-Stratton; 1983
2. Winter RB, Moe JH, Lonstein JE. A review of family histories in patients with congenital spinal deformities. Paper presented at: Scoliosis Research Society; September 1982; Denver, CO
3. Wynne-Davies R. Congenital vertebral anomalies: aetiology and relationship to spina bifida cystica. J Med Genet 1975;12:280–288
4. Beals R, Robbins JR, Rolfe B. Anomalies associated with vertebral malformation. Spine 1993;18:1329–1332
5. Basu PS, Elsebaie H, Noordeen MH. Congenital spine deformity: a comprehensive assessment at presentation. Spine 2002;27:2255–2259
6. MacEwen GD, Winter RB, Hardy JH. Evaluation of kidney anomalies in congenital scoliosis. J Bone Joint Surg Am 1972;54:1451–1454
7. Kuhns JG, Hormel RS. Congenital scoliosis. Arch Surg 1952;65:250–262
8. Winter RB, Moe JH, Eilers VE. Congenital scoliosis; a study of 234 patients treated and untreated. J Bone Joint Surg Am 1968;50:1–47
9. McMaster MJ. Congenital scoliosis caused by a unilateral failure of vertebral segmentation with contralateral hemivertebrae. Spine 1998;23:998–1005
10. McMaster MJ, Ohtsuka K. The natural history of congenital scoliosis, a study of 251 patients. J Bone Joint Surg Am 1982;64:1128–1147
11. Facanha-Filho FA, Winter RB, Lonstein JE, et al. Measurement accuracy in congenital scoliosis. J Bone Joint Surg Am 2001;83:42–45
12. Winter RB, Moe JH, MacEwen GD, Peon-Vidales H. The Milwaukee brace in the non-operative treatment of congenital scoliosis. Spine 1976;1:85–96
13. Winter RB, Moe JH, Lonstein JE. Posterior spinal arthrodesis for congenital scoliosis: an analysis of the cases of 190 patients five to nineteen years old. J Bone Joint Surg Am 1984;66:1188–1197
14. Kesling KL, Lonstein JE, Denis F, et al. The crankshaft phenomenon after posterior spinal arthrodesis for congenital scoliosis: a review of 54 patients. Spine 2003;28:267–271
15. Marks DS, Sayampanathan SRE, Thompson AG, Piggott M. Long-term results of convex epiphyseodesis for congenital scoliosis. Eur Spine J 1995;4:296–301
16. Dubousset J, Katti E, Seringe R. Epiphyseodesis of the spine in young children for congenital spine malformations. J Pediatr Orthop 1993;1B:123–130
17. Winter RB, Lonstein JE, Denis F, Sta-Ana de la Rosa H. Convex growth arrest for progressive congenital scoliosis due to hemivertebrae. J Pediatr Orthop 1988;8:633–638
18. Ruf M, Harms J. Posterior hemivertebra resection with transpedicular instrumentation: early correction in children aged 1–6 years. Spine 2003;28:2132–2138
19. Shono Y, Abumi K, Kaneda K. One-stage posterior hemivertebra resection ad correction using segmental posterior instrumentation. Spine 2001;26:752–757
20. Nakamura H, Matsudaz H, Konishi S, Yamano Y. Single stage excision of hemivertebrae via the posterior approach alone for congenital spine deformity: follow-up longer than 10 years. Spine 2002;27:110–115
21. Holte D, Winter RB, Lonstein JE, Denis F. Excision of hemivertebrae and wedge resection in the treatment of patients with congenital scoliosis. J Bone Joint Surg Am 1995;77:159–171
22. Campbell RM Jr. Congenital scoliosis due to multiple vertebral anomalies associated with thoracic insufficiency syndrome. In: Drummond DS, ed. State of the Art Reviews. Philadelphia: Hanley and Belfus; 2000:209–218
23. Lonstein JE. Congenital deformities of the spine. In: Drummond DS, ed. State of the Art Reviews. Philadelphia: Hanley and Belfus; 2000:191–208
24. Winter RB, Lonstein JE, Boachie-Adjei O. Congenital spine deformity. Instructional Course Lecture, presented at American Academy of Orthopaedic Surgery. J Bone Joint Surg Am 1996;78:300–311
25. McMaster MJ. Congenital scoliosis. In:Weinstein S, ed. The Pediatric Spine, Principles and Practice. New York: Raven Press; 1994:227–244

Chapter 13

Infantile Scoliosis

Michael T. Rohmiller and Behrooz A. Akbarnia

Initially, James divided idiopathic scoliosis into three categories based on the age at presentation: infantile (0 to 3 years), juvenile (4 to 9 years), and adolescent (10 years to skeletal maturity).[1] At the time of the categorization, it was believed that the three groups corresponded with the periods of increased spinal growth velocity and thus increased risk of scoliosis progression. However, later published data demonstrated that spinal growth velocity is relatively constant or even declines between 5 and 10 years of age.[2–4] Due to the rarity of juvenile onset scoliosis and the data demonstrating decreased spinal growth velocity during this age frame, Dickson recommended that idiopathic scoliosis be divided into two categories: early onset (0 to 5 years) and late onset (after the age of 5).[5,6]

The age of onset remains important as a prognostic tool because curves that demonstrate a significant thoracic deformity before age 5 will have a higher likelihood of cardiopulmonary abnormalities such as restrictive lung disease, pulmonary hypertension, cor pulmonale, and thoracic insufficiency syndrome.[7–10] In addition, the treatment of children with early onset scoliosis has proved to be difficult. Standard modalities used in older patients with scoliosis such as orthotic treatment or spinal fusion have limited roles due to the potential deleterious effects on the growth of the spine, lungs, and thoracic cage. This chapter will focus on the evaluation, treatment, and outcomes of patients diagnosed with infantile (early onset) idiopathic scoliosis.

♦ Natural History

Infantile idiopathic scoliosis is a curvature of the spine in the coronal plane of a child in the first 3 years of life for which no identifiable cause is known. Unlike idiopathic scoliosis, there are multiple described etiologies of curvature of the spine in infants. Common causes include congenital vertebral or chest wall anomalies, neuromuscular (cerebral palsy, myelomeningocele, and muscle disease), syndromic scoliosis such as neurofibromatosis, and scoliosis due to intraspinal pathology such as tumor, diastomatomyelia, syrinx, or tethered cord. After eliminating all possible causes of early onset scoliosis, a child is diagnosed with infantile idiopathic scoliosis.

Infantile idiopathic scoliosis is relatively rare and accounts for less than 1% of idiopathic scoliosis seen in the United States. The incidence of infantile idiopathic scoliosis is slightly higher in Europe.[11,12] Infantile scoliosis presents as a left-sided mid to low thoracic curve in 75 to 90% of cases.[2,11,13] Unlike late onset idiopathic scoliosis, boys are affected more frequently than girls with a 3:2 ratio.[11,13] Fortunately, the prognosis for infantile scoliosis also differs from late onset. In the initial description of infantile scoliosis by James, he described a curve that "developed rapidly and relentlessly, causing the severest form of orthopaedic cripple with dreadful deformity, marked dwarfing and shortening of life."[14] The original series reported that 4 out of 33 cases resolved with the remaining developing major deformities.[14] In the following years, he added more patients to his study and ultimately reported on a total of 212 patients with infantile scoliosis. In the larger group, 36% of the cases resolved spontaneously.[11] Similarly, Scott and Morgan reported a significant likelihood of progression in infantile scoliosis curves.[13] Within 10 years, several authors reported an increase in the frequency of spontaneous resolution.[15,16] Later, Ceballos et al. reported a 74% rate of resolution.[17] Today, as in the study by Lloyd-Roberts and Pilcher, more than 90% of cases will spontaneously resolve without the need for treatment.[18] However, one must be aware that girls who present with a right-sided thoracic infantile curve have a worse prognosis and do not follow the typical rate of spontaneous resolution.[19]

Since the initial description almost 75 years ago, the number of cases of infantile scoliosis has declined.[20] Further investigation reveals possible factors responsible for the difference in incidence rates. Infantile scoliosis was initially attributed to intrauterine molding. Browne hypothesized that intrauterine molding caused not only infantile scoliosis but was also responsible for the associated crowding deformities. In his series, 83% of patients exhibited some form of intrauterine crowding deformity such as plagiocephaly, plagiopelvy, decreased hip abduction, or rib molding.[21,22] Mehta subsequently agreed that intrauterine molding was responsible for infantile scoliosis.[23] The view has subsequently been refuted due to the absence of scoliosis at birth. Although intrauterine molding is likely responsible for the other deformities that are occasionally present at birth, the association with scoliosis has not been shown. The second hypothesis to explain infantile scoliosis was proposed by Mau.[15] Mau believed that prolonged oblique supine positioning in the crib was responsible for infantile scoliosis. The focused pressure from positioning a child that is unable to roll may induce scoliosis, plagiocephaly, hip adduction, and pelvic molding. Wynne-Davies' data also supports the postnatal pressure theory as she observed that 97 of 134 cases developed scoliosis and plagiocephaly within the first 6 months of life (time during which children are unable to reposition).[24] The rate of plagiocephaly in children without scoliosis is 28%.[25] Given that European children were sleeping supine whereas American children were positioned prone, this may also account for the difference in incidence of infantile scoliosis between the two continents. A new study evaluating the incidence of infantile scoliosis in children in Europe and North America is needed as the current recommendations from the American Academy of Pediatrics advocate supine sleeping to decrease the risk of sudden infant death syndrome.[26]

In addition to her contributions in other aspects of pediatric orthopaedics, Wynne-Davies also described several associations with infantile scoliosis. She confirmed the predominance of left-sided thoracic curves and noted that most were diagnosed between 1 and 6 months of age. Because very few curves were present at birth, she also refuted the claim that these curves were congenital in nature. However, she has hypothesized that intrauterine molding plays a role similar to congenital muscular torticollis. Although torticollis is rarely present at birth, it is believed to be due to intrauterine molding and presents after the body resumes the intrauterine shape in the first months of life. In her study population, 13% of male infants with progressive curves were mentally retarded, and 7% of males had concomitant inguinal hernias. Progressive curves were commonly associated with advanced maternal age. The genetics of infantile scoliosis were similar to that of late onset scoliosis in which parents or siblings of affected children are 30 times more likely than controls to have scoliosis.[24] Mehta's data concurred with that of Wynne-Davies. She noted that infants with hypotonia were unable to resist deformation compared with children with normal tone.[23] Connor reported that children with congenital malformations, including hiatal hernia, were at increased risk of progression.[27]

♦ Anatomic and Physiologic Variants of Infantile Scoliosis

One cannot attempt to evaluate and treat patients with infantile scoliosis without an understanding of the anatomic involvement of the condition. Infantile scoliosis affects the growth of the chest wall, spine, and lung parenchyma. Normal development of the lungs requires adequate space in the thoracic cavity. When inadequate space is available, abnormalities occur based on the time at which the restriction occurs. If the compression is prenatal, major airway development is abnormal. This is most commonly seen with congenital diaphragmatic hernia and resultant pulmonary hypoplasia. This entity does not occur even in severe cases of congenital scoliosis. When the restriction develops after birth and before age 8, the alveoli are affected. Davies and Reid have shown that the alveoli are normal in size but reduced in number.[28] This scenario occurs in infantile scoliosis and the reduction in alveoli is greater with earlier presentation.

Major airway development is complete at birth, but limited bronchioles and alveoli exist. It is estimated that 20 million alveoli are present at birth. Normal alveoli develop rapidly during the first year of life, increasing in both size and volume. By age 4, 250 million alveoli have developed, and the full adult alveoli development is complete by age 8. Similarly, by age 8, the respiratory tree has matured to the final adult composition with 23 generations.

Spine and thoracic cage growth occur simultaneously with the pulmonary system. Dimeglio demonstrated that the spine from T1 to S1 grows an average of 2 cm per year from birth to age 5. Two thirds of the final sitting height is achieved by 5 years of age. Between age 5 and 10, deceleration in the rate of growth occurs followed by a second increase after age 10 during the pubertal growth spurt. However, the growth velocity is fastest during the initial phase between birth and age 5.[4] The volume of the thoracic cage also increases during early life although more slowly than the spine or lungs. The thoracic volume increases long after the pulmonary development has ceased. Full adult thoracic volume is attained by age 15 in males and females. At birth, the thoracic volume is 6% of final adult volume. At age 5, the volume has increased to 30% and reaches 50% of the adult volume by age 10.[4]

Given that the growth of the spine, chest wall, and pulmonary system are rapid during the first 5 years of life, conditions that interfere with normal development of one system have serious ramifications on the development of related structures. Scoliosis that presents during this time has a higher chance of cardiopulmonary compromise. Early onset scoliosis impairs the normal development of the alveoli and pulmonary vessels. The abnormal lung parenchyma and vasculature result in ventilation defects.[29] The severity of pulmonary compromise is related to the age of onset of scoliosis. Patients who develop scoliosis at a younger age will have more severely involved lungs.[7] Restrictive lung disease with decreased vital capacity (VC) and total lung capacity (TLC) and increased residual volume (RV) is seen in patients with early onset scoliosis. Compliance of both the lungs and

thoracic cage are decreased and account for the restrictive pattern. The actual percent decrease in VC is related to the severity of deformity and the age of onset. Early onset curves will have more deleterious effects than similarly severe curves that present after maturation of the pulmonary system. When severe, restrictive pulmonary disease results in pulmonary arterial hypertension and cor pulmonale. The gas exchange is normal in these patients so hypoxemia is related to diminished tidal volumes.[30] Respiratory compromise or failure is common in patients with severe early onset scoliosis, although it frequently presents later in life due to significant pulmonary reserve.[7,8] This situation differs from patients with scoliosis and thoracic insufficiency syndrome that present with pulmonary failure at an early age.[10]

Previous authors have reported that untreated idiopathic scoliosis resulted in cardiopulmonary compromise. Whereas these reports typically described the patients as having adolescent idiopathic scoliosis (AIS), subsequent data indicate that patients with adolescent idiopathic scoliosis are unlikely to develop curves of a magnitude large enough to create life-threatening cardiopulmonary compromise. Close examination of historic papers reveals that many of the patients previously categorized as AIS most likely had infantile scoliosis. Cardiopulmonary compromise relies on incomplete development of the pulmonary system with decreased space available for the lungs. Patients who develop AIS (or late onset scoliosis) have near normal lung and chest wall development. Therefore, the only aspect of the multifactorial formula of cardiopulmonary compromise present is scoliosis, and this is not powerful enough to create cardiopulmonary distress.

♦ Clinical Evaluation

The clinical evaluation of a child with suspected scoliosis or spinal deformity must proceed in a thorough, systematic fashion. A complete history must be obtained prior to physical examination. Prenatal history of the mother including health problems, previous pregnancies, and medications is performed. Birth history of the child should include details such as length of gestation, type of delivery (vaginal or caesarean), birth weight, and complications. Similar to developmental dysplasia of the hip, infantile scoliosis has an association with breech presentation.[24] Unlike developmental dysplasia of hip (DDH), infantile scoliosis is also seen more commonly in males with low birth weight. The developmental history should include both motor and cognitive milestones. This must be carefully performed because cognitive delay has been associated with progressive curves.[24,27]

The physical examination attempts to analyze the spinal deformity and eliminate associated conditions from the potential diagnosis. Initial inspection should include the skin, entire spine, head, pelvis, and extremities. The skin must be examined for cutaneous stigmata such as café au lait spots or axillary freckles seen in neurofibromatosis, midline patches of hair seen in spina bifida occulta, or bruising seen in trauma. The spine exam should include inspection and palpation of the spine. In young children, the Adams forward bend test (looking for prominence of the ribs in the thoracic spine or transverse processes in the lumbar spine) is not possible, but the test can be simulated by lying the child prone over the examiner's knee. Curve flexibility can be assessed by placing the child in the lateral position over the knee or suspending the infant under the arms. Notation of chest or flank asymmetry, chest excursion, and abdominal reflexes must be made. Limitation in chest excursion may indicate syndromic scoliosis and thoracic insufficiency syndrome.[10] Abdominal reflex abnormalities should initiate a thorough neurologic evaluation. Muhonen et al. described the absence of an abdominal reflex as the only objective finding seen in some patients with a Chiari malformation.[31] When abnormal, the absent reflex is usually on the convex side of the curve.[32] Other studies suggest that even in the presence of a normal physical exam, total spine magnetic resonance imaging is indicated in patients with infantile scoliosis due to the high incidence of neural axis abnormalities.[33] In the report by Gupta et al. on six patients with infantile scoliosis and normal neurologic exam, three patients were found to have neural axis abnormalities on MRI.[34] Dobbs et al. subsequently reported on 46 neurologically normal patients with Cobb angles greater than 20 degrees who underwent MRI. Of those patients, 10 demonstrated a neural axis abnormality of MRI and 8 patients ultimately required neurosurgical intervention for the abnormality. The current recommendation is to perform an MRI on patients with infantile scoliosis and a Cobb angle greater than 20 degrees.[35]

The head must be thoroughly examined in children referred for scoliosis. Plagiocephaly is common in patients with infantile scoliosis and responds well to therapy. Other conditions affecting the head that are associated with infantile scoliosis include bat-ear deformity and congenital muscular torticollis. Although these conditions frequently occur without scoliosis, one must be aware of the association. The pelvic exam should rule out plagiopelvy and developmental hip dysplasia, both of which are associated with infantile scoliosis.[21,22] The lower extremity exam must exclude limb length inequality as the etiology of scoliosis. When scoliosis is secondary to a limb-length inequality, the lumbar prominence is found on the side of the longer limb. Functional scoliosis due to limb length inequality may be negated by performing a sitting forward bend or placing a lift under the short limb to equalize the limb lengths.

♦ Radiologic Evaluation

Initial evaluation of the patient with reported scoliosis should consist of antero-posterior and lateral radiographs of the entire spine (including the cervical spine and pelvis). In children who are too young to stand, the films should be taken supine. Cervical spine abnormalities or fusions should be evaluated. Similarly, the lumbosacral junction, pelvis, and hips should be carefully examined to rule out congenital conditions and establish that the hips are reduced. In patients

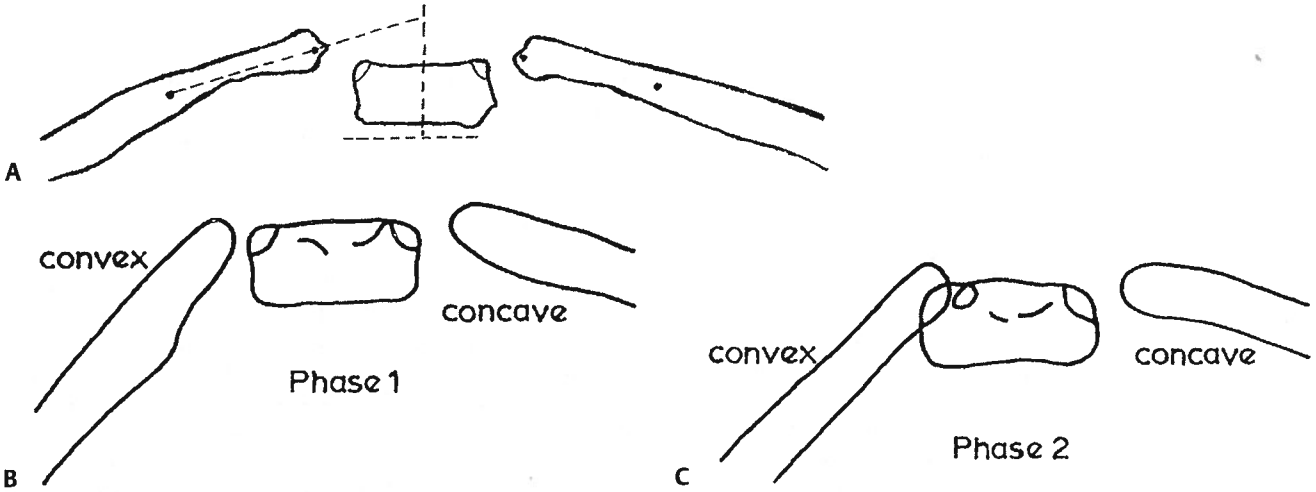

Figure 13–1 Mehta's rib vertebral angle difference. **(A)** Calculation of rib-vertebral angle. Draw a line perpendicular to the end plate of the apical vertebrae. Then draw a line from the midpoint of the head of the rib to the midpoint of the neck of the rib on the convex side and the angle calculated. The similar angle is calculated on the concave side. Concave – convex = rib vertebral angle difference. **(B)** Phase 1 rib head. No overlap of rib head and vertebral body. If RVAD <20 degrees, the curve is unlikely to progress. **(C)** Phase 2 rib. Note the overlap of the rib on the vertebra, which indicates certain progression of the curve. Reproduced with permission and copyright © of the British Editorial Society of Bone and Joint Surgery. Mehta MH. The rib-vertebra angle in the early diagnosis between resolving and progressive infantile scoliosis. J Bone Joint Surg Br 1972;54(2):230–243.

with scoliosis, measurement of the Cobb angle is mandatory and will be used to monitor progression of the curve. However, infantile scoliosis is unlike late onset scoliosis in two ways. First, infantile scoliosis frequently resolves spontaneously. Second, a reliable method is available to predict progression or resolution of the curve. In 1972, Mehta described the method that now bears her name. Frustrated with the inability to predict which curves would progress, she evaluated the relationship of the rib attachment to the vertebral body. She noted variability in the takeoff angle of the ribs from the convex versus the concave side of the curve. The rib-vertebral angle difference of Mehta (RVAD) measures the angle of a line drawn perpendicular to the apical thoracic vertebra end plate and a line drawn down the center of the concave and convex ribs. The actual difference is calculated by subtracting the convex from the concave angles[36] **(Fig. 13–1A).** An RVAD of less than 20 degrees indicates a curve that is likely to resolve (85 to 90% of cases), whereas an RVAD of greater than 20 degrees is frequently associated with curves that will progress. Mehta later described an additional tool known as the "phase of the rib head" that is useful for prognostication of infantile scoliosis. The phase of the rib head notes the position of the convex rib head on the apical vertebra. A phase 1 relationship indicates no overlap of the rib head or neck on the apical vertebra **(Fig. 13–1B).** In cases that have a phase 1 relationship, the RVAD may be calculated and used to determine likelihood of progression. In a phase 2 relationship, the head of the rib on the convex side of the apical vertebra overlaps the vertebra, and the RVAD is not measured because the curve is certain to progress[36] **(Fig. 13–1C).** In the initial description of the RVAD and phase of the rib head, Mehta reported 83% resolution in phase 1 relationships with RVAD of less than 20 degrees. Conversely, the group that progressed had 84% of the patients with an RVAD of greater than 20 degrees.

Ferreira and James tested the RVAD and head of the rib phase in their own patient population and reported results similar to those of Mehta. Patients with phase 1 ribs and RVAD less than 20 degrees resolved in 98.5% of cases, whereas 97.5% of cases with an RVAD of greater than 20 degrees or phase 2 relationship progressed.[37] One final radiographic clue to evaluate is the presence of a lumbar curve. Ceballos et al. demonstrated that double curves are very likely to progress and must be followed closely.[17]

♦ Nonoperative Treatment

In all cases of scoliosis in skeletally immature patients, the three treatment options are observation, bracing (via cast or orthotic), and surgery. The treatment of infantile scoliosis is based on the likelihood of progression, as determined by Mehta's criteria. Curves that have less than a 25-degree Cobb angle and an RVAD of less than 20 degrees are considered nonprogressive curves. The treatment recommendation is observation with serial radiographs at 4- to 6-month intervals. If resolution occurs, the span between radiographs may be extended to 1 to 2 years. However, the radiographic evaluations must continue until the patient has reached skeletal maturity. If progression occurs, defined as a 10-degree increase in curvature, treatment must be initiated. A thorough clinical, radiographic, and neurologic evaluation must be performed to rule out other etiologies responsible for the progression.[33,38]

Infants with curves between 25 and 35 degrees and an RVAD greater than 20 degrees (or a phase 2 rib relationship) are considered at high risk for progression. Initial treatment is observation with serial radiographs at 4- to 6-month intervals.

However, Cobb angle progression of 5 degrees in these patients warrants active treatment.

Patients who progress beyond the observation stage of treatment typically advance to orthotic care. Orthotic care for scoliosis is composed of casting or bracing. Infantile scoliosis is primarily treated with serial molded body casts followed by orthosis.[39] Casts are applied and removed under general anesthesia at 6- to 12-week intervals. The surgeon should apply the cast with gentle pressure over the convex prominence to attempt derotation of the deformity. However, one must be aware that force applied to the ribs may deform the thoracic cage prior to transmitting significant derotational force to the spine. By 18 months of age, the maximum correction possible with casting has been attained. At that point, the patient should be transitioned to a Milwaukee brace and instructed on full-time wear (at least 23 hours per day). Although thoracolumbar orthoses are the mainstay of nonoperative treatment in late onset scoliosis, it is not recommended for use in infantile scoliosis due to concern that the circumferential fit of the brace may distort the rib cage and cause a decrease in ultimate pulmonary function.[8] Brace treatment is continued for 2 to 3 years. One may begin to wean the brace when there is no evidence of curve progression as determined by a stationary Cobb angle and RVAD. After the end of bracing, the surgeon must continue to monitor the patient for evidence of relapse both clinically and radiographically until skeletal maturity. If curve progression occurs, full-time bracing should be started immediately. If the progression is rapid, one should consider an MRI to evaluate possible intraspinal pathology. Parents should be counseled that progressive curves may ultimately require operative intervention. However, Mehta and Morel demonstrated that if complete correction occurs prior to the prepubertal growth spurt, there will be no relapse during adolescence.[39]

Although principally mentioned for historical purposes, longitudinal traction may be an option for nonoperative treatment of infantile scoliosis. Initially proposed by Glisson in 1660, traction for treatment of scoliosis has declined in popularity as operative methods have improved.[40] Today, most patients who undergo traction treatment are treated for a short duration (weeks to months) with a device that uses a halo combined with either gravity, femoral, or pelvic fixation. Given this limitation, the authors do not recommend long-term treatment of infantile scoliosis with traction. This technique, however, may be useful in some severe curves to achieve flexibility prior to surgery.

♦ Surgical Treatment

The ultimate goal of surgical treatment of infantile scoliosis is to stop progression of the curve while allowing maximum growth of the spine, lungs, and thoracic cage. Surgical treatment of infantile scoliosis is recommended for progressive curves greater than 45 degrees in a skeletally immature patient.[25] This statement indicates the current trend toward less tolerance of curve progression prior to operative management. Age of the patient at the time of curve progression will frequently dictate the type of surgical procedure. Initial techniques promoted spinal fusion as the primary method to halt curve progression. Success was thought to be a straight shortened spine rather than a deformed spine of near normal length. Isolated posterior spinal fusion in young children was quickly found to be unsuccessful for long-term correction of deformity due to the crankshaft phenomenon described by Dubousset et al.[41] The crankshaft phenomenon describes the continued progression of curvature due to anterior growth of the spine after posterior spinal fusion in skeletally immature patients. Sanders et al. reported that patients who have open triradiate cartilages and are Risser 0 have a high likelihood of curve progression due to crankshaft if an isolated posterior fusion is performed.[42] To prevent crankshaft in patients with open triradiate cartilage, anterior arthrodesis must be included with posterior fusion. However, anterior and posterior fusion results in considerable loss of potential height. Remembering that there are two stages of maximal spinal growth velocity (0 to 5 and 10 to 15 years), one can imagine that early fusion for infantile scoliosis will result in substantial loss of expected height. Dimeglio has developed charts to calculate the remaining growth.[4] Similarly, Winter described a formula for calculating the amount of projected shortening of the spine due to spinal fusion.[43] To calculate projected shortening in centimeters, multiply 0.07 × (number of segments fused) × (number of years of remaining growth). These valuable tools allow the physician and family to understand the ramifications of spinal fusion in the very young child. In addition to the effect on spinal growth, fusion has potential morbidity to the developing thoracic cage and lungs and has resulted in attempts to devise other methods for treatment of infantile scoliosis. Current research has focused on methods other than spinal fusion for treatment of infantile scoliosis.

The surgical treatment of infantile scoliosis has been through several generations. More than 40 years ago, Roaf proposed that the deformity in infantile scoliosis was due to asymmetric growth between the convex (faster growing) and concave (inhibited) side of the curve.[44] Due to success in treating angular growth deformities in the extremities of growing children with hemiepiphysiodesis, he recommended a similar approach to the spine. The technique he described involved ablation of the convex epiphyseal cartilage and adjacent disks at the vertebrae near the apex of the curve. Whereas 23% of the patients showed improvement in the Cobb angle of the curve, 40% were viewed as little or no improvement in Cobb angle (<10-degree change). More recently, Marks et al. reported on convex epiphysiodesis with or without Harrington instrumentation and found no significant improvement in the measured deformity.[45] Out of 13 patients, 12 demonstrated progression of deformity despite treatment. The report recommended instrumentation at the time of convex epiphysiodesis as the best option to control but not reverse the progression of the curve.

Convex hemiepiphysiodesis continues to have supporters in the treatment of infantile scoliosis. The latest attempts to control curvature with hemiepiphysiodesis have focused on a minimally invasive approach. Through the use of thoracoscopic techniques, staples similar to those used for treating angular deformity in the lower extremities are placed on the convex side of the vertebrae in the apex of the curve. The

technique avoids fusion and thereby has the potential for future growth. The minimally invasive nature of the procedure has the potential for decreased patient morbidity and future surgery. Early attempts at the procedure were unsuccessful due to failure of the staple fixation among other reasons. In 2003, Betz et al. reported on the use of staples placed thoracoscopically for convex epiphysiodesis in patients with adolescent idiopathic scoliosis.[46] In the study, 60% of the patients remained stable (<6-degree progression) at minimum 1-year follow-up. The authors recommend caution in interpreting the results and have not attempted the procedure on any younger patients with infantile scoliosis.

Other techniques of instrumentation without fusion have been attempted. The goal of this treatment is preservation of spinal growth with correction of the deformity. Ironically, this technique was initially reported by Harrington for treatment of scoliosis.[47] He described a fusionless approach with a distraction rod attached to subperiosteal hook placed at each end of the concave side of the deformity. Complications including hook dislodgment and rod breakage were reported, but no long-term follow-up was included. Harrington reported that "a progressive scoliosis in a child less than ten years old can be managed with the apparatus alone without fusion, whereas in a child more than ten years old fusion should be done at the time of initial correction."[47] Subsequently, his technique for instrumented spinal fusion altered the course of modern scoliosis surgery.

Using the work of Harrington as a foundation, Moe et al. modified the surgical technique by limiting subperiosteal dissection to the location of hook placement[48] **(Table 13–1).** No formal fusion was performed at the site of hook placement, and the rod was tunneled subcutaneously rather than below the muscle. The actual rod itself was also modified to include a smooth contour to the midportion of the rod to avoid scar formation and allow sagittal contouring. Moe and coworkers used a Milwaukee brace for postoperative immobilization. Lengthening of the construct was performed at intervals of 6 to 12 months or if loss of correction was greater than 10 degrees. The final results of the technique demonstrated additional growth of 2.9 cm in the instrumented region among all patients. Of the patients that ultimately were treated with fusion, growth averaged 3.8 cm compared with the predicted 4.5 cm for the same patients. The authors reported a 50% complication rate with hook dislodgment from both the rod and lamina occurring. The modified thicker rod resulted in slightly less rod breakage. The 20-year experience of the Moe modification for 67 patients was reported by Klemme et al.[49] The patients averaged 6.1 procedures from initiation of treatment to final fusion. The method was considered successful as 66% of the patients demonstrated either no curve progression or improvement in curve magnitude of an average of 30%. In the remaining patients, 12 of which had neuromuscular scoliosis, curve progression averaged 33%. The overall spinal growth of the patients treated with the method was comparable with normal growth. Complications due to implant failure were reported in 8% of cases.

In 1977, Luque and Cardosa described segmental spinal fixation without instrumentation.[50] Luque reported the technique of sublaminar wires attached to Harrington rods in 47 patients with neuromuscular scoliosis.[51] Using this technique, he reported an average growth of 2.6 cm in the instrumented portion of the spine with a 78% curve correction. The technique was later modified to include smooth L-shaped rods and wires known as a "Luque trolley." Proponents of this technique suggested that operative lengthening would be unnecessary as the rods would slide through the wires and allow growth of the spine.[52] The strength of the construct also obviated the need for postoperative immobilization. However, the Luque trolley was not without complications. Rod breakage continued to occur and patients required lengthening procedures. The sublaminar passage of wires was noted to result in spontaneous fusion in young patients.[53] Several authors also noted that growth of the spine in the instrumented portion of the spine was minimal.[53,54] Modifications

Table 13-1 Comparison of Various Surgical Techniques for the Treatment of Early Onset Scoliosis

Authors	Number of Patients	Average Initial Elongation Pre- to Postinitial (cm)	Average Growth of Instrumented Area (cm)	Average Growth of Entire Spine (cm)	Complication Rate (% of patients with complication)
Moe et al.*	13	Not reported	2.9	3.8	50
Luque and Cardosa†	43	Not reported	2.6	Not reported	42
Klemme et al.‡	55	Not reported	3.1	Not reported	37
Blakemore et al.§	29	Not reported	Not reported	Not reported	24
Akbarnia et al.¶	23	5.3	3.7	9.84	22

* *Source*: Data from Moe JH, Kharrat K, Winter RB, Cummine, JL. Harrington instrumentation without fusion plus external orthotic support for the treatment of difficult curvature problems in young children. Clin Orthop 1984;185:35–45.

† *Source*: Data from Luque ER, Cardosa A. Segmental spinal instrumentation in growing children. Orthop Trans 1977;1:37.

‡ *Source*: Data from Klemme WR, Denis F, Winter RB, Lonstein JW, Koop SE. Spinal instrumentation without fusion for progressive scoliosis in young children. J Pediatr Orthop 1997;17(6):734–742.

§ *Source*: Data from Blakemore LC, Scoles PV, Poe-Kochert C, Thompson GH. Submuscular Isola rod with or without limited apical fusion in the management of severe spinal deformities in young children: preliminary report. Spine 2001;26(18):2044–2048.

¶ *Source*: Data from Akbarnia BA, Marks DS, Boachie-Adjei O, Thompson A, Asher MA. Dual rod posterior instrumentation without fusion for the treatment of progressive early onset scoliosis: a multicenter study. Presented at: Scoliosis Research Society 38th Annual Meeting. 2003. Quebec City, Quebec. Spine 2005 Sep 1; 30(17 suppl):S46–57

of the Luque trolley have been described. Patterson et al. combined the Luque trolley with anterior growth arrest on the convexity in young patients.[55] Curve correction averaged 46% at 2-year follow-up. The results were better for patients undergoing segmental instrumentation and anterior fusion than those with posterior segmental instrumentation alone. No spontaneous fusions were reported in their series. A similar study was performed by Pratt et al.[56] The study agreed with the findings of Patterson et al. regarding the poor prognosis for patients treated solely with posterior segmental spinal instrumentation. The Cobb angle worsened in 54% of patients, remained stable in 31%, and improved in only 15% of patients. Given these disappointing results, the authors still felt that the technique was superior to brace treatment for infantile scoliosis but required modification of technique and implants for improved success.

At the same time that Luque reported on his technique, Marchetti and Faldini described the "end fusion technique" for treating early scoliosis in young children.[57] The technique described staged operative procedures in which the vertebrae at the ends of the Cobb angle were fused initially. Several months later, hook and subperiosteal rod placement were performed. The third procedure, typically 6 to 8 weeks after placement of the hooks and rod, involved distraction of the upper hook. The report contained only limited follow-up.

Other reports have focused on lengthening via submuscular rather than subperiosteal rod placement. Blakemore et al. described the use of an Isola submuscular rod with and without apical fusion in a heterogeneous population of 29 patients with scoliosis or kyphoscoliosis.[58] Only 10 of the patients were considered idiopathic scoliosis. Unlike previous reports, the rod was placed in a submuscular position. The hypothesis for the method was that the rod position would allow improved rod contour yet limit the potential for spontaneous fusion. Curves that were greater than 70 degrees or were stiff on bending radiographs were treated with apical fusion in addition to the submuscular rod. Initial postoperative curve measurements averaged 38 degrees, which was a significant improvement from the average preoperative measurement of 66 degrees. Complications including hook displacement, rod breakage, and superficial wound infection occurred in 24% of the patients. Spinal growth was not reported. Despite the complications, the authors believed that the technique was useful in the treatment of significant spinal deformity in young children.

Several other studies regarding submuscular rod placement have recently been reported. The recent studies attempt to promote continued spinal growth while minimizing complications. Using the basic principles of Isola instrumentation described by Asher, Akbarnia and Marks have developed a dual growing rod technique that can be used submuscularly or subcutaneously.[59,60] This technique is currently used by the authors. Subperiosteal dissection is performed only at the upper and lower implant anchor sites. These sites are called the "foundations" of the construct. At the upper end of the curve, hooks are placed in a claw pattern spanning two to three levels to allow adequate space between the hooks in a young child. Either pedicle screws or a similar hook pattern is placed at the lower end of the curve. When placing the rods, a transverse closed rod connector is placed at the level of each foundation. In a biomechanics study, Bagheri et al. demonstrated that pedicle screws and transverse connectors add significant stability to the construct.[61] Fusion is performed at the site of the foundations with the use of local bone or synthetic graft. The rods are then measured and cut into an upper and lower rod for each side. Contoured 3/16-in.-diameter rods are placed on each side of the spine and the upper and lower rods are linked in a tandem connector placed at the thoracolumbar junction **(Figs. 13–2A and 13–2B).** Lengthening of the construct is performed via a distractor designed to fit inside the connector. After the initial placement of the construct, lengthenings are performed at 6-month intervals. We use somatosensory evoked potential monitoring at the time of lengthening to monitor spinal cord response to the correction. Bracing is used on all patients until the foundation sites are felt to be fused. Akbarnia presented the initial miminum 2-year follow-up data at the 2003 Scoliosis Research Society Meeting[62] **(Figs. 13–3A to 13–3E).** Age at the time of initial surgery averaged 5.6 years and patients averaged 6 lengthenings. Cobb angle averaged 81 degrees initially, 38 degrees at the initial postoperative visit and at the most recent follow-up. Growth of the spine approached normal spinal growth with an average of 0.82 cm per year. Seven patients who were followed to final fusion averaged 14 cm of total spine growth during the time of treatment. Five complications occurred in the series including one hook dislodgment, one broken rod, two superficial wound infections treated with oral antibiotics, and one patient required extension of the fusion one level distally.

The latest data on growing rod technique by Thompson et al. again supports dual rod instrumentation.[63] Twenty-eight patients were divided into three groups and followed to final fusion: single rod with anterior and posterior apical fusion (5 patients), single rod without apical fusion (16 patients), and dual rod without apical fusion (7 patients). Although the authors determined that either single or dual rod technique was effective at controlling curve correction and allowing spinal growth, the dual rod system improved the curves and maintained initial correction better and was able to facilitate increased spinal growth. In the series, short apical fusion was associated with curve stiffening, crankshaft phenomenon, and a higher incidence of complications. As a result, the authors question the effects of combining apical fusion in patients treated for early onset scoliosis with growing rod techniques.

The treatment of infantile scoliosis remains one of the more challenging aspects of spine surgery. Historical data has demonstrated that untreated curves have the potential for serious cardiopulmonary and skeletal complications.[1,11] Observation, orthotics, traction, and operative treatment remain the options in the surgeon's armamentarium against infantile scoliosis. Operative treatment should be reserved for patients who do not meet the criteria for observation and fail or do not meet the criteria for orthotic management. Although current operative techniques attempt to allow normal spinal growth and prevent curve progression, the patient requires numerous operations prior to the definitive spinal fusion. The dual growing rod technique has shown good maintenance of correction throughout the treatment period. The question needs to be asked if it is possible to start the treatment earlier when the curves are not severe and to use the growing

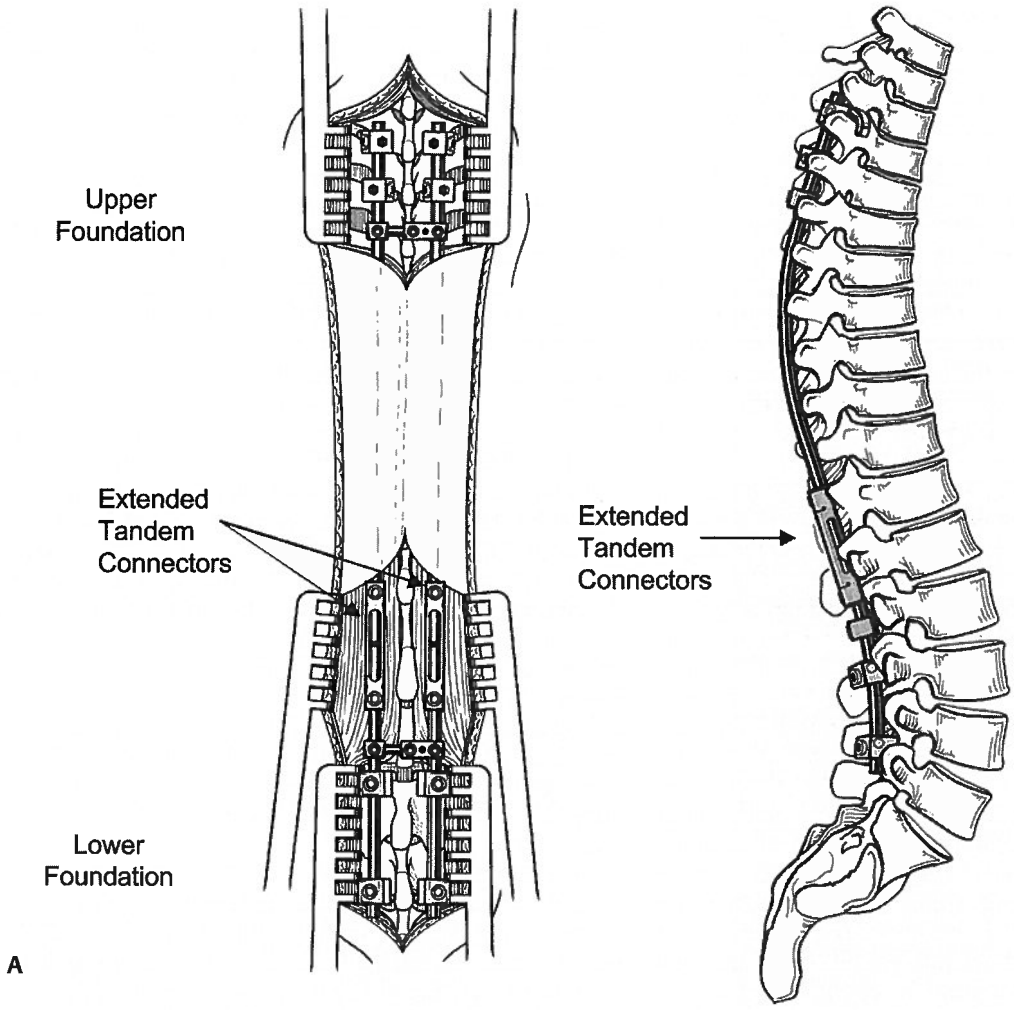

Figure 13–2 The technique of dual rod growing construct. **(A)** Anteroposterior view of the upper and lower rods joined by extended tandem connectors in thoracolumbar spine. **(B)** Dual rod growing construct as viewed laterally. Instrumentation is contoured to preserve sagittal alignment. To minimize profile, extended tandem connectors are placed at the thoracolumbar junction. From Bagheri R, Akbarnia BA. Pediatric ISOLA (DePuy spine) instrumentation. In: Kim DH, Vaccaro AR, Fessler RG, eds. Spinal Instrumentation: Surgical Techniques. New York: Thieme Medical Publishers; 2005:636–643. Reprinted with permission

rods as an internal brace. If the treatment is extended to skeletal maturity, it may be possible to remove the implants at that time without the need for definitive fusion. Future research and longer follow-ups will attempt to answer these questions. We should also find solutions that are less invasive and require fewer operative procedures yet still allow normal spine growth and correction of the deformity.

Acknowledgments The authors would like to acknowledge Sarah Canale, B.S., for her editorial work.

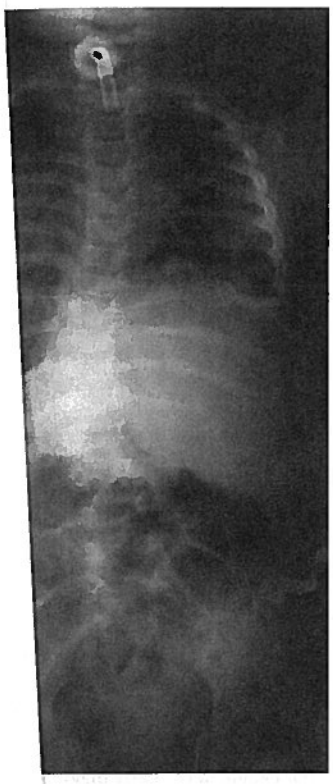

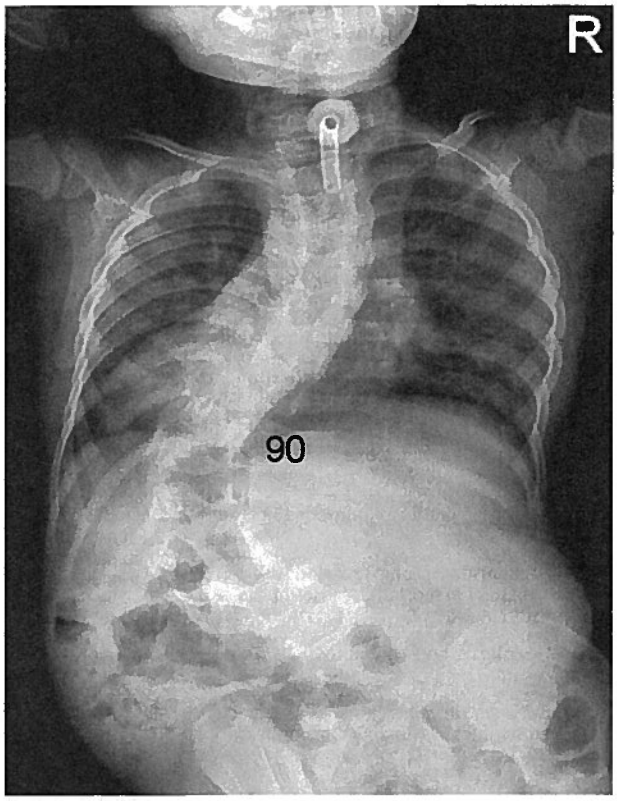

B

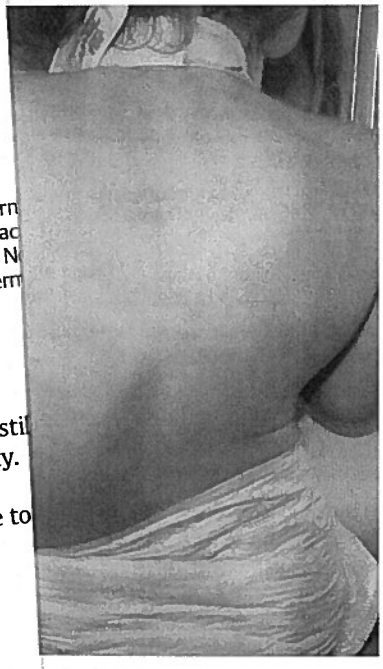

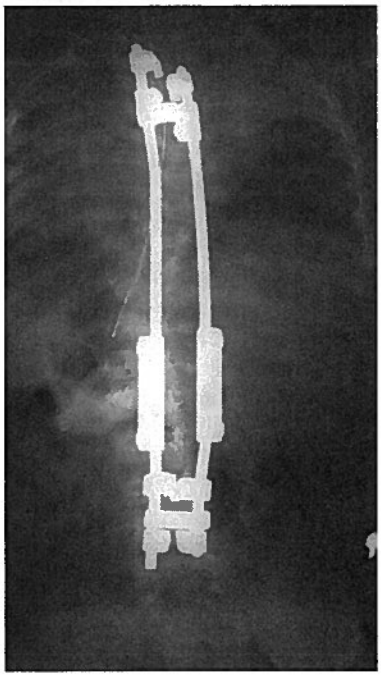

D

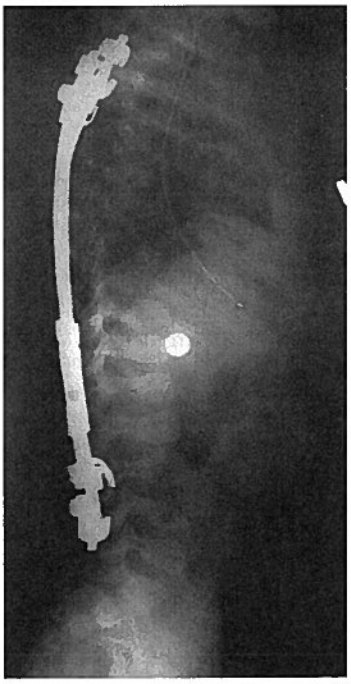

E

B

on. From Bagheri R, Akbarn
ımentation. In: Kim DH, Vac
ation: Surgical Techniques. N
36–643. Reprinted with perm

erative procedures yet stil
rection of the deformity.

The authors would like to
r her editorial work.

+6-year-old boy with infantile idiopathic scoliosis. **(A)** rior radiographs of the spine. **(B)** Preoperative antero- h of the spine at the age of 2+6 years showing significant progression over 18 months. **(C)** Preoperative posterior clinical photograph of the spine. **(D)** Postoperative antero-posterior radiograph of the spine. **(E)** Postoperative lateral radiograph of the spine.

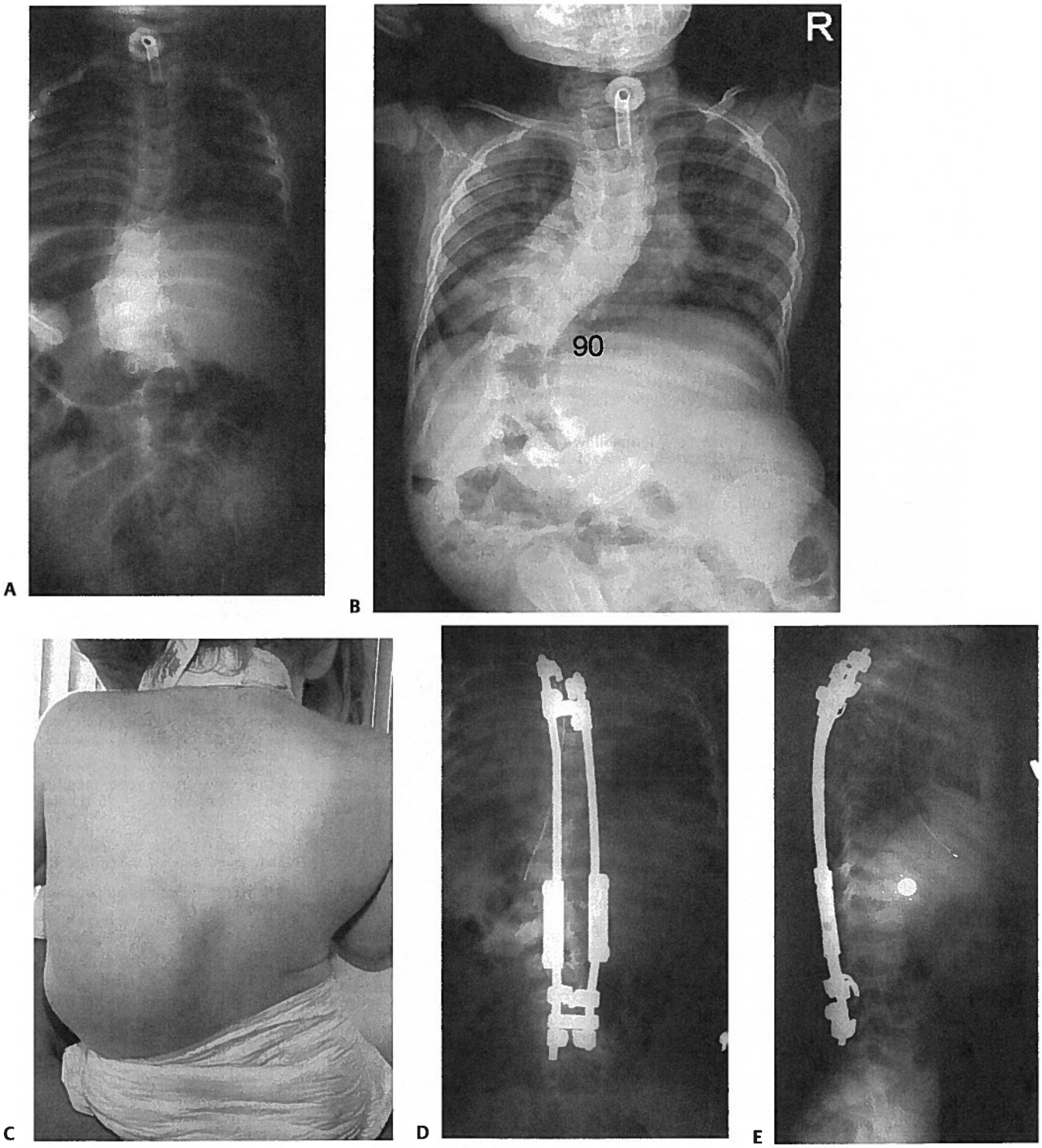

Figure 13–3 A 2+6-year-old boy with infantile idiopathic scoliosis. **(A)** Early antero-posterior radiographs of the spine. **(B)** Preoperative antero-posterior radiograph of the spine at the age of 2+6 years showing significant progression over 18 months. **(C)** Preoperative posterior clinical photograph of the spine. **(D)** Postoperative antero-posterior radiograph of the spine. **(E)** Postoperative lateral radiograph of the spine.

References

1. James JI. Idiopathic scoliosis; the prognosis, diagnosis, and operative indications related to curve patterns and the age at onset. J Bone Joint Surg Br 1954;36-B(1):36–49
2. Dickson RA. Early-onset idiopathic scoliosis. In: Weinstein S, ed. The Pediatric Spine: Principles and Practice. New York: Raven Press; 1994: 421–429
3. Bradford D, Moe JH. Moe's Textbook of Scoliosis and Other Spinal Deformities. Philadelphia: WB Saunders; 1978
4. Dimeglio A. Growth of the spine before age 5 years. J Pediatr Orthop 1993;1-B:102–107
5. Dickson RA, Archer IA. Surgical treatment of late-onset idiopathic thoracic scoliosis. The Leeds procedure. J Bone Joint Surg Br 1987;69(5):709–714
6. Dickson RA. Conservative treatment for idiopathic scoliosis. J Bone Joint Surg Br 1985;67(2):176–181
7. Branthwaite MA. Cardiorespiratory consequences of unfused idiopathic scoliosis. Br J Dis Chest 1986;80(4):360–369
8. Pehrsson K, Larsson S, Oden A, Nachemson A. Long-term follow-up of patients with untreated scoliosis. A study of mortality, causes of death, and symptoms. Spine 1992;17(9):1091–1096
9. Swank SM, Winter RB, Moe JH. Scoliosis and cor pulmonale. Spine 1982;7(4):343–354
10. Campbell RM, Smith MD, Mayes TC, et al. The characteristics of thoracic insufficiency syndrome associated with fused ribs and congenital scoliosis. J Bone Joint Surg Am 2003;85-A(3):399–408
11. James JI, Lloyd-Roberts GC, Pilcher MF. Infantile structural scoliosis. J Bone Joint Surg Br 1959;41-B:719–735
12. McMaster MJ. Infantile idiopathic scoliosis: can it be prevented? J Bone Joint Surg Br 1983;65(5):612–617
13. Scott JC, Morgan TH. The natural history and prognosis of infantile idiopathic scoliosis. J Bone Joint Surg Br 1955;37-B(3):400–413
14. James JI. Two curve patterns in idiopathic structural scoliosis. J Bone Joint Surg Br 1951;33-B(3):399–406
15. Mau H. [Should the so-called infantile scoliosis be treated?] Dtsch Med Wochenschr 1968;93(43):2051–2053
16. Walker GF. An evaluation of an external splint for idiopathic structural scoliosis in infancy. J Bone Joint Surg Br 1965;47:524–525
17. Ceballos T, Ferrer-Torrelles M, Castillo F, Fernandez-Paredes E. Prognosis in infantile idiopathic scoliosis. J Bone Joint Surg Am 1980;62(6):863–875
18. Lloyd-Roberts GC, Pilcher MF. Structural idiopathic scoliosis in infancy: a study of the natural history of 100 patients. J Bone Joint Surg Br 1965;47:520–523
19. Thompson SK, Bentley G. Prognosis in infantile idiopathic scoliosis. J Bone Joint Surg Br 1980;62-B(2):151–154
20. Harrenstein R. Die skoliose bei saueglingen und ihre behandlung. Z Orthop Chir 1930;52:1–40
21. Browne D. Congenital postural scoliosis. Proc R Soc Med 1956;49(7): 395–398
22. Browne D. Congenital deformities of mechanical origin. Proc R Soc Med 1936;49:1409–1431
23. Mehta MH. Infantile idiopathic scoliosis. In: Dickson RA, Bradford D, eds. Management of Spinal Deformities. London: Butterworths International Medical Reviews; 1984:101–120
24. Wynne-Davies R. Infantile idiopathic scoliosis. Causative factors, particularly in the first six months of life. J Bone Joint Surg Br 1975; 57(2): 138–141
25. Lenke LG, Dobbs MB. Idiopathic scoliosis. In Frymoyer J, Wiesel S, eds. The Adult and Pediatric Spine. Philadelphia: Lippincott Williams & Wilkins; 2004:337–360
26. Kattwinkel J, Brooks J, Myerberg D. Positioning and SIDS: AAP Task Force on Infant Positioning and SIDS. Pediatrics 1992;89:1120–1126
27. Conner AN. Developmental anomalies and prognosis in infantile idiopathic scoliosis. J Bone Joint Surg Br 1969;51(4):711–713
28. Davies G, Reid L. Effect of scoliosis on growth of alveoli and pulmonary arteries and on right ventricle. Arch Dis Child 1971;46(249):623–632
29. Muirhead A, Conner AN. The assessment of lung function in children with scoliosis. J Bone Joint Surg Br 1985;67(5):699–702
30. Kafer ER. Idiopathic scoliosis. Gas exchange and the age dependence of arterial blood gases. J Clin Invest 1976;58(4):825–833
31. Muhonen MG, Menezes AH, Sawin PD, Weinstein SL. Scoliosis in pediatric Chiari malformations without myelodysplasia. J Neurosurg 1992;77(1):69–77
32. Zadeh HG, Sakka SA, Powell MP, Mehta MH. Absent superficial abdominal reflexes in children with scoliosis. An early indicator of syringomyelia. J Bone Joint Surg Br 1995;77(5):762–767
33. Dobbs MB, Lenke LG, Bridwell KH. Incidence of neural axis abnormalities in infantile patients diagnosed with idiopathic scoliosis. Is a screening MRI necessary? Presented at: Scoliosis Research Society 36th Annual Meeting; 2001; Cleveland, OH
34. Gupta P, Lenke LG, Bridwell KH. Incidence of neural axis abnormalities in infantile and juvenile patients with spinal deformity. Is a magnetic resonance image screening necessary? Spine 1998;23(2):206–210
35. Dobbs MB, Lenke LG, Szymanski DA. Prevalence of neural axis abnormalities in patients with infantile idiopathic scoliosis. J Bone Joint Surg Am 2002;84-A(12):2230–2234
36. Mehta MH. The rib-vertebra angle in the early diagnosis between resolving and progressive infantile scoliosis. J Bone Joint Surg Br 1972;54(2):230–243
37. Ferreira JH, de Janeiro R, James JI. Progressive and resolving infantile idiopathic scoliosis. The differential diagnosis. J Bone Joint Surg Br 1972;54(4):648–655
38. Lewonowski K, King JD, Nelson MD. Routine use of magnetic resonance imaging in idiopathic scoliosis patients less than eleven years of age. Spine 1992;17(6 Suppl):S109–S116
39. Mehta MH, Morel G. The non-operative treatment of infantile idiopathic scoliosis. In: Zorab P, Siezler D, eds. Scoliosis 1979. London: Academic Press; 1979:71–84
40. Glisson F. De Rachitide, Sive Morbo Puerili Qui Volgo, The Rickets., In: Dicitur and Tractatus, eds. The Rickets 2nd edition. London: L Sadler; 1660;10
41. Dubousset J, Herring JA, Shufflebarger H. The crankshaft phenomenon. J Pediatr Orthop 1989;9(5):541–550
42. Sanders JO, Herring JA, Browne RH. Posterior arthrodesis and instrumentation in the immature (Risser-grade-0) spine in idiopathic scoliosis. J Bone Joint Surg Am 1995;77(1):39–45
43. Winter RB. Scoliosis and spinal growth. Orthop Rev 1997;6:17–20
44. Roaf R. The treatment of progressive scoliosis by unilateral growth-arrest. J Bone Joint Surg Br 1963;45:637–651
45. Marks DS, Iqbal MJ, Thompson AG, Piggott H. Convex spinal epiphysiodesis in the management of progressive infantile idiopathic scoliosis. Spine 1996;21(16):1884–1888
46. Betz RR, Kim J, D'Andrea LP, Mulcahey MJ, Balsara RK, Clements DH. An innovative technique of vertebral body stapling for the treatment of patients with adolescent idiopathic scoliosis: a feasibility, safety, and utility study. Spine 2003;28(20):S255–S265
47. Harrington PR. Treatment of scoliosis. Correction and internal fixation by spine instrumentation. J Bone Joint Surg Am 1962;44-A:591–610
48. Moe JH, Kharrat K, Winter RB, Cummine JL. Harrington instrumentation without fusion plus external orthotic support for the treatment of difficult curvature problems in young children. Clin Orthop Relat Res 1984;185:35–45
49. Klemme WR, Denis F, Winter RB, Lonstein JW, Koop SE. Spinal instrumentation without fusion for progressive scoliosis in young children. J Pediatr Orthop 1997;17(6):734–742

50. Luque ER, Cardosa A. Segmental spinal instrumentation in growing children. Orthop Trans 1977;1:37

51. Luque ER. Paralytic scoliosis in growing children. Clin Orthop Relat Res 1982;163:202–209

52. Leatherman K, Dickson RA. The Management of Spinal Deformities. London: John Wright; 1988

53. Mardjetko SM, Hammerberg KW, Lubicky JP, Fister JS. The Luque trolley revisited. Review of nine cases requiring revision. Spine 1992;17(5): 582–589

54. Rinsky LA, Gamble JG, Bleck EE. Segmental instrumentation without fusion in children with progressive scoliosis. J Pediatr Orthop 1985; 5(6):687–690

55. Patterson JF, Webb JK, Burwell RG. The operative treatment of progressive early onset scoliosis. A preliminary report. Spine 1990;15(8): 809–815

56. Pratt RK, Webb JK, Burwell RG, Cummings SL. Luque trolley and convex epiphysiodesis in the management of infantile and juvenile idiopathic scoliosis. Spine 1999;24(15):1538–1547

57. Marchetti P, Faldini A. "End fusions" in the treatment of some progressive scoliosis in childhood or early adolescence. Orthop Trans 1978; 2:271

58. Blakemore LC, Scoles PV, Poe-Kochert C, Thompson GH. Submuscular Isola rod with or without limited apical fusion in the management of severe spinal deformities in young children: preliminary report. Spine 2001;26(18):2044–2048

59. Asher MA. Isola spinal instrumentation for scoliosis. In: DeWald R, ed. The Textbook of Spinal Surgery. Philadelphia: Lippincott-Raven; 1997:569–609

60. Akbarnia BA, Marks DS. Instrumentation with limited arthrodesis for the treatment of progressive early-onset scoliosis. Spine. State of the Art Reviews 2000;14(1):181–189

61. Bagheri R, Oka R, Mahar A, Kostial P, Akbarnia BA. Biomechanical comparisons of different anchors (foundations) used in the growing dual rod technique. Presented at: IMAST 11th Annual Meeting; 2004; Southhampton, Bermuda

62. Akbarnia BA, Marks DS, Boachie-Adjei O, Thompson A, Asher MA. Dual rod posterior instrumentation without fusion for the treatment of progressive early onset scoliosis: a multicenter study. Spine 2005 Sep 1; 30(17 suppl):S46–57

63. Thompson GH, Akbarnia BA, Kostial P, et al. Comparison of single and dual growing rod techniques followed through definitive surgery. Spine 2005 Sep 15;30(18):2039–2044

Chapter 14

Neuromuscular Scoliosis

John P. Lubicky

This chapter will summarize the collective and traditional wisdom about neuromuscular spine deformity in general and address a few specific conditions to illustrate the concepts and difficulties in reaching the treatment goals of this condition. The literature on this topic is very extensive. The reference section of this chapter lists many book chapters from recently published texts that are quite complete and informative, written by experts in this area of spinal deformity. Additionally, these references have extensive bibliographies that provide the reader with an ample opportunity to peruse the many additional articles that address and expand on the comments in this chapter.

Neuromuscular deformities, also called paralytic spinal deformities, are associated with some type of underlying neurologic condition and may be just one of several musculoskeletal abnormalities caused or exacerbated by the neurologic disease. The neurologic condition may be the patient's primary diagnosis or may be part of a larger syndrome. Although spinal deformity is a consequence of these diagnoses and it is much more prevalent than in the general population, rarely, if ever, is the prevalence 100% within those diagnoses, and the behavior of the deformity and its severity may vary greatly among those affected.[1–3]

The etiology of neuromuscular deformity is primarily that of muscular weakness and/or imbalance and control that affects trunk alignment. Thus, patients with flaccid muscles (e.g., Duchenne's muscular dystrophy, polio)[4–6] **(Fig. 14–1)**, as well as those with spasticity (e.g., cerebral palsy)[7] or those with involuntary muscle contraction (e.g., dystonia and Friedreich's ataxia),[8] can develop deformity. The severity of the underlying muscle abnormality, patient age (e.g., skeletal maturation status), general health, and the natural history of the underlying diagnosis all affect the deformity behavior. Additionally, comorbidities associated with the underlying diagnosis (e.g., lung function, recurrent urinary tract infections, cardiomyopathy, etc.)[5,9,10] may influence how the deformity is handled. Some syndromes have associated spinal deformities, which are particularly "malignant" in their severity and progression as well as their "refractoriness" to even surgical treatment (e.g., familial dysautonomia). Other types are affected not only by the muscular weakness but also abnormalities of the vertebrae (e.g., myelomeningocele) **(Fig. 14–2)**. Patients who have suffered a spinal cord injury secondary to spinal fracture and/or dislocation frequently have had surgical treatment for it. They can develop subsequent spinal deformity from failure of the initial injury procedure as well as the superimposed paralytic factors[11] **(Fig. 14–3)**. Sometimes the major deformity is in the *sagittal* plane without any scoliosis (coronal plane) **(Fig. 14–4)**.

Neuromuscular curves frequently present to the spine surgeon only after they have progressed to large magnitude. Although large idiopathic curves in adolescence are generally not painful and do not interfere with activities of daily living, severe neuromuscular curves frequently cause impaired posture and discomfort that interfere with basic functions such as sitting **(Fig. 14–5)**. Therefore, there is clear evidence of how neuromuscular deformities affect the patient functionally. Though most authors who have written about neuromuscular spinal deformity suggest that treated patients benefit physically, functionally, and emotionally (and so do their caregivers)[12,13] at least one article refutes this notion.[14]

♦ Classification

Neuromuscular deformity may be classified broadly into two types: the developmental and the acquired. The developmental type of neuromuscular scoliosis would be associated with conditions that are recognized at birth or soon thereafter, and examples of such conditions would be cellular abnormalities, inherited myopathies, myelomeningocele, and cerebral palsy. The other type could be considered as

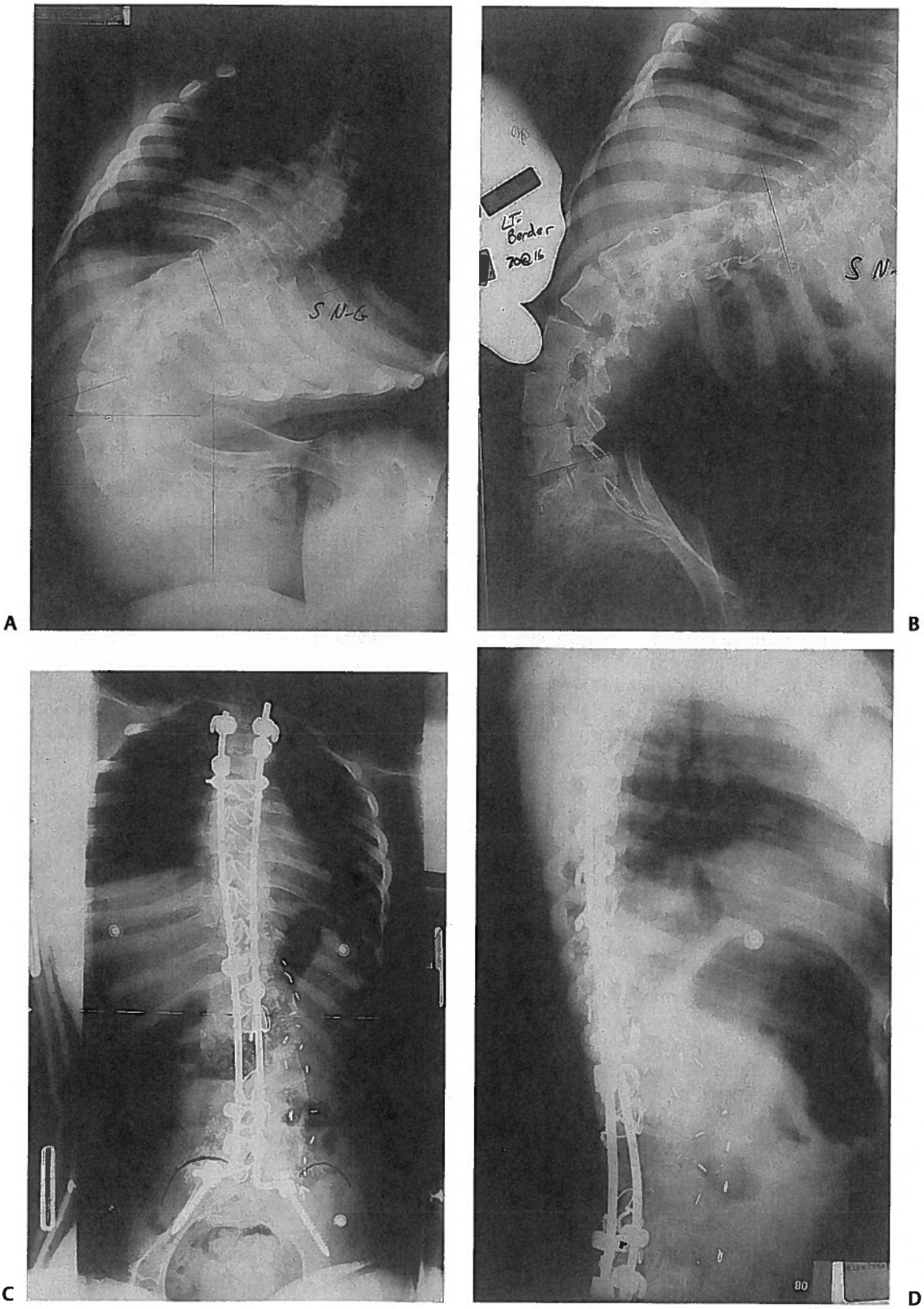

Figure 14–1 This teenage girl had polio with the extensor hallucis longus on one foot as the only functioning lower extremity muscle. She developed a severe spinal deformity with 90 degrees of pelvic obliquity: **(A)** anterior/posterior (AP) and **(B)** bender thoracolumbar (TL) radiographs. A two-stage reconstruction was done involving a two-level vertebrectomy, anterior spinal fusion (ASF), posterior spinal fusion (PSF), and instrumentation to the pelvis with excellent correction: **(C)** AP and **(D)** lateral post-op radiographs. A positive Ober test on the left was noted post-op. After an Ober-Yount release, she was fitted for hip-knee-ankle-foot orthosis (HKAFO) and was able to ambulate with a walker.

A

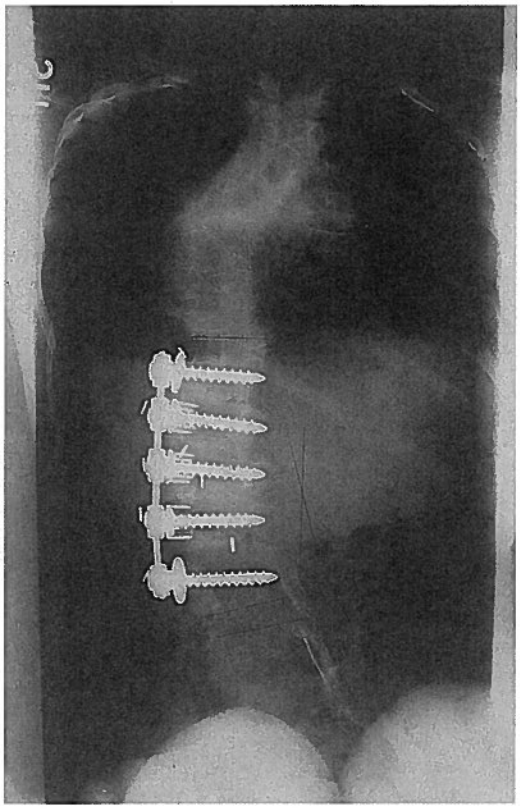

B

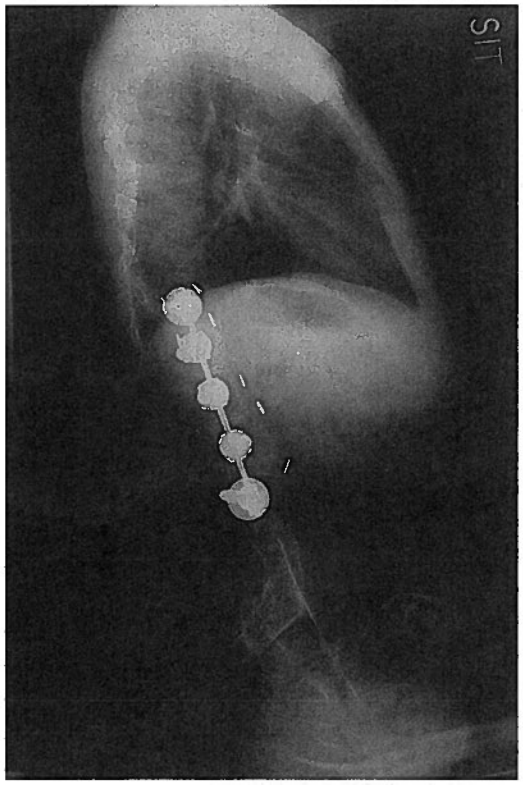

C

Figure 14–2 This young girl has myelomeningocele with spotty lower extremity motor function and several neuraxis abnormalities as well as a complex spinal deformity but no sagittal plane malalignment: **(A)** pre-op AP radiograph. ASF with instrumentation alone provided nice correction: **(B)** AP and **(C)** lateral post-op radiographs. No neurosurgical intervention was involved, and pre-op neurological function was preserved.

acquired, and examples of underlying conditions causing acquired deformity would be spinal cord injury, transverse myelitis, and polio. However, deformity in either type has the potential for severe progression because most deformity starts while the patients are skeletally immature. Even in those diseases with a fairly limited life expectancy, curve progression may occur early, and to improve the quality of life, early treatment may be necessary. For some of these conditions, treatment of the spinal deformity may in fact alter the natural history of the underlying condition because things such as decreased pulmonary function may improve with correction of a severe deformity. Also, treatment of the

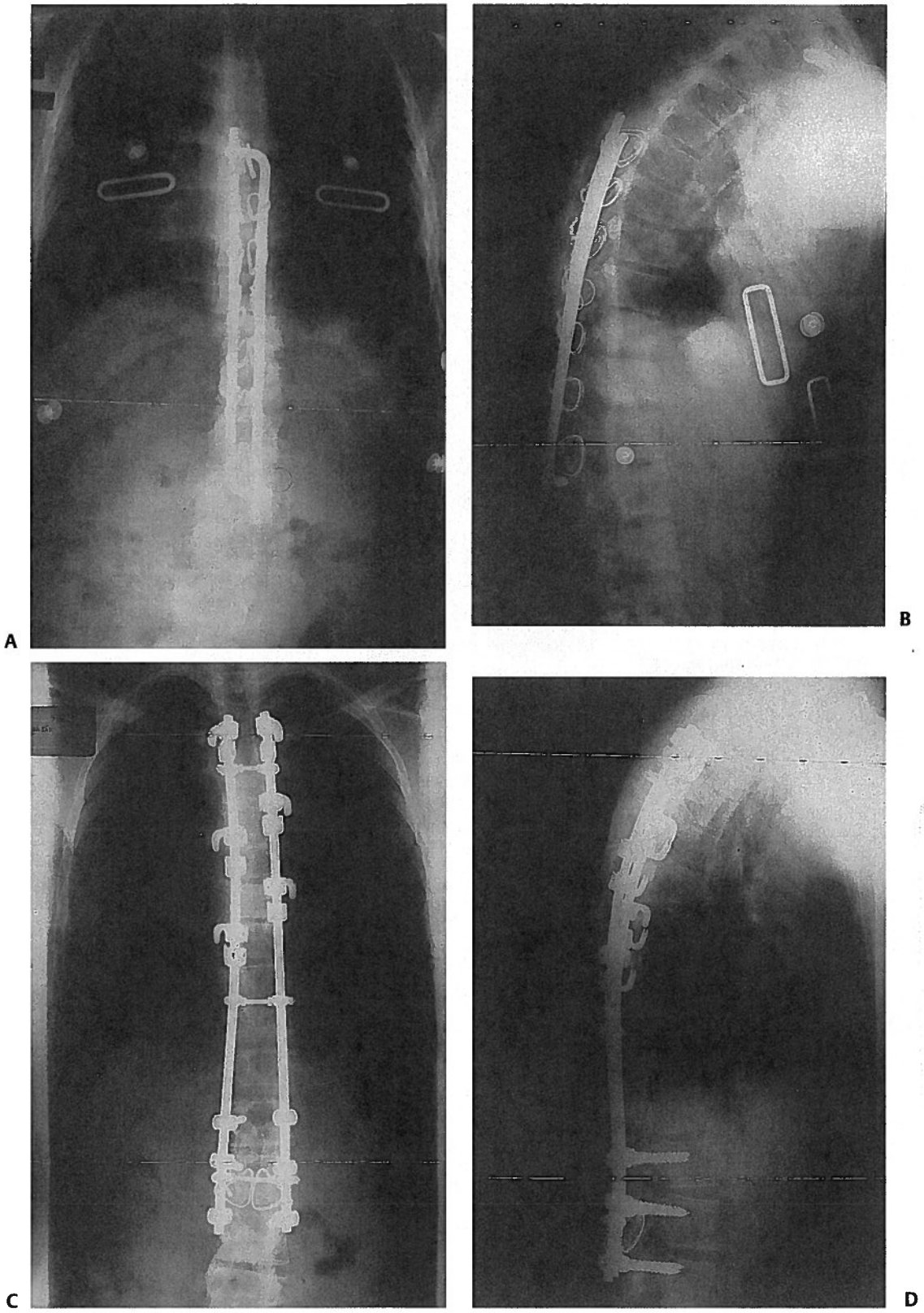

Figure 14–3 This adolescent male had a spinal injury associated with an incomplete spinal cord injury. Surgical treatment of the initial injury was performed but failed: **(A)** AP and **(B)** lateral radiographs. Revision of the spinal surgery resulted in normalization of spinal alignment and a solid fusion: **(C)** AP and **(D)** lateral post-op radiographs.

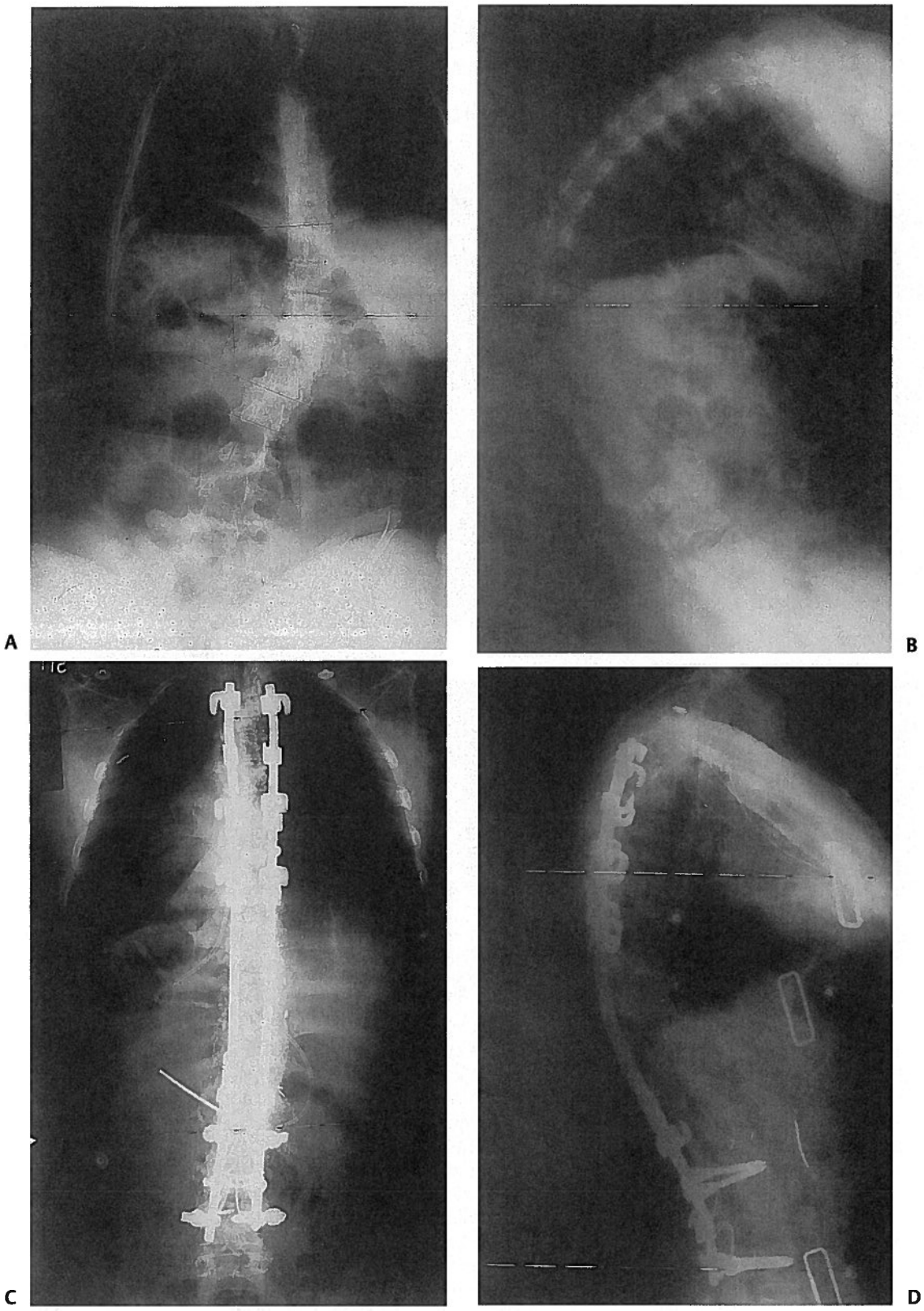

Figure 14–4 This older teenage girl with Rett syndrome has a severe kyphosis as her main deformity. **(A)** AP and **(B)** lateral pre-op radiographs. She had a two-stage reconstruction with a period of halo-gravity traction between the anterior and posterior procedures. Excellent correction and balance were achieved: **(C)** AP and **(D)** lateral post-op radiographs.

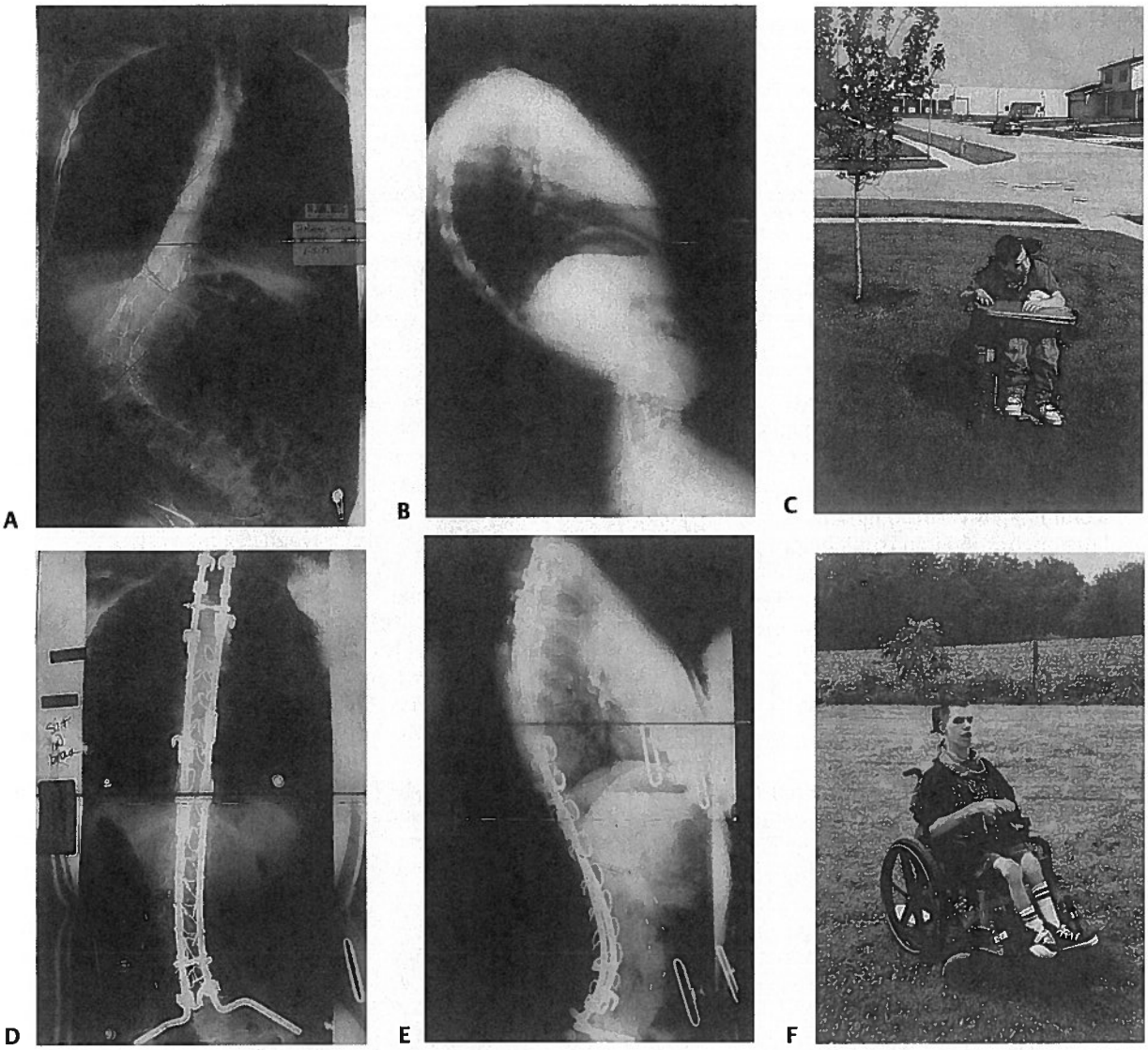

Figure 14–5 This nonambulatory teenager with cerebral palsy developed a significant deformity [**(A)** AP and **(B)** lateral pre-op radiographs] associated with difficulty sitting **(C)**. A same-day ASF and PSF. with instrumentation to the pelvis achieved nice correction [**(D)** AP and **(E)** lateral post-op radiographs], and sitting was markedly improved **(F)**.

underlying neurologic condition may actually have a profound effect on behavior and natural history of the spinal deformity; examples of this would be decompression of a Chiari malformation or the treatment of Duchenne's muscular dystrophy with steroids.

♦ Nonoperative Treatment

Because the deformity can occur in the very young, curve control without resorting to definitive spinal fusion and the subsequent trunk shortening that would occur with such treatment would be desirable. Therefore, young children are often offered brace treatment until the spine has a chance to grow. However, it does not appear that braces affect the natural history of these curves. Braces can improve trunk alignment and make sitting better and more comfortable. However, in order for that to happen, the child must be relatively thin (at least not terribly obese) so that the brace actually fits well. Additionally, the curve needs to be flexible so that passive correction can occur and leveling of the pelvis can occur, otherwise the brace provides absolutely no benefit. "Successful bracing" is continued until age 10 or 11, at which time definitive fusion can be performed without as much trunk shortening as would have occurred with fusion at an earlier age. When braces are used, they should only be used when the patients are up and about, and not be worn at nighttime. Contraindications to bracing are stiff curves with pelvic obliquity, very obese patients whom the brace does not fit properly, and those with an unreliable family situation in which compliance would be a problem.[1–3]

♦ Surgical Treatment

Curves of large magnitude with pelvic obliquity require surgery for proper and permanent correction of trunk malalignment and leveling of the pelvis. In fact, the goals of surgical treatment are the following: correction of the curve in the coronal plane, normalization of sagittal alignment, leveling of the pelvis, and the achievement of a solid fusion (if in fact the surgical treatment being performed is a definitive fusion)[1–3] **(Fig. 14–6)**. Traditionally definitive treatment means a long posterior spinal fusion to the pelvis (with possibly an anterior supplemental fusion) and posterior instrumentation.

However, today there are alternatives to this approach. In certain situations, only a short anterior spinal fusion with instrumentation may be indicated, especially in patients who are less involved neurologically, are walkers, and who have lumbar or thoracolumbar curves. Though this technique does involve a spinal fusion, its effect on trunk height is less than would occur with a long posterior fusion because many fewer vertebrae are involved in the fusion segment[15] **(Figs. 14–7 and 14.8)**. There are some new techniques that fall into the category of "fusionless" spinal correction, and these would include such things as "growing rods," vertebral stapling, and VEPTR (vertical expandable prosthetic titanium rib). Whether stapling will prove to be a permanent and final procedure or whether for a given patient treatment will need to be finished off by converting the stapled spine to a spinal fusion will need to be determined on an individual basis.[16] VEPTR almost certainly will need to be converted to a spinal fusion with instrumentation when the child is considered old enough. The fusionless technique of vertebral stapling is indicated in skeletally immature patients and is envisioned as producing a hemiepiphyseodesis effect on the instrumented segments. Curves ought to be less than 50 degrees at the time of surgery and the child immature enough so that there are several years of growth remaining after the procedure is performed. Otherwise, the procedure will be only a holding device with a modest amount of correction that occurs at the time of the surgery. VEPTR is usually reserved for much younger children (less than 8 years of age) with both chest wall deformity and a spinal deformity. Though early and midterm results in a relatively small number of patients appears encouraging, in terms of curve control and improvement in chest deformity with subsequent improved development of the concave side lung, it requires periodic expansion of the device and replacement when significant growth occurs and the child "outgrows" the currently implanted device. For treating both a chest deformity and a spinal deformity, the hybrid type of VEPTR implant is necessary. VEPTR was envisioned to be used for early onset scoliosis with thoracic insufficiency syndrome but has been used in a limited number of neuromuscular cases, and so far it appears as though these devices can control the curve and avoid the spine shortening that a definitive procedure would produce while at the same time improving chest shape and volume and allowing for development of the hypoplastic lung.[17–20]

However, a long posterior fusion with posterior instrumentation plus or minus anterior spinal fusion is the usual solution for neuromuscular curves. In that regard, some additional principles to be applied when devising surgical strategy need emphasizing. Correction of the pelvic obliquity is essential for most of these patients. Instrumentation and posterior spinal fusion needs to be taken down to and include the pelvis in those with severe curves with significant pelvic obliquity[21] **(Fig. 14–9)**. Though this issue has been debated over and over again, especially as related to Duchenne's muscular dystrophy as well as cerebral palsy, there is little justification to fuse short of the pelvis when there is a large curve and severe pelvic obliquity present preoperatively.[3,5] Fixed pelvic obliquity that persists after the fusion results in an uneven sitting surface, which cannot be adjusted for because of the fusion and may predispose to pressure sores over the lower ischium. Dubousset considers the sacrum/pelvis to function like an additional vertebral segment—the "pelvic vertebra." He describes both "regular" and "opposite" pelvic obliquity, which are good concepts to consider when dealing with pelvic obliquity.[22] If the curve is stiff, then an additional anterior spinal fusion and/or vertebrectomy may be necessary to achieve enough correction of the curve so that the pelvis can be leveled. The addition of the anterior spinal fusion, particularly when it includes the lumbosacral junction, also helps to ensure solid fusion. If the pelvis is not included in the index surgery and the pelvic obliquity worsens, revision will be needed **(Fig. 14–10)**. In some conditions such as Duchenne's muscular dystrophy, the patients may no longer be surgical candidates because of their poor pulmonary status, cardiomyopathy, or other medical problems. Finally, adequate hip flexion is necessary to allow for comfortable and proper sitting after the spinal fusion.[23]

Debate about fusion that includes the pelvis and ambulators continues. Conventional thinking indicates that once this has been done, walking will cease because it will somehow interfere with the mechanics of walking. The presence of hip flexion contracture, spasticity, weakness, or poor muscle control can no longer be compensated for by changing the trunk/pelvis alignment once the fusion is performed. However, if appropriate sagittal plane contouring is incorporated into the spinal construct and perhaps some lower extremity surgery to correct deformities is performed, walking should not be precluded all else being equal. Though walking can continue, it certainly can be affected by the presence of the spinal fusion whether or not lower extremity corrective surgery is performed. Whereas prior to spinal fusion no ambulatory aids may be necessary, crutches, a cane, or a walker might be needed afterwards. For instance, patients with Friedreich's ataxia can no longer have the same kind of spine motion that often aids in their ambulation. Therefore, modification of their walking "style" may be needed as well as ambulatory aids. Polio patients in particular often have peculiar ambulatory mechanics to compensate for significant motor deficits **(Fig. 14–1)**. Many of these patients have severe neuromuscular curves in excess of 100 degrees and yet still walk using limb swing initiated by trunk twisting or rotation to advance their weak

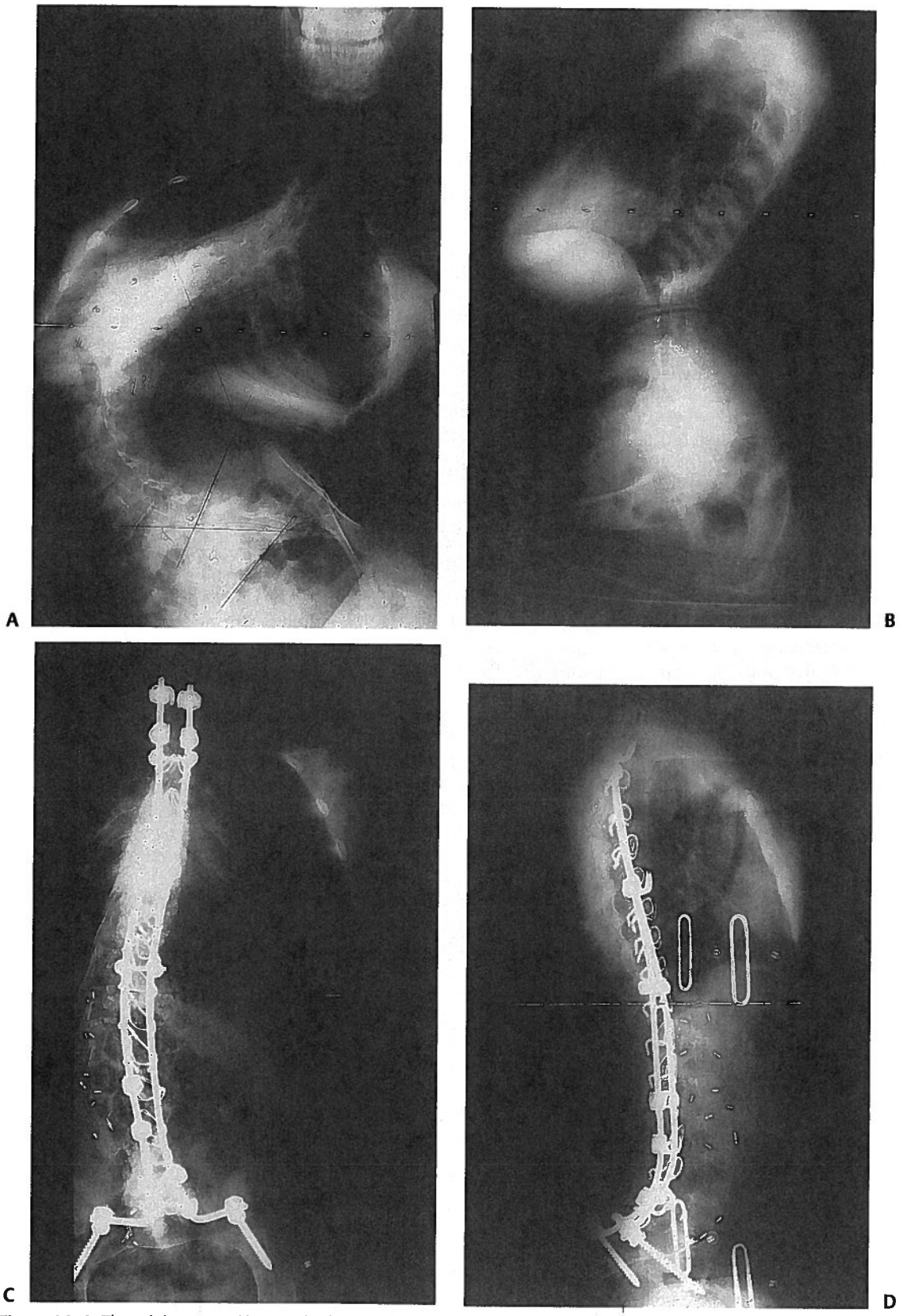

Figure 14–6 This adolescent girl has cerebral palsy with severe coronal and sagittal plane deformities: **(A)** AP and **(B)** lateral pre-op radiographs. A two-stage ASF and PSF with instrumentation to the pelvis provided excellent correction in both planes: **(C)** AP and **(D)** lateral post-op radiographs.

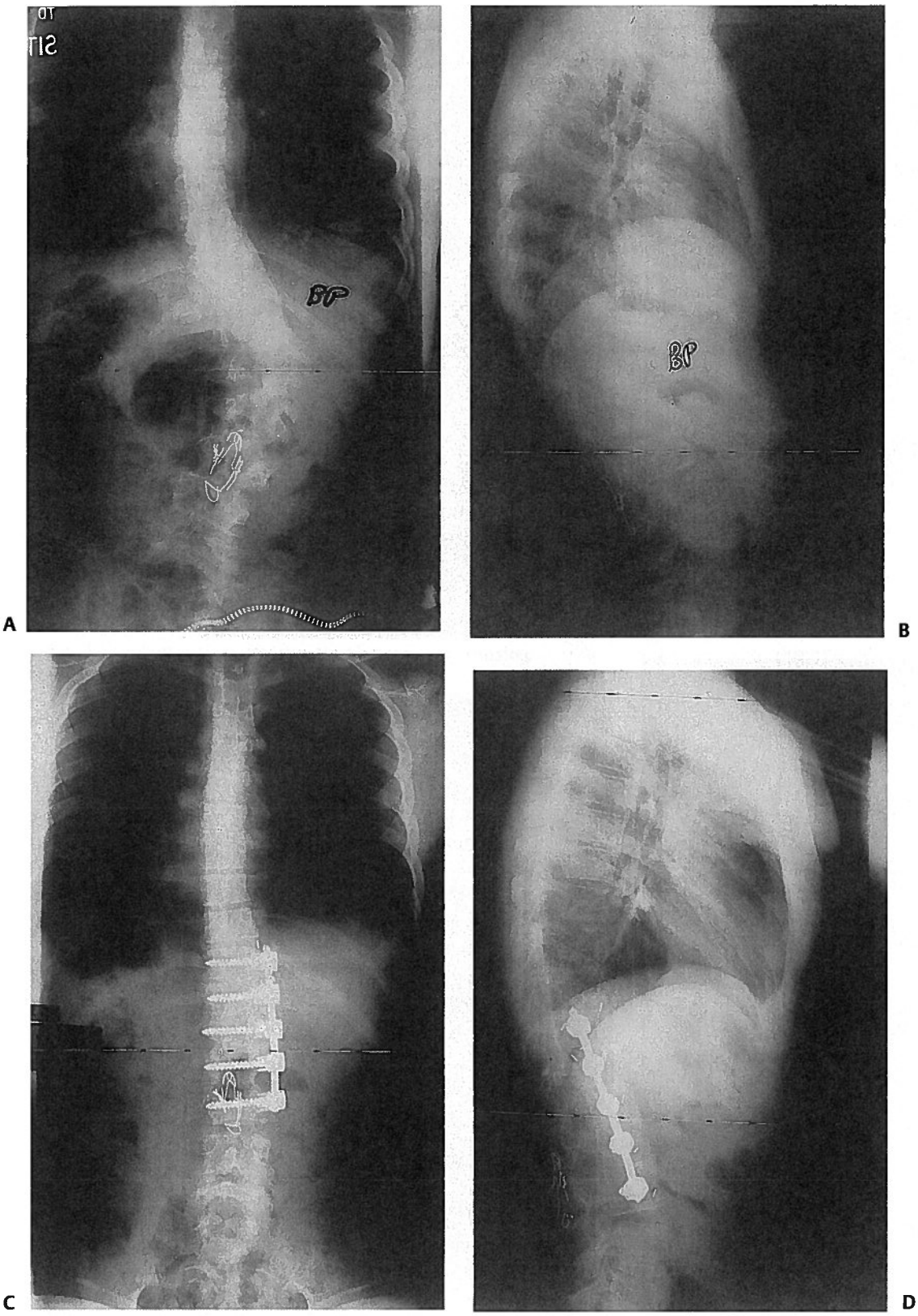

Figure 14–7 This teenager had an incomplete spinal cord injury and was a walker using braces. He developed a progressive scoliosis: **(A)** AP and **(B)** lateral pre-op radiographs. The broken wire was from his spinal injury surgery. ASF with instrumentation alone provided good correction of the deformity while fusing only a short segment of the spine: **(C)** AP and **(D)** lateral post-op radiographs.

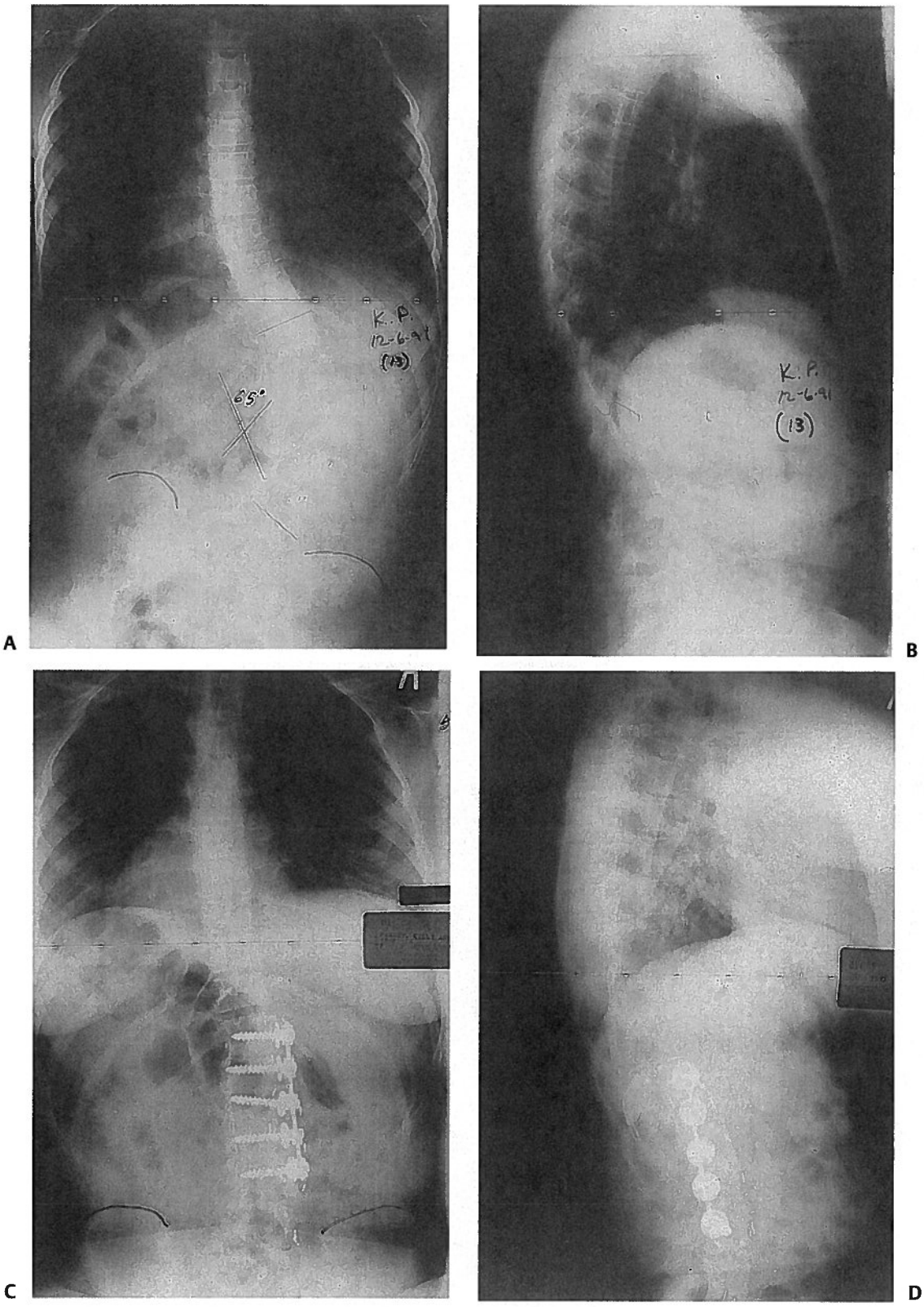

Figure 14–8 This girl had myelomenigocele with little leg motor function but was a good ambulator in HKAFOs. She developed a progressive scoliosis with "regular" pelvic obliquity: **(A)** AP and **(B)** lateral pre-op radiographs. She had a short ASF with instrumentation only and achieved complete scoliosis and pelvic obliquity correction: **(C)** AP and **(D)** lateral post-op radiographs.

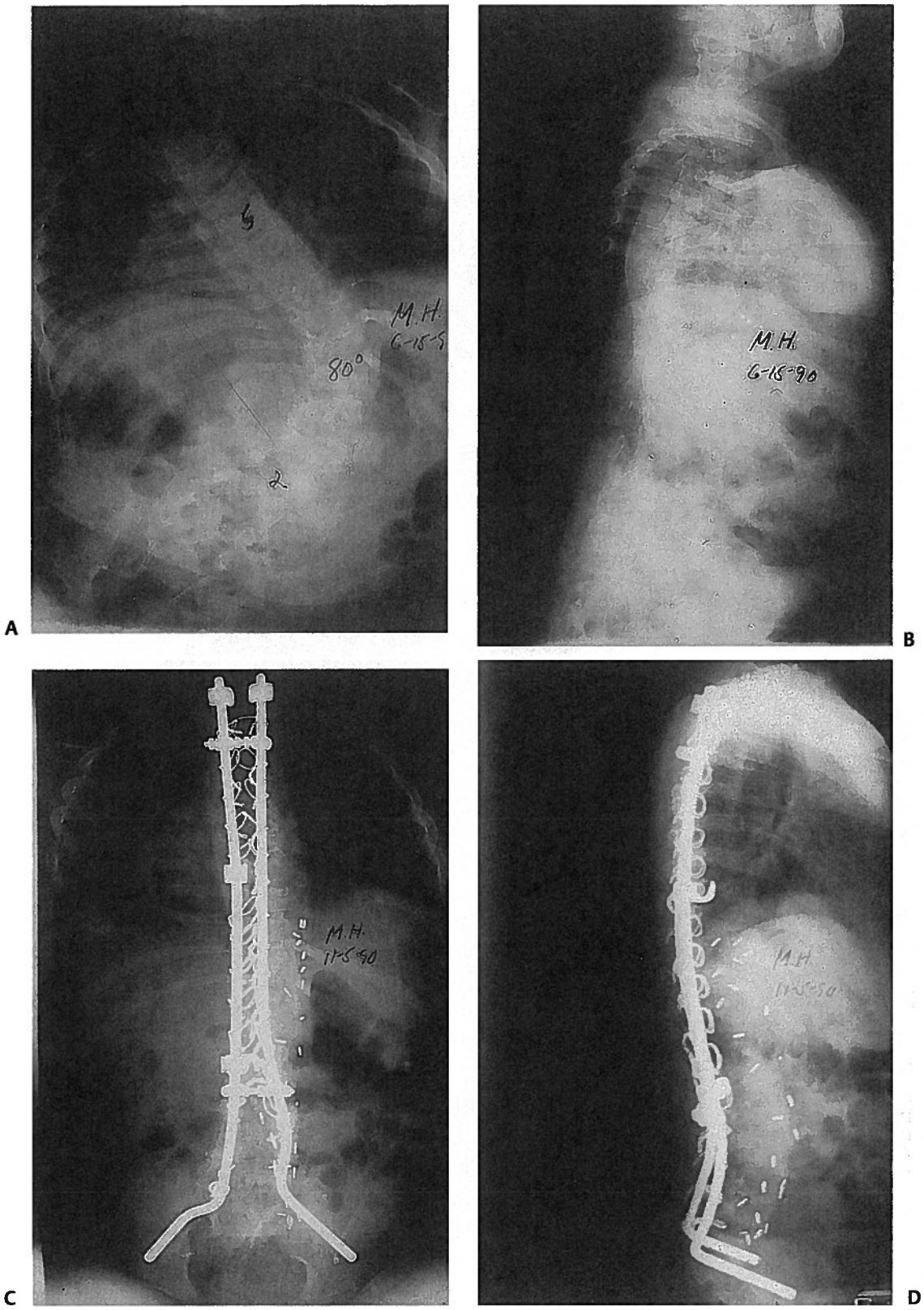

Figure 14–9 This boy has myelomeningocele with a severe progressive deformity: **(A)** AP and **(B)** lateral pre-op radiographs. He underwent a two-stage reconstruction using the Luque technique with Galveston pelvic fixation, but strategically placed hooks were used to provide better correction and stability than could be achieved with the wires alone: **(C)** AP and **(D)** lateral post-op radiographs.

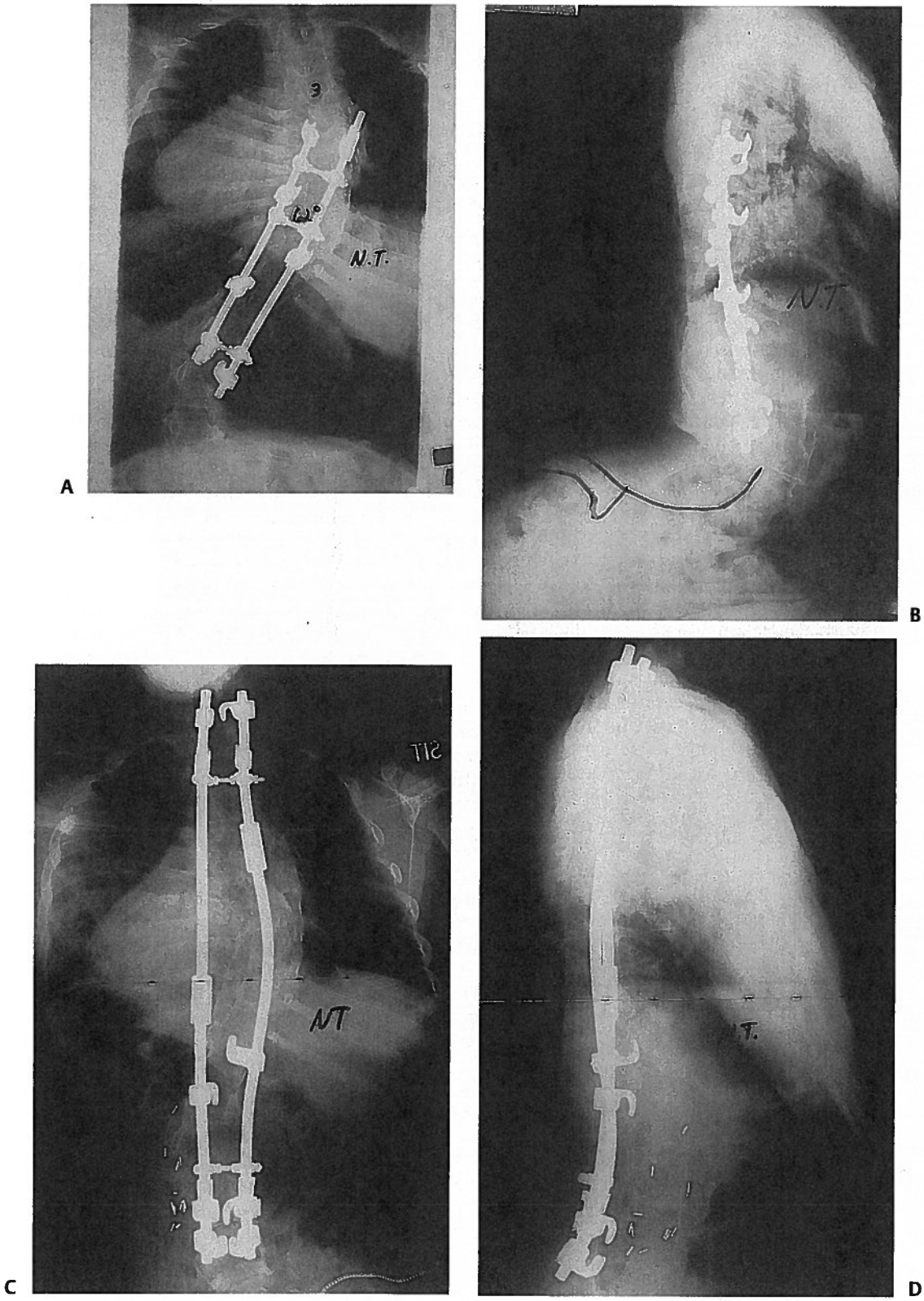

Figure 14–10 Unfortunately, this teenage boy had index surgery for his spinal deformity that was too short. The spine underwent "crankshafting" and developed a severe "holospine" lordosis: **(A)** AP and **(B)** lateral pre-op radiographs. This necessitated a two-level vertebrectomy and revision instrumentation with excellent deformity correction in both planes: **(C)** AP and **(D)**, lateral post-op radiographs.

legs. Once spinal fusion is performed, these trunk motions are decreased or eliminated, thus severely impairing their ambulatory ability.[3,8]

As far as other functional implications are concerned, in patients with upper extremity weakness, loss of height secondary to the curve allows propping of the elbows on the armrest of their wheelchairs and provides the arms with stability for functioning of the hands. Once the scoliosis is corrected, the trunk is elongated and the elbows no longer reach the armrests, making upper extremity function more difficult. Paraplegic patients often use the "long sitting" position during dressing and other activities. Fusion to the pelvis may preclude this or at least interfere with it because of loss of flexibility. In addition, "long sitting" subjects the fusion and instrumentation construct to kyphotic forces, which may predispose to pseudarthrosis if not instrumentation failure.

To illustrate problems with specific diagnoses, Duchenne's muscular dystrophy, spinal cord injury, and myelomeningocele will be discussed in detail to point out the peculiarities of these conditions and how they relate to neuromuscular scoliosis. Similar points can be made concerning other specific conditions as well.

Duchenne's Muscular Dystrophy

Traditional teaching states that once a boy with muscular dystrophy ceases to walk and scoliosis starts to develop, it progresses relentlessly. Once it starts, spinal fusion should be done immediately before pulmonary function deteriorates to the point that he is no longer a surgical candidate because worsening of lung function is associated with curve progression and vice versa.[3,5] However, there is some information that actually questions these axioms. The first is that not all muscular dystrophy curves are progressive. Boys with lordotic spines have less of a tendency for progressive deformity than those with kyphotic ones. Second, the use of systemic steroids seems to be effective in preserving lung function and decreasing the progression of the scoliosis, preserving the ability to walk and prolonging life. Additionally, families are more willing to embark on long-term mechanical ventilation to sustain life than they have been in the past. Obviously then, these issues must be considered when evaluating Duchenne's muscular dystrophy patients with regard to how their deformities will be managed.

Spinal Cord Injury

Spinal cord injury can result in flaccid or spastic paralysis. In can also be complete or incomplete. Depending on the extent of the paralysis and patient motivation, some "walking" may be possible for some patients. The development of a severe spinal deformity may interfere with that ability. Those who are nonambulators face the same challenges as those with other underlying diagnoses in terms of their sitting posture. Spinal deformity in these patients can be due entirely to the paralysis or from failed or inappropriate spinal injury surgery or a combination of both. Problems with index spinal injury surgery are surprisingly common[11] **(Fig. 14–11)**. Additionally, rapid progression of a curve may be related to the development of a syrinx due to secondary destruction of the spinal cord tissue from the original injury. This should be evaluated with spinal cord imaging. Skeletally immature patients and those with no useful lower extremity motor function are at greatest risk for developing significant postinjury spinal deformities[11] **(Fig. 14–12)**.

Myelomeningocele

The less lower extremity function a myelomeningocele patient has, the more he or she is prone to develop a spinal deformity. The indications for operative and nonoperative treatment follow the same guidelines as for any other of these conditions and apply to these patients with the added problem of insensate skin. Rapidly worsening scoliosis needs to be evaluated to rule out shunt malfunction, hydrosyringomyelia, and cord tethering, all of which can be associated with deterioration of the deformity, and reversal or slowing of progression may occur if those problems are recognized and treated.[24] Myelomeningocele has the additional problem of the spina bifida defect in which the posterior elements of the effected vertebrae are absent. Though there is some debate as to whether or not these patients *always* need a concomitant anterior fusion when doing a definitive surgery, the safest way to manage these patients to ensure a solid fusion is to include anterior spinal fusion as well as the posterior spinal fusion with instrumentation across the area of the bifid spine **(Fig. 14–13)**. Short anterior spinal fusion with instrumentation only in those with better function and with lumbar or thoracolumbar curves may be an alternative **(Fig. 14–8)**. The risk of infection, pseudarthrosis, and instrumentation problems remain more common in the myelomeningocele patients than in others with neuromuscular deformity.[9,10] **(Fig. 14–14)**.

Finally, a deformity peculiar to myelomeningocele is myelokyphosis. Children with this severe and progressive kyphotic deformity, which is generally in the lumbar or thoracolumbar area, have the "full dose" of myelomeningocele. Their deformity is present at birth, and its presence often makes closure of the spinal defect very difficult for neurosurgeons. The trunk deformity and shortening causes a very abnormal sitting posture and fosters the development of ribcage deformity, cramps the abdominal contents, decreases chest/lung expansion due to upward displacement of the diaphragm, and can also result in the development of a compensatory thoracic lordosis. The abnormal skin over the gibbus is often prone to repeated breakdown in some patients because the paraspinal muscles have been displaced by the deformity and the overall dysplasia of the spine. The need for and timing of corrective surgery requires careful evaluation and judgment. Delaying kyphectomy, which is the usual procedure for this problem, until the child is older and bigger must be tempered by the thoracolumbar or the thoracic lordosis and recurrent skin breakdown, as well as possible respiratory difficulties.

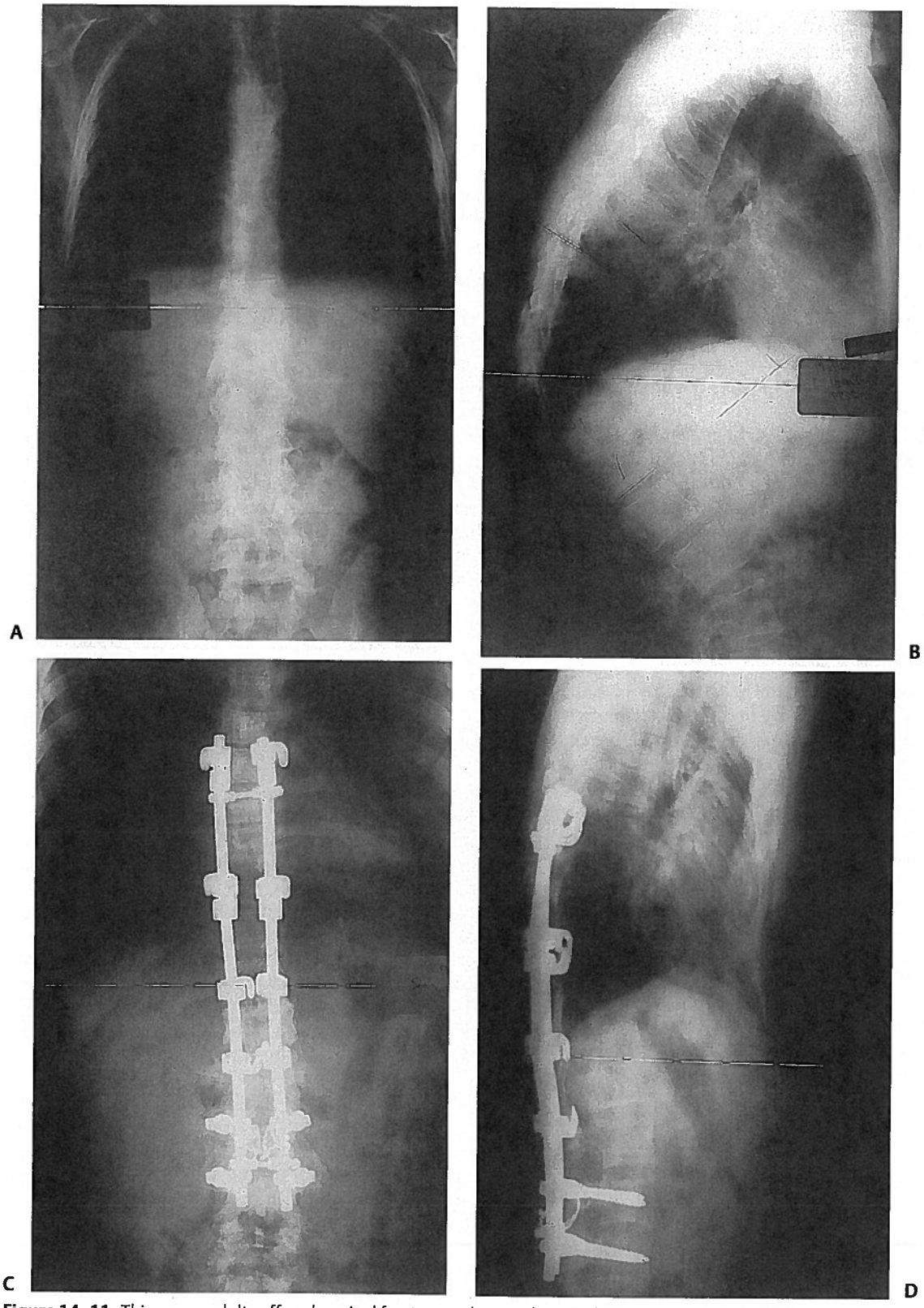

Figure 14–11 This young adult suffered a spinal fracture and a spinal cord injury. The fracture was surgically treated using the "rod long/fuse short" technique with poor original kyphosis correction. The rods were removed per protocol, but an unrecognized pseudarthrosis was present resulting in severe kyphosis: **(A)** AP and **(B)** lateral pre-op radiographs. An ASF and PSF with instrumentation restored the spinal alignment: **(C)** AP and **(D)** lateral post-op radiogrphs.

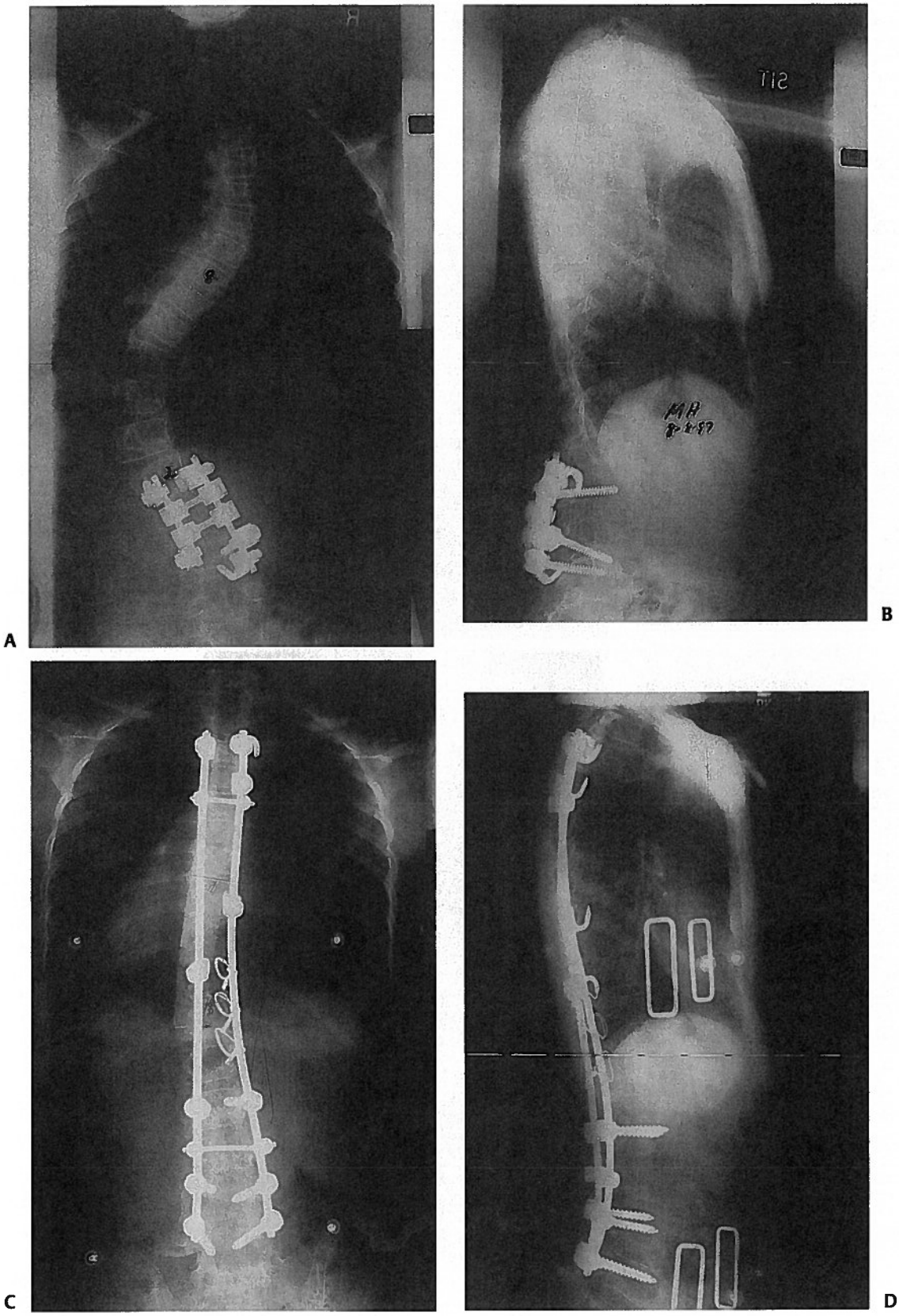

Figure 14–12 This premenarchal girl had a spine fracture and a spinal cord injury for which she underwent surgical treatment. Within a year of the injury, she developed a severe deformity: **(A)** AP and **(B)** lateral pre-op radiographs. Pre-op MRI did not reveal syrinx formation. Revision of the posterior instrumentation and PSF resulted in excellent correction: **(C)** AP and **(D)** lateral post-op radiographs.

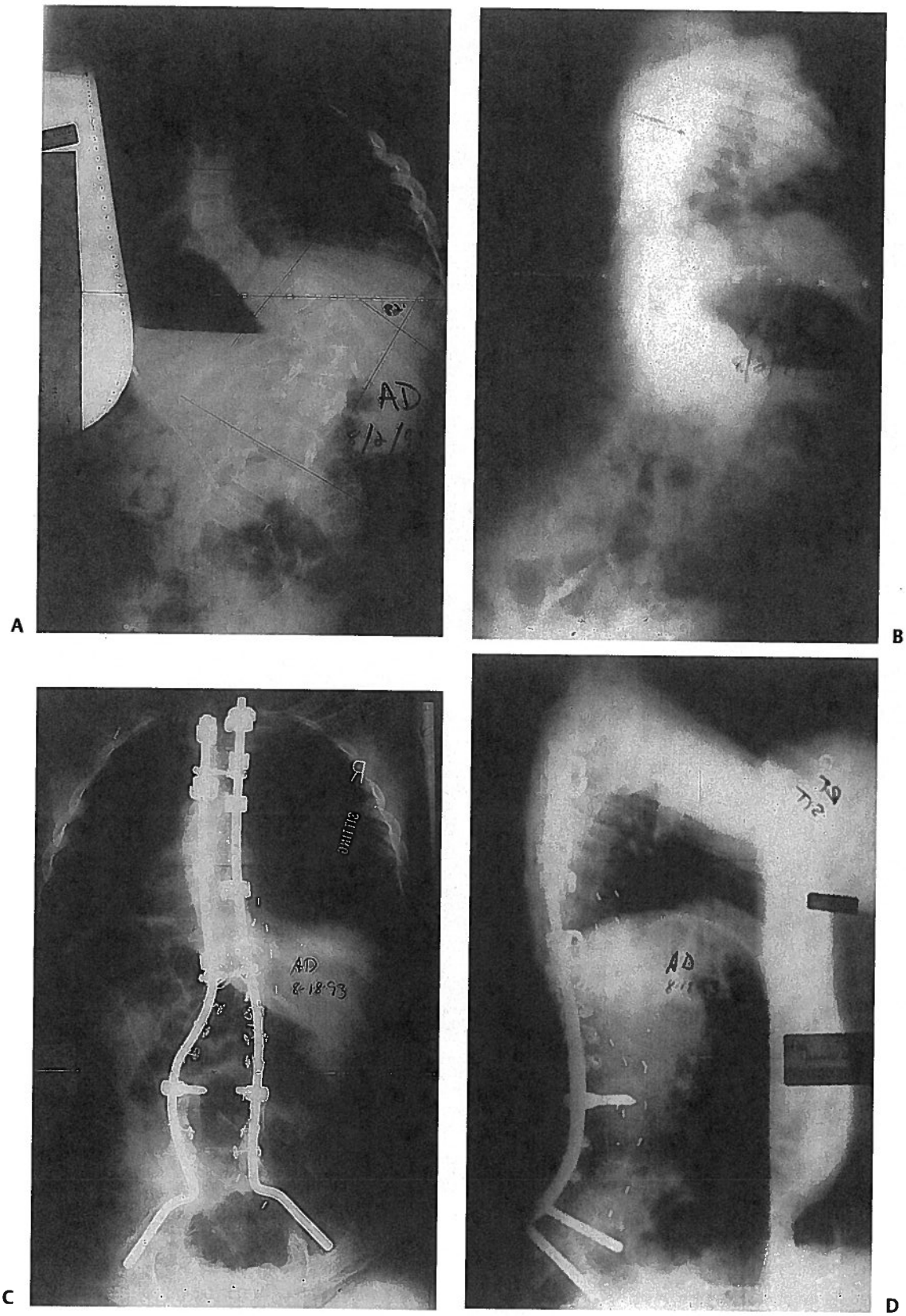

Figure 14–13 This teenager with myelomeningocele has coronal and sagittal plane deformities: **(A)** AP and **(B)** lateral pre-op radiographs. Staged ASF and PSF with instrumentation using different anchors achieved nice correction: **(C)** AP and **(D)** lateral post-op radiographs.

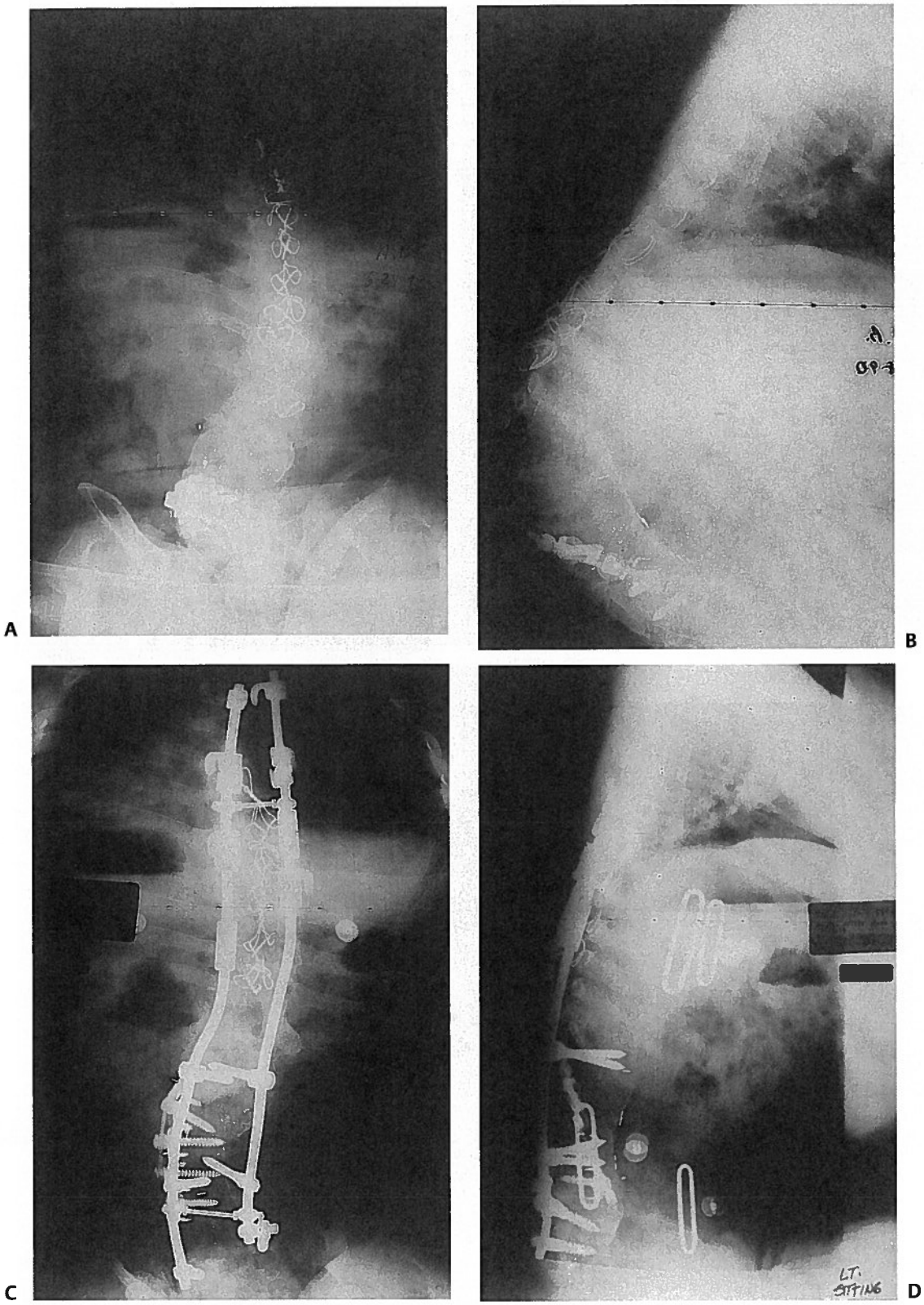

Figure 14–14 This boy had scoliosis surgery using the Dwyer device. He subsequently developed a severe kyphosis. Surgery was performed to correct it, but instrument pull-out occurred with severe soft tissue problems requiring flap coverage. He presented with significant difficulty with sitting: **(A)** AP and **(B)** lateral pre-op radiographs. A posterior approach with spinal cord and pseudarthrosis resection and posterior instrumentation achieved excellent deformity correction and a solid fusion: **(C)** AP and **(D)** lateral post-op radiographs.

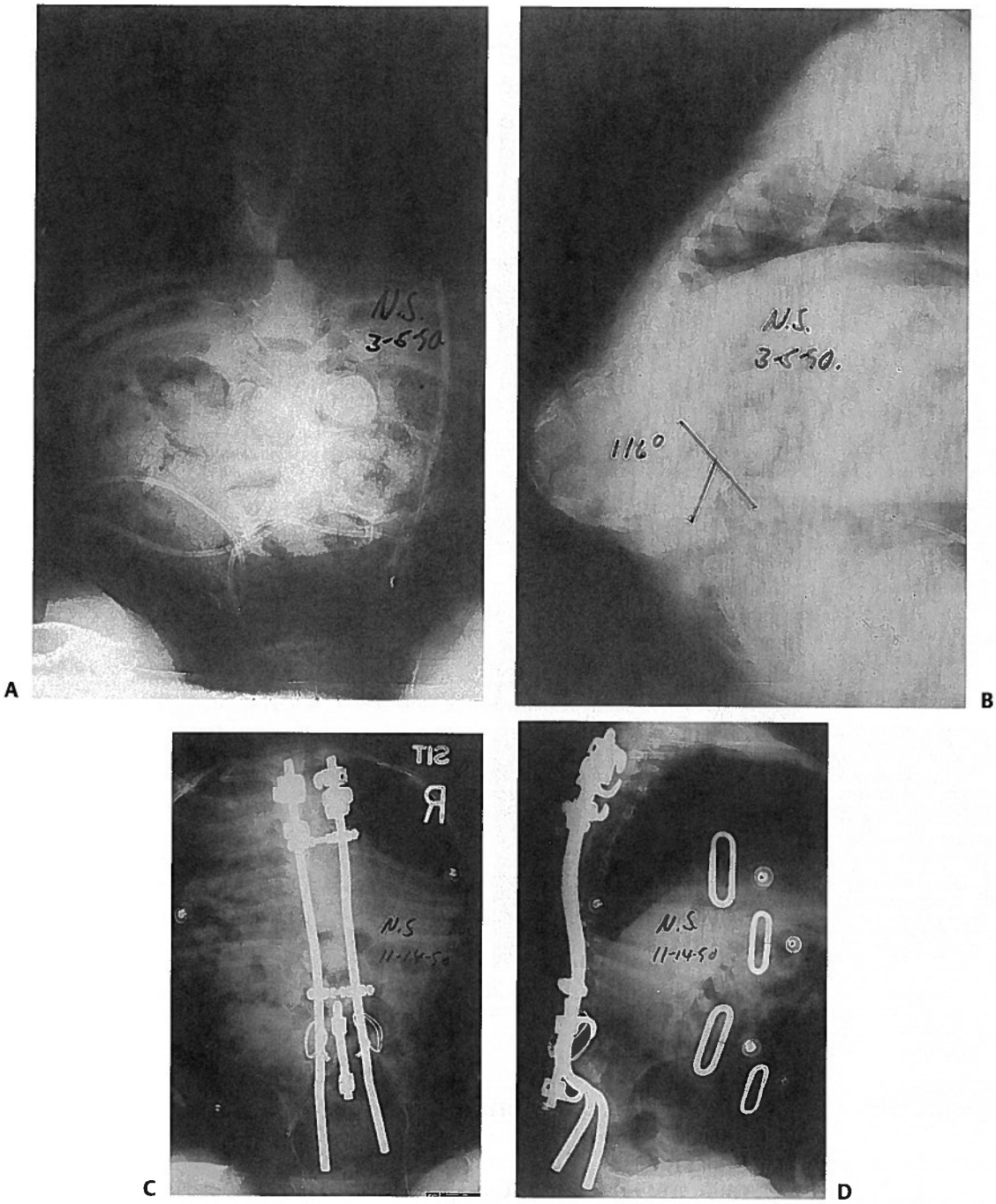

Figure 14–15 This young boy with severe posterior element deficiency and myelokyphosis was having recurrent skin breakdown: **(A)** AP and **(B)** lateral pre-op radiographs. He had a kyphectomy with posterior instrumentation with Heydemann-Gillespie lower rod contouring and hook anchors cranially. He achieved anatomical spinal realignment: **(C)** AP and **(D)** lateral post-op radiographs.

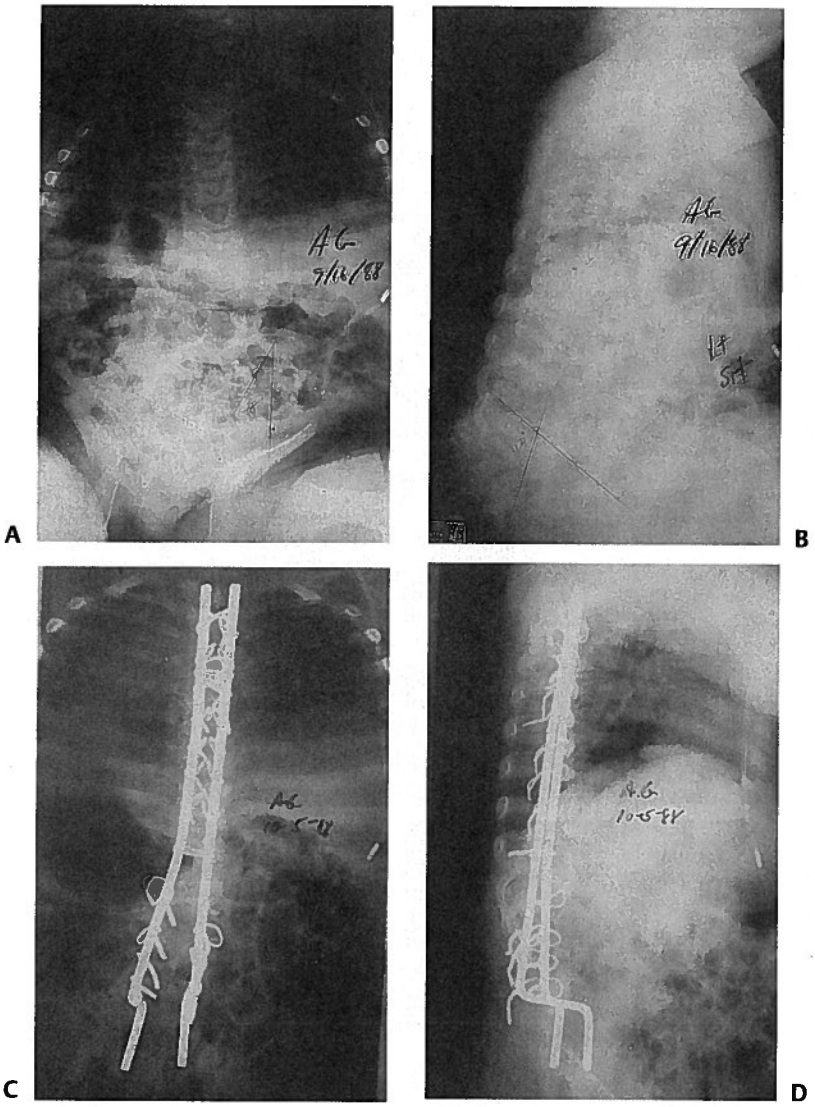

Figure 14–16 This child had a myelokyphosis with difficulty sitting: **(A)** AP and **(B)** lateral pre-op radiographs. He underwent a kyphectomy stabilized with Heydemann-Gillespie long posterior instrumentation. The upper vertebrae were not fused to allow for growth: **(C)** AP and **(D)** lateral post-op radiographs.

Long instrumentation with distal fixation as described by Heydemann and Gillespie seems to be the most effective **(Fig. 14–15)**. Instrumentation without fusion in the thoracic spine allows for some trunk growth while still controlling the corrected deformity below **(Fig. 14–16)**. A functioning VP shunt and hip flexion of at least 90 degrees are important prerequisites for kyphectomy before kyphectomy is performed.[10]

♦ Conclusion

The treatment of neuromuscular spinal deformities is challenging but when successful improves the quality of life of those treated. Adherence to the principles of the spinal surgery and the achievement of the goals stated previously will result in generally good outcomes.

References

1. Lonstein JE. Neuromuscular spinal deformity. In: Weinstein SL, ed. The Pediatric Spine – Principles and Practice. Philadelphia: Lippincott Williams & Wilkins; 2001:789–796
2. McCarthy RE, Saer III EH. Neuromuscular scoliosis. In: Dewald RL, Bridwell KH, eds. The Textbook of Spinal Surgery, 2nd Ed. Philadelphia: Lippincott Raven; 1997:881–902
3. Shook JE, Lubicky JP. Paralytic scoliosis. In: DeWald RL, Bridwell KH, eds. The Textbook of Spinal Surgery, 2nd Ed. Philadelphia: Lippincott Raven; 1997:837–880
4. Chen PQ, Shen YS. Poliomyelitis scoliosis. In: Weinstein SL, ed. The Pediatric Spine—Principles and Practice. Philadelphia: Lippincott Williams & Wilkins; 2001:869–880

5. Hahn GU, Mubarak SJ. Muscular dystrophy. In: Weinstein SL, ed. The Pediatric Spine – Principles and Practice. Philadelphia: Lippincott Williams & Wilkins; 2001:819–832

6. Bowen JR, Lipton GE. Spinal muscular atrophy. In: Weistein SL, ed. The Pediatric Spine – Principles and Practice. Philadelphia: Lippincott Williams & Wilkins; 2001:833–844

7. Lonstein JE. Spinal deformity due to cerebral palsy. In: Weinstein SL, ed. The Pediatric Spine – Principles and Practice. Philadelphia: Lippincott Williams & Wilkins; 2001:797–808

8. Labelle H. Spinal deformity I: Friedeich's ataxia. In: Weistein SL, ed. The Pediatric Spine – Principles and Practice. Philadelphia: Lippincott Williams & Wilkins; 2001:809–818

9. Lindseth RE. Myelomeningocel spine. In: Weinstein SL, ed. The Pediatric Spine – Principles and Practice. Philadelphia: Lippincott Williams & Wilkins; 2001:845–868

10. Lubicky JP. Spinal deformity in myelomenuingocele. In: DeWald RL, Bridwell KH, eds. The Textbook of Spinal Surgery. Philadelphia: Lippincott Raven; 1997:903–932

11. Altiok H, Mekhail A, Vogel LC, Herman JE, Lubicky JP. Issues in surgical treatment of thoraco-lumbar injuries associated with spinal cord injury in children and adolescents. Am J Orthop 2002;11:647–651

12. Amory DW, Godfried DH, Hammerberg KW, Lubicky JP. Effectiveness of spinal deformity correction in children with cerebral palsy and cerebral palsy-like conditions. Paper presented at: Scoliosis Research Society Annual Meeting; San Diego, CA; Sep 1999

13. Comstock C, Leach J, Wenger DR. Scoliosis in total body cerebral palsy: analysis of surgical treatment and patient and caregiver satisfaction. Spine 1998;23:1412–1424

14. Wai EK, Young NL, Feldman BM, Badley EM, Wright JG. The relationship between function self perception and spinal deformity: implications for treatment of scoliosis in children with spina bifida. J Pediatr Orthop 2005;25:64–69

15. Basobas L, Mardjetko SM, Hammerberg KW, Lubicky JP. Selective anterior instrumentation and fusion for neuromuscular scoliosis. Spine 2003;28:S245–S248

16. Betz RR, Kim J, D'Andrea LP, Mulcahey Balsara RK, Clements DH. An innovative technique of vertebral body stapling for the treatment of patients with adolescent idiopathic scoliosis: a feasibility study. Spine 2003;28(20):S255–S265

17. Campbell RM Jr, Hell-Vocke AK. Growth of the thoracic spine in congenital scoliosis after expansion thoracoplasty. J Bone Joint Surg Am 2003;85-A:409–420

18. Campbell RM Jr, Smith MD, Mayes TC, et al. The characteristics of thoracic insufficiency syndrome associated with fused ribs and congenital scoliosis. J Bone Joint Surg Am 2003;85-A:399–408

19. Campbell RM Jr, Smith MD, Mayes TC, et al. The effect of opening wedge thoracostomy on thoracic insufficiency syndrome associated with fused ribs and congenital scoliosis. J Bone Joint Surg Am 2004;86-A:1 659–1674

20. Hell AK, Campbell RM Jr, Hefti F. The vertical expandable prosthetic titanium rib for the treatment of thoracic insufficiency syndrome associated with congenital and neuromuscular scoliosis in young children. J Pediatr Orthop B 2005;14:287–293

21. Mardjetko SM, Lubicky JP. Disorders of the spinopelvic junction: indications for fixation and fusion – pediatric aspects. In: Marguiles J, Floman Y, Farcy J-P, Neuwirth MG, eds. Lumbosacral and Spinopelvic Fixation. Philadelphia: Lippincott Raven; 1996:129–142

22. Dubousset J. Cotrel-Dubousset instrumentation for paralytic neuromuscular spinal deformities with emphasis on pelvic obliquity. In: DeWald RL, Bridwell KH, eds. The Textbook of Spinal Surgery, 2nd Ed. Philadelphia: Lippincott Raven; 1997:933–948

23. Lubicky JP. Anterior scoliosis surgery in cerebral palsy. In: Lenke LG, Betz RR, Harms J, ed. Modern Anterior Scoliosis Surgery. St. Louis: Quality Medical Publishing Inc., 2004:587–602

24. Weprin B, Oakes JB, Lubicky JP. Myelomeningocele: neurosurgical perspectives. In: Vacarro AR, Betz RR, Zeidman S, eds. Principles and Practice of Spine Surgery. St. Louis: Mosby; 2003:667–680

5. Hahn GU, Mubarak SJ. Muscular dystrophy. In: Weinstein SL, ed. The Pediatric Spine – Principles and Practice. Philadelphia: Lippincott Williams & Wilkins; 2001:819–832

6. Bowen JR, Lipton GE. Spinal muscular atrophy. In: Weistein SL, ed. The Pediatric Spine – Principles and Practice. Philadelphia: Lippincott Williams & Wilkins; 2001:833–844

7. Lonstein JE. Spinal deformity due to cerebral palsy. In: Weinstein SL, ed. The Pediatric Spine – Principles and Practice. Philadelphia: Lippincott Williams & Wilkins; 2001:797–808

8. Labelle H. Spinal deformity I: Friedeich's ataxia. In: Weistein SL, ed. The Pediatric Spine – Principles and Practice. Philadelphia: Lippincott Williams & Wilkins; 2001:809–818

9. Lindseth RE. Myelomeningocel spine. In: Weinstein SL, ed. The Pediatric Spine – Principles and Practice. Philadelphia: Lippincott Williams & Wilkins; 2001:845–868

10. Lubicky JP. Spinal deformity in myelomenuingocele. In: DeWald RL, Bridwell KH, eds. The Textbook of Spinal Surgery. Philadelphia: Lippincott Raven; 1997:903–932

11. Altiok H, Mekhail A, Vogel LC, Herman JE, Lubicky JP. Issues in surgical treatment of thoraco-lumbar injuries associated with spinal cord injury in children and adolescents. Am J Orthop 2002;11:647–651

12. Amory DW, Godfried DH, Hammerberg KW, Lubicky JP. Effectiveness of spinal deformity correction in children with cerebral palsy and cerebral palsy-like conditions. Paper presented at: Scoliosis Research Society Annual Meeting; San Diego, CA; Sep 1999

13. Comstock C, Leach J, Wenger DR. Scoliosis in total body cerebral palsy: analysis of surgical treatment and patient and caregiver satisfaction. Spine 1998;23:1412–1424

14. Wai EK, Young NL, Feldman BM, Badley EM, Wright JG. The relationship between function self perception and spinal deformity: implications for treatment of scoliosis in children with spina bifida. J Pediatr Orthop 2005;25:64–69

15. Basobas L, Mardjetko SM, Hammerberg KW, Lubicky JP. Selective anterior instrumentation and fusion for neuromuscular scoliosis. Spine 2003;28:S245–S248

16. Betz RR, Kim J, D'Andrea LP, Mulcahey Balsara RK, Clements DH. An innovative technique of vertebral body stapling for the treatment of patients with adolescent idiopathic scoliosis: a feasibility study. Spine 2003;28(20):S255–S265

17. Campbell RM Jr, Hell-Vocke AK. Growth of the thoracic spine in congenital scoliosis after expansion thoracoplasty. J Bone Joint Surg Am 2003;85-A:409–420

18. Campbell RM Jr, Smith MD, Mayes TC, et al. The characteristics of thoracic insufficiency syndrome associated with fused ribs and congenital scoliosis. J Bone Joint Surg Am 2003;85-A:399–408

19. Campbell RM Jr, Smith MD, Mayes TC, et al. The effect of opening wedge thoracostomy on thoracic insufficiency syndrome associated with fused ribs and congenital scoliosis. J Bone Joint Surg Am 2004;86-A:1 659–1674

20. Hell AK, Campbell RM Jr, Hefti F. The vertical expandable prosthetic titanium rib for the treatment of thoracic insufficiency syndrome associated with congenital and neuromuscular scoliosis in young children. J Pediatr Orthop B 2005;14:287–293

21. Mardjetko SM, Lubicky JP. Disorders of the spinopelvic junction: indications for fixation and fusion – pediatric aspects. In: Marguiles J, Floman Y, Farcy J-P, Neuwirth MG, eds. Lumbosacral and Spinopelvic Fixation. Philadelphia: Lippincott Raven; 1996:129–142

22. Dubousset J. Cotrel-Dubousset instrumentation for paralytic neuromuscular spinal deformities with emphasis on pelvic obliquity. In: DeWald RL, Bridwell KH, eds. The Textbook of Spinal Surgery, 2nd Ed. Philadelphia: Lippincott Raven; 1997:933–948

23. Lubicky JP. Anterior scoliosis surgery in cerebral palsy. In: Lenke LG, Betz RR, Harms J, ed. Modern Anterior Scoliosis Surgery. St. Louis: Quality Medical Publishing Inc., 2004:587–602

24. Weprin B, Oakes JB, Lubicky JP. Myelomeningocele: neurosurgical perspectives. In: Vacarro AR, Betz RR, Zeidman S, eds. Principles and Practice of Spine Surgery. St. Louis: Mosby; 2003:667–680

Chapter 15

Anterior Surgery for Thoracic Scoliosis

Randal R. Betz, Peter O. Newton, Linda P. D'Andrea, David H. Clements III, and Harsh Grewal

Anterior surgery has been used for correction of spinal deformity since 1960. Anterior surgery can used for diskectomy, specifically for a release, to improve curve correction after posterior instrumentation; for improving the fusion rate, especially in adults; or for prevention of crankshaft in young adolescents by eliminating the anterior growth plates. In addition, anterior surgery can be the primary means of correction of thoracic scoliosis.

The use of anterior instrumentation for correction of thoracic curvatures in idiopathic scoliosis was reported by Dwyer and Schafer in 1974[1] using theories developed by Dr. Klaus Zielke for lumbar and thoracolumbar curves.[2–6] However, anterior instrumentation for correction of thoracic curves did not come into general use until the late 1980s, when Dr. Jürgen Harms began elaborating and refining the technique.

♦ Classification of Thoracic Scoliosis

In an effort to determine who would be best suited for anterior surgery, the new classification by Lenke et al.[7] is best in determining the extent of spinal arthrodesis. The major components of the classification system are as follows: The major curve is always the largest curve and is considered structural. The additional curves are considered minor and can be either structural or nonstructural. The structural characteristics are described in **Table 15–1**.

The residual coronal Cobb angle on side-bending films is 25 degrees for residual structural curves. This is independent of the mechanism of side-bending films, whether supine, erect, or fulcrum.

Based on whether the proximal thoracic curve, middle thoracic curve, or the thoracolumbar/lumbar curve is structural or nonstructural, there are basically six curve types: main thoracic, double thoracic, double major, triple major, primary thoracolumbar/lumbar, and thoracolumbar/lumbar with a structural main thoracic curve. The description of these curve types, including whether the curves are structural or nonstructural and their prevalence in a series reported by Lenke et al.,[8] is shown in **Table 15–2**.

Table 15–1 Structural Characteristics of Regional Curves

Regional Curve	Side-Bend Coronal Cobb Angle	Sagittal Plane Angle
Proximal thoracic (PT) curve	≥25 degrees	≥ +20 degrees (T2-T5)
Main thoracic (MT) curve	≥25 degrees	
Thoracolumbar/ lumbar (TL/L)	≥25 degrees	≥ +20 degrees (T12-L2)

Table 15–2 Curve Types (1 to 6) Based on Structural Characteristics of Regional Curves

Curve Type	PT	MT	TL/L	Curve Type	Prevalence[8] (%)
1	NS	S	NS	Main thoracic curve (MT)	51
2	S	S	NS	Double thoracic (DT)	20
3	NS	S	S	Double major (DM)	11
4	S	S	S	Triple major (TM)	3
5	NS	NS	S	TL/L	12
6	NS	S	S	TL/L – Main thoracic curve	3

PT, proximal thoracic curve; MT, middle thoracic curve; TL/L, thoracolumbar/lumar curve; NS, nonstructural; S, structural.

Indications for Anterior Surgical Approach for Thoracic Scoliosis

It is generally believed that anterior spinal surgery with instrumentation for the thoracic curve is an option for patients with curve Type 1. The classification system of Lenke et al. further subdivides these curve types into lumbar modifiers A, B, and C. Type C modifier curves behave as false double-major curves, with the lumbar curve crossing the midline. Generally, any of these Type 1 curves with a modifier A, B, or C are candidates for anterior instrumentation. The type C modifier curves are particularly amenable to treatment with anterior instrumentation for preventing lumbar curve decompensation as is seen in 42% of cases after posterior instrumentation.[9]

Anterior surgery may still play a role in thoracic curve Types 2, 3, and 4 (double thoracic, double major, triple major) where the curves are exceedingly large (greater than 70 degrees) in performing an anterior spinal release for better coronal correction or, on occasion, correction of the thoracic hypokyphosis or thoracic lordosis.

The Lenke et al. classification system further subdivides curves according to the thoracic profile as measured from T5 to T12. Those with sagittal profiles less than 10 degrees are considered hypokyphotic, and in those situations, an anterior release may be considered such that correction of the thoracic kyphosis may be performed consistently. Posterior instrumentation does not consistently correct hypokyphosis with hooks and wires[10] nor even with pedicle screws (personal observation). In the authors' experience, failure to correct the thoracic hypokyphosis significantly leaves the patient vulnerable to development of a proximal thoracic kyphosis.[11]

Indications for Anterior Instrumentation for Thoracic Adolescent Idiopathic Scoliosis

Despite reports of highly satisfactory results of posterior spinal fusion with multisegmented hook-rod-screw fixation, problems have been reported,[9,12–14] including the lumbar curve ending up worse than it was preoperatively, causing unbalancing of the spine[9,12,13,15]; failure to consistently correct hypokyphosis of the thoracic spine[12,14]; and the presence of a thoracolumbar kyphosis postoperatively below the level of instrumentation.[13,15A] The crankshaft phenomenon has been reported after a posterior spinal fusion (PSF) in skeletally immature patients.[16] Lumbar pain below the level of posterior instrumented fusion has been reported by Ginsburg and colleagues[16A] and Cochran and colleagues.[17]

The published indications for anterior instrumentation for correction of thoracic scoliosis include the potential to save two or more distal fusion levels **(Figs. 15–1A to 15–1L)** and/or the ability to correct hypokyphosis (less than 20 degrees of kyphosis). In addition, in skeletally immature patients, an anterior release and fusion may be indicated to prevent the crankshaft phenomenon.[10] In this situation, insertion of anterior instrumentation potentially involves less surgery than an anterior spinal arthrodesis followed by a posterior arthrodesis with instrumentation.[10]

The potential number of fusion levels to be saved can be analyzed as follows: The lower instrumented vertebra (LIV) instrumented with anterior thoracic instrumentation is the end vertebral body of the Cobb measurement or, if there are two parallel vertebrae, the more distal vertebra is used. This then can be compared against the predicted posterior LIV either by the stable vertebrae, the Cotrel-Dubousset method,[18,19] or Suk's method.[20] In the Cotrel-Dubousset method, the disk below the proposed LIV on a bending radiograph must reverse 5 degrees and the LIV must have less than 20% rotation in the mature patient or have no residual rotation in the immature patient. Dr. Suk's method uses the neutral vertebra (NV). If the neutral vertebra is the same as the end vertebra (EV) or one level distal, then it is fused to the NV. If the NV is two levels or more distal to the EV, then it is fused to one level proximal to the NV (NV-1).[20]

Residual hypokyphosis has been reported to occur in up to 60% of cases after posterior multisegmented hook-rod systems,[10,12,13] and anterior instrumentation can consistently correct thoracic hypokyphosis and thoracic lordosis.[10]

Contraindications for Anterior Approach for Thoracic Scoliosis

A double thoracic curve (Lenke et al. Type 2) is one in which the proximal thoracic curve does not bend below 25 degrees. Beware of a proximal kyphosis (T1 to T5) being greater than or equal to 20 degrees and a Lenke Type 2 also.

Patients with preoperative kyphosis (measured from T5 to T12) greater than 40 degrees should have posterior instrumentation. Anterior instrumentation (single rod) cannot correct nor maintain kyphosis.[20A]

♦ Surgical Treatment

Open Technique

Indications for the Open Technique

Currently, the author only uses an open approach when it is not possible to do the surgery thoracoscopically. Most commonly, this is due to inability to use one-lung ventilation.

Technique

Most commonly, we use a double thoracotomy with a single skin incision.

Results of the Open Technique

The authors, along with other members of the Harms Study Group, conducted a prospective study[10] of two cohort groups of patients (one group receiving anterior instrumentation and the other posterior instrumentation) receiving treatment for thoracic idiopathic scoliosis. The objective was to

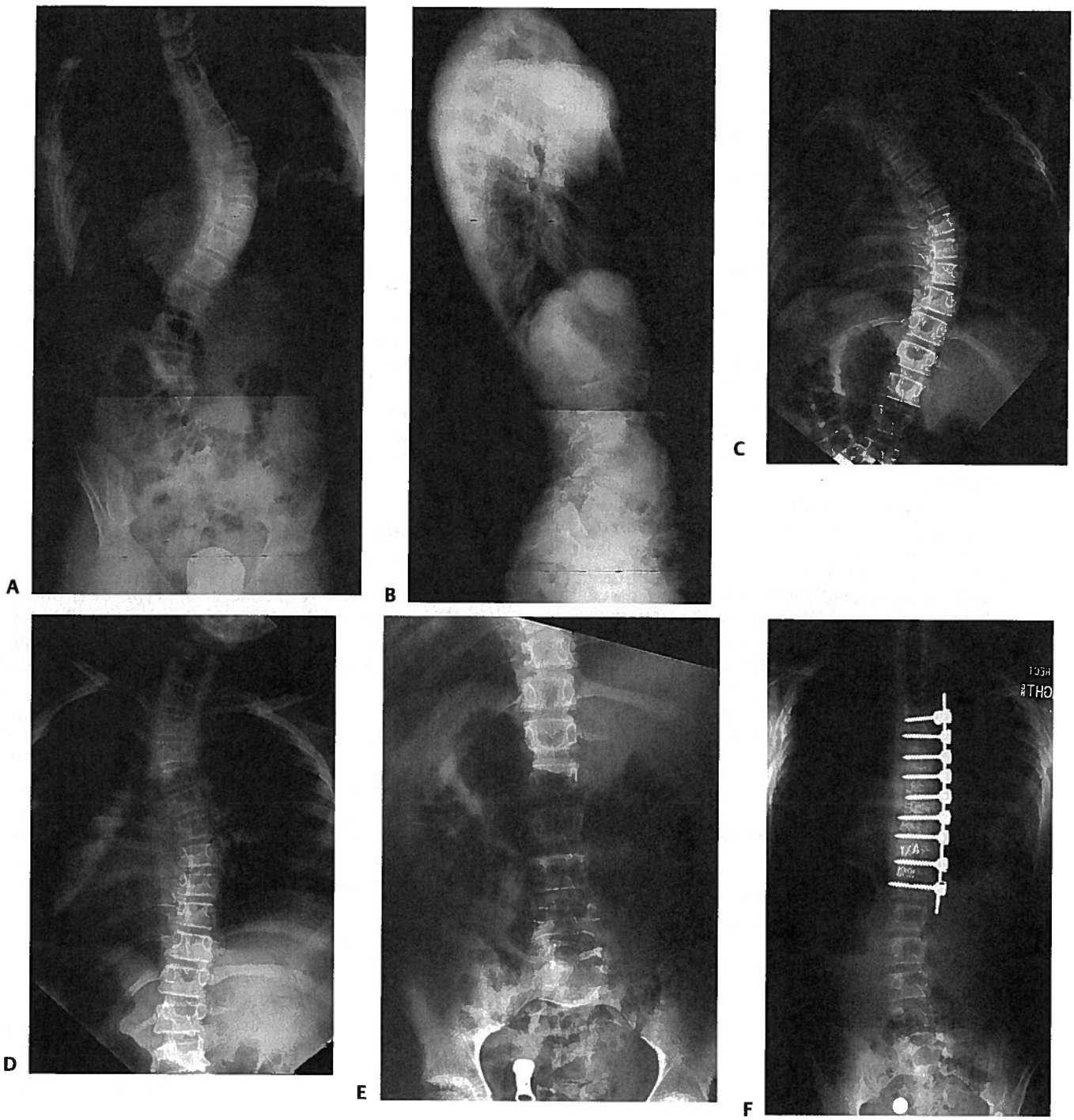

Figure 15–1 Posterior/anterior (PA) **(A)** and lateral **(B)** erect of the thoracolumbar spine on a 14″ × 36″ film showing a Type 1CN Lenke curve in this 14-year-old male. The left upper thoracic curve bends down below 25 degrees **(C)**. The main right thoracic curve bends down to 30 degrees **(D)**. The left lumbar bend shows the lumbar curve to be extremely flexible; it bends down to almost 0 degrees **(E)**. This erect postoperative PA **(F)** and lateral

(Continued)

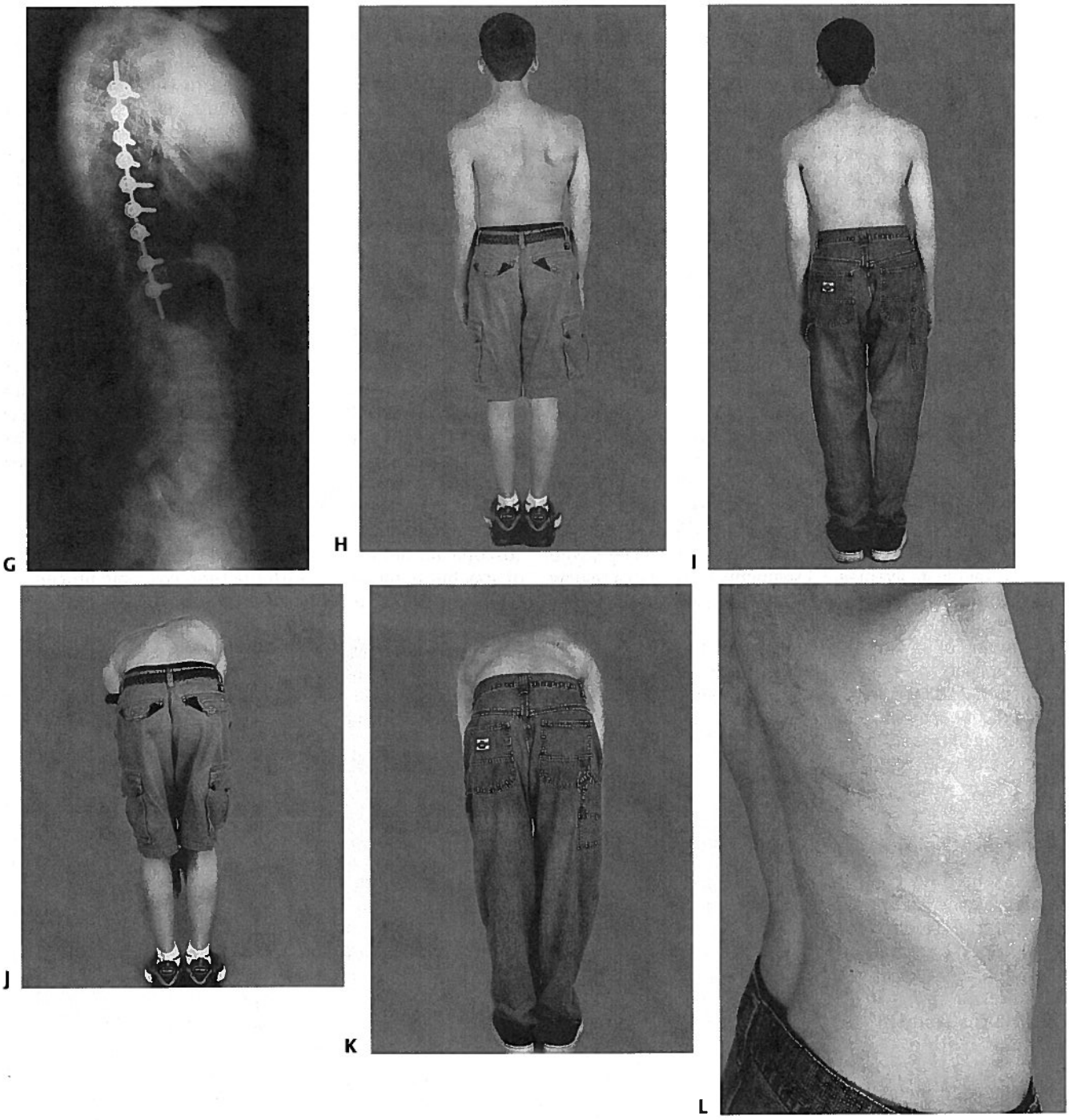

Figure 15–1 *(Continued)* **(G)** was taken after minimally invasive thoracic anterior instrumentation. Clinical pre **(H)**- and postoperative **(I)** photographs. Bending Adams test preoperative **(J)** versus postoperative **(K)** showing dramatic improvement in the preoperative thoracic rib prominence just after anterior instrumentation. No thoracoplasty was performed. **(L)** Close-up of the skin incisions showing the minimally invasive approach with extension of the distal thoracotomy portal into a mini-thoracotomy.

present the 2-year postoperative results of a prospective multicenter study comparing the use of anterior instrumentation with that of posterior multisegmented hook instrumentation for the correction of adolescent thoracic idiopathic scoliosis.

The physician's traditional criterion for evaluating the outcome of scoliosis surgery has been postoperative radiographic improvement, but there are currently no comprehensive, objective radiographic analyses in the literature. This multicenter study (five institutions) included patients with thoracic idiopathic scoliosis treated surgically with a minimum 2-year follow-up. Ninety-eight patients had anterior instrumentation (anterior group) and 122 had posterior instrumentation (posterior group). The average age at surgery was 14.3 and 14.4 years,

respectively, and the preoperative curves averaged 53 and 56 degrees, respectively. The 100-point radiographic scoring system includes both coronal and sagittal measurements. The preoperative radiographic score in the anterior group was 59 ± 8.9 and 57 ± 8.9 degrees in the posterior group, improving to 86 ± 10.3 in the anterior group and 83 ± 7.0 degrees in the posterior group at 2 years. Most of the improvements occurred in the coronal score (38 preoperatively to 64 at 2 years in the anterior group versus 36 to 62 in the posterior group). The sagittal scores changed little in either group. Regarding lumbar spine position in relation to the center sacral vertical line, there was no change in 62% of the anterior versus 66% of the posterior group, improved position in 33% versus 28%, and worsening in 5% versus 6%. In 73 of 98 patients (74%), the fusion stopped at or above L1 in the anterior group versus only 45 of 122 patients (37%) in the posterior group. In conclusion, equal improvement was seen postsurgery in both groups. However, patients with anterior instrumentation were consistently fused shorter than those in the posterior group.

The most significant advantage of anterior instrumentation for thoracic idiopathic scoliosis appears to be the number of distal fusion levels saved (mean 2.5 levels).[10] This is in agreement with a study by Hammerberg and Zielke[20B], who reported saving an average 2.3 segments distally in a review of 32 patients who underwent ventral derotation scoliosis (VDS) for correction of idiopathic scoliosis.

The saving of any lumbar fusion levels, not just the lower lumbar, appears to be significant regarding prevention of future back pain. Ginsburg et al.[16A] conducted a review of 113 patients operated between 1946 and 1972 (average 28-year follow-up) and concluded that scoliosis fusions should include as few lumbar segments as possible.

Perioperative Complications

Most research on complications after spine surgery are clouded by the grouping of multiple diagnoses, with few concentrating solely on idiopathic scoliosis. We analyzed the perioperative complications of 673 patients with thoracic adolescent idiopathic scoliosis (AIS) treated with either anterior spinal fusion (ASF) or PSF from the DePuy Spine Harms Study Group Database. "Perioperative" complications (within 3 months of surgery) were defined as "major" (those that caused permanent sequelae, necessitated a second major operation, or required a prolonged hospital stay [≥3 weeks]) or "minor" (those that necessitated a minor operation, caused significant temporary hardship, caused persistent minor problems, or prolonged the hospital stay [<3 weeks]). Because databases tend to underreport minor complications, the charts of those patients from the Philadelphia center were specifically reviewed. Of these 159 patients, 83 patients had ASF and 76 had PSF. The ASF included only open thoracotomies, and none in the PSF group had anterior release, but all had thoracoplasties. The average preoperative curve was 51 degrees in the ASF group and 54 degrees in the PSF group. Average age at surgery was 14 years.

In the Philadelphia center patients, there was one major complication of acute respiratory distress syndrome (1/159, or 0.6%). This complication occurred in the ASF group (1/83, or 1.2%), and there were none in the PSF group. There were 13 patients with minor complications (13/159, or 8%). Of these, 6 (7%) occurred in the ASF group and 7 (8%) in the PSF group. Two patients in the ASF group and one patient in the PSF group had an additional complication. The majority of minor complications in both groups were pulmonary. Five patients (6%) in the ASF group and 5 patients (7%) in the PSF group had either a pleural effusion requiring reinsertion of a chest tube or tapping under CT guidance, or atelectasis.

Thoracoscopic Technique

Once it has been decided that an anterior approach may be of benefit, a minimally invasive option for the approach may be considered. In one study, Rosenthal and Dickman found thoracosopy to be associated with less operative time, less blood loss, shorter duration of chest tube usage, decreased usage of pain medication, and shorter hospitalization time as compared with thoracotomy.[21] Newton et al.[22] compared open anterior release and fusion to thoracoscopic for deformity and showed no difference in length of stay but higher costs with the thoracoscopic procedure. Most surgeons still believe that the advantages of the thoracoscopic procedure include muscle sparing and improved cosmesis, but these are yet to be proved.

A question that arises in using the thoracoscopic approach for anterior release and fusion is whether adequate spine flexibility can be obtained. Wall et al.[23] looked at biomechanical flexibility obtained after thoracoscopic and open diskectomy in swine and found it to be comparable, and similar results were obtained in a goat model by Newton et al.[24] A clinical study comparing thoracoscopic release versus open release was done by Newton et al.[22] in a small series of 10 patients in each group. This study showed no statistically significant difference in the amount of correction obtained via posterior instrumentation when the anterior release was done either open or thoracoscopically.

The next question that arises is whether adequate disk annulus and end plate can be removed to create a good bed for fusion with thoracoscopic techniques. Bunnell[25] reported that greater than 50% of the disk end plate had to be resected to obtain an adequate anterior spinal fusion. Huntington et al.[26] compared open versus thoracoscopic diskectomies in a sheep model and found no statistically significant difference in the amount of end plate resected between the two approaches. In addition, they found no statistical difference in the number of disks that had 50% of their end plate resected.

There are several variations of thoracoscopic instrument insertion. The Newton, Betz, Clements technique[27] includes making two to three portals anterolaterally to perform annular release, disk removal, end plate obliteration, fusion, and thoracoplasty when needed.

In contrast, another method developed for thoracoscopic technique is that of Picetti and colleagues,[28] who use only posterolateral portals for both the diskectomy approach and the insertion of the instrumentation. They use a guide pin and cannulated screws and require intraoperative radiographic

imaging. A case report of a tension pneumothorax on the contralateral chest secondary to pin migration, however, has been reported (A. Crawford, personal communication.)

Indications for the Thoracoscopic Technique

A thoracic idiopathic curve (Lenke et al. Type 1[7]) that measures between 40 and 70 degrees by the Cobb method is the primary indication (**Figs. 15–2A and 15–2B**). In a study by Lenke and colleagues,[7] Type 1 primary thoracic curves accounted for 51% of the curves in a consecutive series of 606 surgical patients. We have performed the thoracoscopic instrumentation technique on both right and left thoracic curves. Ideally, for a pure thoracoscopic approach, the end vertebra of the primary curve should fall within T4 to T12, as exposure and visualization may be compromised beyond those limits. The liver and diaphragm may block adequate exposure below T12, and the intercostal space may not allow insertion of instrumentation above T4. If the end Cobb angle vertebra is L1 or L2, we would do a small thoracotomy (3 to 4 cm) at T9-T10 or T10-T11 to put a retractor on the diaphragm. The upper thoracic curve should correct below 25 degrees on the side-bending films. Kyphosis should definitely be less than 40 degrees and probably closer to 30 degrees. A lateral Stagnara view can be helpful.

Contraindications for the Thoracoscopic Technique

Contraindications include prior surgical procedures in the chest cavity to be entered or a history of pleural adhesions or scarring, due to the subsequent inability to completely collapse the lung.

Surgical Technique

The patient is initially intubated supine with a double lumen tube and then turned to a lateral decubitus position so that the convexity of the curve is up. An axillary roll is used along with padding under the legs and greater trochanter and between the legs. The legs are scissored so that there is no excessive pressure on the down leg. An airplane arm board is used for the up arm, and arm position is crucial to allow room

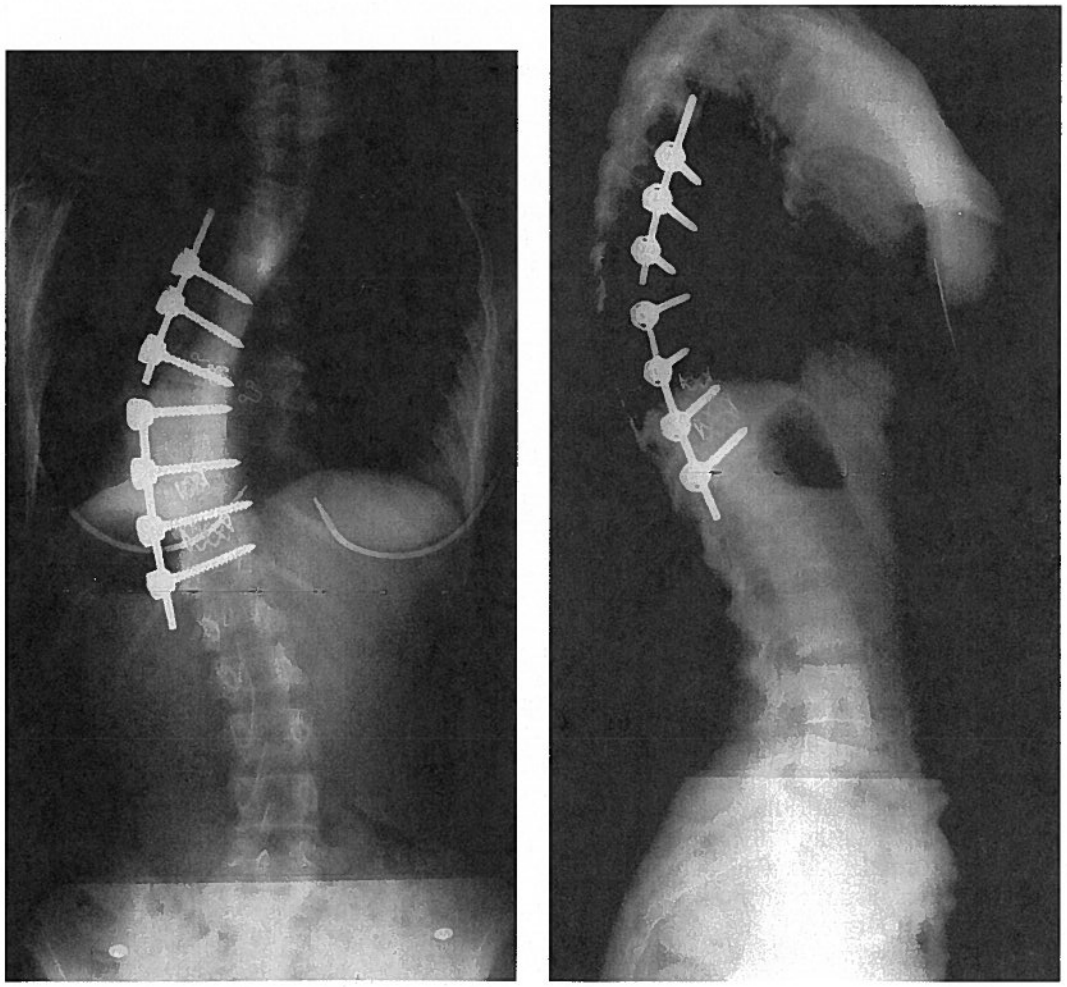

A B

Figure 15–2 (A, B) This patient has a broken rod between T8 and T9 secondary to pseudarthrosis. In the senior author's experience, a kyphotic deformity preoperatively predisposes one to rod breakage.

for the surgeons to stand facing the patient's chest. The scapula should be shifted posterior to allow access to the intercostal space in the posterior axillary line at T6 and above. A single lumen tube with a blocker, or a double lumen tube, is used. The position of the tube is checked with a bronchoscope after intubation and subsequently after positioning the patient in the lateral decubitus position. The lung in the cavity to be entered is deflated before prep and draping to ensure that the patient can tolerate one-lung ventilation.

At this point, image intensification can be used to identify the potential portal sites along the posterolateral axillary line. The first stage of the procedure involves the diskectomy and release. Two to three portals are placed in the anterior axillary line to allow access to the thoracic spine. We normally insert the first portal at the level of the inferior crease of the breast and then visualize the entry of the subsequent portals. Care should be taken in the distal portals not to damage the diaphragm and liver. Thirty- and 45-degree thoracoscopes are used to visualize the spine and endoscopic instruments to retract the lung, pleura, and diaphragm. A long K-wire is inserted along the posterior axillary line into a disk space. The angle of insertion assists in placing the subsequent portals for insertion of the vertebral screws. A radiograph is taken to determine the level, and the disk is marked. The pleura is then incised in a longitudinal fashion across the disks, and the segmental vessels are ligated. We use the harmonic scalpel or bipolar coagulation to perform the ligation. The pleura is then bluntly dissected over the rib heads and down under the concavity of the spine. A sponge is packed between the spine and the pleura on the concave side.

Diskectomy is performed by incising the annulus circumferentially with the monopolar cautery or harmonic scalpel. The annulus and nucleus are removed with pituitaries and the end plates with a Cobb endoscopic elevator. Diskectomy can be accomplished back to the posterior longitudinal ligament, if desired. The empty disk spaces are then packed with powdered gel foam. When all the diskectomies have been performed, attention is turned to the thoracoplasty.

Next, an internal thoracoplasty (if necessary) can be performed. For severe deformity, resect 4 to 5 ribs per case. This has a positive effect on cosmesis and the flexibility of the spine. The rib harvested is chopped into small pieces to use as bone graft. The pleura is dissected off the internal rib surface with the monopolar cautery or harmonic scalpel. Angled 90- and 45-degree endoscopic dissectors are then used to free the rib edges and the external rib surface. The rib is cut medially at its junction with the transverse process and then laterally ~2 cm. The rib heads are left intact. Gel foam strips are placed in the rib beds.

At this stage, the disk spaces are packed with bone graft, either autologous iliac crest or rib pieces. Attention is then turned to inserting the instrumentation. A K-wire is inserted in the posterior axillary line at the most proximal intercostal space above the upper end vertebra to be instrumented. The K-wire is directed at the vertebral body, with the anterior inferior point of the rib head being the marker for entering the sulcus of the vertebra, parallel to the posterior wall of the vertebra. An x-ray should be taken at this point to confirm the angle of approach and the vertebral level. A 3-cm incision parallel and directly on top of the inferior rib of the appropriate interspace is made. A portal is then inserted into the intercostal space, and a sharp, long-handled straight awl is inserted through the portal and an entry hole made on the lateral aspect of the vertebral body at the anterior-inferior corner of the rib, in the middle of the vertebral sulcus. The awl is removed and the first screw is inserted. The thoracoscope should be in the opposite portal to the vertebra to allow orientation for angle at entry point. For the most proximal vertebra, usually a 30- to 35-mm-long screw, with two washers, is inserted. The tip of the screw should be visualized or palpated with a thin vascular clamp on the opposite side of the vertebra or confirmed with x-ray. At least two threads of the screw must engage the opposite vertebral body (average protrusion of 2 to 3 mm on the concave side). We use two washers on the proximal screw to reduce the dislodging force because of a usual step-off of the top two vertebrae. Using this approach has reduced the usual 10% incidence of proximal screw pull-out.[28A]

The next portal is then placed through the same skin incision, but inferior to the rib. Thus, two screws may be inserted through each portal, one above and one below the rib centered in the portal. The next screw usually is 30 mm long without a washer. Each subsequent portal is created on the posterior axillary line, anticipating a perpendicular approach to each vertebrae. Each screw should be in the same position in each vertebrae. When a rod is then inserted, a derotation force will be placed on the spine. Care must be taken to line up the screws in a smooth arc on insertion to allow the rod to engage the screw heads easily. Also, the heights of the screw heads must be approximated to allow full seating of the rod. After all the screws are inserted, an x-ray may be taken to visualize their angle of insertion and depth of penetration of the opposite cortex. If screw placement is difficult, the inferior portal and/or superior portal can be converted to a minimal thoracotomy incision (3 to 5 cm).

The rod length is then measured. A string or trial rod may be used to determine length. Care must be taken not to cut the rod too short. The appropriate sagittal profile can be bent into the rod, but it is usually inserted straight. If the patient is immature (Risser 0), anticipate 15 degrees of additional kyphosis with growth secondary to overgrowth of posterior elements.[29]

Using the morselized autograft from the ribs or iliac crest, each disk space is packed full after removing the powdered gel foam. A tamp is used to ensure complete filling of each disk space. Structural support such as allograft or cages must be used in the distal disk spaces (T10 and below). Once the disk spaces are packed, the rod is inserted.

At this point, the most distal posterior portal may be extended slightly to allow retraction of the diaphragm and insertion of the rod. Using a rod holder, the rod is inserted into the distal portal and guided proximally. It is checked for length visually and inserted into the most proximal screw first, and held in place with a rod pusher inserted through a more distal portal. The set screws are introduced through the proximal portal and inserted into the screw head, but are left loose. After 2 or 3 screws are engaged with the rod, the rod rotation is checked by the rod marking, which should be directly lateral. If it is, the proximal plugs or caps are tightened. If it is not, the rod is rotated using the endoscopic rod rotator until the rod marking is lateral. Then, using cantilever forces,

the rod is reduced into the subsequent screw heads and the deformity is corrected. Optional reduction screws facilitate ease of the cantilever reduction or rod reduction devices (P. Newton, personal communication). The axillary roll should be removed, as it blocks correction. A standard compressor is then introduced through the anterior portals, and the screw heads are sequentially compressed toward the apex and tightened. The second author prefers initial compression superiorly and working distally.

By extending the distal portal into a mini-thoracotomy, a dual screw, dual rod for the lowest three segments can be performed. This may reduce the pseudarthrosis rate (**Figs. 15–3A and 15–3B**).

A wake-up test is then performed and an x-ray is taken to check the final position of the instrumentation and the correction of the scoliosis. A chest tube is inserted and the portals are closed with subcuticular stitch.

Postoperative Care

We use an intrapleural catheter with a lidocaine pump for pain control in the immediate postoperative period. The patients are transferred to an intensive care setting and extubated when stable. They are gotten out of bed on postoperative day 1 and measured for a thoracolumbosacral orthosis (TLSO). When the chest tube is removed, usually on postoperative day 2 to 3, they are allowed to ambulate as tolerated. They are discharged in the TLSO, to be worn for 3 months.

Results of Thoracoscopic Technique

In a recent study,[30] Newton et al. reported a case series of idiopathic scoliosis patients treated with thoracoscopic anterior instrumentation compared with a similar group of patients treated by open anterior instrumentation. There were 38 thoracoscopic instrumentation cases with greater than 6 months' follow-up that were compared with 68 anterior open instrumentation cases. The radiographic outcomes were similar (60% ± 11% versus 59% ± 17% thoracic curve correction for the thoracoscopic and open groups, respectively). The reduction in forced vital capacity was significantly ($p = 0.01$) greater in the open group (0.6 ± 0.3 L) compared with the endoscopic group (0.4 ± 0.3 L). There was a trend toward greater return of shoulder girdle strength and range of motion 6 weeks after surgery in the thoracoscopic patients.

Another study on defining the learning curve for performing a thoracoscopic anterior spinal fusion and instrumentation for adolescent idiopathic scoliosis was recently reported by Sucato et al.[31] They reviewed 147

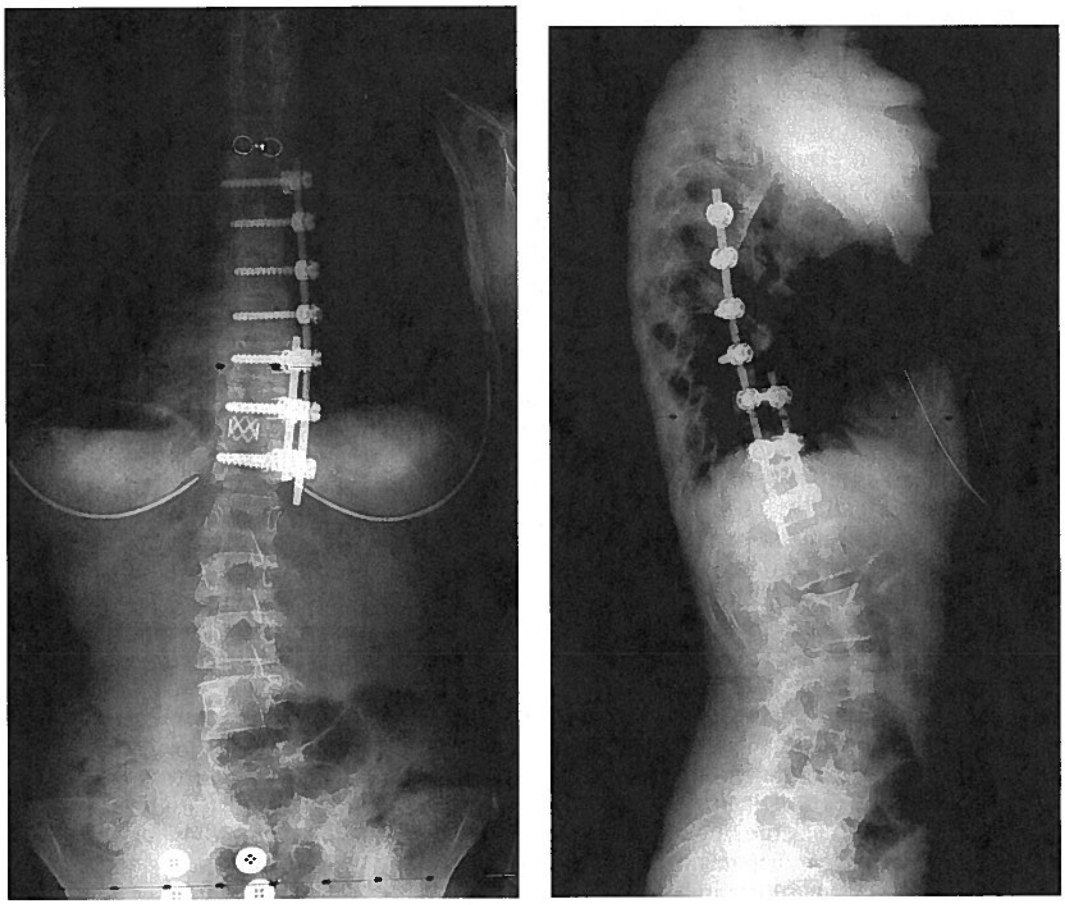

Figures 15–3 (A, B) This is a patient after anterior instrumentation for thoracic idiopathic scoliosis. Through a mini-incision in the distal portal, a dual screw and dual rod system was able to be applied in an effort to prevent future pseudarthrosis.

patients (132 females, 15 males) from 9 institutions. The average age of the patients was 13.7 ± 2 years. There were differences in technique with respect to position of the surgeon (anterior or posterior); pleural closure performed (yes, 44%; no, 56%); and type of graft used (rib, 49%; iliac crest, 51%). These variations did not influence surgical time, curve correction, or complications. The preoperative main thoracic curve was 52.4 ± 8.1 degrees, corrected to 19.3 ± 9 degrees (63.2% correction) postoperatively and 21.9 ± 9.8 degrees (58.2% correction) at 1-year follow-up. Curve correction at 1 year was better in the early group compared with the late group (60.6 versus 55.0%; $p = 0.1$). Thoracic kyphosis improved from 20.3 ± 10.2 degrees preoperatively to 22.6 ± 10.1 degrees postoperatively and 26.7 ± 11.3 degrees at 1 year. The surgical time per disk level decreased from 76.4 minutes in the early group to 70.3 minutes in the late group ($p = 0.09$). Estimated blood loss was 649 ± 454 cc with no change over time ($p < 0.3$). The incidence of complications was 53% (78 of 147) and significantly decreased with surgeon experience ($p < 0.005$). There were no neurologic injuries. Intraoperative complications included proximal screw pullout in 8 (5%) and screw cutout requiring operative plan change in 1 (0.7%). Early postoperative complications included prolonged chest tube drainage in 9 (6%) and pleural effusion requiring tube reinsertion or thoracentesis in 4 (3%). Late postoperative complications included pseudarthrosis in 7 patients (5%), loss of proximal fixation in 5 (3%), and reoperation (planned or not) in 18 patients (12%). Probability analysis demonstrated that the likelihood of having no complications was 90% when surgeon experience reached 35 cases.

♦ Other Issues Associated with Anterior Spinal Fusion

Spontaneous Correction of the Lumbar Curve

A commonly asked question concerning selected fusion of the thoracic curve with anterior instrumentation is whether the spontaneous correction of the lumbar curve will continue to hold up over time, and is it any better than selected posterior instrumentation? In a study by Lenke et al.,[32] not only did the lumbar curve spontaneously reduce predictably, but this correction either stayed improved or, on occasion, continued to improve over a 2-year follow-up. Although this similar pattern occurred in the posterior (control) group, the amounts of correction obtained were dramatically different. Overall, for thoracic curvatures instrumented selectively with anterior spinal fusion (ASF), they obtained 58% correction, and the lumbar curve spontaneously corrected 56% at 2-year follow-up. In the posterior group, only 38% correction was obtained in the thoracic curve and, likewise, spontaneous correction of the lumbar curve was only 37%. This was found to be even more significant in the King II double-major curves, where the mean thoracic curves were 65 degrees in the anterior group and 67 degrees in the posterior group. The mean residual curve in the anterior group was 27 degrees and in the posterior group 49 degrees, with percent correction 59% and 27%, respectively. Similarly, the residual lumbar curves at 2-year follow-up were only 21 degrees in the anterior group versus 37 degrees in the posterior group (50% correction and 30%, respectively).

A similar trend in proximal thoracic curve spontaneous correction has been reported by Kuklo et al.[33]

Pulmonary Function

Graham et al.[34] observed 44 patients with thoracic adolescent idiopathic scoliosis (average age, 15 years) who had pulmonary function tests (PFTs) evaluating volume (FVC), flow (FEV-1), and total lung capacity (TLC) and showed a significant decline in PFT absolute values (L) of 27% FVC, 15% FEV-1, and 11% TLC at 3 months postoperatively with continued improvement to baseline with no statistical difference between preoperative values and those measured at 2 years postoperatively. These results are identical to those of posterior spinal fusion (PSF) with thoracoplasty, and it raises the question of whether the temporary effect is secondary to the thoracoplasty associated with the ASF.

Progressive Sagittal Kyphosis

When skeletal immaturity is an indication for anterior instrumentation to prevent crankshaft, one needs to be aware of the potential for hyperkyphosis in these immature patients. Recently, D'Andrea et al.[29] reported the phenomenon of progressive sagittal kyphosis after ASF in immature patients. They showed that in patients with a Risser 0 who underwent ASF, 60% developed kyphosis greater than 40 degrees as compared with only 27% of patients operated on at Risser 1 to 4. The patients who progressed after the ASF did so an average of 15 degrees. Therefore, when performing ASF on immature patients, we currently advise reducing the residual kyphosis at the time of surgery through use of structural interbody grafts, anticipating a 15-degree progression of sagittal deformity as the patient matures. The exact etiology of this progressive sagittal kyphosis is unclear. D'Andrea et al.[29] speculate that it may be due to overgrowth of the posterior elements with a solid ASF.

♦ Conclusion

Despite the widespread posterior use of thoracic pedicle screws for thoracic adolescent idiopathic scoliosis, the true benefit of anterior instrumentation for saving distal levels as compared with posterior instrumentation is not known. There probably is still a significant number of patients in whom distal levels can be saved, but we await the data. The major advantage to having the ability to instrument the spine anteriorly is that it lends itself to the advantages of minimally invasive surgery.

References

1. Dwyer AF, Schafer MF. Anterior approach to scoliosis. Results of treatment in fifty-one cases. J Bone Joint Surg Br 1974;56:218–224
2. Kostuik JP, Carl A, Ferron S. Anterior Zielke instrumentation for spinal deformity in adults. J Bone Joint Surg Am 1989;71:898–912
3. Lowe TG, Peters JD. Anterior spinal fusion with Zielke instrumentation for idiopathic scoliosis. A frontal and sagittal curve analysis in 36 patients. Spine 1993;18:423–426
4. Moe JH, Purcell GA, Bradford DS. Zielke instrumentation (VDS) for the correction of spinal curvature. Analysis of results in 66 patients. Clin Orthop Relat Res 1983;180:133–153
5. Ogiela DM, Chan DPK. Ventral derotation spondylodesis. A review of 22 cases. Spine 1986;11:18–22
6. Swank SM, Brown JC, Williams L, Stark E. Spinal fusion using Zielke instrumentation. Orthopedics 1982;5:1172–1182
7. Lenke LG, Betz RR, Harms J, et al. Adolescent idiopathic scoliosis: a new classification to determine extent of spinal arthrodesis. J Bone Joint Surg Am 2001;83:1169–1181
8. Lenke LG, Betz RR, Clements D, et al. Curve prevalence of a new classification of adolescent idiopathic scoliosis: can classification predict treatment? Spine 2002;27:604–611
9. Bridwell KH, McAllister JW, Betz RR, Huss G, Clancy M. P.L. S. Coronal decompensation produced by Cotrel-Dubousset "derotation" maneuver for idiopathic right thoracic scoliosis. Spine 1991;16:769–777
10. Betz RR, Harms J, Clements DH, et al. Comparison of anterior and posterior instrumentation for correction of adolescent thoracic idiopathic scoliosis. Spine 1999;24:225–239
11. Betz RR. Kyphosis of the thoracic and thoracolumbar spine in the pediatric patient: normal sagittal parameters and scope of the problem. AAOS Instructional Course Lectures. Rosemont, IL: American Academy of Orthopaedic Surgeons; 2004:479–484
12. Lenke LG, Bridwell KH, Baldus C, Blanke K, Schoenecker PL. Cotrel-Dubousset instrumentation for adolescent idiopathic scoliosis. J Bone Joint Surg Am 1992;74:1056–1067
13. Richards BS, Birch JG, Herring JA, Johnston CE, Roach JW. Frontal plane and sagittal plane balance following Cotrel-Dubousset instrumentation for idiopathic scoliosis. Spine 1989;14:733–737
14. Richards BS, Herring JA, Johnston CE, Birch JG, Roach JW. Treatment of adolescent idiopathic scoliosis using Texas Scottish Rite Hospital instrumentation. Spine 1994;19:1598–1605
15. Lenke LG, Bridwell KH, Baldus C, Blanke K. Preventing decompensation in King type II curves treated with Cotrel-Dubousset instrumentation. Spine 1992;17:S274–S281

15A. Massey TB, Winter RB, Lonstein JE, Denis F. Selection of fusion levels with special reference to coronal and sagittal balance in right thoracic adolescent idiopathic scoliosis using Cotrel-Duboussel instrumentaion. 25th Annual Meeting of the Scoliosis Research Society; Honolulu, Hawaii, 23–27 Sept 1990

16. Dubousset J, Herring JA, Shufflebarger HL. The crankshaft phenomenon. J Pediatr Orthop 1989;9:541–550

16A. Ginsburg HH, Goldstein L, Haake PW, Perkins S, Gilbert K. Longitudinal study of back pain in postoperative idiopathic scoliosis: long-term follow-up, phase IV. 30th Annual Meeting of the Scoliosis Research Society; Asheville, North Carolina, 13–16 Sept 1995

17. Cochran T, Irstam L, Nachemson A. Long-term anatomic and functional changes in patients with adolescent idiopathic scoliosis treated by Harrington rod fusion. Spine 1983;8:576–584
18. Chopin D, Morin C. Cotrel-Dubousset instrumentation for adolescent idiopathic scoliosis. In: Bridwell KH, DeWald RD, eds. The Textbook of Spinal Surgery. Philadelphia: Lippincott; 1991:198
19. Shufflebarger HL. Theory and mechanisms of posterior derotation spinal systems. In: Weinstein SL, ed. The Pediatric Spine: Principles and Practice. New York: Raven Press; 1994:1518
20. Suk S-I, Lee S-M, Chung E-R, Kim J-H, Kim W-J, Sohn HM. Determination of distal fusion level with segmental pedicle screw fixation in single thoracic idiopathic scoliosis. Spine 2003;28:484–491

20A. Clements DH, Betz RR, Lowe TG, Lenke LG, Newton PO. Adolescent idiopathic scoliosis with excessive thoracic kyphosis: comparison of anterior versus posterior instrumentation for maintaining correction. 35th Annual Meeting of the Scoliosis Research Society; Cairns, Australia, 18–21 Oct 2000

20B. Hammerberg KW, Zielke K. VDS instrumentation for idiopathic thoracic curvatures. 52nd Annual Meeting of the American Academy of Orthopaedic Surgeons; Las Vegas, Nevada, 24–29 Jan 1985

21. Rosenthal D, Dickman CA. Thoracoscopic microsurgical excision of herniated thoracic disks. J Neurosurg 1998;89:224–235
22. Newton PO, Wenger DR, Mubarak SJ, Meyer RS. Anterior release and fusion in pediatric spinal deformity. A comparison of early outcome and cost of thoracoscopic and open thoracotomy approaches. Spine 1997;22:1398–1406
23. Wall E, Bylski-Austrow DI, Shelton FS, Crawford AH, Kolata RJ, Baum DS. Endoscopic diskectomy increases thoracic spine flexibility as effectively as open diskectomy. A mechanical study in a porcine model. Spine 1998;23:9–15
24. Newton PO, Cardelia JM, Farnsworth CL, Baker KJ, Bronson DG. A biomechanical comparison of open and thoracoscopic anterior spinal release in a goat model. Spine 1998;23:530–535
25. Bunnell WP. Anterior spinal fusion: experimental evaluation of technique. J Pediatr Orthop 1982;2:469–477
26. Huntington CF, Murrell WD, Betz RR, Cole BA, Clements DH, Balsara RK. Comparison of thoracoscopic an open thoracic diskectomy in a live ovine model for anterior spinal fusion. Spine 1998;23: 1699–1702
27. Betz RR, Clements DH. Thoracoscopic anterior release and fusion for idiopathic scoliosis: focus on technique, morbidity, and future applications. In: Fabris D, ed. Il Trattamento Precoce della Scoliosis Idiopatica e Congenita. Bologna, Italy: Aulo Gaggi Editore; 1996: 99–103
28. Picetti G 3rd, Blackman RG, O'Neal K, Luque E. Anterior endoscopic correction and fusion of scoliosis. Orthopedics 1998;21:1285–1287

28A. Betz RR, Lenke LG, Lowe TG, Harms J, Clements DH, Newton PO, et al. Proximal screw pull-out during anterior instrumentation for thoracic scoliosis: preventive techniques. 35th Annual Meeting of the Scoliosis Research Society; Cairns, Australia, 18–21 Oct 2000

29. D'Andrea LP, Betz RR, Lenke LG, Harms J, Clements DH, Lowe TG. The effect of continued spinal growth on sagittal contour in patients treated by anterior instrumentation for adolescent idiopathic scoliosis. Spine 2000;25:813–818
30. Newton PO, Marks MC, Faro FD, et al. Use of video-assisted thoracoscopic surgery to reduce perioperative morbidity in scoliosis surgery. Spine 2003;28:S249–S254
31. Sucato DJ, Newton PO, Betz RR, et al. Defining the learning curve for performing a thoracoscopic anterior spinal fusion and instrumentation for AIS: A multi-center study. Presented at the NASS Annual Meeting, Philadelphia, Pennsylvania; 27 Sep to 1 Oct 2005
32. Lenke LG, Betz RR, Bridwell KH, Harms J, Clements DH, Lowe TG. Spontaneous lumbar curve coronal correction after selective anterior or posterior thoracic fusion in adolescent idiopathic scoliosis. Spine 1999; 24:1663–1671
33. Kuklo TR, Lenke LG, Won DS, et al. Spontaneous proximal thoracic curve correction following isolated fusion of the main thoracic curve in adolescent idiopathic scoliosis. Spine 2001;26:1966–2001
34. Graham EJ, Lenke LG, Lowe TG, et al. Prospective pulmonary function evaluation following open thoracotomy for anterior spinal fusion in adolescent idiopathic scoliosis. Spine 2000;25:2319–2325

Chapter 16

Posterior Surgery for Thoracic Scoliosis

Yongjung J. Kim and Lawrence G. Lenke

Since the introduction of the Harrington Rod Instrumentation System (hooks and distracting rods) in the late 1950s,[1] spinal instrumentation has evolved in an effort to maximize correction and stabilization. Advances have been made toward trying to obtain balanced correction, to save more motion segments, and to get patients back to their previous daily activities more quickly with less reliance on bed rest, casting, or bracing. The next step in the evolution was using two rods for a thoracic curve and achieving segmental fixation with sublaminar wires. Luque[2] introduced segmental fixation using sublaminar wires in the 1970s and Drummond et al.[3] subsequently modified the Luque technique by using segmental wiring through the base of the spinous process (Wisconsin wiring technique). In the early 1980s, the Cotrel-Dubousset (CD) spinal instrumentation system was introduced.[4] CD instrumentation using multiple hooks with both rods became a new standard of posterior spinal instrumentation in an effort to get even stronger fixation and to "derotate" the spine to optimize three-dimensional correction. This original CD instrumentation technique has evolved into several hybrid variants: (1) hook anchors at the top and the bottom of the curve with Wisconsin wires in between; (2) hook anchors at the top and pedicle screw anchors at the bottom of the curve with sublaminar wires in between; (3) proximal hook anchors and distal pedicle screw anchors. CD instrumentation allows distraction, compression, translation, lordosing, and kyphosing forces for deformity correction. Biplane correction (coronal and sagittal) of the deformity became possible using CD instrumentation **(Fig. 16–1)**.

The next evolutionary phase for posterior treatment has been that of using pedicle screws more liberally throughout the thoracic and upper lumbar spine.[5–11] As spinal instrumentation and surgical techniques in addition to experience of surgeons have evolved, pedicle screw fixation in the thoracic spine can be safely placed reducing the possibility of short-term (neurovascular or visceral damage) and long-term complications (curve progression, crankshaft phenomenon, coronal or sagittal imbalance, loss of fixation, implant failure, or pseudarthrosis).[5–11] The benefits of using pedicle screws instead of hooks or sublaminar wires are many: three-column fixation allows better pull-out strength and greater control in the sagittal, coronal, and rotational planes due to increased stability to axial, bending, and rotational forces. Additionally, fewer vertebral motion segments may need to be arthrodesed and should lessen or obviate the need for postoperative bracing. Other benefits include secure fixation after a laminectomy, when the posterior elements are otherwise incompetent, and the ability to treat three-column injuries with adequate stability. In patients with spinal deformities, segmental pedicle screw fixation has demonstrated greater three-dimensional correction with decreased rates of curve progression and higher fusion rates.[4–11] Recently, Luhmann et al.[12] demonstrated that posterior segmental pedicle screw instrumentation and fusion in patients with thoracic adolescent idiopathic scoliosis (AIS) curves from 70 to 100 degrees had equal coronal correction with anterior and posterior segmental spinal fusion. The apical vertebrae can be derotated to enhance correction and potentially prevent the need for a thoracoplasty.[13] Our preliminary results demonstrated that direct bilateral apical vertebral derotation (BAVD) techniques using pedicle screws increase the percent-predicted pulmonary function test (PFT) results.[13] Also, the flexibility of multiple screw types and stability of the screw anchor allows easier connection to the rods. Various hook and wire fixation techniques can be applied in addition to pedicle screws depending on local anatomy and surgical indications. Despite the potential benefits, many surgeons have avoided placing pedicle screws especially in the thoracic spine because of their concern for neurologic, vascular, and visceral complications.[14–18] The smaller size of the vertebral body and pedicles, variable pedicle insertion angles, and requirements for more precise screw placements, due to nearby neural and vascular structures, add to concerns regarding this technique. Rinella et al.[19] demonstrated nearly 180% pedicle expansion (compared with preoperative internal diameter of the pedicle) after pedicle screw placement in a pediatric cadaveric spine. Complications can be minimized by



Figure 16–1 Various deformity-reduction techniques.

using the free-hand anatomic technique described in this chapter with appropriate somatosensory evoked potential (SSEP), motor evoked potential (MEP), and triggered electromyogram (EMG) neurophysiologic monitoring techniques.[10–13,19–24] At our institution, more than 10,000 thoracic pedicle screws (750 patients, range 2 to 79 years) have been used as a primary fixation without any neurologic, visceral, or vascular complications or revision surgery needed at up to 13 years follow-up.

♦ Indications for Surgical Treatment of Thoracic Scoliosis

The indication for surgery due to AIS is a 45- to 50-degree thoracic curve. In addition to this coronal major Cobb angle, physical appearance such as shoulder balance, rib hump, patient and parents' acceptance of the patient's physical appearance, and skeletal maturity should be considered.

♦ Selection of Fusion Levels

The Lenke et al.[25] classification simplifies and clarifies the decision-making process by including all curve types and sagittal plane measurements. The first principle is to differentiate the Lenke Type 1 (single thoracic) and 2 (double thoracic) curves from other curve types. The sagittal T2-T5 kyphosis (angle between the upper end plate of T5 and the lower end plate of T2) ≥20 degrees implies a "compensatory and structural" proximal thoracic cure regardless of the coronal flexibility measurements and is included in the fusion area.[26] The sagittal T10-L2 kyphotic angle (angle between the upper end plate of T10 and the lower end plate of L2) ≥20 degrees is also very important to differentiate a thoracic curve from a double-major curve irregardless of the coronal flexibility measurements of the thoracolumbar/lumbar curve and is included in the fusion area.[26] Thoracolumbar sagittal kyphotic angle, ligament laxity, and remaining growth potential must be considered to prevent postoperative distal junctional kyphosis (DJK).

The second principle is to fuse selectively (selective fusion). Specific measurement ratios must be considered with minor curve flexibility measurements close to the 25-degree threshold. When analyzing main thoracic (MT) and thoracolumbar/lumbar (TL/L) curves, the relative apical vertebral translation (AVT), apical vertebral rotation (AVR), and Cobb angle measurements ratios should be considered. The thoracic AVT is the distance from the center of the vertebral body at the thoracic apex to the C7 plumbline. Similarly, the TL/L AVT is measured from the center of the lumbar apical vertebral body to the center sacral line (CSL). The CSL is measured as the vertical line from the center of S1 regardless of pelvic position. When the patient is perfectly

balanced, the C7 plumbline and CSL are the same. The AVR is based on the Nash-Moe rotation index including half sizes as appropriate. For thoracic major curves, all three ratios (main thoracic/TL) >1.5 implies a false double-major pattern so selective fusion of only the thoracic curve should be strongly considered. When fusing only the major thoracic curve, the remaining angle of the major curve should be similar to the final angle of the compensatory curve, the supine lumbar curve, or push-prone lumbar curve.

The third principle is how to decide the uppermost instrumented vertebra. To determine the proximal end point of the fusion, the position of the shoulders, the flexibility and size of the proximal thoracic (PT) curve, and the anticipated amount of main thoracic correction must be considered. When the PT curve is relatively inflexible, a supine or push-prone radiograph demonstrates contralateral shoulder elevation, or the preoperative clinical position of the contralateral shoulder is high, we will usually fuse the proximal curve to T2. By "contralateral shoulder," we mean the shoulder opposite the main curve, that is, left shoulder for a right thoracic curve or right shoulder for a left lumbar curve. When the PT curve is somewhat flexible or the shoulders are in neutral position, we will consider fusing to T3; whereas with flexible PT curves or with a low contralateral shoulder we typically fuse to T4.

The fourth principle is deciding the lowest instrumented vertebra (LIV). The stable vertebra[27] is the vertebral body that the CSL bisects. This lower end point is considered "safe" with hook instrumentation systems. The LIV in the hook group (n = 146) was 0.29 above the stable vertebra, and the LIV in the pedicle screw group (n = 48) was 0.67 above the stable vertebra in 194 consecutive AIS Lenke Type 1 and 2 patients in one study.[27] Now we frequently can stop one to two levels short of the stable vertebra depending on rotation, curve magnitude, flexibility, coronal and sagittal balance, and so forth. In most of our recent cases with pedicle screw constructs, the LIV is the most proximal lumbar vertebra in which the center CSL touches any aspect of the vertebral body. Review of supine, push-prone, and lateral benders provide a sense of postoperative balance.

Is there any difference between the DJK in a fusion ending at T12 versus L1 in AIS undergoing segmental posterior spinal instrumentation? Thirty-nine AIS patients who underwent a posterior spinal fusion (PSF) with a T12 LIV (T12 group) were compared with 76 patients who underwent a PSF with an L1 LIV (L1 group). Abnormal DJK was defined by the distal junction disk angle between the lower end plate of the LIV and the upper end plate of the infra-adjacent vertebra, which was at least 5 degrees greater than the preoperative measurement and also at least 5 degrees greater than the normal disk angle. The disk angle beneath the LIV (LIV-D) demonstrated similar changes (6.9 to 3.7 degrees in the T12 group and 7.3 to 2.8 degrees in the L1 group, p = 0.459). The average disk height change beneath the LIV demonstrated similar changes (0.6-mm decrease in the T12 group and 0.7-mm decrease in the L1 group). The incidence of DJK as defined was 10 cases (2/39, 5% in the T12 group and 8/76, 11% in the L1 group) (p = 0.324). No patient complained of symptoms related to the DJK.[28]

The LIV should be correctly tilted to allow smooth transition into the compensatory lumbar curve. For Type A lumbar modifiers in the Lenke et al. system, the distal end plate of the LIV can often be corrected to horizontal. Mild tilt is allowed for the LIV of Type B lumbar modifiers. For Type C lumbar modifiers, an appropriate degree of tilt must be maintained. A rough estimate is the remaining tilt on the supine and bending radiographs, although intraoperative radiographic analysis is equally important. The planned LIV tilt on the preoperative supine radiograph is a good reference point but it is not necessarily the rule.

♦ Selection of Posterior versus Anterior Approach to Spinal Fusion

The decision to approach the curve with an anterior and/or posterior fusion depends on a variety of factors including the size and "personality" of the major curve, the characteristics of the compensatory curves, the patient's sagittal balance, and the patient's performance on pulmonary function tests.[29] Our typical fusion levels for anterior-only approaches to a Lenke Type 1 curve are between the upper and lower end vertebrae.[30] Advantages to anterior-only instrumentation are generally shorter fusion levels, no disruption of the posterior extensor musculature (less junctional problems), and convex compression curve correction.[31] We typically use dual rod systems and approach the spine from the side of the convexity of the curve. Occasionally, a single rod endoscopic (VAT) approach will be used in smaller patients with flexible thoracic curves. As noted previously, our posterior-only fusion levels depend on a variety of factors, but we can usually stop a level or two short from the distal stable level depending on our flexibility assessment. When the fusion levels are equivalent based on anterior and posterior fusion assessments (or the LIVs are equivalent and the UIVs are reasonably close), we tend to prefer posterior approaches because recovery is generally easier, and there is no chest wall violation. The corrective power of all-pedicle screw constructs have dramatically altered our operative approach and have increased the number of posterior-only procedures at our institution. In adolescents, we can typically approach curves ≤120 degrees with a posterior-only, all-pedicle screw construct. Very large curves (major Cobb angle >120 degrees) may require perioperative or intraoperative halo or halo-femoral traction in addition to a formal anterior or posterior vertebral column resection with preservation of segmental vessels and adjacent level diskectomy and fusion through open thoracotomy or thoracolumbar approaches to prevent irreversible spinal cord paraplegia.[32]

♦ Surgical Treatment

"Free-Hand" Technique for Pedicle Screw Placement

The "free-hand" technique is equivalent for lumbar and thoracic pedicle screw placement. No imaging is needed after initial localization films until all of the screws are placed. After initial exposure, each step is repeated sequentially at each

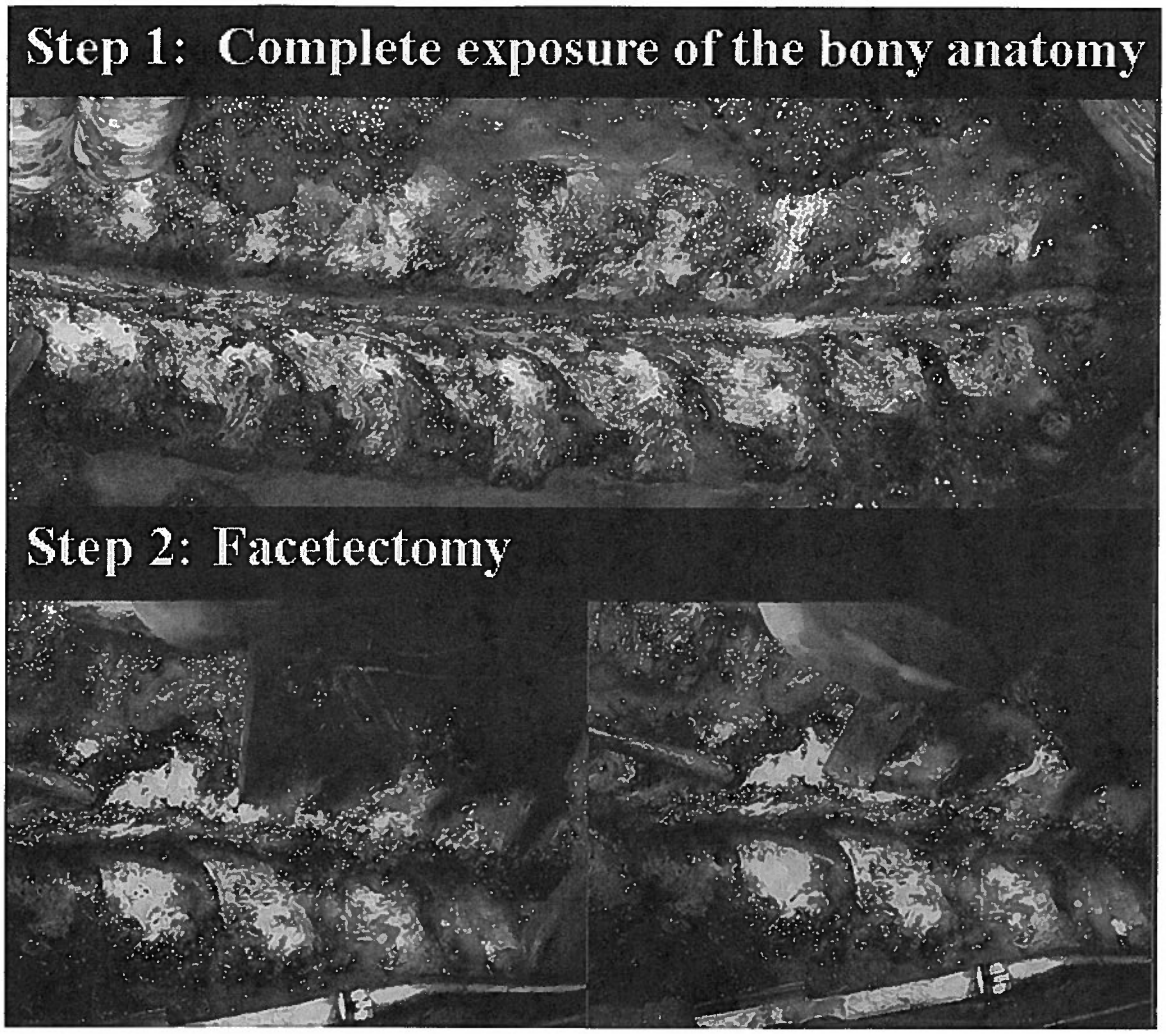

Figure 16–2 Free-hand technique for lumbar and thoracic pedicle screw placement. Steps 1 and 2: Complete exposure of the bony landmark and facetectomy.

level to be instrumented. If necessary, hooks or sublaminar wires can still be used after the screws are placed.

1. *Incision and Exposure*

A meticulous exposure of the posterior elements to be fused is critical to successful screw insertion. The dissection should be limited to only the fusion levels to limit soft-tissue disruption and reduce the potential for junctional kyphosis or transition syndromes. Usually, the proximal junctional dissection is a bit more difficult. We aim to place pedicle screws at the most proximal and distal vertebrae without disrupting the facet capsules, supraspinous and interspinous ligaments, and ligamentum flavum either proximally or distally. The spine is exposed to the tips of the transverse process bilaterally staying strictly subperiosteal to reduce bleeding **(Fig. 16–2)**.

2. *Facetectomy*

The facet joints must be thoroughly cleaned and partially osteotomized to enhance visualization and fusion. The inferior 3 to 5 mm of the inferior facet and articular cartilage on the superior facet are removed except for the lowermost instrumented vertebra. It is essential to completely expose the base of the superior articular process as it is an important landmark to the ventral pedicle **(Fig. 16–3)**.

3. *Starting Point*

The starting point for each thoracic level is slightly variable and is based on the posterior element anatomy of the transverse process, the lateral portion of the pars interarticularis, and the base of the superior articular process. Usually, the supine or push-prone preoperative films are very illustrative to locate the ideal starting point. It is also biomechanically beneficial to place each screw in a position parallel to the superior end plate in the thoracic spine. In general, visualize the starting point based on as much anatomical information as possible and always start from the neutrally rotated and distal vertebra. When starting distal at T12, there is a trend toward a more medial and cephalad pedicle starting point on the posterior elements as one proceeds toward the apical midthoracic region (T7-T8). Proximal to this, the starting

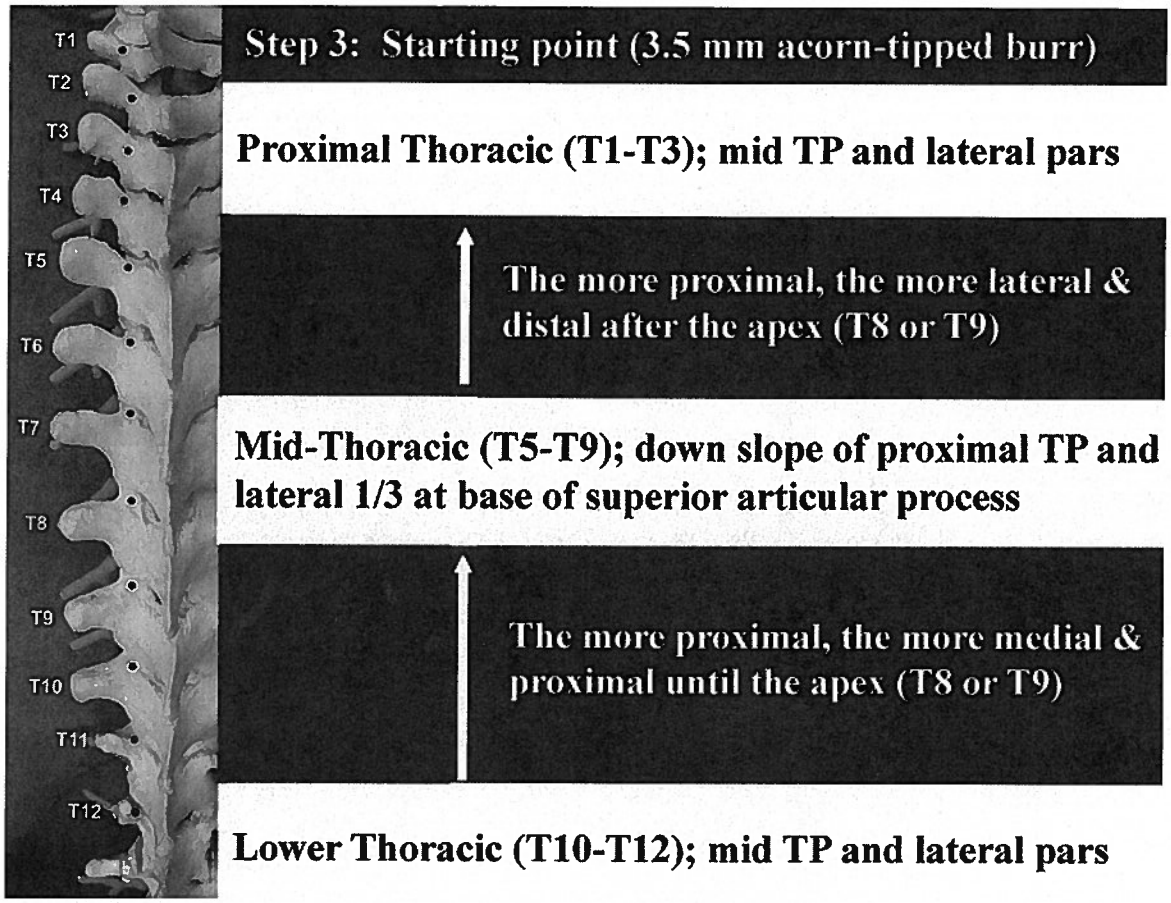

Figure 16–3 Free-hand technique for lumbar and thoracic pedicle screw placement. Step 3: Starting point using 3.5-mm acorn-tipped burr.

point tends to move more lateral and caudad as one proceeds more proximal to the T1 level. It is advantageous to note these trends when placing a screw at each level in succession, working from distal to proximal in the thoracic spine and by making fine adjustments to the trajectory of the previous level's screw or contralateral screw. It is also important to have smooth transitions between each screw for effortless rod placement. When performing selective thoracic or lumbar fusions, remember: The pedicles may be smaller in the concavity of the upper or lower compensatory curves. If hooks are used during the procedure, they are typically placed at the level of the uppermost concave thoracic vertebra due to the small pedicle size on the proximal thoracic concavity **(Fig. 16–3)**.

4. *Cortical Burring*

First, a 3.5-mm acorn-tipped burr is used to create a posterior cortical breach ~5 mm in depth. The pedicle "blush" should be visualized suggesting entrance into the cancellous bone at the base of the pedicle. This may not be seen in smaller apical, concave pedicles because of very limited intrapedicular cancellous bone. In this situation, the tip of a probe may be required to find this using a funnel-like technique **(Fig. 16–4)**.

5. *Gearshift Probing*

With the appropriate amount of ventral pressure, the thoracic gearshift (2-mm blunt-tipped, slightly curved pedicle finder) is placed in the base of the pedicle searching for a cancellous "soft spot" indicating the entrance to the pedicle. The gearshift is initially pointed lateral as a safety measure to avoid ventral lamina and medial pedicle wall perforation. Our CT scan study demonstrated that the average transverse angle of the acceptable screw was 15.3 degrees. That of the laterally violated screw was 10.6 degrees, and that of medially violated screw was 23 degrees. The difference in the transverse angle was more significant in the thoracic spine.[21] Often, the endosteal diameter of the pedicle is quite small, so one must allow the finder to "fall" into the pedicle. Although nearly 200% pedicle expansion is possible (compared with preoperative internal diameter of the pedicle) after pedicle screw placement in a pediatric spine, poor trajectory can break the medial pedicle wall with smaller expansion.[19] After inserting the tip ~20 to 25 mm (the length of the pedicle), the gearshift is removed, and the tip is turned to face medial. Before advancing the pedicle finder, place the tip carefully in the base of the prior hole. This technique is extremely useful as vertebral rotation may be deceiving. The path down the pedicle is then continued medial into the body with an ultimate depth averaging 40 to 45 mm for the lower thoracic region, 35 to 40 mm for

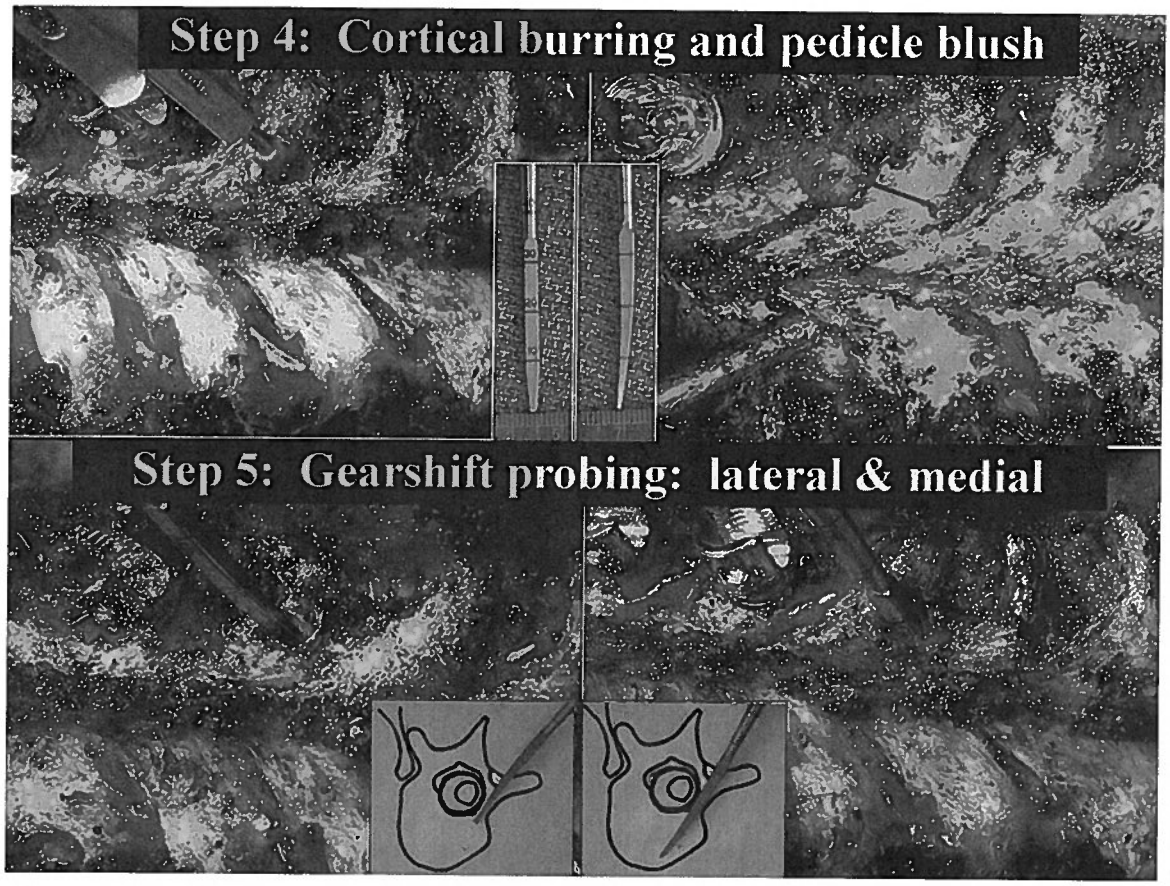

Figure 16–4 Free-hand technique for lumbar and thoracic pedicle screw placement. Steps 4 and 5: Cortical burring and gearshift probing into the pedicle laterally and medially.

the midthoracic region, and 30 to 35 mm for the proximal thoracic region in adolescents and most adults. Rotate the finder 180 degrees to make room for the screw after advancing the finder to the approximate length of the desired screw. Make sure you feel bone the entire length of the pedicle. The surgeon must pay strict attention to the axial and sagittal position of the vertebrae space to position the probe down the pedicle shaft appropriately. In addition, probing of the pedicle with the thoracic gearshift should proceed in a smooth and consistent manner with a snug feel because of the small size of the thoracic pedicles. Any sudden advancement of the gearshift suggests penetration into soft tissue, and thus a pedicle wall violation or vertebral body violation has occurred. These should be investigated immediately to possibly salvage the pedicle and avoid complications. It is important not to extend deep anteriorly or laterally into the body of the thoracic spine; for that purpose, the thoracic gearshift is calibrated. However, the surgeon must use caution as the anterior and lateral vertebral body cortices are not very strong and may be penetrated by the gearshift tip **(Fig. 16–4)**.

It is important to avoid penetration of the anterior cortex. Approximately 60% of the strength of the screw comes from the pedicle itself with an additional 20% added from the posterior half of the vertebral body. There is not a significant increase in strength in the anterior vertebral body unless the anterior cortex is tapped. This is not recommended in any level except the sacrum because of the damage-risk to the vascular and visceral structures. Normal thoracic pedicle screw diameters will vary between 6.5 mm for the lower thoracic region to 4.0 mm in the concave apex of a scoliosis deformity in the midthoracic region or the proximal thoracic region. Decision of screw diameter is based on preoperative assessment as well as how the pedicle "feels" with the pedicle finder and sequential tapping. Pedicle diameter transitions occur gradually, so segmental fixation allows one to note the fine variations between levels with the goal of maximum fit and fill of the screw within the pedicle.

6. *Palpation*

Once the pedicle-seeker is removed, the tract is visualized to make sure that only blood is coming out and not cerebrospinal fluid (CSF) (very rare). One must note the amount of blood extruding from the pedicle hole as excessive bleeding may indicate epidural bleeding secondary to medial wall perforation. Next, a flexible ball-tipped pedicle sounding or palpating device is used to palpate five distinct bony borders: a floor and four walls (medial, lateral, superior, and inferior). Special attention must be paid to the junction of the middle and upper portions of the tract (the first 10 to 15 mm of the tract) as this is the region of the pedicle where the spinal canal and pedicle isthmus are located. This is an absolutely critical step, whereby inadvertent deep (anterior), medial, lateral, or more rare superior and inferior pedicle breaches

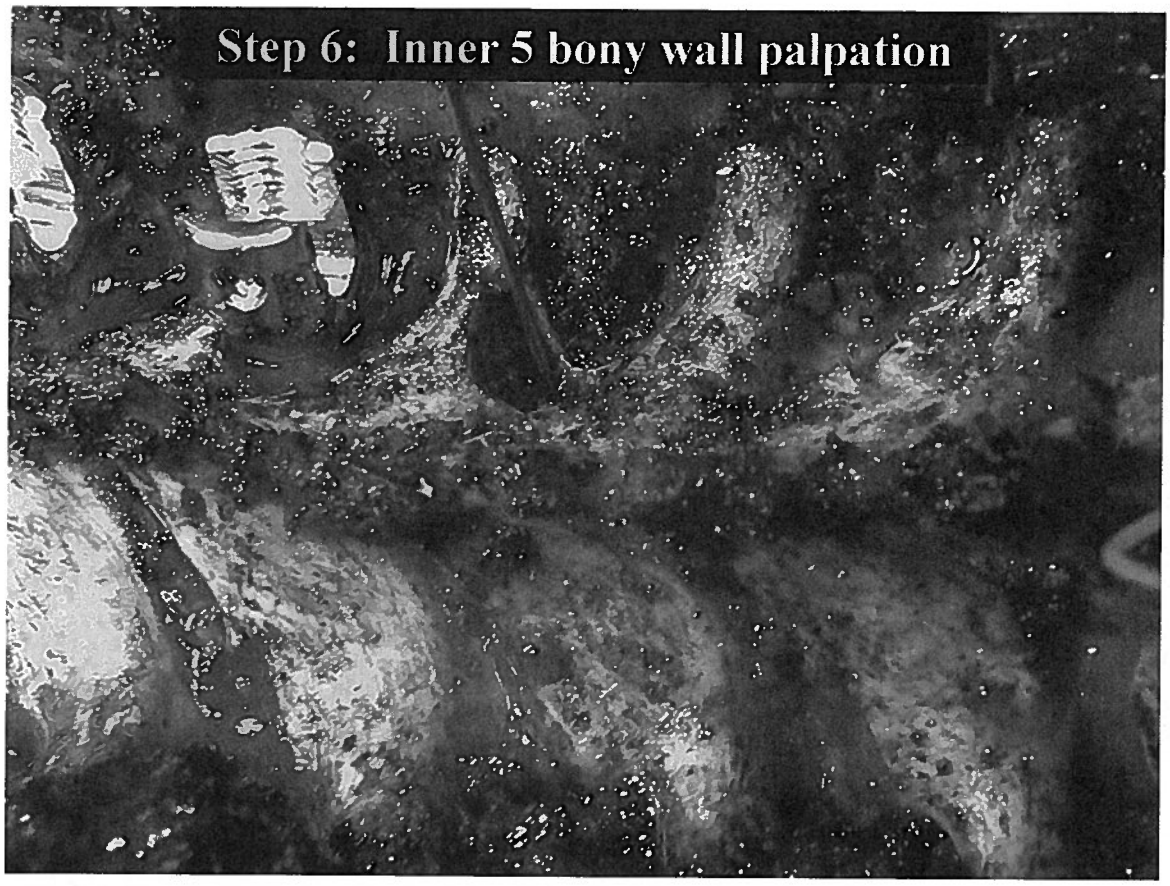

Figure 16–5 Free-hand technique for lumbar and thoracic pedicle screw placement. Step 6: Palpate the inner five bony walls.

can be identified. At this point, if a soft tissue breach is palpated, there may be an opportunity to redirect the screw into an appropriate position in the pedicle so that complete intraosseous borders can be obtained. If any wall including the medial has been breached, the pedicle may be salvaged. One can place bone wax in the pedicle hole to limit bleeding and re-angle the pedicle finder with a more appropriate trajectory **(Fig. 16–5)**.

7. Pedicle Length Measurement, Tapping, and Repalpation

With the sounder in the base of the anticipated pedicle tract after confirming all five intraosseous borders, the length of the tract must be marked with a hemostat and measured. If the tract appears too shallow, consider replacing the gearshift and advancing to the appropriate length. The pedicle tract is undertapped with a 1.0-mm smaller diameter tap than the intended screw (e.g., 4.5-mm tap for a 5.5-mm-diameter screw). If there is difficulty passing the tap, use the next smaller tap and retap the pedicle. If the pedicle is quite small or when more than one pass has to be made into a pedicle with the thoracic gearshift, place a K-wire down the pedicle tunnel into the body, and cannulated tapping can occur over that. It is mandatory that a bony floor exist when using a K-wire so as not to advance the K-wire beyond the anterior or lateral cortex. If there is any question whether the anterior wall is intact, never use a K-wire as a cardiac tamponade as K-wire–induced trauma to a coronary artery has been reported[11] **(Fig. 16–6)**.

Although the ideal screw diameter is known as 80% of the pedicle diameter, screws up to 200% of the pedicle diameter can be inserted without causing significant decrease in the screw holding-power because of the plasticity of the pedicular cortex in pediatric patients.[18] We have used the internal diameter of the neutrally rotated spine as a reference diameter to determine screw diameter and the tightness of the tap. Currently, we often insert 5.0-mm screws if the internal diameter of the pedicle is around 2.5 mm. After tapping, the pedicle tract is repalpated to make sure that the five osseous borders are intact. This second palpation will often allow palpation of distinct bony ridges confirming intraosseous positioning, and then the tract length is remeasured with a hemostat. Compare this measurement directly to the adjacent screw to ensure appropriate screw length.

8. Screw Placement

Place the screw slowly into the body pedicle in the same alignment to confirm that it is threaded properly and to allow for viscoelastic expansion. It is advantageous to have a variety of pedicle diameters and lengths available. We have used screws with diameters between 4.5 mm and 7.5 mm in 0.5-mm increments and lengths ranging from 25 mm for the smaller diameter screws up to 55 mm for the larger diameter screws.



Figure 16–6 Free-hand technique for lumbar and thoracic pedicle screw placement. Step 7: Pedicle screw length measurement, tapping, and repalpation of the inner walls.

Typical screws range from 45 mm in length in the distal thoracic spine to 30 to 35 mm in the proximal thoracic spine. For the most part, we use fixed-angle screws; however, multiaxial screws may be helpful in the hyperkyphotic thoracic spine and in the entire lumbar spine. Monoaxial screws are preferred for direct derotation of the vertebral body[33] **(Fig. 16–7)**.

Screws are inserted on every segment on the correction sides such as the concave side of the idiopathic normo- and hypokyphotic scoliosis and the convex side of the hyperkyphotic idiopathic scoliosis. For the supportive side, we have inserted screws at every third or fourth level after inserting the two lowermost screws for the pedicle screw translational technique. In kyphosis, congenital scoliosis, and bilateral apical vertebral rotational techniques, more screws have been inserted to increase correction power and rigidity of the instrumentation.

9. *Confirmation of Intraosseous Screw by Imaging Modality*

It is imperative that the surgeon document intraosseous placement via fluoroscopy and/or radiography. Some surgeons prefer to use fluoroscopy to obtain a true anterior/posterior (AP) of each level. Other surgeons prefer intraoperative AP and lateral x-ray films be obtained of all screws placed prior to rod placement. The coronal plane radiograph is evaluated for the harmonious position of all screws especially when any rotational deformity exists such as in scoliosis. Being able to view the screw length on the lateral x-ray film is useful to adjust the screw tip position on the posterior/anterior (PA) radiograph. Three plain radiographic criteria using the intraoperative PA plain radiograph are used to judge the accuracy of the screw position: (1) violation of the harmonious segmental change in the tips of the inserted screws with reference to the vertebral body rotation (medial or lateral out); (2) no crossing of the medial pedicle wall by the inserted pedicle screw (lateral out); and (3) violation of the imaginary midline of the vertebral body using the posterior upper spinolaminar junction in the plain PA x-ray film by the absolute position of the inserted pedicular screw tip after minor adjustment according to the lateral x-ray film (medial out). If the internal diameter of the pedicle is <7 mm, the position of the screw tip in a coronal plane radiograph should be somewhere between the medial wall of the pedicle and the imaginary midline of the vertebral body. On the lateral x-ray film, the screws should be parallel to the superior end plates and should not extend past the anterior border of the vertebral body. These radiographs should confirm the harmonious position of the screws as noted by the surgeon in vivo[24] **(Fig. 16–8)**.

10. *Confirmation of Intraosseous Screw by Triggered EMG*

EMG stimulations are performed with real-time monitoring of the thoracic nerve root, which is recorded from the rectus abdominus muscles for screws placed from T6 to T12. In

Figure 16–7 Free-hand technique for lumbar and thoracic pedicle screw placement. Step 8: Slow screw placement.

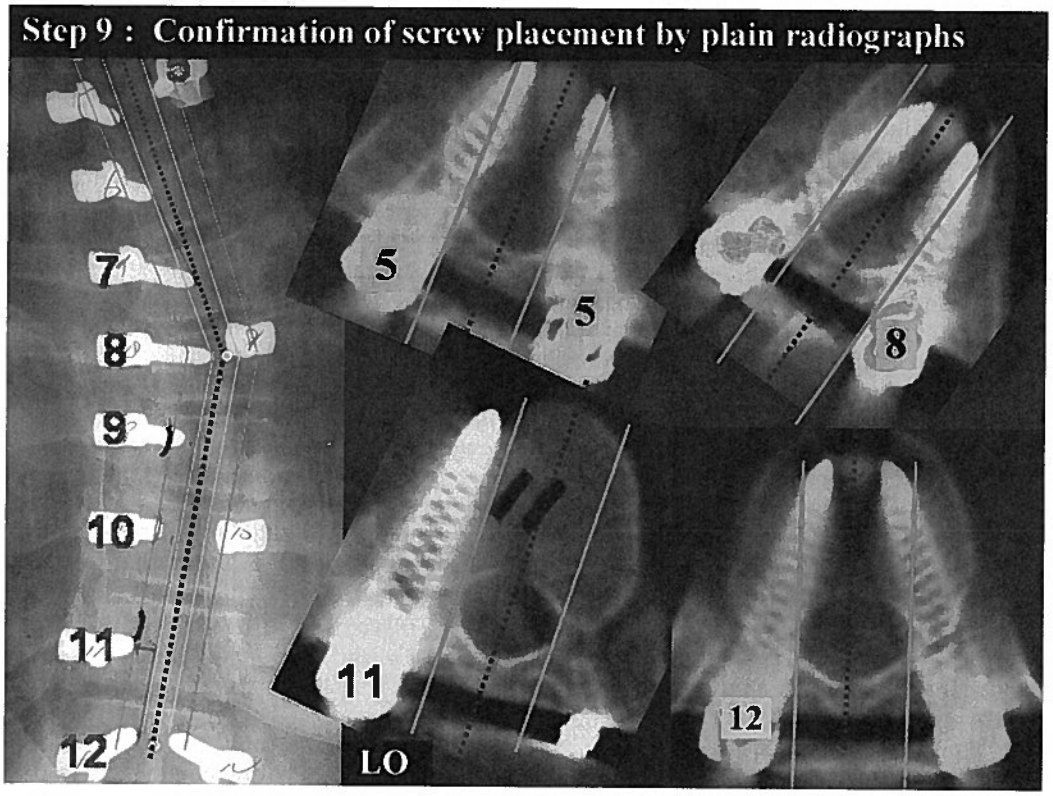

Figure 16–8 Free-hand technique for lumbar and thoracic pedicle screw placement. Step 9: Confirmation of screw position using intraoperative plain radiographs.

lumbar spine, EMG recordings from the adductor (L1) and vastus medialis (L2, 3, and 4) are performed. We recheck and repalpate the thoracic pedicle tract with a ball-tipped sounder for EMG threshold levels less than 6 mA or less than 65% of the mean of all other T6-T12 screws in the patient to confirm intraosseous placement.[20] We recheck and repalpate the lumbar pedicle tract with a ball-tipped sounder for EMG threshold levels less than 6 mA (absolute). These EMG results should be taken along in context with results from pedicle palpation, screw positioning on radiographs, and overall assessment of how each screw feels during placement throughout the thoracic and lumbar spine **(Fig. 16–9)**.[20,23,24]

11. Rod Contouring

After the insertion of the pedicle screws, the rods are measured and contoured in the sagittal and coronal planes. It is often helpful to orient the cut end of the rod in a vertical direction while contouring to serve as a reference point. We typically secure the rod with two clamps and hold the rod over the wound to allow visualization during contouring. The rod will tend to rotate with three-dimensional contouring; therefore, the use of two clamps and rod-reference orientation is helpful.

♦ Correction Maneuver of Thoracic Scoliosis

Conventional Maneuver

Typically, the rod on the side of the concavity is placed first (for hypokyphotic or normokyphotic sagittal alignment) and correction is performed. When hyperkyphosis is present, the convex rod is placed first as corrective maneuvers tend to lordose the spine. When no apical derotation is performed, the curve is corrected with the concave rod in place by a cantilever maneuver. With the set screws loose (or locked at one end), the rod is straightened slowly using coronal benders. Each straightening of the rod is performed over a pedicle screw, typically placed at every level on the concavity of the major curve. Several passes may be necessary to allow for viscoelastic relaxation to occur. Occasionally, a derotational maneuver is performed for single thoracic curves before rod translation. Segmental compression and distraction of the screws also aid in straightening the curve. The apical screw(s) are usually tightened, and appropriate compression (on the convexity) or distraction (on the concavity) is performed. It is important to watch the screw-bone interface with all correction maneuvers because any signs of loosening may imply impending bony failure or loss of fixation. The second rod is placed, and a long-cassette AP radiograph is performed.

Figure 16–9 Free-hand technique for lumbar and thoracic pedicle screw placement. Step 10: Confirmation of screw placement by triggered EMG.

While the film is developing, iliac crest bone graft can be harvested. This also allows time for NMEP and/or SSEP monitoring to detect slow progression of neurologic deficits until 1 hour after rod fixation. A report of the Scoliosis Research Society Morbidity and Mortality Committee demonstrated 28 neurologic deficits after 4369 posterior spinal fusions and 801 AP spinal fusions for idiopathic scoliosis (0.5%).[32] It is important to assess all of the screws and the tilt of the end vertebrae as well as overall balance on the intraoperative radiographs. Also, check to make sure that screw position has not changed during the corrective maneuvers.

After the x-ray films are reviewed and the iliac crest bone graft is obtained, the posterior elements are decorticated with a burr and the bone graft is placed. We typically use only autogenous bone in adolescent idiopathic scoliosis cases and fresh frozen allograft for neuromuscular scoliosis patients. The graft is placed in a morselized fashion and two cross-links are placed. We typically measure and test-fit the cross-links prior to placing the graft. After the bone graft and cross-links are in place, the wound is debrided and closed over drains deep and superficial to the lumbodorsal fascia. We use absorbable sutures at all levels of the wound closure.

Bilateral Apical Vertebral Derotation Maneuver

Bilateral apical vertebral derotation (BAVD) maneuvers are commonly performed as long as screw purchase is adequate and the thoracic spine is not overly kyphotic. Poor bone quality around the apex and a thin lateral cortical wall compared with the medial cortex was the reason for bilateral apical derotation.[13] King et al.[34] demonstrated that a significantly greater torque before failure can be achieved by rotating a convex screw laterally versus medially. They also demonstrated lateral cut-out and medial canal encroachment during and after pedicle screw derotation. Assisted manual rib hump derotation and spinal cord monitoring is mandatory during this procedure. High levels of thoracic kyphosis (a "+" sagittal modifier by the Lenke et al. classification system) will place considerable strain on the proximal screws if a BAVD maneuver is attempted and thus should be carefully considered. The goal is to enhance correction and potentially obviate the need for a thoracoplasty, which causes pulmonary function to decline even 5 years postoperatively.[30] Original "derotation" maneuvers that merely "derotate" the correcting rod 90 degrees only translate the spine and do not provide true rotation.[4]

Correction Postplacement After Bilateral Pedicle Screw Fixation

Four correcting posts are placed on each screw on the concave and convex sides on the apex of the curve **(Fig. 16–10)**.

First BAVD Maneuver

With the four apical vertebrae secured on both sides, an assistant performs the BAVD maneuver with ventromedial

Figure 16–10 Bilateral apical vertebral derotation maneuver. Step 1: Initial bilateral pedicle screw insertion and periapical postplacement.

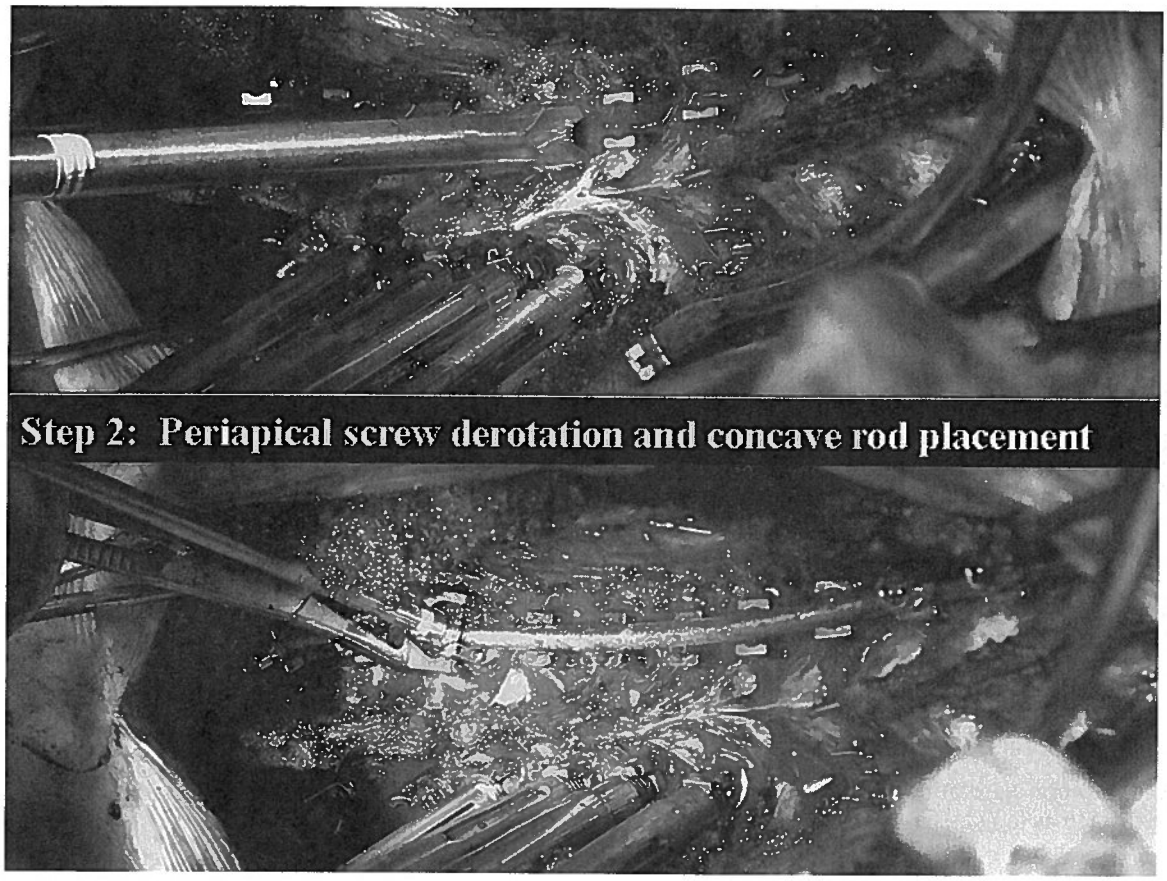

Figure 16–11 Bilateral apical vertebral derotation maneuver. Step 2: Concave rod placement after periapical screw derotation.

manual pressure on the convex rib prominence simultaneously. The convex-sided screws with positioning against the thicker cortical medial wall perform most of the derotation and downward pressure. The degree of correction depends on the flexibility of the curve and strength of the bone-screw interface. The posts on the concavity are removed (if the concave rod is the correcting rod) while maintaining correction with the posts on the convexity **(Fig. 16–11)**.

Place Correcting Rod

The previously contoured concave rod is placed and the set screws inserted at each level. All screws are tightened except for the six apical vertebrae (the four derotation vertebrae and one additional level proximally and distally). Coronal straightening of the correcting rod can be performed with in situ rod benders **(Fig. 16–12).**

Second BAVD Maneuver

With the rod in place and all set screws except the six apical levels tightened, the concave-sided posts are replaced and the BAVD maneuver is reperformed. The apical set screws are tightened through the posts on the concavity. The rod can be further contoured in a standard fashion using coronal benders and segmental compression/distraction forces as necessary. The second or third derotation around the concave rod has been necessary to allow viscoelastic relaxation to occur providing better derotation **(Fig. 16–13)**.

Place Second Rod

No additional correction is performed after the second rod is placed. However, appropriate compression and distraction forces should be placed on this rod to optimize deformity correction. Convex periapical screws appear very important to hold the apical spine and adjacent rib cage during follow-up **(Fig. 16–14).**

Results

We studied the results of these techniques in 96 consecutive AIS patients with Lenke Type 1 and 2 curves treated by the senior author at our institution. The correction rates in Lenke Type 1 curve were 75% (59 to 15 degrees) in 65 patients. The correction rates according to the deformity correction methods were 71% using the pedicle screw translational technique (n = 45) and 84% (n = 20) using the bilateral apical vertebral derotational technique. The correction rates in Lenke Type 2 curves were 67% (68 to 22 degrees) in 31 patients. The correction rates according to the deformity correction methods were 66% using the pedicle screw translational technique (n = 26) and 71% (n = 5) using the bilateral apical vertebral derotational technique. BAVD instrumentation using pedicle screws also offers a significant improvement of PFTs at 1 year postoperatively (absolute value; preoperative 2.77→2.92 L in FVC and 2.26→2.41 L in FEV-1 at 1 year postoperatively) (percent predictive value: preoperatively 82%→86% in FVC and 75%→80% in FEV-1 at 1 year postoperatively).



Figure 16–12 Bilateral apical vertebral derotation maneuver. Step 3: Concave rod translation by in situ bending technique and loosening of periapical eight screws.



Figure 16–13 Bilateral apical vertebral derotation maneuver. Step 4: Second derotation around the straightened concave rod.

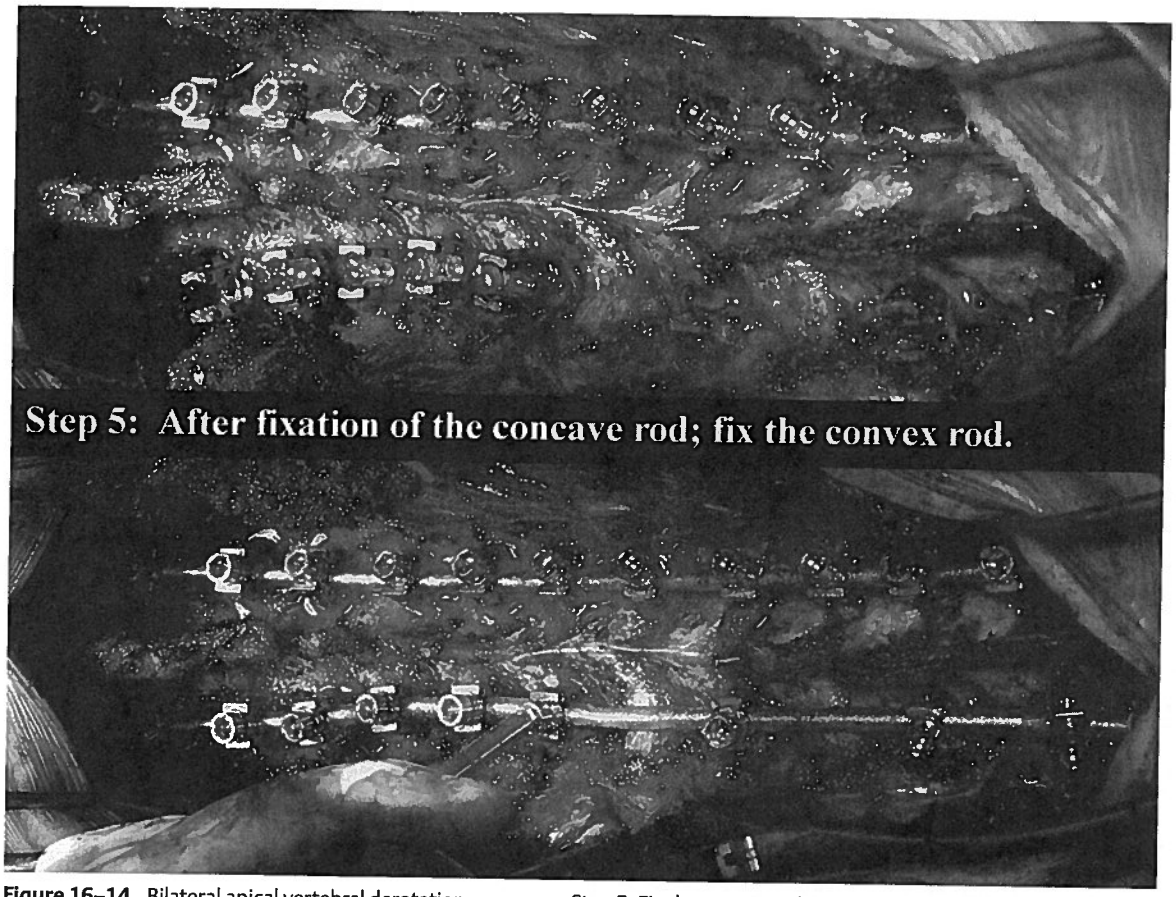

Figure 16–14 Bilateral apical vertebral derotation maneuver. Step 5: Fix the convex rod after fixation of the concave rod.

Case Example

Patient is a 10+11-year-old female with adolescent idiopathic scoliosis that progressed despite bracing. Her long-cassette AP view demonstrates a 68-degree right thoracic and compensatory 62-degree left lumbar curvature. Her lateral view shows thoracic normokyphosis of +24 degrees measured from T5 to T12 **(Figs. 16–15A and 16–5B)**. Her flexibility films show correction of her main thoracic curve to 38 degrees and her lumbar curve to 34 degrees. Her Lenke classification is 3CN (double major) **(Figs. 16–15C and 16–15D)**.

The patient underwent a posterior bilateral apical vertebral derotational instrumentation and fusion from T4 to L3 with the 5.5-mm CD Horizon instrumentation system **(Fig. 16–15E)**. Her 1-year postoperative radiographs demonstrate correction of her main thoracic curvature to 6 degrees (91%) and lumbar curvature to 8 degrees (87%). Her coronal balance is excellent. Her 1-year postoperative lateral view shows thoracic kyphosis to +14 degrees from T5 to T12 and a normalized, harmonious sagittal profile **(Figs. 16–15F and 16–5G)**.

♦ Postoperative Management

Pediatric patients are typically observed in a pediatric ICU setting overnight then transferred to the pediatric orthopaedic floor. They are routinely placed on patient-controlled analgesia (PCA) and converted to oral narcotic medication once they are able to tolerate fluids. Physical therapy begins on the first postoperative day. The patients usually sit and briefly stand with assistance on the first day, progressing to ambulation on subsequent days. The Foley catheter is discontinued when the patient is ambulating well. Prophylactic antibiotics (first- or second-generation cephalosporins) are discontinued after the drains and Foley catheter are removed, typically postoperative day 3. Standing long-cassette AP and lateral radiographs are obtained when the patient is able to ambulate in the halls without difficulty. We do not provide postoperative bracing. Patients may shower once they are discharged from the hospital, assuming their wound is healing well. They also begin trunk range-of-motion exercises based on their comfort level.

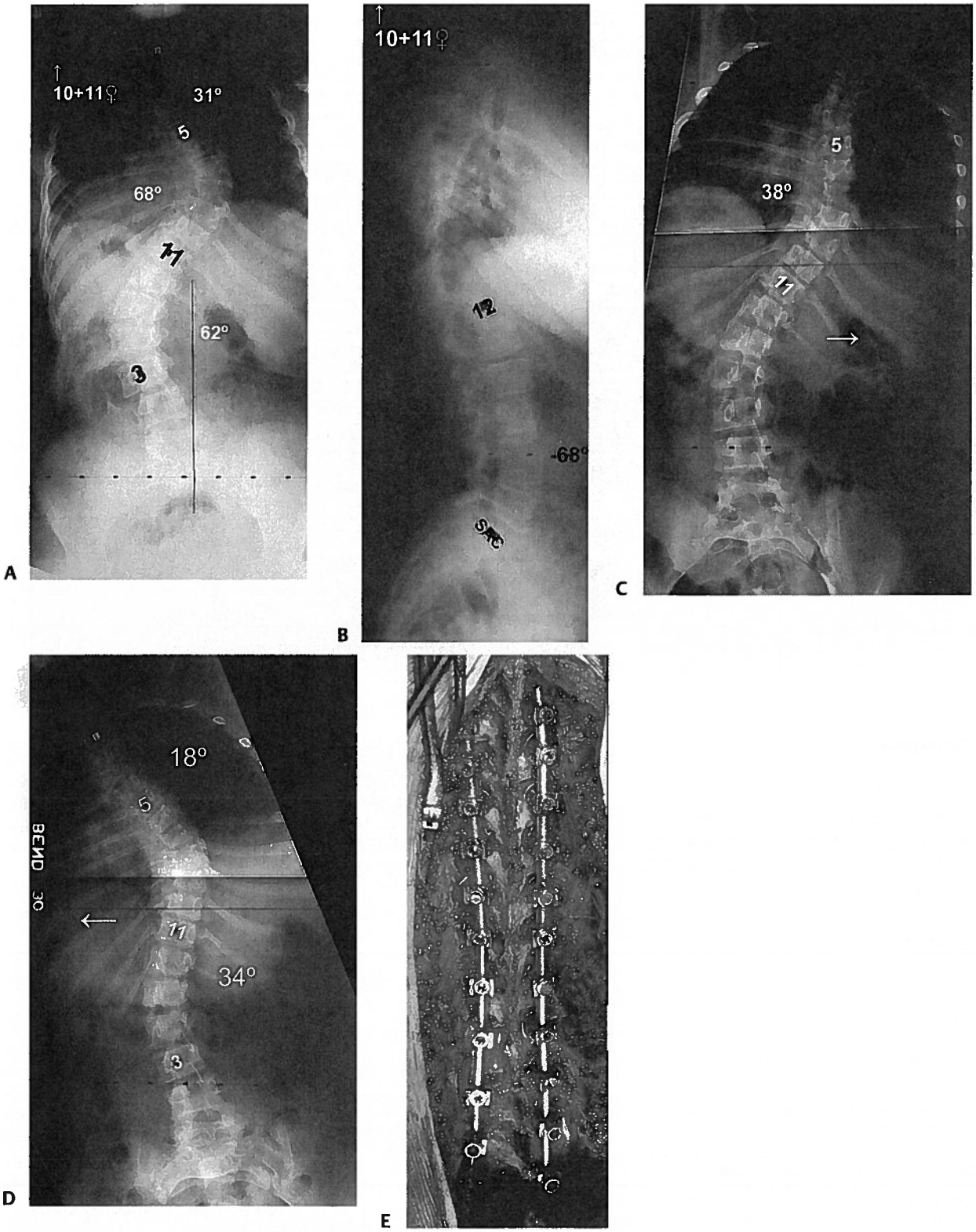

Figure 16–15 10+11-year-old female with adolescent idiopathic scoliosis that progressed despite bracing. Preoperative whole spine **(A)**, standing AP and **(B)** lateral x-ray. **(C** and **D)** Preoperative supine side-benders. **(E)** Intraoperative final instrumentation picture.

(Continued)

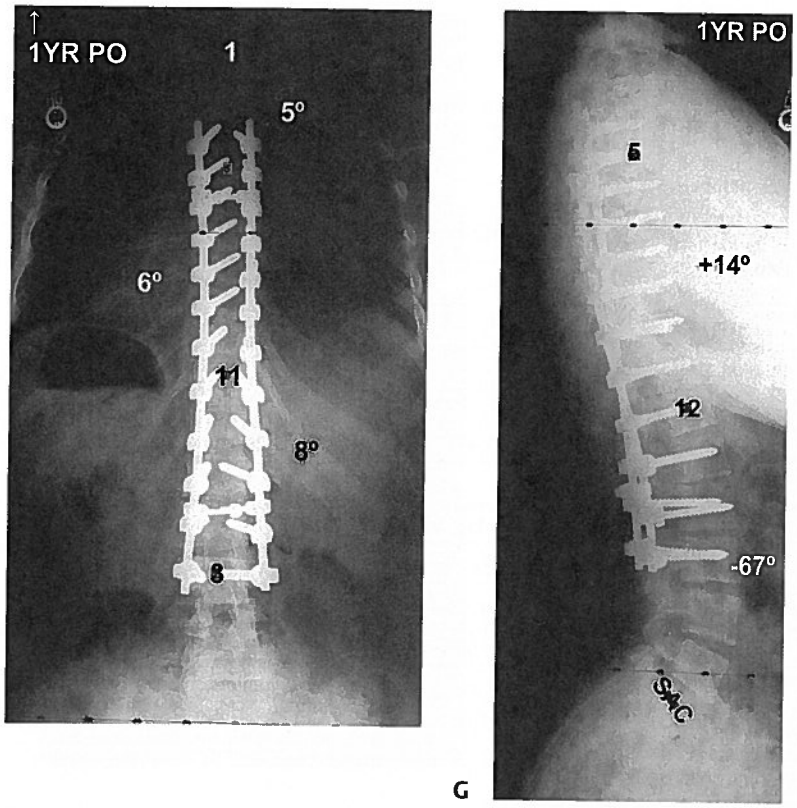

Figure 16–15 *(Continued)* Whole spine **(F)** standing AP and **(G)** lateral x-ray 1 year postoperatively.

◆ Conclusion

Thoracic and lumbar pedicle screw instrumentation allows maximum correction while minimizing complications resulting from implant failure or dislodgement. To date, we have had no neurologic complications related to pedicle screw placement. The tremendous power of such instrumentation is redefining how scoliosis is operatively managed at our institution. The number of anterior releases and instrumented fusions has decreased considerably as we have refined our posterior techniques.

References

1. Harrington PR. Treatment of scoliosis. J Bone Joint Surg Am 1962;44A: 591–610
2. Luque ER. The anatomic basis and development of segmental spinal instrumentation. Spine 1982;7:256–259
3. Drummond DS, Keene JS. Spinous process segmental spinal instrumentation. Orthopedics 1988;11:1403–1410
4. Cotrel Y, Dubousset J, Guillaumat M. New universal instrumentation in spinal surgery. Clin Orthop Relat Res 1988;227:10–23
5. Suk SI, Lee CK, Kim WJ, et al. Segmental pedicle screw fixation in the treatment of thoracic idiopathic scoliosis. Spine 1995;20:1399–1405
6. Hamill CL, Lenke LG, Bridwell KH, et al. The use of pedicle screw fixation to improve correction in the lumbar spine of patients with idiopathic scoliosis. Is it warranted? Spine 1996;21:1241–1249
7. Liljenqvist UR, Halm HF, Link TM. Pedicle screw instrumentation of the thoracic spine in idiopathic scoliosis. Spine 1997;22:2239–2245
8. Halm HF, Niemeyer T, Link TM, et al. Segmental pedicle screw instrumentation in idiopathic thoracolumbar and lumbar scoliosis. Eur Spine J 2000;9:192–197
9. Suk SI, Kim WJ, Lee SM, et al. Thoracic pedicle screw fixation in spinal deformities: are they really safe? Spine 2001;26:2049–2057
10. Kim YJ, Lenke LG, Bridwell KH, et al. Free hand pedicle screw placement in the thoracic spine: is it safe? Spine 2004;29:333–342
11. Kim YJ, Lenke LG, Bridwell KH, et al. Comparative analysis of pedicle screw versus hook instrumentation in posterior spinal fusion of adolescent idiopathic scoliosis: a matched cohort analysis. Spine 2004;29: 2040–2058
12. Luhmann SJ, Lenke LG, Kim YJ, et al. Thoracic adolescent idiopathic scoliosis curves between 70 and 100 degrees: is anterior release necessary? Spine 2005;30:2061–2067
13. Kim YJ, Lenke LG, Bridwell KH, Cheh G. Bilateral apical vertebral derotational pedicle screw instrumentation in the posterior spinal fusion of adolescent idiopathic scoliosis: comparison with pedicle screw translational techniques. Paper presented at: International Meeting on Advanced Spine Technology (IMAST) 11th Annual Meeting; July 1–3, 2004; South Hampton, Bermuda; and at North American Spine Society 20th Annual Meeting; September 27–October 1, 2005; Philadelphia, PA

14. Heini P, Scholl E, Wyler D, et al. Fatal cardiac tamponade associated with posterior spinal instrumentation: a case report. Spine 1998;23: 2226–2230

15. Lonstein JE, Denis F, Perra JH, et al. Complications associated with pedicle screws. J Bone Joint Surg Am 1999;81:1519–1528

16. Esses SI, Sachs BL, Dreyzin V. Complications associated with the technique of pedicle screw fixation: a selected survey of ABS members. Spine 1993;18:2231–2239

17. Papin P, Arlet V, Marchesi D, et al. Unusual presentation of spinal cord compression related to misplaced pedicle screws in thoracic scoliosis. Eur Spine J 1999;8:156–159

18. Kasten M, Kambach B. Proximal pedicle screw complications: fractures with spinal cord injury. Paper presented at: Scoliosis Research Society 39th Annual Meeting; September 7–10, 2004; Buenos Aires, Argentina

19. Rinella AS, Cahill P, Ghanayem A, et al. Thoracic pedicle expansion after pedicle screw placement in a pediatric cadaveric spine: a biomechanical analysis. Paper presented at: Scoliosis Research Society 39th Annual Meeting; September 7–10, 2004; Buenos Aires, Argentina

20. Raynor BL, Lenke LG, Kim YJ, et al. Can triggered electromyograph thresholds predict safe thoracic pedicle screw placement? Spine 2002;27:2030–2035

21. Kim YJ, Lenke LG, Cheh G, et al. CT scan accuracy of "free hand" pedicle screw placement technique in spinal deformity: an analysis of 789 pedicle screws. Paper presented at: International Meeting on Advanced Spine Technology (IMAST) 11th Annual Meeting; July 1–3, 2004; South Hampton, Bermuda

22. Kim YJ, Lenke LG, Cheh G, et al. Defining the learning curve of free hand pedicle screw placement for adolescent idiopathic scoliosis surgery: sixty-seven consecutive cases. Poster presented at: International Meeting on Advanced Spine Technology (IMAST) 11th Annual Meeting; July 1–3, 2004; South Hampton, Bermuda

23. Kim YJ, Lenke LG, Cheh G, et al. Reliability of *in-vivo* triggered EMG thresholds in detecting medial malposition of pedicle screws: comparison between the thoracic and lumbar spine. Poster presented at: International Meeting on Advanced Spine Technology (IMAST) 11th Annual Meeting; July 1–3, 2004; South Hampton, Bermuda

24. Kim YJ, Lenke LG, Cheh G, Riew KD. Evaluation of pedicle screw placement in the deformed spine using intraoperative plain radiographs: a comparison with computerized tomography. Spine 2005;30:2084–2088

25. Lenke LG, Betz RR, Harms J, et al. Adolescent idiopathic scoliosis: a new classification to determine extent of spinal arthrodesis. J Bone Joint Surg Am 2001;83:1169–1181

26. Lenke LG, Betz RR, Clements D, et al. Curve prevalence of a new classification of operative adolescent idiopathic scoliosis: does classification correlate with treatment? Spine 2002;27:604–611

27. King HA, Moe JH, Bradford DS, Winter RB. The selection of fusion levels in thoracic idiopathic scoliosis. J Bone Joint Surg Am 1983;65:1302–1313

28. Kim YJ, Lenke LG, Bridwell KH, et al. Thoracolumbar junctional analysis in patients fixed to T12 vs L1 in adolescent idiopathic scoliosis: is there any difference? Poster presented at: North American Spine Society 19th Annual Meeting; October 26–30, 2004; Chicago

29. Kim YJ, Lenke LG, Bridwell KH, et al. Pulmonary function in adolescent idiopathic scoliosis relative to the surgical procedure. J Bone Joint Surg Am 2005;87:1534–1541

30. Satake K, Lenke LG, Kim YJ, et al. Analysis of the lowest instrumented vertebra following anterior spinal fusion of thoracolumbar/ lumbar adolescent idiopathic scoliosis: can we predict postoperative disk wedging? Spine 2005;30:418–426

31. Betz RR, Harms J, Clements DH III, et al. Comparison of anterior and posterior instrumentation for correction of adolescent thoracic idiopathic scoliosis. Spine 1999;24:225–239

32. Coe JD, Arlet V, Donaldson W, et al. Complications in spinal fusion for idiopathic scoliosis in the new millennium. A report of the Scoliosis Research Society Morbidity and Mortality Committee. Spine 2006;31:345–349

33. Kuklo TR, Potter BK, Polly DW Jr, et al. Monoaxial *versus* multiaxial thoracic pedicle screws in the correction of scoliosis. Spine 2005;30:2113–2120

34. King A, Baratta R, Burger E, et al. Derotation of the thoracic spine using pedicle screws: a comparison of concave and convex screws. Paper presented at: Scoliosis Research Society 39th Annual Meeting; September 7–10, 2004; Buenos Aires, Argentina

Chapter 17

Anterior/Posterior (AP) Surgery for Spinal Deformity

Keith Synnott and Bernard A. Rawlins

A significant number of spinal deformities are successfully treated with a single anterior or posterior approach. However, in certain instances, both an anterior and posterior (AP) approach is indicated. Despite the increased morbidity[1] of such AP procedures, improved deformity correction and enhanced arthrodesis has been reported.[2–8]

AP spine fusions may be performed on the same day in a sequential manner under a single anesthesia or under separate anesthesia several days apart, which we shall refer to as a staged procedure. Simultaneous approaches are performed under a single anesthesia at the same time. The simultaneous approach refers to both anterior and posterior procedures occurring at the same time under the same anesthesia. The simultaneous AP approach is not routinely recommended for deformity surgery because multiple vertebral segments may need to be treated, which is difficult given the patient position and resulting restricted access.[9] With the developments in thoracoscopic techniques, the simultaneous approach may become more useful in the future.

♦ Indications for AP Surgery

The primary indication for AP procedures is large rigid curves. Rigid curves are generally referred to as those with flexibilities less than 50% based on supine side-bending films or traction films. The approach to treatment in the pediatric patient differs from that of the adult patient. Pediatric patients inherently have improved fusion rates and more flexible curves in comparison with adults.

In the pediatric patient with idiopathic scoliosis, successful curve correction may be achieved in patients with curves up to 85 degrees with a single approach.[10–13] Although there are several techniques for providing this type of correction, the authors prefer the use of proximal and distal anchors and intervening sublaminar wires that translate the spine to a sagittal rod contoured to the expected sagittal contour of the patient. Proponents of multiple screw constructs suggest that use of screws over the apex of the curve can provide increased correction and improved rotation.[10,13] This technique still requires additional validation in multiple centers. Pediatric patients with idiopathic curves greater that 85 degrees and rigid curves require AP procedures[14] **(Fig. 17–1)**.

In the adult patient, the indication for surgery may include pain in thoracic curves greater than 50 to 60 degrees unrelieved by conservative management; significant deformity unacceptable to the patient; significant curve progression with or without sagittal or coronal imbalance; back pain, radicular or stenosis symptoms associated with lumbar deformity; significant loss in pulmonary function unrelated to parenchymal disease.

In the adult patient, cures less than 70 degrees may be treated by surgery performed posteriorly only. Thoracoplasty and or concave rib osteotomies will assist in correction in these cases. Curves greater than 70 degrees with poor flexibility will generally require an AP procedure.[15]

Adults with thoracolumbar and lumbar curves should consider an anterior fusion for increased fusion rates in addition to poor flexibility. If the spine under consideration has poorly developed transverse processes or a laminectomy for stenosis will be required, the absence of sufficient posterior fusion surface may compromise the spine fusion, and an anterior fusion should be considered.

The AP approach may be required in patients with instability, congenital scoliosis, pseudarthrosis, and postlaminectomy defects or to avoid crankshaft deformity in children. The indications for surgery are based on age, curve magnitude, extent of the curve, and etiology. The details in and variation in approaches for each individual etiology would be outside the scope of this chapter.

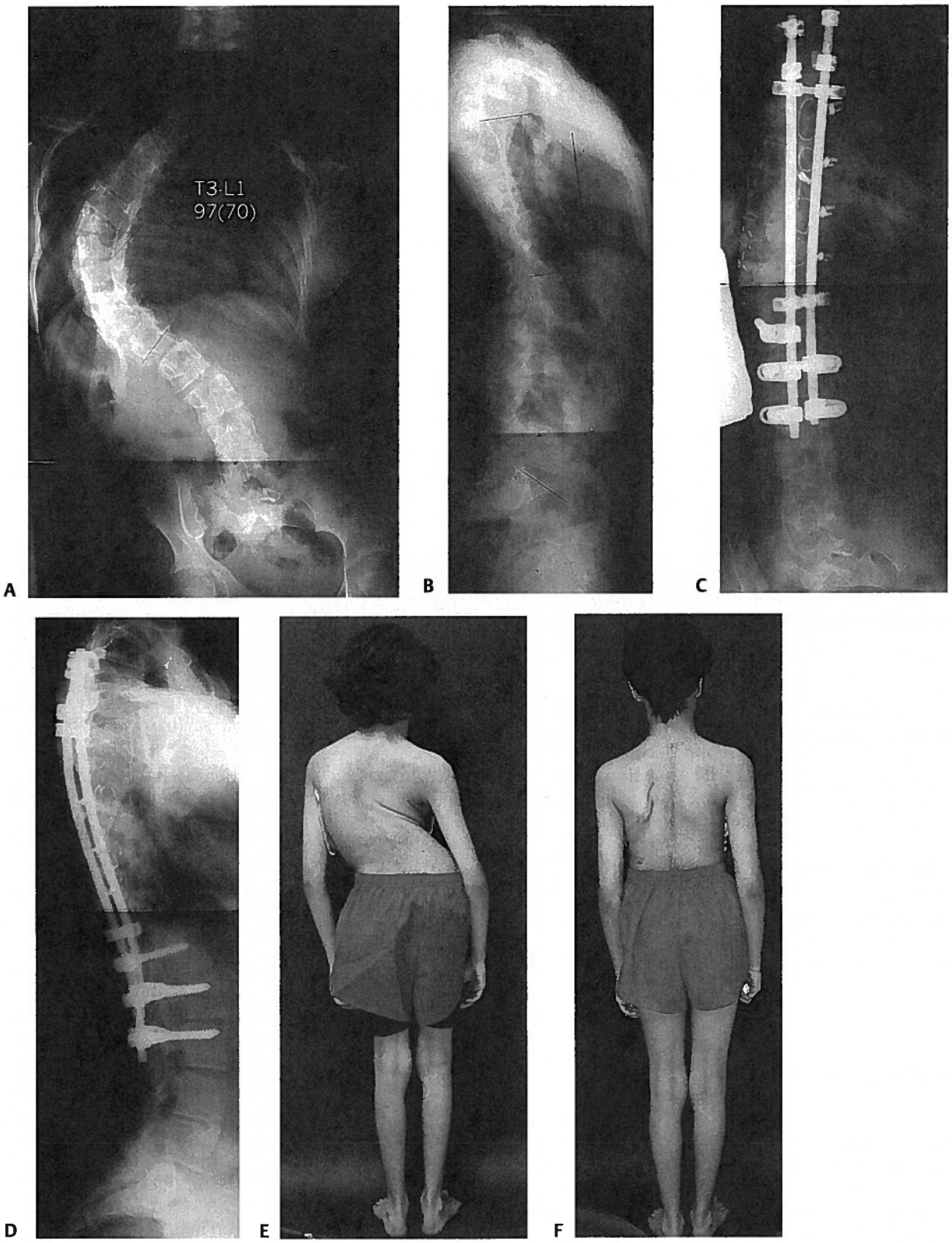

Figure 17–1 Fourteen-year-old female with untreated scoliosis presented with large, aesthetically displeasing deformity. This patient underwent a sequential anterior release with internal thoracoplasty followed by posterior concave rib osteotomies and fusion with instrumentation and autologous bone graft. **(A)** Preoperative posterior/anterior (PA) standing radiograph demonstrates a rigid right thoracic curve, which measured 97 degrees from T3 to L1 and corrects to 70 degrees on bending. **(B)** Preoperative lateral radiograph with evidence of hypokyphosis and decreased lordosis with good global alignment. **(C)** Postoperative PA standing radiograph demonstrates balanced correction of the thoracic curve to 20 degrees. **(D)** Postoperative lateral radiograph demonstrates excellent sagittal contours. **(E)** Preoperative clinical photograph demonstrates a large, left thoracic prominence with coronal malalignment. **(F)** Postoperative clinical photograph with excellent restoration of balance and reduction in the thoracic prominence.

G

H

Figure 17–1 *(Continued)* **(G)** Preoperative clinical photograph of the Adams forward bend test demonstrating a significant prominence. **(H)** Postoperative clinical photograph demonstrates excellent improvement in the thoracic prominence.

♦ Preoperative Care

Preoperative radiographic evaluation should in include full-length standing spine films in frontal and sagital planes, and 14 in. × 36 in. films are the routine at our institution. This full-length film allows complete assessment of all curves and the patient's global balance. Bending films to assess the flexibility of the curve are crucial if surgery is being considered. Our preferred approach is with supine bending or traction films for larger curves.[16,17] Other approaches including the fulcrum bending[18,19] and push-pull films are not used routinely at our institution. Radiographic evaluation should not only include Cobb measurement of the curves but an evaluation of overall balance in the coronal and sagittal planes.

MRI and CT-myelogram are common adjuncts particularly in the adult patient. An MRI alone is frequently insuffcient in providing all the necessary information particularly when assessing a large adult curve with stenosis. Diskography although still controversial may be helpful in the adult patient when evaluating the lowest disk to be included in the fusion or the disk that would become the junctional disk.

Cardiac and pulmonary preoperative assessment should be part of the initial evaluation. Pulmonary function test should be considered particularly if thoracotomy, thoracoplasty, or concave rib osteotomies are planned. Lenke has described decreased pulmonary function of 27% in adults after thoracoplasty that may not return for up to 2 years.[20] These issues need to be evaluated and considered preoperatively. In the pediatric patient, considerable decrease in pulmonary function, though a significant perioperative challenge, should not be considered a contraindication if an experienced team to manage patients in the perioperative period exists.[21]

♦ Staging

Surgery performed on the same day is preferable to staged surgery performed days apart.[4,22–24] However, there are technical and medical issues that may dictate a procedure be scheduled as a staged procedure or converted to staged from an intended same-day sequential AP procedure. Technically, the amount of surgery required may be far too great for the allotted surgical time and difficult for the surgical team to complete. If a late start is achieved either due to difficulty with required intubation and line insertion or the surgical approach to the spine is difficult, the procedure may need to be staged. After the anterior procedure, it is customary to consult with the anesthesia team to ascertain whether the patient is stable enough to undergo a second operative procedure. Unforeseen medical events during the first procedure such as significant loss in blood, issues regarding blood pressure, or cardiac events may require conversion to a staged procedure.

Preoperatively, a decision to stage the procedure may be made, and in the older patient with neurologic issues and instability we have in some cases performed the posterior procedure first followed by the anterior, which invariably is for fusion rather than release. In these cases, if the staged procedure should require several weeks or months rather than a few days, the patient will have a relatively stable spine. The alternative would leave the patient with an unstable spine and a patient with untreated stenosis that requires decompression.

Procedures performed on the same day have lower infection rates, decreased hospital stay, and increased patient satisfaction.[4,22–24] It has been shown that caloric requirements increase in the days after spine surgery,[25] and reduction in complications with supplemental nutrition have been demonstrated.[26] If an AP procedure is to be staged, hyperalimentation between stages is an important consideration to prevent malnutrition, which has been implicated in complications such as poor wound healing and infection.[24,27,28]

♦ Surgical Treatment

The anterior approach is achieved through a thoracotomy, a retroperitoneal approach, or a thoracoabdominal approach. The thoracoabdominal approach requires release of the

diaphragm and might provide additional morbidity in the perioperative period. If adequate access may be achieved without entering the chest or release of the diaphragm, this may improve recovery. However this should not compromise what access is required to provide the ultimate goal, which is a stable and balanced spine.

Multiple diskectomies is the simplest release required from the anterior approach. Following intervertebral artery ligation and annulotomy, a complete diskectomy is performed to bleeding end plates. Release of the annulus on the opposite side is often difficult, and Kerrison rongeurs can often help complete this release.

Minimally invasive procedures are becoming a popular approach particularly in the thoracic spine in deformity surgery. The advantages cited include enhanced visualization, reduced postoperative pain, less scarring, and reduced blood loss, incisional pain, ICU days, and hospital days.[29–33] The thoracosopic approach provides a useful method for performing diskectomy although multiple boney resections in the ankylosed spine provides an additional challenge. Thoracoscopy provides an improved area of spine exposure without resorting to extensile exposures.[31] The disadvantages are the learning curve, loss of binocular vision, tactile feedback, and the requirement for double-lumen intubation with single-lung ventilation. Endoscopic procedures may have limitations in very large curves because of reduced access and decreased space for instruments. Thoracoscopy has also allowed us to perform instrumented anterior fusion. It does have the potential to allow simultaneous AP surgery.[33] The thoracoscopic approach will certainly have a significant impact in our surgical treatment of spine deformity in the future. Its full potential is still to be realized.

With larger deformities and certainly adult patients, the diskectomy takes the form of an osteotomy in that the disk is severely degenerated and or ankylosed and resection of vertebral end plate with either osteotomies or high-speed drills is required **(Fig. 17–2).** To ensure appropriate release and or fusion, the resection should be completed over the entire transverse plane of the vertebral body.

Fusion is achieved with autologous bone from the rib and or allograft bone. We prefer morselized graft verses structural graft because it allows for posterior correction without the graft displacing as can occur if a large structural graft is used. Anterior fixation would prevent posterior correction and therefore is avoided if deformity correction is anticipated posteriorly. If structural support is considered, our preferred approach is with a mesh cage filled with allograft or tricortical allograft. Other options include various structural spacers, bone substitutes, and commercially obtained bone morphogenetic proteins.

It is important to consider adequate structural grafts at L4-L5 and L5-S1, which helps to protect posterior sacral fixation.

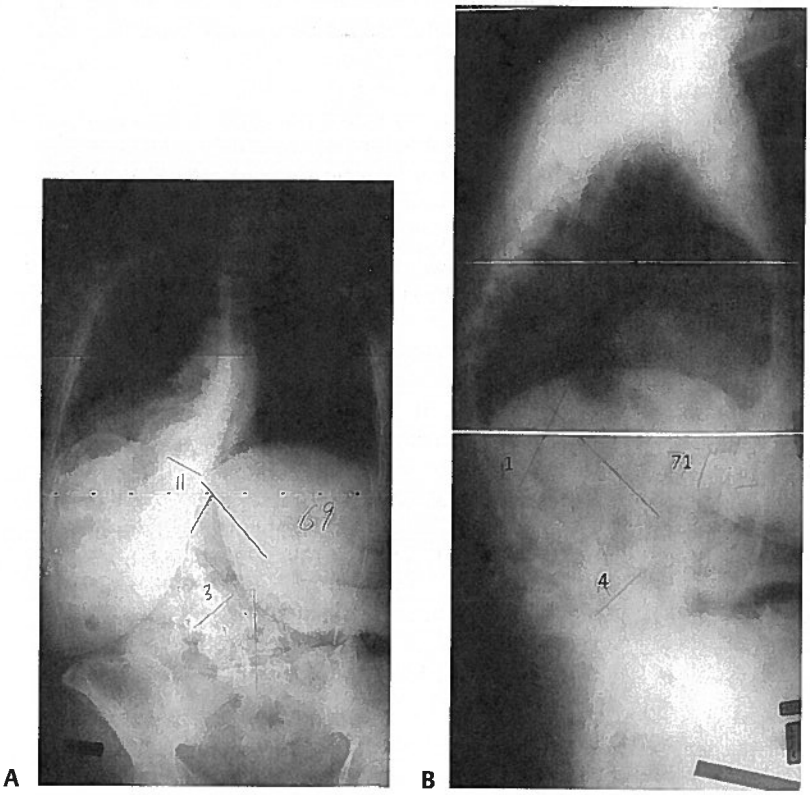

Figure 17–2 A 49-year-old female with adolescent onset scoliosis, progressive spine deformity, and debilitating back pain. This patient underwent staged AP surgery with extensive anterior release followed by posterior fusion to the sacrum with pelvic fixation. **(A)** Preoperative PA standing radiograph demonstrates a rigid left thoracolumbar curve of 67 degrees with coronal misalignment. **(B)** Preoperative lateral radiograph with significant kyphosis with apex at the thoracolumbar junction.

(Continued)

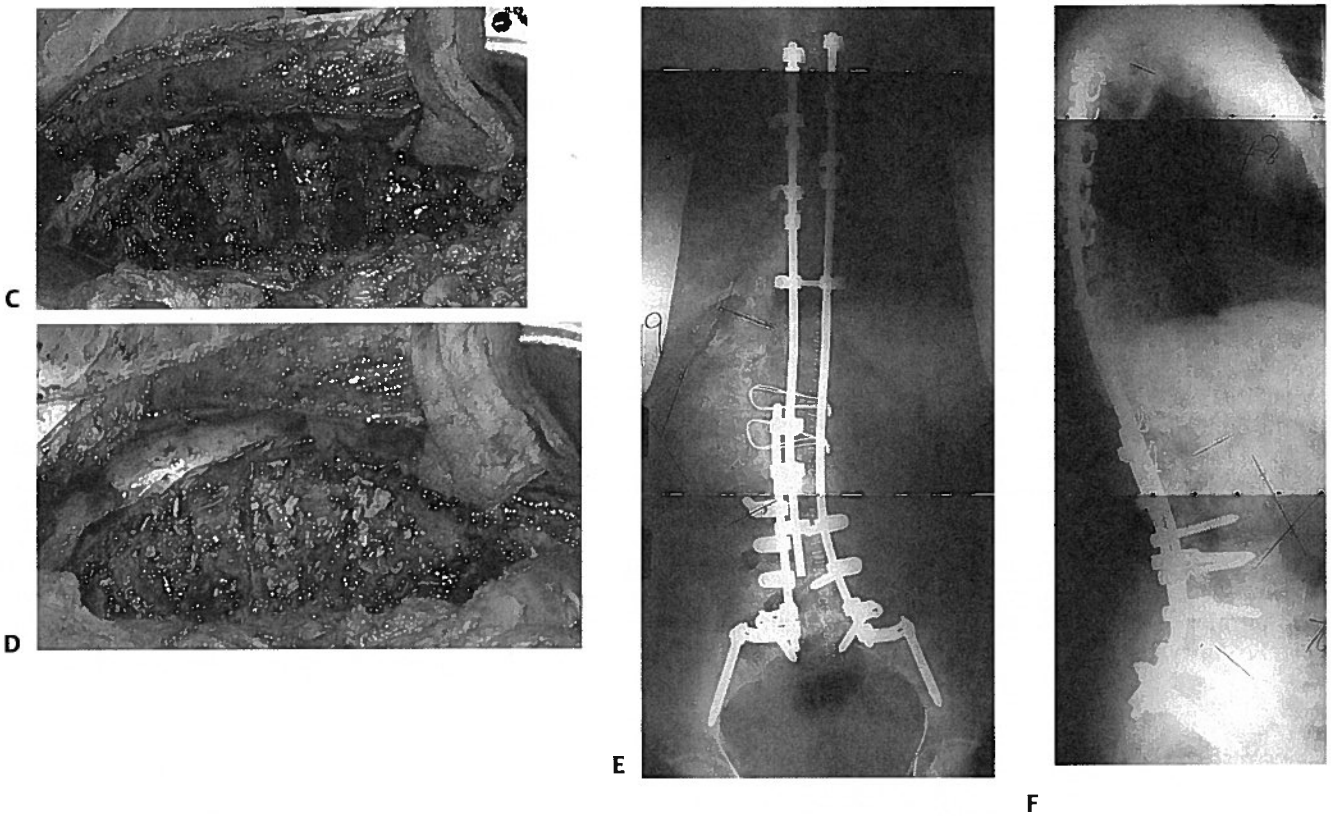

Figure 17–2 *(Continued)* **(C)** Intraoperative photograph showing aggressive diskectomy with bone resection for adequate release. **(D)** Intraoperative photograph showing morselized rib and allograph filling the defects. **(E)** Postoperative PA stranding radiograph with balanced correction of the deformity. **(F)** Postoperative lateral radiograph demonstrating excellent restoration of sagittal alignment.

Significant coronal correction is not always required at L4-L5 and L5-S1 and so this is not as much of an issue when the posterior procedure is required. Coronal correction is important at L4–5 and L5-S1 where 60% of the sagittal lordosis resides.

Thoracoplasty may be performed during the anterior approach if performing a thoracotomy at that level. The rib is exposed from the apex to the rib head through a subperiosteal exposure. The rib is cut at the apex and released from its ligamentous attachments at the rib head. The bone may be used for bone grafting at the disk or osteotomy level. The chest is closed over a chest tube in the usual manner. If thoracoplasty is required with an anterior approach, we have found performing this with the anterior approach avoids additional posterior dissection.

Posterior thoracoplasty requires subcutaneous exposure to the medial aspect of the thoracic prominence from the midline wound. The lateral border of the trapezius muscle is released and the muscle over the rib is retracted medially. The ribs for resection are identified as they contribute to the prominence. Subperiosteal dissection of the ribs is performed using Alexander and Doyin instruments. The medial portion of the rib is resected from apex to the transverse process of the spine. The rib bed is checked for fluid leaks if there is no chest tube from a thoracotomy on that side. If there is a fluid leak, a chest tube should be placed, otherwise the bed is drained and the superficial muscle layers are closed with absorbable running suture.

Concave rib osteotomies are performed on the concave side of the deformity in the thoracic spine. Exposure is performed over the transverse process to the rib. Subperiosteal dissection of the rib is performed, and the rib is cut in the sagittal plane and allowed to displace posteriorly over the instrumentation during correction.

Rigid deformities require adequate posterior release; at the minimum complete release of all facet joints at the levels to be fused is required. Further resection with complete removal of the facet joint to include the inferior facet and the superior facet at the level of the foramina may be required. In the severely ankylosed spine, this may be considered an osteotomy with complete removal of facets and lamina with visualization of the dura from one foramina to the other at a given level. The posterior release should correspond with the level of the anterior release for effective deformity correction.

Large rigid deformities not satisfactorily managed by customary anterior and posterior releases with or without osteotomies may benefit from a spinal shortening procedure or vertebral column resection. The technique consists of an anterior approach to the convexity of the curve. After segmental vessel ligation, an osteoperiosteal flap over the apical two to three vertebral bodies is performed. The vertebrae are resected to the dura posteriorly, and the disks are removed to the posterior longitudinal ligament. The pedicles are resected at the base for which the concave pedicles may be difficult to remove. Cancellous bone removed from the resected vertebral body is then placed in the cavity created with the dura protected by fat or gelfoam. The outer portion of the osteoperiosteal flap is sewn loosely back over the spinal column.

The posterior procedure is done the same day or several days apart. After posterior exposure, concave rib osteotomies and convex thoracoplasty are performed. Provisional fixation is performed, and the posterior arch and remainder of the pedicles are removed. The dura is visualized over the resected segments, and care is taken to ensure pulsations are observed throughout the procedure. Spinal cord monitoring and serial wake-up tests are performed during the correction. Correction is provided through reduction of proximal and distal anchors with a multiple rod technique after removal of the provisional fixation. Control of the spine during this maneuver is essential as caudal spine lifts posteriorly and the cephalic portion tends to drop anteriorly. Inadquate control of the spine during this aspect of the maneuver can cause spine translation and kinking of the dura with potential neurologic sequelae.

♦ Postoperative Care

Postoperatively patients are mobilized within 24 to 48 hours. Antibiotics are used for 24 to 48 hours. Antiembolic lower extremity compression devices are used until the patient is ambulatory. Patients considered at high risk for thromboembolic event are considered for preoperative vena cava filter for which there now exist removable versions. A postoperative brace is frequently used while a patient is out of bed.

♦ Conclusion

Although much spinal deformity can be successfully treated with a single surgical approach, there are occasions when a combined AP approach is indicated. These may be for reasons related to rigidity of the deformity, concerns regarding the potential for fusion, or other patient or pathology specific reasons. These cases are technically and physically demanding. Careful preoperative planning and the availability of a surgical and anesthetic team experienced in these challenging cases are vital to a successful outcome. Whereas same-day procedures have advantages, there are times when it is prudent to stage surgery.

References

1. Floman Y, Micheli LJ, Penny JN, Riseborough EJ, Hall JE. Combined anterior and posterior fusion in seventy-three spinally deformed patients: indications, results and complications. Clin Orthop Relat Res 1982;164:110–122
2. Jules-Elysee K, Urban MK, Urquhart BL, Susman MH, Brown AC, Kelsey WT. Pulmonary complications in anterior-posterior thoracic lumbar fusions. Spine J 2004;4(3):312–316
3. Liew SM, Simmons ED Jr. Thoracic and lumbar deformity: rationale for selecting the appropriate fusion technique (anterior, posterior, and 360 degree). Orthop Clin North Am 1998;29(4):843–858
4. Powell ET, Krengel WF III, King HA, Lagrone MO. Comparison of same-day sequential anterior and posterior spinal fusion with delayed two-stage anterior and posterior spinal fusion. Spine 1994;19(11):1256–1259
5. Pascal-Moussellard H, Klein JR, Schwab FJ, Farcy JP. Simultaneous anterior and posterior approaches to the spine for revision surgery: current indications and techniques. J Spinal Disord 1999;12(3):206–214
6. Lim M, Wazeka A, Boachie-Adjei O. Ventilator weaning after staged anteroposterior spine fusion in a ventilator-dependent patient with congenital scoliosis: a case report. Spine 2003;28(13):E256–E259
7. Kopp M. Caring for the adult patient undergoing anterior/posterior spinal fusion. Orthop Nurs 1997;16(2):55–59; quiz 60–61.
8. Berven SH, Deviren V, Smith JA, Hu SH, Bradford DS. Management of fixed sagittal plane deformity: outcome of combined anterior and posterior surgery. Spine 2003;28(15):1710–1715; discussion 1716
9. Rawlins B, Weidenbaum M, Farcy J, Glassman S. Simultaneous anterior and posterior procedures for short segment spine pathology. Ortho Trans 1994;18:242–243
10. Kuklo TR, Lenke LG, Polly DW, O'Brien MF. Thoracic pedicle screws in curves >90 degrees. Spine (in press)
11. Lenke LG, Dobbs MB. Idiopathic scoliosis. In: Frymoyer JW, Wiesel SW, eds. *The Adult and Pediatric Spine*, Third Ed. Philadelphia: Lippincott Williams & Wilkins; 2004:337–360
12. Lenke LG, Betz RR, Haher TR, et al. Multisurgeon assessment of surgical decision-making in adolescent idiopathic scoliosis: curve classification, operative approach, and fusion levels. Spine 2001;26(21):2347–2353
13. Liljenqvist UR, Halm HF, Link TM. Pedicle screw instrumentation of the thoracic spine in idiopathic scoliosis. Spine 1997;22(19):2239–2245
14. Burton D, Sama A, Asher M, et al. The treatment of large (>70 degrees) thoracic curves in patients with idiopathic scoliosis with posterior instrumentation and arthrodesis: when is anterior release indicated? Spine 2005;30(17):1979–1984
15. Deviren V, Berven S, Kleinstueck F, Antinnes J, Smith JA, Hu SS. Predictors of flexibility and pain patterns in thoracolumbar and lumbar idiopathic scoliosis. Spine 2002;27(21):2346–2349
16. Polly DW Jr, Sturm PF. Traction versus supine side bending. Which technique best determines curve flexibility? Spine 1998;23(7):804–808
17. Vaughan JJ, Winter RB, Lonstein JE. Comparison of the use of supine bending and traction radiographs in the selection of the fusion area in adolescent idiopathic scoliosis. Spine 1996;21(21):2469–2473
18. Luk KD, Lu DS, Cheung KM, Wong YW. A prospective comparison of the coronal deformity correction in thoracic scoliosis using four different instrumentations and the fulcrum-bending radiograph. Spine 2004;29(5):560–563
19. Luk KD, Cheung KM, Lu DS, Leong JC. Assessment of scoliosis correction in relation to flexibility using the fulcrum bending correction index. Spine 1998;23(21):2303–2307
20. Lenke LG, Bridwell KH, Blanke K, Baldus C. Analysis of pulmonary function and chest cage dimension changes after thoracoplasty in idiopathic scoliosis. Spine 1995;20(12):1343–1350
21. Rawlins BA, Winter RB, Lonstein JE, et al. Reconstructive spine surgery in pediatric patients with major loss in vital capacity. J Pediatr Orthop 1996;16(3):284–292
22. Tsirikos AI, Chang WN, Dabney KW, Miller F. Comparison of one-stage versus two-stage anteroposterior spinal fusion in pediatric patients with cerebral palsy and neuromuscular scoliosis. Spine 2003;28(12):1300–1305
23. O'Brien T, Akmakjian J, Ogin G, Eilert R. Comparison of one-stage versus two-stage anterior/posterior spinal fusion for neuromuscular scoliosis. J Pediatr Orthop 1992;12(5):610–615
24. Dick J, Boachie-Adjei O, Wilson M. One-stage versus two-stage anterior and posterior spinal reconstruction in adults. Comparison of outcomes

including nutritional status, complications rates, hospital costs, and other factors. Spine 1992;17(8 Suppl):S310–S316

25. McMulkin ML, Ferguson RL. Resting energy expenditure and respiratory quotient in adolescents following spinal fusion surgery. Spine 2004; 29(16):1831–1835

26. Klein JD, Hey LA, Yu CS, et al. Perioperative nutrition and postoperative complications in patients undergoing spinal surgery. Spine 1996; 21(22):2676–2682

27. Lapp MA, Bridwell KH, Lenke LG, Baldus C, Blanke K, Iffrig TM. Prospective randomization of parenteral hyperalimentation for long fusions with spinal deformity: its effect on complications and recovery from postoperative malnutrition. Spine 2001;26(7):809–817

28. Hu SS, Fontaine F, Kelly B, Bradford DS. Nutritional depletion in staged spinal reconstructive surgery. The effect of total parenteral nutrition. Spine 1998;23(12):1401–1405

29. Crawford AH, Wall EJ, Wolf R. Video-assisted thoracoscopy. Orthop Clin North Am 1999;30(3):367–385, viii

30. Cunningham BW, Kotani Y, McNulty PS, et al. Video-assisted thoracoscopic surgery versus open thoracotomy for anterior thoracic spinal fusion. A comparative radiographic, biomechanical, and histologic analysis in a sheep model. Spine 1998;23(12):1333–1340

31. Dickman CA, Detweiler PW, Porter RW. Endoscopic spine surgery. Clin Neurosurg 2000;46:526–553

32. Regan JJ, Mack MJ. Endoscopic thoracic fusion cage. In: Regan JJ, Mack MJ, McAfee PJ, eds. *Atlas of Endoscopic Spine Surgery*. St. Louis: Quality Medical Publishing; 1995

33. Lieberman IH, Salo PT, Orr RD, Kraetschmer B. Prone position endoscopic transthoracic release with simultaneous posterior instrumentation for spinal deformity: a description of the technique. Spine 2000;25(17):2251–2257

Chapter 18

Anterior Surgery for Adolescent Thoracolumbar and Lumbar Scoliosis

Timothy R. Kuklo and Brett A. Freedman

History of Instrumented Anterior Spinal Fusion

In 1964, Dwyer was the first to perform an instrumented anterior spinal fusion (ASF) for scoliosis.[1] Subsequently, he reported similar coronal correction of thoracolumbar and lumbar curves after ASF to that achieved with posterior spinal fusion (PSF) using Harrington's technique.[2,3] However, this system, which consisted of screws that were connected via a flexible titanium cable, provided insufficient rigidity and resulted in high rates of hardware failure and pseudarthrosis.[1] Further, it proved to be kyphogenic.

In the 1970s, Zielke improved on Dwyer's technique by exchanging the titanium cable for a semirigid rod.[4–6] Consequently, the bicortical screws (Dwyer's original method) could now be more rigidly connected, thus permitting optimization of Zielke's "ventrale derotations-spondylodese" technique. This technique advocated anterior translation and derotation of the apical vertebra, thus resulting in improved "lordisation" of the lumbar curve by converting a coronal scoliotic curve into a well-balanced normal lumbar contour.[6,7] Moe was the first to report on the Zielke system for thoracolumbar and lumbar scoliosis in the United States.[7] He, too, achieved three-plane correction superior to standard posterior spinal instrumentation techniques while fusing fewer vertebral levels.[7] Other authors have reported similar results, with curve correction of 59 to 83% and fusion rates of 70 to 100% **(Table 18–1)**. The improved coronal and sagittal correction, as well as the enhanced construct rigidity, significantly improves mechanical loading across the anterior vertebral column and theoretically leads to a higher fusion rate.[8,9]

In 1985, the Texas Scottish Rite Hospital (TSRH) anterior instrumentation system was introduced (Medtronic Sofamor Danek, Memphis, TN, USA). This system introduced a larger rod (6.35 mm), which predominantly increased construct stability in rotation and flexion-extension.[9–11] However, the rigid rod proved to be more difficult to contour, especially in situ.[9] Nonetheless, Hall introduced short-segment anterior fusion using this system.[12] He advocated overcorrection at the apex of the curve, fusing an average of only 3.4 levels, and reported coronal and sagittal plane correction similar to those achieved using longer constructs. Bitan et al. achieved similar results with the short-segment technique but without overcorrecting the instrumented segment.[13]

The next major advance was the introduction of the dual-rod Kaneda anterior scoliosis system (KASS)[14] (Depuy Acromed, Rayhnam, MA, USA). He modified his fracture/tumor system to improve upon the perceived weaknesses of the Zielke system in scoliosis surgery, specifically: (1) weak implants, (2) suboptimal sagittal plane correction, and (3) unacceptable correction losses at long-term follow-up.[14] This system includes two flexible (4-mm) rods for improved stability while maintaining implant flexibility. Halm and Liljenqvist similarly modified the Zielke system by adding a second (rigid) rod. They have also reported 2-year results comparable with KASS[15,16] **(Fig. 18–1)**. Multiple other dual-rod anterior systems are now available, each offering improved construct stability, elimination of postoperative bracing, and decreased pseudarthrosis rates.

Clinical and Radiographic Evaluation in Adolescent Idiopathic Scoliosis

A thorough history and physical examination remains the hallmark of any scoliosis evaluation. This includes evaluation of trunk asymmetry and rotation, shoulder balance, and curve flexibility. In addition, most patients will decompensate or shift toward the curve convexity. Clinical correlation with the radiographs is also important, especially when correcting trunk shift and shoulder balance. The menarchal

Table 18–1 Results After Anterior Spinal Fusion for Adolescent Idiopathic Thoracolumbar or Lumbar Scoliosis

Author	Journal	Year	System	Bone Graft	n*	Average Number Fused Levels	Fusion Rate (%)	TL/L* Correction Post-op (%)	Correction* at Final Follow-up (%)	Initial* Thoracic Correction (%)	Postoperative Bracing
Dwyer[2]	JBJS	1974	Dwyer	Morcelized	26	E-E‡	96	NA	58–70	NA	Yes
Moe[7]	CORR	1983	Zielke	Structural	31	5.1	98	77	68	40	Yes
Ogiela[8]	Spine	1985	Zielke	M/S§	6	5	83	85	83	56	Yes
Kaneda[73]	CORR	1986	Zielke	M/S	23	E-E	100	87	82	NA	Yes
Puno[42]	Spine	1989	Zielke	NA	34	<E-E‖	100	68	51	31	Yes
Wojcik[74]	Spine	1990	Zielke	NA	18	NA	78	82	63	33	Yes
Lowe[45]	Spine	1993	Zielke	M/S	36	4.5	NA	NA	69	37	Yes
Moskowitz[76]	Spine	1993	Zielke	Structural	13	4.4	100	94	82	50	Yes
Turi[10]	Spine	1993	TSRH†	Morcelized	14	5	100	75	66	43	Yes – 13/14
Kaneda[14]	Spine	1996	KASS	Structural	13	<E-E	100	83	81	47	Yes
Johnston[51]	Sem Spine	1997	TSRH	NA	31	NA	84	75	68	32	Mostly not
Bernstein[12]	JPO Br	1998	Short-TSRH¶	Morcelized	17	3.4	82	87	67	24	Yes
Majd[41]	Spine	2000	Moss#/TSRH	Cages	22	NA	96	NA	82	65	NA
Sweet[60]	Spine	2001	Moss/CD**	Cages	47	E-E	96	74	70	36	No
Ouellet[66]††	Spine	2002	TSRH	M/S	50	4	70	72	61	NA	No
Bitan[19]‡‡	Spine	2002	Short-TSRH	Morcelized	24	2.9	92	NA	54	21	No
Bullman[70]	Spine	2003	HZ[a]	NA	31	E-E	98	72	64	NA	No
Brodner[26]	Spine	2003	KASS	NA	31	3.3	100	NA	62	40	Yes
Average							**93**	**79**	**68**	**40**	

*n, number of only thoracolumbar/lumbar (TL/L) AIS patients reported in the study; overall curve correction rates are reported for all patients in each series, as this data was rarely segregated based on patient age or underlying indication for surgery.

†Texas Scottish Rites Hospital.

‡End Cobb vertebra to end Cobb vertebra.

§Morcelized and/or structural bone graft.

‖Less than end Cobb vertebra to end Cobb vertebra.

¶Short-segment construct.

#Moss Miami.

**CD Horizon.

††Compared morcelized bone graft to cages.

‡‡Compared structural bone graft to cages.

[a]Halm-Zielke.

status, peak height velocity, Risser sign, and triradiate cartilage status are all markers of skeletal maturity and should also be noted from the history and radiographic evaluation.[17–20] Of these markers, an open triradiate cartilage is most predictive of continued curve progression, crankshafting, and decompensation after spinal arthrodesis.[19,20]

Standard posterior-anterior (PA) or anterior-posterior (AP) and lateral standing and supine side-bending radiographs are required for preoperative planning. It is generally recommended that the lowest instrumented vertebra (LIV) should correct to within 5 to 10 degrees of horizontal on reverse side-bending to prevent decompensation and excessive disk wedging.[21–24] Correction of the planned lowest instrumented vertebra to <5 degrees on reverse side-bending is correlated with improved curve correction, better horizontalization of the end vertebra, and better correction of the lumbosacral fractional curve.[24] This is especially true for thoracolumbar and lumbar scoliosis. The push-prone and traction films can provide important information regarding the flexibility of both the major and minor curves.[25,26] The push-prone view has been shown to predict the postoperative alignment and position of the lowest instrumented vertebra better than supine side-bending views.[24] Additionally, these films can help predict the response of the compensatory curves to selective fusion of the primary curve.[24,25] Information obtained from the push-prone radiograph was equivalent to or better than two side-bending radiographs at predicting the final postoperative coronal alignment. However, both techniques underestimate the ultimate correction obtained with segmental ASF with instrumentation for thoracolumbar/lumbar curves by 7 to 13%.[24,25] Alternatively, axial traction views provide a better prediction of curve correction for large curves (>50 to 60 degrees), and a similar preoperative "stretch film" is required for the Gaines vertebral bone-on-bone fusion technique.[25,26] Attention to the vertebral rotation and apparent thoracolumbar kyphosis on the standing lateral radiograph is also paramount in preoperative thoracolumbar and lumbar curve assessment.

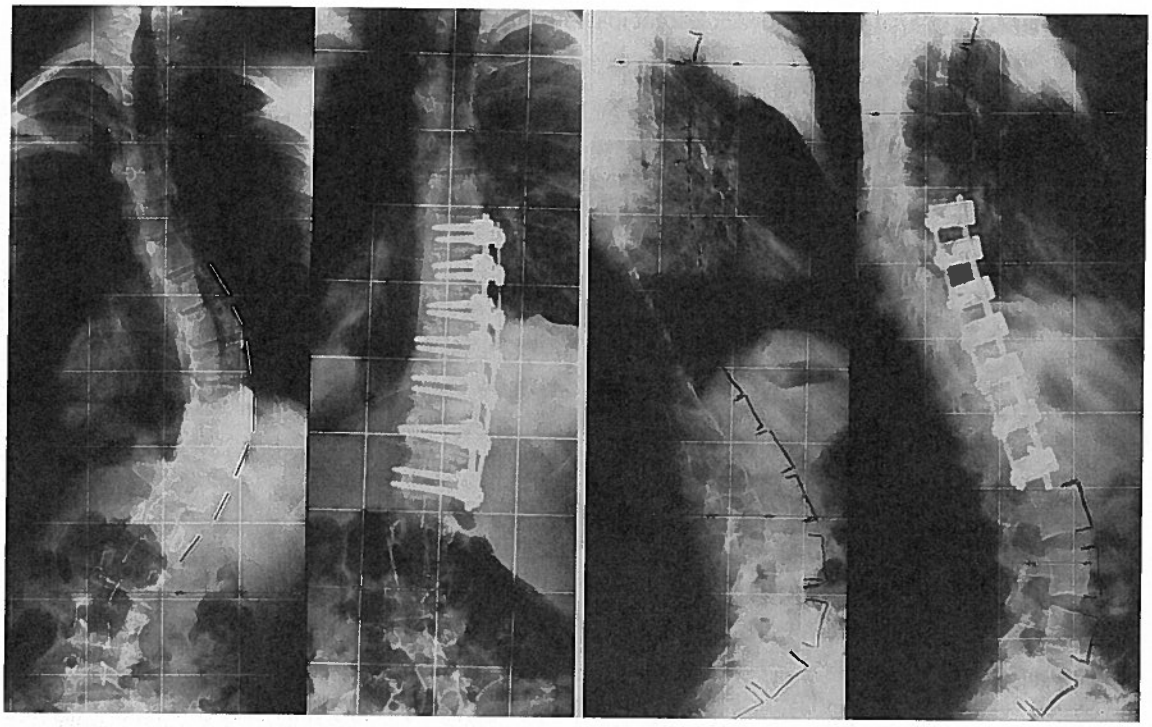

A–D

Figure 18–1 (**A** to **D**) Preoperative and postoperative radiographs of a 14-year-old who underwent anterior spinal fusion using the Halm-Zielke anterior spinal instrumentation system (DePuy Spine SARL, Neuchatel, Switzerland).

As for vertebral rotation, the Nash-Moe and Perdriolle methods are most commonly used.[27] However, the method of Aaro and Dahlborn, which measures the axis of apical vertebral body rotation compared with a sagittal reference line on computed tomography (CT) scanning, yields the best assessment of vertebral rotation.[28,29] This technique is not ideal, however, as it is performed in the supine position, not the standing position. We do not promote the routine use of CT for the evaluation and treatment of scoliosis with ASF, as CT scans are impractical and expensive. Furthermore, they result in excessive radiation exposure.[30,31]

♦ Indications for Anterior Spinal Fusion

In general, thoracolumbar and lumbar curves >40 to 45 degrees in skeletally immature patients are indicated for arthrodesis to prevent further curve progression. However, there are no absolute indications for selecting an anterior or posterior approach in these curve types. During the past 30 years, ASF has become a favored treatment for idiopathic thoracolumbar and lumbar curves because it offers excellent coronal and rotational correction while fusing fewer levels.[32–35] This approach also preserves the integrity of the posterior spinal musculature. Further, posterior fusions ending at L3 or above have been shown to have a decreased incidence of low back pain later in life, hence ASF has been an appealing approach if extension to L4 or L5 would be necessary with a posterior fusion.[21,36,37]

Whereas an anterior or posterior approach can be used to treat most cases of idiopathic thoracolumbar/lumbar scoliosis, some cases preferentially respond to PSF. Patients with asymptomatic spondylolisthesis may benefit from the distal fusion level(s) saved with an anterior approach,[33,34] whereas patients with symptomatic spondylolisthesis may best be approached posteriorly as this permits later extension to the sacrum.[12,38] Similarly, King I or Lenke 5C (and most 6C) curves in which the thoracic minor curve demonstrates poor flexibility (<50%) or moderate to large magnitude (>35 to 50 degrees) may best be approached posteriorly as these curves may need to be included in the fusion.[12,39] Likewise, rigid fractional lumbosacral curves ("oblique spinal take-off") inferior to the planned fusion level are best treated via a posterior approach, allowing extension of the fusion to L4 or caudally as needed. Lumbosacral fractional curves that do not correct to <15 degrees from the horizontal on supine side-bending films have an increased risk of postoperative coronal imbalance.

Finally, anterior instrumentation should not be routinely placed at L4 level or below, as the hardware poses a risk to the nearby iliac vessels and increases the incidence of injury to the superior hypogastric plexus. Patients with very large (>70 to 90 degrees) or rigid curves, or obese patients (>15% over ideal body weight) may require a combined anterior and posterior spinal fusion, where the anterior approach (release) provides increased curve flexibility while the posterior approach provides supplemental internal stability.[40,41] However, advancements in spinal instrumentation techniques have decreased the need for such combined anterior and posterior fusions.

♦ Selecting Fusion Levels

The proper selection of fusion levels is simply a balance of the competing goals of improved curve correction versus preservation of spinal mobility, with the ultimate goal of achieving a balanced spine centered over the sacrum in both the coronal and sagittal plane while fusing as few motion segments as possible. Much research has been dedicated toward this end; however, rigid guidelines are not possible.

For anterior thoracolumbar or lumbar spinal fusion, the most common recommendation is to include the superior and inferior end vertebrae in the fusion **(Fig. 18–2).** Puno et al. found that anterior fusions that were stopped short of the inferior end vertebra resulted in increased overall curve progression compared with fusions stopped at the inferior end vertebra.[42] Similarly, Luk et al. noted an "adding on" phenomenon with Dwyer and Zielke instrumentation when thoracolumbar or lumbar curves were fused to one level short of the inferior end vertebra.[43] Kaneda et al. and Puno et al. both demonstrated better correction of the lower compensatory lumbosacral curve when the primary curve was fused from end vertebra to end vertebra using the Zielke system.[42,44] In addition, when instrumentation is extended cephalad to the superior end vertebra, there was an increased likelihood of worsening of the compensatory thoracic curve (29% versus 7% of those fused from end vertebra to end vertebra).[42,44] Kaneda et al. reported saving a distal motion segment in 64% of patients in which the vertebra above the inferior end vertebra was neutral, within the Harrington stable zone and horizontalized on side bending.[44] For the superior end vertebra, they included this level in the fusion if the compensatory thoracic curve demonstrated >50 to 60% flexibility on supine side-bending. If the compensatory thoracic curve was rigid, then they fused to one vertebral body caudad to the superior end vertebra to prevent decompensation of the thoracic curve. Using these criteria, mean trunk shift improved 84%. When the compensatory curve is large (>35 to 50 degrees) or rigid (<50% flexibility), decompensation can occur after selective fusion, thus necessitating a subsequent PSF.[39] For these more problematic curves, primary long posterior or anterior/ posterior fusion is preferential.

We currently advocate ASF from superior to inferior end vertebra (Cobb angle) for Lenke 5C curves **(Table 18–2)** and some Lenke 6C thoracolumbar/lumbar curves that meet the listed criteria **(Table 18–3).** However, if the vertebra above the

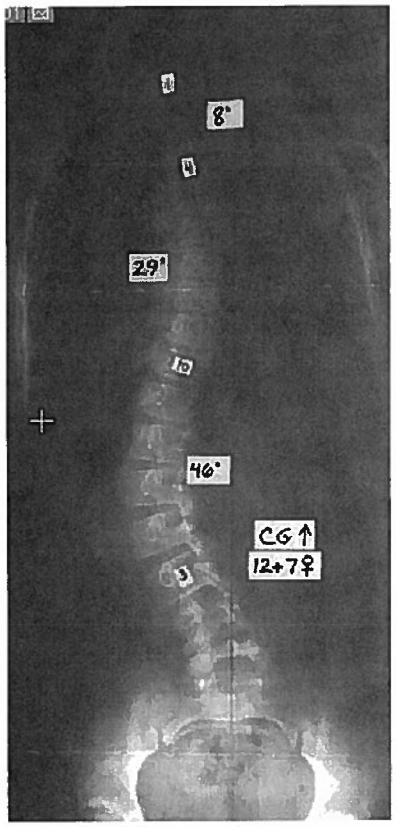

Figure 18–2 Anterior/posterior (AP) radiograph of a 46-degree Lenke 5C thoracolumbar-lumbar curve with mild coronal decompensation to the left. For this case, proper fusion levels should most likely be from T10 to L3 (end vertebra to end vertebra).

Table 18–2 Lenke Classification System

Class	Prevalence Rate (%)	
1	51	Main thoracic (MT)
2	20	"Double thoracic," MT + proximal thoracic (PT)
3	11	"Double major," MT ≥ thoracolumbar/ lumbar (TL/L)
4	3	"Triple major," PT + MT + TL/L
5	12	"Thoracolumbar/lumbar," TL/L
6	3	Thoracolumbar/lumbar–main thoracic," TL/L > MT

Sources: Adapted from Lenke LG, Betz RR, Harms J, et al. Adolescent idiopathic scoliosis: a new classification to determine extent of spinal arthrodesis. J Bone Joint Surg Am 2001;83-A(8):1169–1181. Prevalence rates from Lenke LG, Betz RR, Clements D, et al. Curve prevalence of a new classification of operative adolescent idiopathic scoliosis: does classification correlate with treatment? Spine 2002;27(6):604–611.

Table 18–3 Criteria for Selecting Fusion Levels[77]

Selective Thoracolumbar/Lumbar Curve (Lenke 5C, 6C) Criteria
Cobb, AVT, AVR ratio of TL/L:MT > 1.25
Flexible thoracic compensatory curve (bends to ≤20 to 25 degrees)
No TL/L junctional kyphosis (T10-L2 < +20 degrees)
TL/L > MT trunk shift – decompensation to the side of the TL/L curve
Thoracic rib prominence is acceptable to patient, family, and surgeon
Closed triradiate cartilage
Normal or hypokyphosis (T2-T12 <40 degrees)
LIV corrects to ≤10 degrees from horizontal

AVT, apical vertebral translation from the center sacral line; AVR, apical vertebral rotation (Nash-Moe grade); TL/L, thoracolumbar/lumbar curve; MT, main thoracic curve; LIV, lowest instrumented vertebra.

Sources: Adapted from Lenke LG, Edwards CC 2nd, Bridwell KH. The Lenke classification of adolescent idiopathic scoliosis: how it organizes curve patterns as a template to perform selective fusions of the spine. Spine 2003;28(20):S199–207; Sanders AE, Baumann R, Brown H, Johnston CE 2nd, Lenke LG, Sink E. Selective anterior fusion of thoracolumbar/lumbar curves in adolescents: when can the associated thoracic curve be left unfused? Spine 2003;28(7):706–713; discussion 714; Lowe TG, Betz R, Lenke L, et al. Anterior single-rod instrumentation of the thoracic and lumbar spine: saving levels. Spine 2003;28(20):S208–216.

inferior end vertebra horizontalizes (tilt angle ≤10 degrees) completely on reverse (concave) side-bending films without causing more than 15 degrees of wedging in the subjacent disk, this distal motion segment may be spared. Likewise, if the lower end vertebra does not horizontalize sufficiently, then we caution ending the fusion at this level.[45]

♦ Surgical Treatment

The anterior thoracolumbar retroperitoneal approach provides excellent exposure for disk removal, interbody grafting and/or placing of structural grafts, instrumentation, and deformity correction across the thoracolumbar junction. It has been the standard anterior surgical approach for deformity correction since it was introduced by Hodgson.[46,47] The following sequence of steps is our adaptation of this standard approach for adolescent thoracolumbar or lumbar curves. We currently recommend a dual solid-rod system to provide increased construct rigidity and a decreased pseudarthrosis rate.

Preoperative Preparation

Somatosensory evoked potentials (SSEPs) and motor evoked potentials (MEPs) are used for all deformity correction surgeries to provide early warning of neurological compromise. For anterior spinal surgery, segmental vertebral artery ligation may result in a critical decrement in the blood supply to the corresponding spinal cord level, as approximately two-thirds of the blood supply to the spinal cord comes from the anterior spinal artery, which is supplied by these segmental arteries.[48] The largest and most important segmental artery is the arteria radicularis magna, or the artery of Adamkiewicz, which is most commonly found to the left of midline between T8 and L2 in 80% of individuals.[49] Preoperative spinal angiography, magnetic resonance angiography, and intravascular contrast-enhanced CT have been used to identify and avoid the artery of Adamkiewicz in an effort to protect the anterior circulation to the spinal cord.[49] Alternatively, segmental arteries can be clipped or occluded prior to ligation to evaluate the effect on SSEP and MEP signals. This technique may be more efficacious in congenital scoliosis where the spinal cord may be at an increased risk of ischemia.[48] We do not image for the artery of Adamkiewicz preoperatively and consider segmental artery ligation to be extremely safe. Additionally, the Stagnara wake-up test is used as an adjunct to neuromonitoring.[50] It is considered the "gold standard" for assessing intraoperative spinal cord integrity.[48,50] However, we do routinely practice the Stagnara wake-up test with all patients at a preoperative clinic visit to familiarize the patients with this exam, should it be necessary at the time of operation.

A peripheral arterial line and a central venous line are routinely placed prior to positioning. These permit continuous blood pressure and fluid monitoring by the anesthesia team. A Foley catheter is also placed. If fusion above T10 is planned, a double lumen endotracheal tube may be required, but for routine anterior thoracolumbar or lumbar curves, this is usually not necessary. In most cases, curves up to and including T12 can be treated without taking down the diaphragm.

Surgical Approach

The thoracoabdominal approach is less bloody than the posterior approach.[51,52] It traverses well-defined, avascular anatomic planes and does not result in paraspinal muscle denervation as compared with the posterior midline approach.[51,53] The approach is almost always on the curve convexity, which is typically the left side, because all anterior instrumentation systems place screws on the convex, lateral side of the instrumented vertebrae. Additionally, the descending aorta is on the left side. The vessel wall is thicker and more durable than the inferior vena cava, which is more easily injured.

The patient is placed on an inflatable beanbag in the lateral decubitus position on a Jackson table (OSI, Union City, CA, USA). An axillary roll is placed approximately one fist-width inferior to the axilla on the dependent side to take pressure off the brachial plexus. The nondependent arm (left arm for a left thoracoabdominal approach) is placed across the body onto a well-arm holder. The hips and knees are flexed to relax the psoas muscle, and the peroneal nerve is padded for protection. A pillow is placed between the knees. The shoulders and hips are then taped in place to immobilize the patient.

The skin incision is made directly over and follows the contour of the rib selected for resection, usually T10[52] **(Fig. 18–3).** The incision starts lateral to the paraspinal musculature and ends anteriorly, at the lateral margin of the rectus abdominis muscle. Smaller incisions are possible but should not be used if adequate visualization is not possible. It can be carried caudal along the lateral border of the rectus sheath, if a more expansile exposure is needed. The fascia and superficial muscles are divided in line with the incision. Resection of the 10th rib allows for excellent access to the entire thoracolumbar/lumbar spine. The rib is then subperisoteally stripped, with particular attention to avoiding the neurovascular bundle on the caudal side of the rib. A Doyen elevator is used to strip the deep side of the rib, and a rib cutter is used to cut the rib as far posteriorly as possible.

The chest cavity is then entered, and a rib spreader is inserted. When necessary, the lung can be packed out of the field with a moist sponge; however, full lung inflation is possible for most of the procedure. The lower thoracic vertebral bodies are now exposed, and the diaphragm is sharply incised ~1 to 2 cm from its peripheral rib attachment.[1,8,52] This prevents denervation because the phrenic nerve innervation of the diaphragm is from central to peripheral.[1] The retroperitoneal plane is then developed with blunt dissection to expose the lumbar vertebrae. Preoperative ureteral stenting has been advocated by various authors, but we do not use this routinely as it risks perioperative bacteremia. This technique may be valuable for revision cases.

Spinal Exposure

After this, the vertebral bodies are identified, and selected levels are confirmed with fluoroscopy. The disks ("hills") on the convex side of the curve can be quite large. The vertebral bodies are palpated as "valleys." The pleura over the

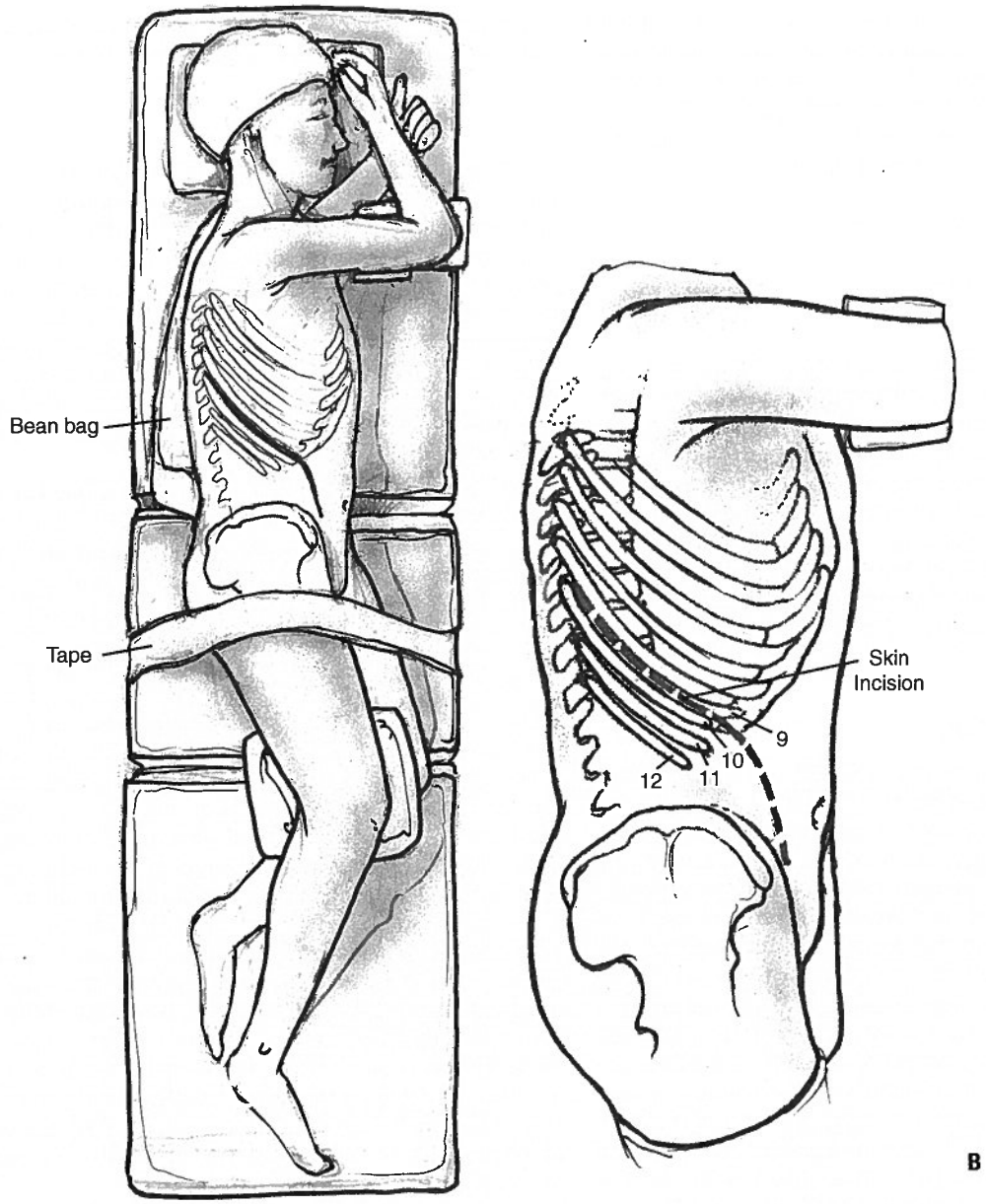

Figure 18–3 Schematic representation of patient positioning **(A)** and incision over 10th rib **(B)**.

thoracic vertebral bodies is incised longitudinally in the midline and then elevated from anterior to posterior as a flap. The areolar tissue overlying the lumbar vertebral bodies is also dissected in a similar fashion. A flap that incorporates the anterior longitudinal ligament can be raised from the midline and elevated to expose the lateral portion of the vertebral body.[42,52] Care is taken when elevating this plane, as the sympathetic chain lies within this tissue layer. The segmental arteries and veins are next dissected, ligated anteriorly, and tied with 2-0 silk sutures on both ends. Anterior or anterolateral ligation protects the more posterior anastomosis that passes between the segmental arteries. This anastomosis protects the anterior blood supply to the spinal cord when multiple segmental arteries are ligated. The dissection is carried just proximal to and distal to the intended fusion levels, thus indirectly mobilizing the aorta, allowing it to fall away. Iliac and iliolumbar vessels will be encountered around the L4 level.

The psoas muscle is elevated by blunt dissection to expose the lateral vertebral body. Care must be taken when elevating the psoas medially, as the sympathetic chain is adjacent to the vertebral body lying in the plane of the aerolar tissue distally and the parietal pleura in the thorax. Neuropraxic injuries to the sympathetic chain from blunt retractors are fairly common. This results in ipsilateral vasodilation and hyperthermia relative to the contralateral extremity. Ogiela and Chan reported transient symptoms from sympathetic chain neuropraxia in 100% of their patients, which resolved in all by 6 months.[8] The psoas typically provides an excellent soft tissue cover to the instrumentation at the end of the case.

Disk Space Preparation

Meticulous disk removal and interbody preparation is essential to a successful outcome. Togawa et al. reported that up to 50% of the cross-sectional area in failed interbody fusions with mesh cages in humans was occupied with remnants of the cartilaginous end plate and nucleus pulposus.[54,55] Additionally, Li et al. demonstrated that residual nucleus pulposus material in the disk space reduced the fusion rate from 70 to 20% in a porcine model.[56] The far side annulus can be left intact to function as a hinge during the corrective maneuver and contain bone graft in the disk space; however, we routinely remove the concave side annulus to increase spinal mobility.[7,57–59] Moe et al. recommended dissecting the adjacent 5 mm of periosteum on either side of the disk space to further ensure that no soft tissue would interpose in the disk space.[7] After this, the cartilaginous end plates are curetted to bleeding cancellous bone, without destroying the structural integrity of the end plate. When using interbody cages, Bridwell and Lenke advocate removing only the cartilaginous portion of the end plates, leaving the subchondral bone intact in the area where mesh cages will be placed.[59–61] They perform decortication of the areas adjacent to the cage(s) once the cages are placed.[59] This sequence is done to avoid settling of the vertebral bodies around the cages. Once the disk space is completely prepared, a thrombin-soaked gelfoam and cottonoid are inserted prior to graft placement to decrease bleeding while completing work at other levels.

Vertebral Screw Placement

Once all levels have been prepared, a dual staple is placed on the lateral vertebral body for screw placement. Staple placement is extremely important because the weakest link in anterior instrumentation systems is the bone-screw interface.[62] Further, the rod derotation maneuver places the highest pullout stresses on the screws, which is distributed more evenly by the vertebral staples. For the KASS tetraspike staple (Depuy Acromed), this leads to a 50% increase in axial screw pullout strength.[57] For dual-rod systems, care must be taken to position the staple in the midbody posterior enough to permit placement of the anterior screw. In the lower thoracic spine, the staple is placed just anterior to the rib head, or alternatively, a small amount of the rib head is removed with a rongeur to permit proper staple placement.[26] The foramen can also be palpated with a no. 4 Penfield to assist in staple placement.

After starting the screw hole with an awl, the posterior screw is generally placed in a slight posterior to anterior angle, at the proper length to achieve bicortical fixation, while leaving only one screw thread exposed on the far cortex. The screw tip should be visualized or at least palpated to ensure that it is not too proud. The posterior screw should not be completely seated on the vertebral staple prior to anterior screw placement, as it will elevate the staple anteriorly off of the vertebral body. The anterior screw is then placed in a slight anterior to posterior direction. Both screws should parallel the vertebral end plates. For scoliosis, the apical screw is placed slightly more posterior, to accommodate the curvature and improve the effect of derotation. Screw placement should usually proceed sequentially more anterior as the upper and lower instrumented vertebrae are approached.[7] The upper and lower screws may be approximately 0.5 to 1 cm anterior to the apical screw[7] **(Fig. 18–4).** The progression between screws should promote a smooth contour to the rod. The more posteriorly placed apical screw is translated relatively more anteriorly during the derotation maneuver, leading to improved lordosis.[6,7]

Rod Placement and Derotation

Rods are cut so that a minimum amount of rod (<3 mm) will protrude cephalad and caudad to the end screws. We place the posterior rod first, while pushing on the anterior screws to assist with correction. This rod should be prebent to match the expected final curvature and the desired lumbar lordosis. After proper placement, little rod rotation is generally required. Set screws are not completely tightened until the derotation has occurred to allow for subtle rod adjustments.

The derotation concept stems from Roaf's observation that scoliosis may actually represent a rotational lordosis, in which there is relative overgrowth of the anterior column versus the posterior column.[53] Diskectomy eliminates this longitudinal mismatch and rotation swings the scoliotic curve into an anatomical lordotic position. This has important implications to the timing of interbody cage placement, as placing the cages prior to derotation may negate the mobilizing effect of the diskectomy. Bitan et al. reported a lower coronal correction when cages were used (38%) compared with when they were not (58%) when fusing with rigid single rod systems.[13] They concluded that although cages improve sagittal correction, they may limit derotation. Thus, the timing and placement of intervertebral spacers should be individualized to each curve and the optimal surgical strategy. Intervertebral grafting with autogenous rib graft, iliac crest bone graft, or cancellous allograft chips can be performed before or after rod placement and correction maneuvers.

Compared with translational corrective techniques, derotation allows for a more even distribution of the corrective force over the entire construct.[10,63] In fact, due to this distribution of force, there is less stress at each individual screw-bone interface than compared with that generated by convex compression.[10] Nevertheless, a significant amount of force is still focused on the bone-screw interface with derotation, so the screws must be observed for evidence of pullout. The primary goal of the derotation maneuver is to restore normal lumbar sagittal contour. Remaining coronal deformity and the angle of the lowest instrumented vertebra can be corrected with convex compression. We generally concur with Bitan et al. and perform derotation prior to interbody spacer placement to enhance the rotatory correction, except at the lowest interbody space. Once derotation has been completed, the set screws or locking nuts are placed to hold this correction. After this, the anterior rod is cut, contoured, and placed with set screws. No further correction is applied after placement of this rod.

Bone Grafting and Intervertebral Spacers

The next step is bone grafting. One level at a time, the gelfoam is removed and a curved curette is used to ensure there is adequate cortical end-plate bleeding. The morcelized bone graft

is then placed—the rib resected during the approach typically provides sufficient graft volume to fill all disk spaces. The set screws or locking nuts can be loosened and gently distracted across each disk space if necessary or if an interbody spacer is planned. Various authors have advocated allograft matchsticks, rib struts, femoral ring allografts, or vertical titanium cages.[14,40,59,60,64–66] Regardless, it is important to pack the remaining disk space with morcelized autologous rib graft. Although the impact of intervertebral cages on pseudarthrosis is not yet completely understood, there is little question that they improve construct rigidity and sagittal plane correction.[64–66] Smith et al. have used structural femoral ring allografts along with Texas Scottish Rite Hospital (TSRH) instrumentation and achieved a 100% fusion with excellent, maintained sagittal correction.[67] Likewise, Moe et al. obtained a 50% correction of kyphosis by placing structural wedge grafts anteriorly versus generation of 11 degrees of kyphosis over the instrumented curve when only bone chips were placed in the disk space.[7] Regardless of the grafting technique, the bone should be placed anteriorly to "prop open" the disk spaces and maintain normal lordosis.[6,7,67]

Convex Rod Compression and Closure

Once all disk spaces have been grafted and spacers have been placed, convex compression on the posterior rod can be applied if necessary. As with the derotation maneuver,

A

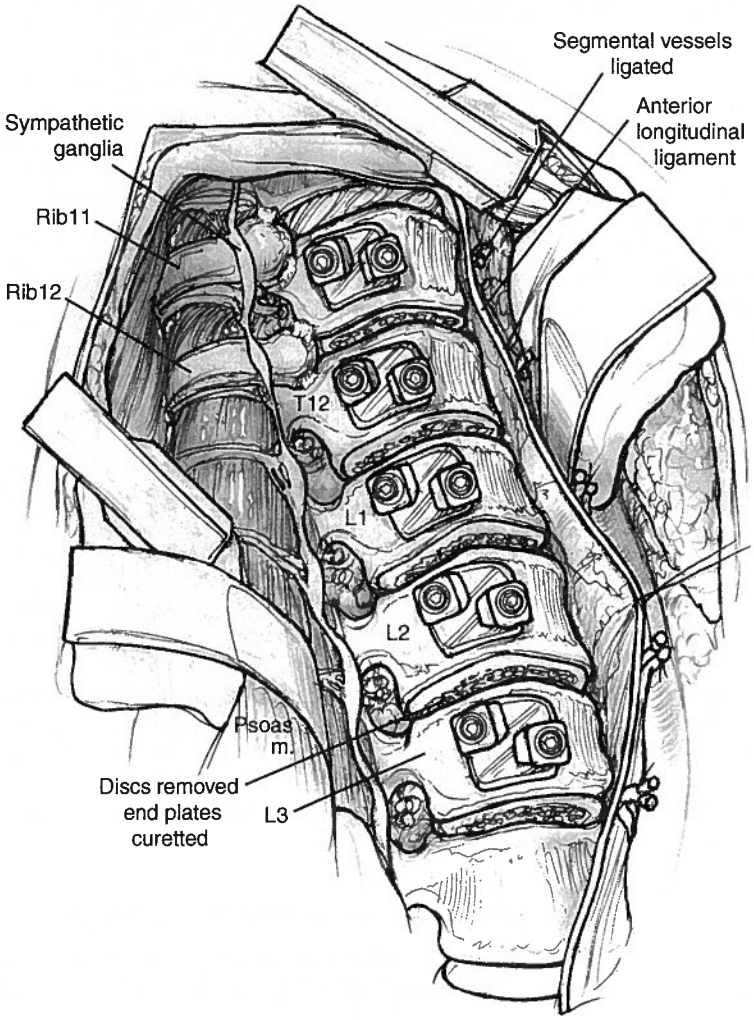

B

Figure 18–4 **(A)** Intraoperative positioning of vertebral body staples, with **(B)** schematic representation and

(Continued)

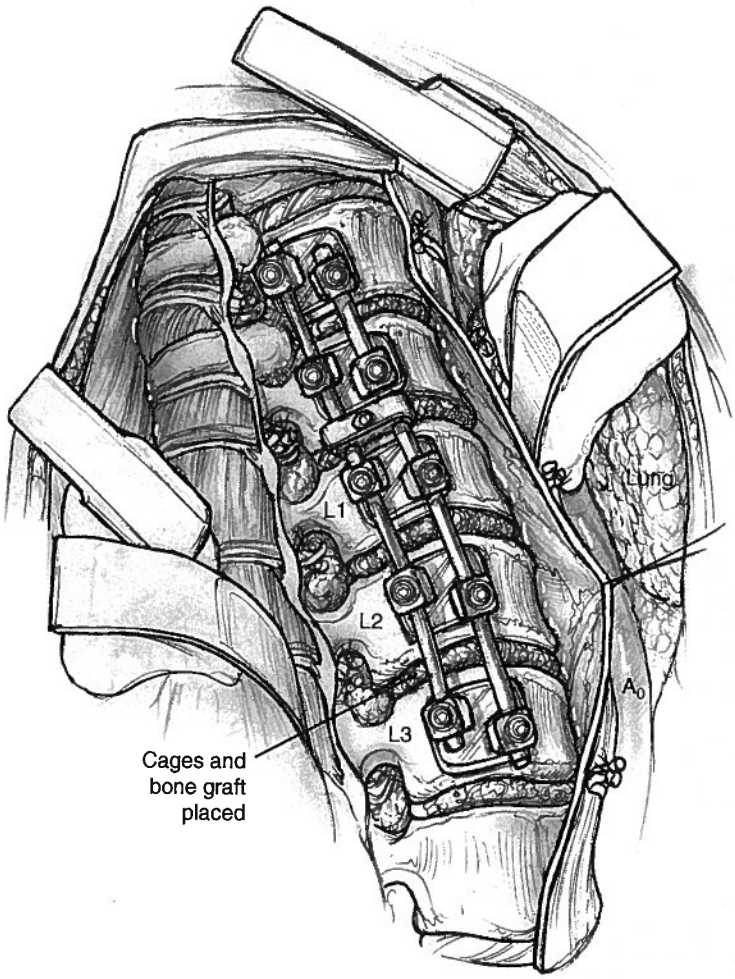

C

Figure 18–4 *(Continued)* **(C)** correction and restoration of lordosis with placement of a dual-rod construct.

the posterior rod is the correcting rod for convex compression, whereas the anterior rod is used to maintain this correction. Interbody compression enhances fusion, as well as curve correction achieved with derotation.[8] Convex compression is also an excellent means for fine-tuning the horizontalization of the lowest instrumented vertebra. Intraoperative AP and lateral radiographs are obtained to confirm coronal and sagittal correction and placement of the instrumentation and interbody spacers. All set screws are then seated and locked. A cross-link may be desired to increase the biomechanical construct rigidity, but this is not necessary. The pleura can be closed with 2-0 chromic catgut suture, but this can be difficult. A chest tube is placed if the thoracic cavity was entered. We repair the diaphragm with interrupted 0 silk sutures, whereas the internal oblique and transversalis muscle layers can be closed in an interrupted or continuous fashion. Our preference is for interrupted no. 1 or 0 vicryl sutures. The external oblique muscle is repaired in a similar manner. A rib approximator is used to assist with approximation before closure of the thoracotomy site. Care should be taken to avoid the intercostal nerve to prevent postthoracotomy syndrome. Absorbable sutures are used for the subcutaneous layers, and steri-strips are placed prior to sterile dressing sponges.

Postoperative Management and Bracing

Historically, thoracolumbosacral orthoses or casts have been prescribed after anterior scoliosis surgery for 3 to 6 months or until fusion.[8,12,39] More recently, improved instrumentation systems have negated the need for postoperative bracing after ASF, although some authors still routinely brace postoperatively. This may have some role in preventing progression of the uninstrumented curve(s) or in maintaining compensatory curve correction and preventing progressive truncal imbalance.[14] Regardless, we typically do not use postoperative braces.

Follow -up Care

Standing PA and lateral radiographs are obtained prior to discharge, and at 6 weeks, 3 months, 6 months, and 1 year postoperatively **(Fig. 18–5).** They are also obtained at 2 and 5 years to evaluate for fusion, implant failure, decompensation, and curve progression. The length of long-term follow-up is debatable. Kohler et al. found that the curve correction and complication rate did not change significantly at 10 years versus 2 years after surgery; thus, 2-year follow-up is a reliable indicator for long-term prognosis.[39] In this series, most hardware failure occurred at 6- to 18-month follow-up.[39] Additionally, pseudarthrosis and

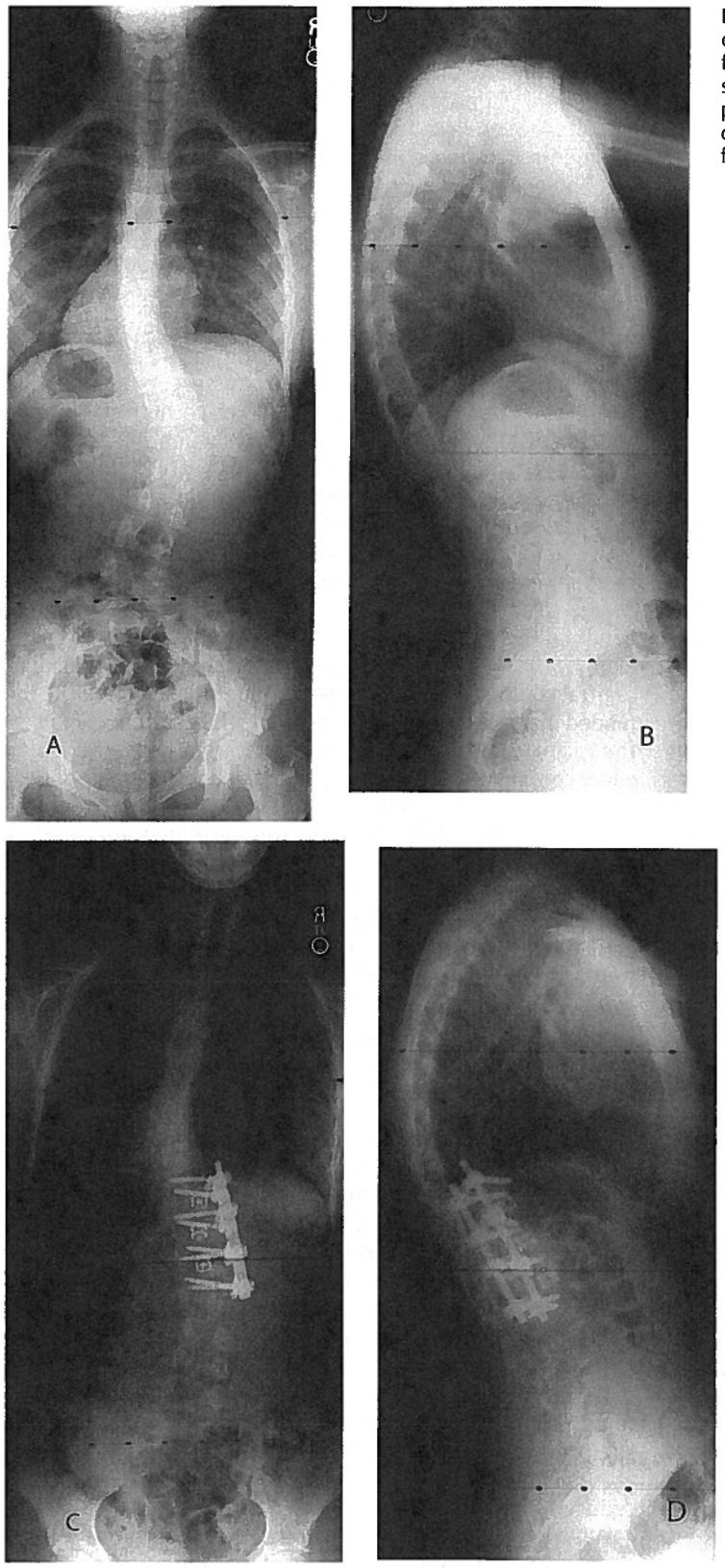

Figure 18–5 (**A** to **D**) Preoperative and postoperative radiographs of a 13-year-old female who underwent anterior spinal fusion from T11 to L2 with CD Horizon instrumentation, Anteres staples, and Pyramesh cages (Medtronic Sofamor Danek, Memphis, Tennessee, USA). The inferior end vertebra is L3. A better overall correction may have been achieved by extending the fusion to L3.

implant failure are strongly associated with curve progression of >10 degrees within the instrumented curve. Skeletally immature patients should be followed closely for signs of progression and decompensation of the thoracic compensatory curve. Once progression occurs, bracing has not proved to be effective, and the only treatment is early surgical intervention. If decompensation or curve progression remains an issue, then posterior fusion is usually the treatment of choice.

Structured physical therapy stressing posture, body mechanics, core muscle strength training, and flexibility is started in a graded fashion on postoperative day 1. It is continued for 6 to 12 weeks after surgery. Patients are placed on a walking program for the first 6 weeks and then are progressed to light, low-impact aerobic activities. Pool therapy may be beneficial and is usually started at 3 weeks when the wound is dry. Patients usually return to school at 2 to 4 weeks. Bookbag limitations are given, and patients are encouraged to carry one book at a time, or alternatively use a roller bag at school. Patients are permitted to return to sports at 6 months.

Results

Anterior scoliosis surgery consistently results in 50% or greater curve and apical vertebral rotation correction, which corresponds with improved cosmesis through resolution of the lumbar prominence **(Table 18–1)**. Numerous clinical trials have reported the results for anterior surgical techniques in treating single curve idiopathic thoracolumbar/lumbar scoliosis **(Table 18–1)**. Although Dwyer and Zielke must be acknowledged for their tremendous contributions toward anterior scoliosis treatment, these older instrumentation systems have become obsolete because of insufficient rigidity, which has led to unacceptably high pseudarthrosis, loss of correction, and implant failure rates. Nevertheless, many key principles from their surgical techniques (i.e., convex compression and derotation) have persisted through the evolution of anterior scoliosis surgery. Current rigid anterior single and dual-rod systems have emerged as the techniques of choice for anteriorly addressing thoracolumbar/lumbar scoliosis. Rhee et al. compared rigid single-rod anterior constructs to segmental posterior constructs and found comparable corrections of sagittal contour, but there was less incidence of proximal junctional kyphosis seen with ASF compared with PSF.[40] The propensity for proximal junctional kyphosis or the need to fuse more proximally than the upper end vertebra when performing PSF stems from the mismatch between coronal and sagittal curves seen with thoracolumbar/lumbar scoliosis. The superior end vertebra of the coronal curve tends to be at or approaching the apex of the thoracic kyphosis, thus posterior fusions that end at the superior end vertebra of the coronal curve are at an increased risk of proximal kyphosis.[51,61] To date, there are no studies comparing the coronal curve correction and overall balance achieved with ASF versus PSF using modern instrumentation systems for thoracolumbar or lumbar curves.

Turi et al. presented the first clinical results of solid, rigid anterior single-rod instrumentation (TSRH).[9,10] They achieved a 100% fusion rate but had an unacceptable rate of progressive kyphosis across the instrumented segments. Bridwell and Lenke stress the importance of this finding and directly address it with structural interbody supports that can block open the vertebrae in a more consistent fashion.[59,61] Settling has not been reported with the Kaneda dual-rod system.[14] It seems that the increased rigidity of this system overcomes the propensity for settling across the intervertebral disk space. Fricka et al. demonstrated that dual-rod constructs were two times more rigid than the native lumbar spine in a bovine cadaver model and that the addition of interbody cages only increased this rigidity by 8%.[68] Alternatively, interbody cages increased construct flexion stiffness by 52% in single-rod constructs. Further, Oda and coauthors demonstrated that increasing the rod diameter is far less effective than adding a second rod to improve construct stiffness.[69] Consequently, it appears that dual-rod systems are biomechanically superior to single-rod systems. In the thoracolumbar spine, the vertebral bodies are almost always large enough to accept a dual-rod system; therefore, it is our preferred technique.

One problem encountered when comparing results from various ASF studies is the variability of curves included in each series and the lack of a good outcome standard. Some authors report the results of isolated thoracolumbar/lumbar curve correction or correction in the face of very small thoracic minor curves, whereas others report on the selective treatment of true double curves, in which both the minor and major curves are structural. Consequently, caution is necessary when comparing differing series' outcomes. Because the ultimate goal of scoliosis surgery is to achieve a balanced stable spine, the best correction for a patient with a double curve may be undercorrection of the major curve. Further, an uninstrumented compensatory curve should be expected to correct no greater than that seen on reverse sidebending. The measured correction of the compensatory curve along with the magnitude of the coronal shift and the regional sagittal contour should be used as guides for selecting the intended magnitude of curve correction when selectively fusing the major curve in double-curve patterns. Thus, the major curve coronal correction may not be the best indicator of success. Overall coronal and sagittal balance may be better indicators; however, they have not been as widely reported in previous clinical trials.

Analysis of these series shows that the general trends include the following: (1) the current rigid anterior single- and dual-rod systems provide more coronal, sagittal, and rotational correction than their predecessors, and (2) segmental kyphosis has decreased with the use of rigid instrumentation systems and structural anterior wedge grafting or interbody spacers.

Complications

Loss of coronal curve correction and segmental kyphosis from instrumentation failure are more commonly found in older, more flexible, single-rod systems. Nonetheless, continued meticulous attention to surgical technique is still required. The use of structural allograft or autograft and more recently interbody spacers have reduced and/or eliminated the incidence of settling and loss of curve correction. In addition, these structural anterior grafts along with more rigid single- and dual-rod instrumentation systems enable the spine surgeon to more accurately correct sagittal contour in the thoracolumbar/lumbar spine.[40] The previous reports of implant failure have been significantly reduced.[33,40,60,70]

When compared with PSF, the pseudarthrosis rate after ASF has historically been greater. This was largely due to the lack of implant rigidity. With modern dual-rod systems, the pseudarthosis rate is now comparable.[14] Although decompensation does occur, it has been less of a problem with ASF. In addition to better immediate postoperative correction, several authors have indicated that coronal imbalance or truncal

Table 18–4 List of Potential Complications After Anterior Spinal Fusion with Instrumentation

Overall complication rate (0–58%)[14,71,72]
Pseudarthrosis (0–30%)[2,7,26,66,76]
Hardware failure (0–38%)
Including screw pullout or ploughing and/or rod breakage[7,12,14,57,71,73]
Complications associated with curve correction
Instrumented kyphosis[7,42,45,71,76,78]
Decompensiaton[32]
Loss of correction[7,42,71]
Retrolisthesis[41]
Complications associated with thoracotomy/pulmonary
Pneumothorax[7,8,26,72]
Atelectesis[2,72]
Pneumonia[26,72]
Post-thoracotomy syndrome[72]
Infection complications
Wound infection[60,72,75,78]
UTI[2,7,8,26,72]
Neurological complications
Sympathectomy[7,8,26,39]
Retrograde ejaculation[72]
Dural tear[72]

UTI, urinary tract infection.

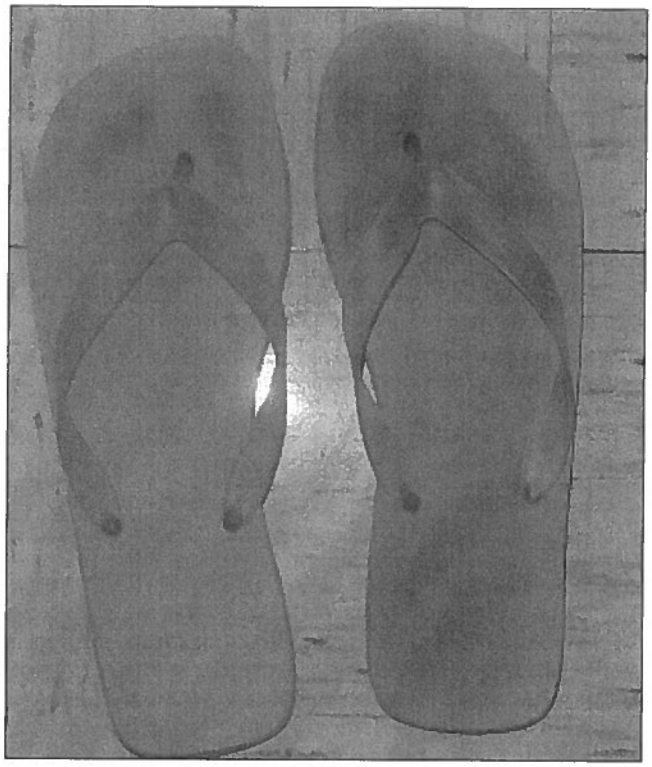

Figure 18–6 Photograph of the flip-flop sandals of a 15-year-old female referred to us with a persistent asymptomatic sympathectomy at 3 years postoperative after anterior spinal fusion from T11 to L3 for a Lenke 5 curve. Notice the lack of staining on the left sandal secondary to anhydrosis.

shift tends to reduce even more with time after ASF as the body settles to its own balance point around the newly straightened segment.[60,61]

Various other complications are inherent to the anterior approach, and care should be taken to minimize these problems (**Table 18–4**).[71,72] Incidental sympathectomy is unique to the anterior surgical approach and is manifested as an increased temperature of the ipsilateral lower extremity due to lack of sympathetic input and consequential vasodilation. It generally resolves with time, although we have seen one patient referred to our practice with a persistent asymptomatic sympathectomy noted by differential foot sweating (**Fig. 18–6**). In very rare instances, it can lead to a complex regional pain syndrome in the involved extremity. Fortunately, we have not seen this in our practice.

Disclaimer The opinions or assertions contained herein are the private views of the authors and are not to be construed as official or as reflecting the views of the United States Army or the Department of Defense. The authors are employees of the United States government. This work was prepared as part of their official duties and as such, there is no copyright to be transferred. The preparation of this manuscript was supported by the Defense Spinal Cord and Spinal Column Injury funding and the Spine Research Center, Walter Reed Army Medical Center.

References

1. Dwyer AF, Newton NC, Sherwood AA. An anterior approach to scoliosis. A preliminary report. Clin Orthop Relat Res 1969;62:192–202
2. Dwyer AF, Schafer MF. Anterior approach to scoliosis. Results of treatment in fifty-one cases. J Bone Joint Surg Br 1974;56(2):218–224
3. Hall JE. Dwyer Instrumentation in anterior fusion of the spine. J Bone Joint Surg Am 1981;63(7):1188–1190
4. Zielke K. [Ventral derotation spondylodesis. Results of treatment of cases of idiopathic lumbar scoliosis (author's transl).] Z Orthop Ihre Grenzgeb 1982;120(3):320–329
5. Zielke K, Stunkat R, Beaujean F. Ventrale derotations-spondylodesis. Arch Orthop Unfallchir 1976;85(3):257–277
6. Giehl JP, Volpel J, Heinrich E, Zielke K. Correction of the sagittal plane in idiopathic scoliosis using the Zielke procedure (VDS). Int Orthop 1992;16(3):213–218
7. Moe JH, Purcell GA, Bradford DS. Zielke instrumentation (VDS) for the correction of spinal curvature. Analysis of results in 66 patients. Clin Orthop Relat Res 1983;180:133–153
8. Ogiela DM, Chan DP. Ventral derotation spondylodesis. A review of 22 cases. Spine 1986;11(1):18–22
9. Johnston CE II, Welch RD, Baker KJ, Ashman RB. Effect of spinal construct stiffness on short segment fusion mass incorporation. Spine 1995;20(22):2400–2407
10. Turi M, Johnston CE II, Richards BS. Anterior correction of idiopathic scoliosis using TSRH instrumentation. Spine 1993;18(4):417–422
11. Shimamoto N, Kotani Y, Shono Y, et al. Biomechanical evaluation of anterior spinal instrumentation systems for scoliosis: in vitro fatigue simulation. Spine 2001;26(24):2701–2708

12. Bernstein RM, Hall JE. Solid rod short segment anterior fusion in thoracolumbar scoliosis. J Pediatr Orthop B 1998;7(2):124–131

13. Bitan FD, Neuwirth MG, Kuflik PL, Casden A, Bloom N, Siddiqui S. The use of short and rigid anterior instrumentation in the treatment of idiopathic thoracolumbar scoliosis: a retrospective review of 24 cases. Spine 2002;27(14):1553–1557

14. Kaneda K, Shono Y, Satoh S, Abumi K. New anterior instrumentation for the management of thoracolumbar and lumbar scoliosis. Application of the Kaneda two-rod system. Spine 1996;21(10):1250–1262

15. Halm H, Liljenqvist U, Castro WH, Jerosch J. Augmentation of ventral derotation spondylodesis according to Zielke with double-rod instrumentation. Preliminary report on two-year results of thoracolumbar curves. Acta Orthop Belg 1995;61(4):286–293

16. Halm HF, Liljenqvist U, Niemeyer T, Chan DP, Zielke K, Winkelmann W. Halm-Zielke instrumentation for primary stable anterior scoliosis surgery: operative technique and 2-year results in ten consecutive adolescent idiopathic scoliosis patients within a prospective clinical trial. Eur Spine J 1998;7(5):429–434

17. Sanders JO, Little DG, Richards BS. Prediction of the crankshaft phenomenon by peak height velocity. Spine 1997;22(12):1352–1357

18. Little DG, Song KM, Katz D, Herring JA. Relationship of peak height velocity to other maturity indicators in idiopathic scoliosis in girls. J Bone Joint Surg Am 2000;82(5):685–693

19. Sanders JO, Herring JA, Browne RH. Posterior arthrodesis and instrumentation in the immature (Risser-Grade-0) spine in idiopathic scoliosis. J Bone Joint Surg Am 1995;77(1):39–45

20. Dubousset J, Herring JA, Shufflebarger H. The crankshaft phenomenon. J Pediatr Orthop 1989;9:541–550

21. Ogilvie JW. Anterior spine fusion with Zielke instrumentation for idiopathic scoliosis in adolescents. Orthop Clin North Am 1988;19(2):313–317

22. Gaines RW, Leatherman KD. Benefits of the Harrington compression system in lumbar and thoracolumbar idiopathic scoliosis in adolescents and adults. Spine 1981;6(5):483–488

23. Lowe TG, Alongi PR, Smith DA, O'Brien MF, Mitchell SL, Pinteric RJ. Anterior single rod instrumentation for thoracolumbar adolescent idiopathic scoliosis with and without the use of structural interbody support. Spine 2003;28(19):2232–2242

24. Vedantam R, Lenke LG, Bridwell KH, Linville DL. Comparison of push-prone and lateral-bending radiographs for predicting postoperative coronal alignment in thoracolumbar and lumbar scoliotic curves. Spine 2000;25(1):76–81

25. Polly DW Jr, Sturm PF. Traction versus supine side bending. Which technique best determines curve flexibility? Spine 1998;23(7):804–808

26. Brodner W, Mun Yue W, Moller HB, Hendricks KJ, Burd TA, Gaines RW. Short segment bone-on-bone instrumentation for single curve idiopathic scoliosis. Spine 2003;28(20):S224–S233

27. Nash CL Jr, Moe JH. A study of vertebral rotation. J Bone Joint Surg Am 1969;51(2):223–229

28. Aaro S, Dahlborn M. Estimation of vertebral rotation and the spinal and rib cage deformity in scoliosis by computer tomography. Spine 1981;6:460–467

29. Aaro S, Dahlborn M. The longitudinal axis rotation of the apical vertebra, the vertebral, spinal, and rib cage deformity in idiopathic scoliosis studied by computer tomography. Spine 1981;6:567–572

30. Hall EJ. Lessons we have learned from our children: cancer risks from diagnostic radiology. Pediatr Radiol 2002;32(10):700–706

31. Lee CI, Haims AH, Monico EP, Brink JA, Forman HP. Diagnostic CT scans: assessment of patient, physician, and radiologist awareness of radiation dose and possible risks. Radiology 2004;231(2):393–398

32. Suk SI, Lee CK, Chung SS. Comparison of Zielke ventral derotation system and Cotrel-Dubousset instrumentation in the treatment of idiopathic lumbar and thoracolumbar scoliosis. Spine 1994;19(4):419–429

33. Lowe TG, Betz R, Lenke L, et al. Anterior single-rod instrumentation of the thoracic and lumbar spine: saving levels. Spine 2003;28(20):S208–S216

34. Betz RR, Harms J, Clements DH III, et al. Comparison of anterior and posterior instrumentation for correction of adolescent thoracic idiopathic scoliosis. Spine 1999;24(3):225–239

35. Lee GA, Betz RR, Clements DH III, Huss GK. Proximal kyphosis after posterior spinal fusion in patients with idiopathic scoliosis. Spine 1999; 24(8):795–799

36. Cochran T, Nachemson A. Long-term anatomic and functional changes in patients with adolescent idiopathic scoliosis treated with the Milwaukee brace. Spine 1985;10(2):127–133

37. Hayes MA, Tompkins SF, Herndon WA, Gruel CR, Kopta JA, Howard TC. Clinical and radiological evaluation of lumbosacral motion below fusion levels in idiopathic scoliosis. Spine 1988;13(10):1161–1167

38. Lindholm TS, Ragni P, Ylikoski M, Poussa M. Lumbar isthmic spondylolisthesis in children and adolescents. Radiologic evaluation and results of operative treatment. Spine 1990;15(12):1350–1355

39. Kohler R, Galland O, Mechin H, Michel CR, Onimus M. The Dwyer procedure in the treatment of idiopathic scoliosis. A 10-year follow-up review of 21 patients. Spine 1990;15(2):75–80

40. Rhee JM, Bridwell KH, Won DS, Lenke LG, Chotigavanichaya C, Hanson DS. Sagittal plane analysis of adolescent idiopathic scoliosis: the effect of anterior versus posterior instrumentation. Spine 2002;27(21): 2350–2356

41. Majd ME, Castro FP Jr, Holt RT. Anterior fusion for idiopathic scoliosis. Spine 2000;25(6):696–702

42. Puno RM, Johnson JR, Ostermann PA, Holt RT. Analysis of the primary and compensatory curvatures following Zielke instrumentation for idiopathic scoliosis. Spine 1989;14(7):738–743

43. Luk KD, Leong JC, Reyes L, Hsu LC. The comparative results of treatment in idiopathic thoracolumbar and lumbar scoliosis using the Harrington, Dwyer, and Zielke instrumentations. Spine 1989;14(3):275–280

44. Kaneda K, Satoh S, Fujiya N. Analysis of results with Zielke instrumentation for thoracolumbar and lumbar curvature. Nippon Seikeigeka Gakkai Zasshi 1985;59(8):841–851

45. Lowe TG, Peters JD. Anterior spinal fusion with Zielke instrumentation for idiopathic scoliosis. A frontal and sagittal curve analysis in 36 patients. Spine 1993;18(4):423–426

46. Hodgson AR. Correction of fixed spinal curves, a preliminary communication. J Bone Joint Surg Am 1965;47:1221–1227

47. Hodgson AR, Stock FE. Anterior spinal fusion for the treatment of tuberculosis of the spine. J Bone Joint Surg Am 1960;42A:295–310

48. Doita M, Marui T, Nishida K, Kurosaka M, Yoshiya S, Sha N. Anterior spinal artery syndrome after total spondylectomy of T10, T11, and T12. Clin Orthop Relat Res 2002;405:175–181

49. Rodriguez-Baeza A, Muset-Lara A, Rodriguez-Pazos M, Domenech-Mateu JM. The arterial supply of the human spinal cord: a new approach to the arteria radicularis magna of Adamkiewicz. Acta Neurochir (Wien) 1991;109(1–2):57–62

50. Ben-David B, Haller G, Taylor P. Anterior spinal fusion complicated by paraplegia. A case report of a false-negative somatosensory-evoked potential. Spine 1987;12(6):536–539

51. Johnston CE. Anterior correction of thoracolumbar and lumbar idiopathic scoliosis. Sem Spine Surg 1997;9(2):150–163

52. Holt RT, Majd ME, Vadhva M, Castro FP. The efficacy of anterior spine exposure by an orthopedic surgeon. J Spinal Disord Tech 2003;16(5):477–486

53. Roaf R. The basic anatomy of scoliosis. J Bone Joint Surg Br 1966;48(4): 786–792

54. Togawa D, Bauer TW, Brantigan JW, Lowery GL. Bone graft incorporation in radiographically successful human intervertebral body fusion cages. Spine 2001;26(24):2744–2750

55. Togawa D, Bauer TW, Lieberman IH, Sakai H. Lumbar intervertebral body fusion cages: histological evaluation of clinically failed cages retrieved from humans. J Bone Joint Surg Am 2004;86-A(1):70–79

56. Li H, Zou X, Laursen M, Egund N, Lind M, Bunger C. The influence of intervertebral disk tissue on anterior spinal interbody fusion: an experimental study on pigs. Eur Spine J 2002;11(5):476–481

57. Kaneda K, Shono Y. Kaneda anterior multisegmental instrumentation – two-rod system for the treatment of thoracolumbar and lumbar scoliotic curvatures. In: Bridwell KH and Dewald RL, eds. The Textbook of Spinal Surgery, Second Ed. Philadelphia: Lippincott-Raven; 1997: 641–663

58. Riseborough EJ. The anterior approach to the spine for the correction of deformities of the axial skeleton. Clin Orthop Relat Res 1973;93:207–214

59. Lenke LG, Bridwell KH. Mesh cages in idiopathic scoliosis in adolescents. Clin Orthop Relat Res 2002;394:98–108

60. Sweet FA, Lenke LG, Bridwell KH, Blanke KM, Whorton J. Prospective radiographic and clinical outcomes and complications of single solid rod instrumented anterior spinal fusion in adolescent idiopathic scoliosis. Spine 2001;26(18):1956–1965

61. Lenke LG, Rhee J. Adolescent scoliosis: anterior surgical techniques for adolescent idiopathic scoliosis. Curr Opin Orthop 2001;12:199–205

62. Snyder BD, Zaltz I, Hall JE, Emans JB. Predicting the integrity of vertebral bone screw fixation in anterior spinal instrumentation. Spine 1995;20(14):1568–1574

63. Delorme S, Labelle H, Aubin CE, et al. Intraoperative comparison of two instrumentation techniques for the correction of adolescent idiopathic scoliosis. Rod rotation and translation. Spine 1999;24(19):2011–2017; discussion 2018

64. Polly DW Jr, Cunningham BW, Kuklo TR, et al. Anterior thoracic scoliosis constructs: effect of rod diameter and intervertebral cages on multisegmental construct stability. Spine J 2003;3(3):213–219

65. Bridwell K. Point of view. Spine 2002;27(19):2135–2136

66. Ouellet JA, Johnston CE II. Effect of grafting technique on the maintenance of coronal and sagittal correction in anterior treatment of scoliosis. Spine 2002;27(19):2129–2136

67. Smith JA, Deviren V, Berven S, Bradford DS. Does instrumented anterior scoliosis surgery lead to kyphosis, pseudarthrosis, or inadequate correction in adults? Spine 2002;27(5):529–534

68. Fricka KB, Mahar AT, Newton PO. Biomechanical analysis of anterior scoliosis instrumentation: differences between single and dual rod systems with and without interbody structural support. Spine 2002; 27(7):702–706

69. Oda I, Cunningham BW, Lee GA, Abumi K, Kaneda K, McAfee PC. Biomechanical properties of anterior thoracolumbar multisegmental fixation: an analysis of construct stiffness and screw-rod strain. Spine 2000; 25(18):2303–2311

70. Bullmann V, Halm HF, Niemeyer T, Hackenberg L, Liljenqvist U. Dual-rod correction and instrumentation of idiopathic scoliosis with the Halm-Zielke instrumentation. Spine 2003;28(12):1306–1313

71. Horton WC, Holt RT, Johnson JR, Leatherman KD. Zielke instrumentation in idiopathic scoliosis: late effects and minimizing complications. Spine 1988;13(10):1145–1149

72. McDonnell MF, Glassman SD, Dimar JR II, Puno RM, Johnson JR. Perioperative complications of anterior procedures on the spine. J Bone Joint Surg Am 1996;78:839–847

73. Kaneda K, Fujiya N, Satoh S. Results with Zielke instrumentation for idiopathic thoracolumbar and lumbar scoliosis. Clin Orthop Relat Res 1986;205:195–203

74. Wojcik AS, Webb JK, Burwell RG. An analysis of the effect of the Zielke operation on S-shaped curves in idiopathic scoliosis. A follow-up study revealing some skeletal and soft tissue factors involved in curve progression. Spine 1990;15(8):816–821

75. Trammell TR, Benedict F, Reed D. Anterior spine fusion using Zielke instrumentation for adult thoracolumbar and lumbar scoliosis. Spine 1991;16(3):307–316

76. Moskowitz A, Trommanhauser S. Surgical and clinical results of scoliosis surgery using Zielke instrumentation. Spine 1993;18(16):2444–2451

77. Sanders AE, Baumann R, Brown H, Johnston CE II, Lenke LG, Sink E. Selective anterior fusion of thoracolumbar/lumbar curves in adolescents: when can the associated thoracic curve be left unfused? Spine 2003; 28(7):706–714

78. Hsu LC, Zucherman J, Tang SC, Leong JC. Dwyer instrumentation in the treatment of adolescent idiopathic scoliosis. J Bone Joint Surg Br 1982; 64(5):536–541

Chapter 19

Scheuermann's Kyphosis

Suken A. Shah

♦ Kyphotic Deformities

Kyphotic deformities of the spine are defined as curves with abnormally increased posterior convex angulation. In distinction to scoliotic deformities, kyphotic deformities are more typically confined to one plane. Kyphotic deformities can occur in the cervical spine secondary to fracture (with subsequent loss of anterior vertebral body height), as part of postlaminectomy syndromes, or in a patient with ankylosing spondylitis. Causes of increased thoracic and thoracolumbar kyphosis are many and include changes associated with Scheuermann's disease, osteoporosis, post-traumatic kyphosis, postinfection kyphosis, tumor, ankylosing spondylitis, paralytic kyphosis, and others. Winter and Hall have classified more than fifteen major groups of kyphosis.[1] The most common causes of spinal kyphosis among the pediatric population are Scheuermann's disease, postural round back, and congenital kyphosis.

The fundamental principle in the analysis and treatment of kyphotic deformities is restoration or preservation of sagittal plane balance. Neutral sagittal balance is maintained when a line dropped perpendicular to the horizontal from C7 passes through the posterior aspect of the first sacral vertebra. Kyphotic deformities of the cervical, thoracic, or lumbar spine can result in anterior displacement (positive sagittal balance) of this plumb line with a consequent sensation of forward "tipping-over." The correction of kyphotic deformities demands rebalancing to restore the C7 plumb line to within 2 to 3 cm of neutral. Although the lumbar spine does not often fall into absolute kyphosis, a loss of lumbar lordosis causes a *relative* lumbar kyphosis with a subsequent loss of sagittal balance (as the thoracic spine is unable to compensate for the adjacent hypolordosis). Clinically significant sagittal deformities may result in debilitating pain, cosmetic disfigurement, spinal cord dysfunction, swallowing difficulties, gastrointestinal difficulties, pelvic organ prolapse, and cardiopulmonary compromise.

This chapter will address the etiology, evaluation, and treatment of the most commonly encountered kyphotic deformity among children and young adults: Scheuermann's kyphosis.

Normal Sagittal Alignment

Balance of sagittal contour depends on the sagittal vertical axis. This axis falls from the atlanto-occipital articulation through the cervical vertebral bodies and anterior to the thoracic spine. The axis crosses the thoracolumbar junction, travels posterior to the lumbar spine, passes through S1 and then posterior to the second sacral vertebra **(Fig. 19–1)**. Thus, normal thoracic kyphosis combined with cervical and lumbar lordosis maintains the head in a centered, balanced position over the sacrum in the sagittal plane.[2] Clinically, if a patient's standing sagittal balance is neutral, a virtual line drawn vertically should pass from the ear, through the shoulder, greater trochanter, and knee. An increase in thoracic kyphosis in children is easily compensated by residual flexibility demonstrated by the cervical and lumbar spine. In an adult, loss of sagittal balance is often of greater significance secondary to the decreased compensatory flexibility in the mature cervical and lumbar spine, which can result in pain due to compensatory attempts at increasing lordosis.

Anatomy

The normal adult spine has four balanced sagittal plane curves. Thoracic and sacral curves are kyphotic and rigid. These curves are considered primary, as the kyphosis is present at birth. The usual kyphotic curve of the thoracic spine extends approximately from T2 to T12. The cervical and lumbar spines are lordotic, and both are considered secondary or compensatory in nature.

At birth, the spine is kyphotic throughout its entirety from occiput to coccyx **(Fig. 19–2)**. As an infant gains head control and begins to crawl, the cervical kyphosis reverses into

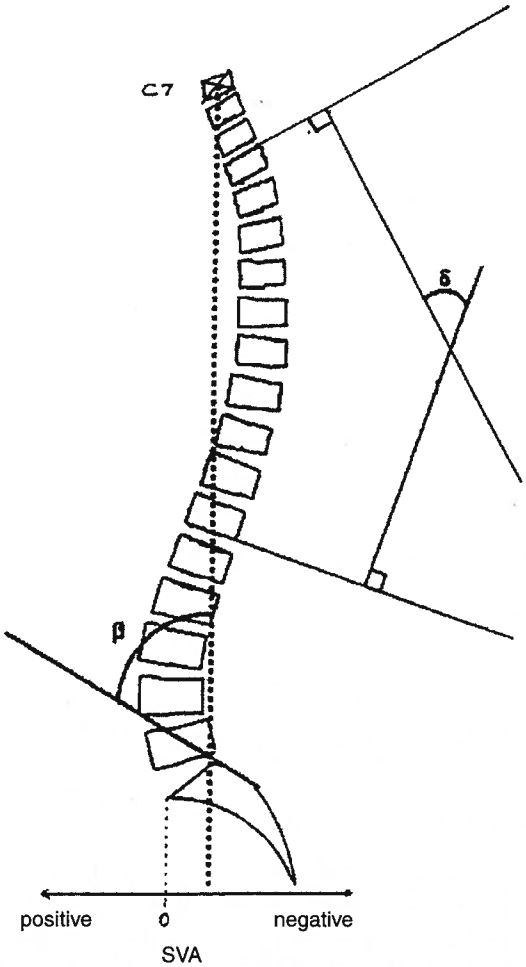

Figure 19–1 Method of measuring various parameters of sagittal spinal alignment. The sagittal vertical axis (SVA) is positive in kyphotic deformities because the C7 plumb line lies anterior to the sacrum. α = the Cobb angle between two vertebrae. β = the angle of sacral inclination. From: Gelb DE, Lenke LG, Bridwell KH, et al. An analysis of sagittal spinal alignment in 100 asymptomatic middle and older aged volunteers. Spine 1995;20:1352. Reprinted by permission.

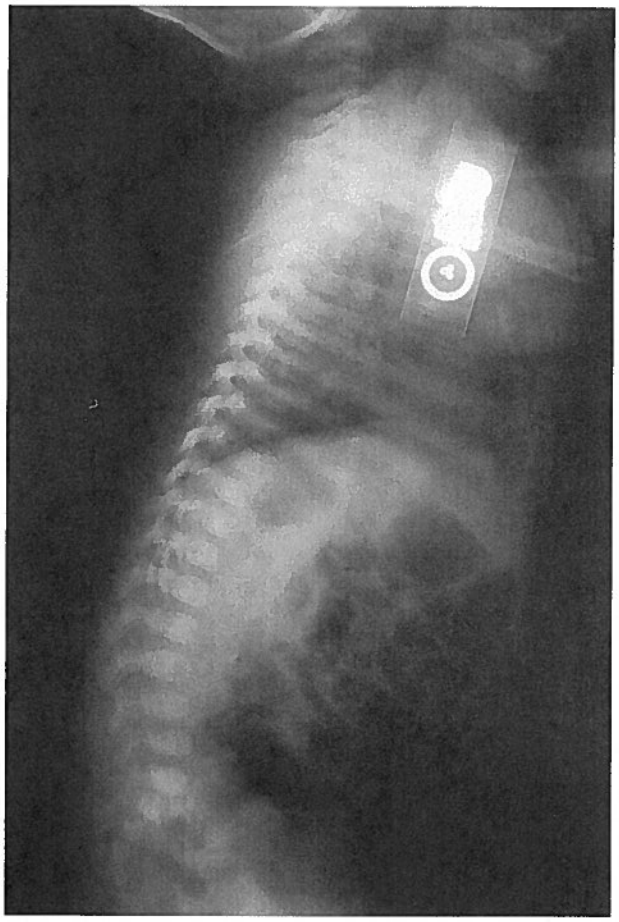

Figure 19–2 Lateral radiograph of a 2-month-old male infant illustrating the global kyphosis of the spine at birth from occiput to coccyx.

anatomic lordosis. As a child begins to ambulate, the lumbar spine develops a more lordotic contour. These compensatory changes balance the structural thoracic kyphosis to maintain normal sagittal balance. This adult configuration of a column with four alternating curvatures is more tolerant of axial load than a straight perpendicular column.

Thoracic kyphosis is manifested by the combined effects of the wedge-shaped thoracic vertebral bodies and the wedge-shaped thoracic intervertebral disks. The Scoliosis Research Society (SRS) has accepted the normal range of thoracic kyphosis in the adolescent to be 20 to 40 degrees, and that any degree of kyphosis at the thoracolumbar or lumbar area should be considered abnormal.[3] Fon et al. noted the upper limit of kyphosis to be 45 degrees in 316 healthy subjects aged 2 to 27 years, and that the average thoracic kyphosis increases with age, from 20 degrees in childhood, to 25 degrees in adolescents, to 40 degrees in adults.[4]

The relative rigidity of the thoracic spine permits less flexion, extension, and lateral bending; this is due, in part, to the additional constraint of the costovertebral articulations with the rib cage. Axial rotation is greater in the thoracic spine than lumbar spine, as facilitated by the coronal orientation of the thoracic facets. These facets transition from T10 to T12 to the more sagittal orientation characteristic of the lumbar spine.

Pathomechanics of Kyphotic Spinal Deformities

The posterior elements of the spine primarily resist tension, and the anterior elements are best adapted to resist compression. Factors that may subsequently contribute to development of a kyphotic deformity include either disruption of the posterior tether (e.g., multilevel laminectomies and facetectomies) or loss of the anterior buttress (e.g., osteoporotic fracture, infection, trauma, or tumor). Kyphosis is the result of a relative lengthening of the posterior column and/or a shortening of the anterior column. Once a kyphotic deformity develops, the patient's center of gravity is displaced anteriorly (**Fig. 19–3**). This results in an increased bending moment acting across the apex of the kyphotic deformity (initiating a cycle of increasing progression until physiologic balance is restored).[5] The more angulation at any given point, the greater the susceptibility to additional angulation at a given load.[1,6] The development of kyphosis in the skeletally immature patient

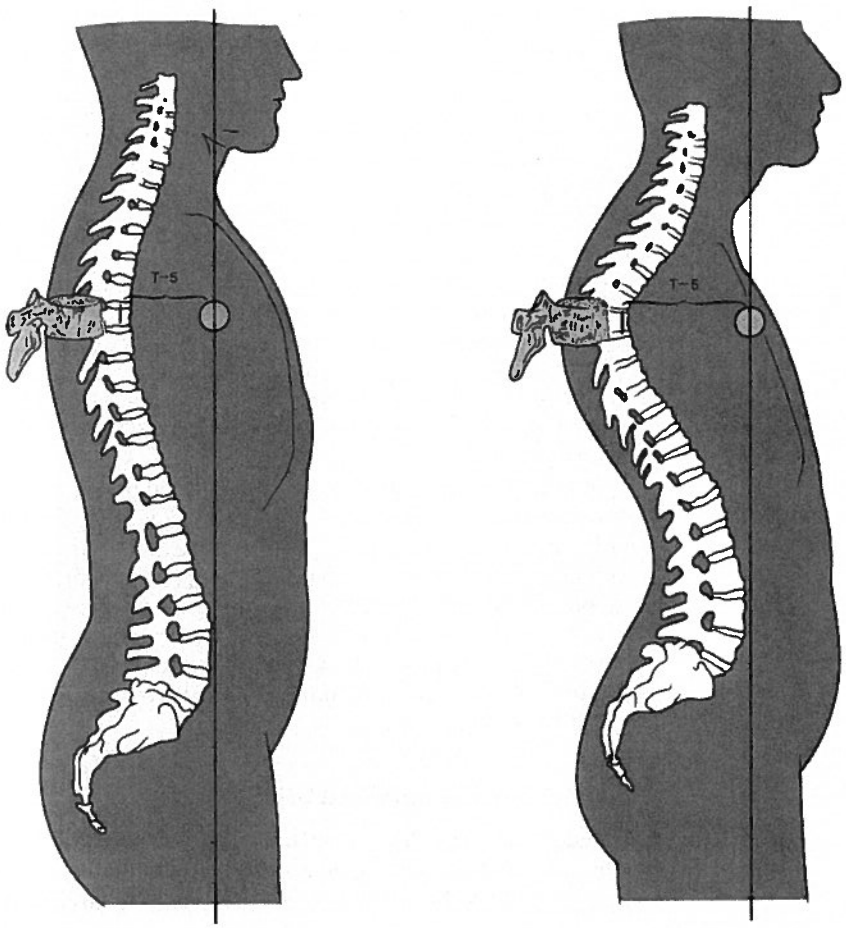

Figure 19–3 The line projected in this illustration is parallel to a plumb line drawn through the center of mass of the body. With increased kyphosis, the moment arm between the thoracic vertebral bodies and the center of gravity increases. As the moment arm increases, there is a greater tendency for progressive deformity. Notice the compensatory increase in lumbar lordosis and cervical lordosis, which causes the characteristic head thrust of kyphotic patients. From: An HS, Balderston RA. Juvenile kyphosis. In: Rothman RH, Simeone FA, eds. The Spine, 3rd Ed. Philadelphia: W.B. Saunders Company; 1992:493. Reprinted by permission.

can result in asymmetric growth as compression tends to inhibit physeal growth anteriorly, and tension forces act to accentuate growth posteriorly. Kyphosis may be associated with malformation of the anterior vertebral body as in the case of Type I congenital kyphosis.[7,8] If posterior column growth velocity exceeds that noted anteriorly, a kyphotic deformity will develop.[9,10] Iatrogenic disruption of the stabilizing structures posteriorly in the pediatric spine, for instance, after selective dorsal rhizotomy or tumor resection, can lead to rapid progression of a kyphotic deformity.[11,12] This may be similarly problematic in adult patients after multi-level cervical laminectomy.

The differentiation of a rigid from flexible kyphosis is important. A flexible kyphosis usually spans multiple segments and corrects to within the normal range with active extension, whereas a rigid kyphosis is typically shorter, sharper, and is fixed with active range of motion. Over time, most flexible kyphotic curvatures will become more rigid. This occurs as a combined result of thickening of the anterior longitudinal ligament, loss of disk height, increasing rigidity of the spinal articulations, and loss of viscoelasticity with aging.

Lonstein et al. have reported that patients with rigid kyphosis of the thoracic spine are at greater risk of developing neurologic impairment.[13] Most cases of neurologic deterioration and kyphosis are the direct result of tethering of the spinal cord over a severe kyphotic deformity.[13,14] Attempts to lengthen the kyphotic spinal column and the presence of anterior compression often aggravate the compressive effects on the cord, increase the neurologic risk, and should be avoided. In addition, small disk protrusions in the thoracic spine will act to further injure the already compromised cord leading to more severe spinal cord compression and neurologic injury. Computed tomography (CT) combined with myelography and magnetic resonance imaging (MRI) are useful diagnostic modalities in evaluating neurologic impairment in the setting of spinal kyphotic deformity.

♦ Scheuermann's Kyphosis

In 1921, Scheuermann described a rigid spinal kyphosis affecting the thoracic or thoracolumbar spine that he distinguished from the more correctable postural hunchback.[15–17] Sorensen characterized this disease radiographically by the presence of anterior wedging (of five degrees or more) of at least three adjacent vertebrae, end plate irregularity, and the presence of Schmorl's nodes **(Fig. 19–4)**.[18,19] Bradford et al. classified a variant of this process as vertebral body changes without wedging and increased kyphosis.[3] Despite these descriptions, making these distinctions can be difficult, and the differentiation of abnormal kyphosis and "pathognomonic" signs of Scheuermann's disease remain controversial.[20]

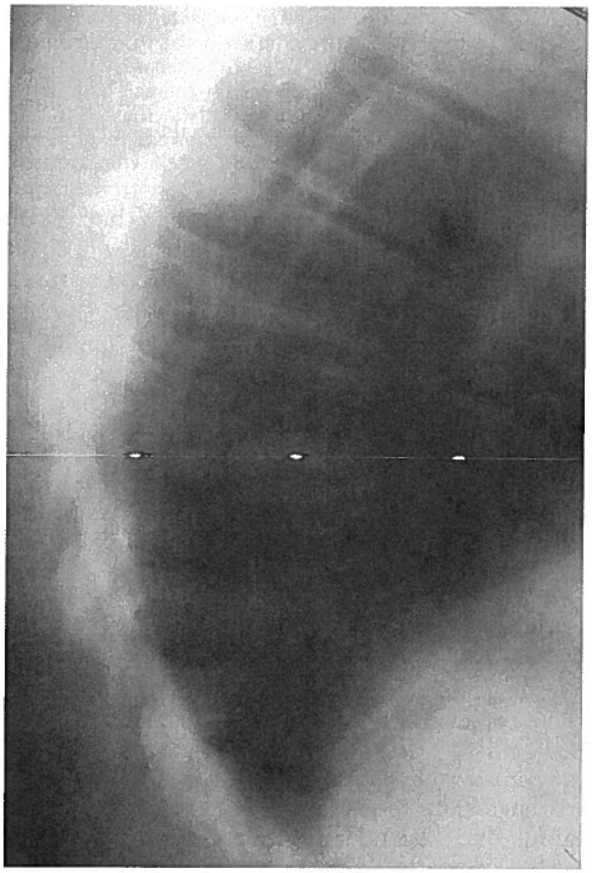

Figure 19–4 This lateral radiograph of an adolescent male demonstrates the typical features of Scheuermann's kyphosis: anterior vertebral body wedging of three consecutive vertebrae, end plate irregularity, disk space narrowing, and Schmorl's nodes.

Scheuermann's kyphosis has a reported incidence of 0.4 to 8.3% in the general population with a ratio favoring males to females, though many authors have stated that it occurs with an equal incidence in males and females.[21–24] It is the most frequent cause of hyperkyphosis of the thoracic and thoracolumbar spine during adolescence.

Scheuermann's kyphosis is rarely very painful unless a severe deformity is present.[25–27] If recognized early, patients with Scheuermann's kyphosis can often be successfully treated with nonoperative intervention, such as bracing[28,29] or exercises.

Etiology and Pathogenesis

The specific etiology of Scheuermann's kyphosis remains unclear.[30–32] Scheuermann's initial description included that the condition results from avascular necrosis of the vertebral ring apophyses, which leads to a premature growth arrest with resultant wedging of the anterior portion of the vertebral bodies, and mentioned that it resembled Legg-Calvé-Perthes disease of the hip.[15–17] Schmorl believed that there was inherent weakening of the cartilaginous end plate, which lead to herniation of disk material into the vertebral body.[18] This was thought to occur during the endochondral ossification process leading to subsequent kyphotic deformity. This theory, however, was weakened by the identification of Schmorl's nodes in vertebrae outside the kyphotic area and in patients without spinal deformity.[22,23]

Various mechanical theories have been put forth that implicate the anterior longitudinal ligament and anterior column pressure changes with the spinal deformity developing as dictated by Wolff's law.[33,34] Juvenile osteoporosis may also play a role in progressive kyphosis.[35–37] Still others have demonstrated abnormal cartilage matrix and decreased expression of various glycoproteins in the affected end plates.[38] What is still unclear in the mechanical theory is whether the end-plate changes seen histologically predispose the vertebrae to kyphosis or are secondary.[7] Scheuermann's disease has been associated with endocrine abnormalities, inflammatory diseases, and neuromuscular disorders.[5,21,39,40] The etiology may lie in genetic factors.

Genetic theories have varied from familial predilection to autosomal dominant inheritance patterns[41] with high degrees of penetrance but variable expression.[30] There have been three case reports of classic Scheuermann's disease in monozygotic male twins, which supports the genetic theory.[42,43] Other investigators, such as Ascani[22] and Skogland,[31] have noted a mean height in affected patients 2.5 standard deviations above normal subjects and increased levels of growth hormone.

Clinical Findings and Natural History

Scheuermann's kyphosis is usually detected at puberty. It is commonly ignored or dismissed by parents or teachers as poor posture, which often leads to a delay in diagnosis. It is rare in patients younger than age 10 years, with the typical presentation in the late juvenile period, and the more severe form commonly appearing between the ages of 12 and 16 years.[20] The primary distinguishing feature between postural kyphosis and Scheuermann's kyphosis is the rigidity of the Scheuermann curvature. Trunk extension will produce deformity correction in those with postural kyphosis, whereas minimal to no such correction will be achieved in the patient with Scheuermann's disease. In addition, patients with Scheuermann's disease may be further affected by contracture of their pectoral muscles, hip flexors, and hamstrings.

The patient with Scheuermann's disease typically has a very well demarcated angular thoracic or thoracolumbar kyphosis, accentuated by forward bending, as well as a compensatory hyperlordosis of the cervical and lumbar spine. The compensatory changes produce the characteristic head and neck thrust typically associated with Scheuermann's kyphosis. Loder reported that the flexible cervical and lumbar spine is linked by the intermediate rigid thoracic segment, and as the thoracic spine becomes more kyphotic, lordosis of the cervical spine increases as a patient struggles to maintain a forward visual gaze.[44]

Clinical manifestations of severe disease include pain, physical disability, decreased range of motion and back strength, restrictive lung disease, hamstring tightness, scoliosis, spondylolisthesis, disk degeneration, and decreased participation in athletic activities or labor-type occupations.[3,22,24,32,45–51] Adolescents with Scheuermann's kyphosis primarily have self-image or postural concerns but will often report neck pain, back pain, and fatigue; pain is more commonly

the chief complaint of adults. The typical pain is above or below the apex of the deformity, in the paraspinal area, and may be activity related. Adult patients may also have lumbar pain, which is related to their compensatory hyperlordosis, subsequent disk degeneration, and facet arthrosis. If an adult's deformity is less than 60 degrees, a patient with Scheuermann's kyphosis may be expected to have little chance of significant back discomfort beyond that noted in the general population.[33] A long-term study by Murray et al. of adult Scheuermann patients with mean 32-year follow-up and age-matched controls showed that although they had more intense back pain, decreased trunk motion and strength, and tended to have less physically demanding occupations, there were no significant differences for days missed from work, self-esteem, social limitations, use of medications, or preoccupation with their physical appearance.[24] However, in a subsequent article by Lowe and Kasten,[52] adults with severe kyphotic deformities (>75 degrees) had severe thoracic pain secondary to degenerative spondylolysis and can have significant limitations, and the authors allude to magnitude of deformity as a cause of pain that alters lifestyle, although this relationship lacks Level I scientific evidence.

Neurologic symptoms are rare in adolescents with Scheuermann's disease. Paraparesis has been reported in rare cases with associated herniated thoracic disks, spinal stenosis, dural cysts, or extremely severe kyphotic deformity with tenting of the spinal cord over the apex of the deformity.[14,27,53,54] One report studying patients with Scheuermann's kyphosis noted that disk herniation resulted in neurologic symptoms in only 1% of the patients studied.[45] One theory proposes that vascular compromise of the artery of Adamkiewicz may be responsible for the onset of acute paraparesis in affected patients.[33] Selective spinal arteriography or magnetic resonance angiography is suggested as a useful diagnostic adjunct in these cases. Vertebral compression fracture may also precipitate acute paraparesis in these patients.[55] In summary, patients with Scheuermann's kyphosis may be neurologically intact, though with little reserve, leaving them vulnerable to acute neurologic deterioration from typically benign lesions or iatrogenic disruption of spinal cord blood flow.[56]

Radiographic Findings

The normal range of thoracic kyphosis is generally considered to be between 20 and 40 degrees using the Cobb method on the erect lateral radiograph.[3,57] Scheuermann's disease is best identified from evaluation of a standing lateral long-cassette (36 in.) roentgenogram displaying narrowed intervertebral disk spaces, end-plate irregularities, and Schmorl's nodes.[47] The radiographic criteria for diagnosis, set forth by Sorensen, includes the presence of greater than 5 degrees of anterior wedging of at least three adjacent vertebrae at the apex of the kyphotic deformity **(Fig. 19–4)**.[19] A radiograph obtained with the patient hyperextended over a bolster will demonstrate the degree of stiffness of the kyphotic curve. We routinely obtain standing full-length lateral and posterior/anterior (PA) radiographs of the entire spine as well as passive hyperextension views of the thoracic spine at the initial evaluation of patients suspected of having Scheuermann's disease. If neurologic findings are present after a careful physical exam, or are mentioned in the history, additional evaluation with MRI is indicated. MRI scans of involved patients will also demonstrate the end-plate irregularities, disk herniations into the vertebral bodies, Schmorl's nodes, and vertebral body wedging. MRI may be useful for detecting myelopathy or cord compression or for evaluation of subtle bony bridging that may influence treatment approach. Bone scans will usually be negative in the area of involvement, and so when a bone scan is positive in a patient with presumed Scheuermann's kyphosis, other causes should be investigated.[58]

Differential Diagnosis

Conditions in the differential diagnosis of adolescent kyphosis and/or back pain deserve mention at this point. Postural kyphosis or familial round-back deformity is a flexible kyphosis that does not display the sharp, angulated, rigid deformity that is characteristic of Scheuermann's disease. With forward bending, the patient will display a gradual, harmonious kyphosis in the sagittal plane that is easily correctable with erect positioning or prone lying. Radiographs do not demonstrate anterior vertebral wedging or end-plate irregularities. Although the patient may have mild back pain, the natural history of postural kyphosis is benign, and nonsteroidal anti-inflammatory drugs (NSAIDs) and physical therapy with postural training, hamstring stretching, and back extensor strengthening form the basis of treatment.

A subgroup of Scheuermann's disease, Type II Scheuermann, lumbar Scheuermann, or "pseudo-Scheuermann," has predominant deformity in the thoracolumbar or lumbar spine and is commonly seen in active adolescent males or those involved with heavy lifting.[20] The patients present with localized back pain, without much clinical kyphosis or cosmetic deformity until the deformity is severe. Their radiographs will demonstrate vertebral end-plate irregularities and Schmorl's nodes at the thoracolumbar junction and below, with a loss of lumbar lordosis **(Figs. 19–5A and 19–5B)**, and on occasion, the bony changes may be so severe that lumbar Scheuermann's disease can be confused with infection, tumor, or other conditions.[20] Wood and others cautioned that some of these changes can be seen on MRI scans of asymptomatic individuals, so clinical correlation is necessary.[59] The etiology is unknown, but epidemiology favors a mechanical cause, and although similar in radiographic appearance, lumbar Scheuermann's disease may be a different entity than Scheuermann's thoracic kyphosis. Lumbar Scheuermann's disease seems to be nonprogressive and usually resolves with NSAIDs, activity modification, and time.[20] Salminen and others articulated concerns that adolescents with Scheuermann-type changes in the lumbar and thoracolumbar disks will have recurrent low-back pain as young adults and the long-term persistence of low-back pain as adults. However, the authors point out that there was considerable inconsistency over time in the end-plate status of individual disk spaces. Therefore, the significance of these observations can be questioned.[60]

The presence of congenital kyphosis must be ruled out in the child or adolescent with clinically apparent kyphosis. If an anterior bar is seen on a lateral radiograph or even discovered later as an incidental finding on MRI scan, this is consistent with congenital kyphosis.

A B

Figure 19–5 **(A)** A lateral radiograph and **(B)** sagittal MRI scan of an adolescent male with lumbar Scheuermann's disease illustrating the characteristic loss of lumbar lordosis, pseudo disk degeneration, end-plate irregularities, and Schmorl's nodes. There is no significant vertebral body wedging associated with this condition.

♦ Nonoperative Treatment

The natural history of Scheuermann's kyphosis is poorly understood. The treatment is based on the severity and progression of the deformity, the presence of pain, neurologic compromise, and the age and general health of the patient. In the skeletally immature patient with Scheuermann's kyphosis, brace treatment has a reasonable success rate in preventing progression. Brace studies have demonstrated efficacy with the Milwaukee brace and an underarm thoracolumbosacral orthosis (TLSO).[28,29] Relative indications for surgical management are progressive kyphosis despite brace compliance, intractable pain, related neurologic deficit or persistent, significant deformity in a skeletally mature patient.[61]

Bracing is the mainstay of initial treatment of Scheuermann's kyphosis, and immature patients will typically respond well to this intervention. Specific criteria for bracing include those patients with at least 40% passive correction of curves measuring between 50 and 75 degrees. Patients with greater than 75 degrees of curvature will respond less favorably to bracing, and surgical intervention should be considered for these patients.[29,62]

The Milwaukee brace is a three-point dynamic orthosis that promotes extension of the thoracic spine. A pelvic girdle stabilizes the lumbar spine and reduces the lumbar hyperlordosis that is typically present in those with Scheuermann's disease. Posteriorly positioned pads are used to apply corrective pressure across the apex of the thoracic deformity, and an occipital chain ring maintains alignment of the cervicothoracic spine. Thoracolumbosacral braces without the neck ring of the Milwaukee brace function by adding padding anteriorly to apply a force to the sternum posteriorly, along one of three vectors correcting thoracic kyphosis.[29]

The bracing regimen usually includes an initial period of full-time brace wear (23 hours/day). This is continued for 12 to18 months or until reversal of vertebral wedging is noted. As the patient matures and the curve corrects, with anterior vertebral body growth, part-time bracing may be initiated and continued until the patient nears skeletal maturity.[63,64] The psychosocial effects of this type of brace regimen on an adolescent must be considered both before and during treatment. The successful use of the Milwaukee brace for the treatment of Scheuermann's kyphosis is well documented,[28,64,65] although there is some predictable loss of correction after bracing is discontinued.

A rigorous schedule of exercise emphasizing thoracic extensor strengthening and endurance is often helpful in association with bracing. Adults with Scheuermann's disease and back pain may also benefit from a directed spinal extensor strengthening program and aerobic exercise. An exercise program has been shown to be of benefit in Scheuermann patients, with control of kyphosis, decrease of pain, and increase in range of motion.[66] The incidence of tight hamstrings varies from 30 to 85%, which motivates physical therapists to encourage hamstring stretching to achieve better posture, lumbar-pelvic range

of motion, and perhaps avoid postsurgical imbalance and sagittal malalignment.[67]

♦ Surgical Treatment

The majority of patients with Scheuermann's kyphosis are successfully treated nonoperatively, but surgical treatment may be indicated in patients with deformity greater than 75 degrees, pain unresponsive to conservative interventions, or neurologic deficit.[20,48,49,68,69] Surgery is not indicated in immature patients with kyphosis less than 75 degrees unless they have failed a previous trial of bracing.[48,51,68] Soo and colleagues reported on long-term follow-up of patients with Scheuermann's kyphosis in a retrospective study of 63 patients followed for a mean of 14 years.[70] Three different treatment modalities were evaluated: exercise and observation, bracing, and surgery using Harrington compression instrumentation. There were no differences in marital status, general health, educational level, work status, degree of pain, or functional capacity between treatment modality and degree of kyphosis. Patients treated by surgery or bracing did have improved self-image, which they attributed to their treatment, whereas patients with kyphosis greater than 70 degrees at the time of follow-up had an inferior functional result. Their conclusion was that despite different treatment protocols, patients with Scheuermann's kyphosis can achieve similar functional results, provided that the proper treatment is selected based on the patient's age, deformity, and severity of back pain. This retrospective study is obviously plagued by selection bias but nonetheless provided valuable insight into the long-term outcome of treatment.

First-generation instrumentation techniques consisted of Harrington compression instrumentation or hook-rod systems such as Cotrel-Dubousset (CD). A posterior-only operation with fusion and compression instrumentation typically results in 50% correction of a flexible kyphosis.[9,49,51,61,71–73] Relief of back pain and spontaneous correction of lumbar hyperlordsis were noted, but complications included instrumentation failure (hook pullout), proximal and distal junctional kyphosis, and loss of correction (4 to 12 degrees) over time. Authors typically recommend posterior-only surgery for immature patients and if the kyphosis decreased to 50 degrees or less on a hyperextension radiograph.[49,69]

The loss of correction after posterior-only surgery has been attributed to the fusion being performed on the tension side of the spine, inadequate strength and failure of instrumentation, lack of anterior column support, and inadequate initial correction of rigid, severe deformities.[34,68] As a result, the principles of kyphosis surgery for large, rigid curves and for those patients who are skeletally mature have been modified to include anterior column release to facilitate posterior correction or posterior column shortening via multiple osteotomies. An anterior release is accomplished by sectioning the anterior longitudinal ligament and complete diskectomies. The posterior annulus is an important barrier to correction as well. Anterior interbody fusion further facilitates curve correction and can serve to restore sagittal alignment across the thoracolumbar junction. Anterior and posterior surgery has generally resulted in excellent correction of deformity in multiple published series[48,52,68,69] from a mean preoperative kyphosis of 77 to 85 degrees decreasing to 32 to 47 degrees. Anterior release and arthrodesis typically includes five to eight interspaces centered about the apex of the kyphosis, and the segmental vessels are spared when possible. We have achieved excellent results with thoracoscopic anterior release and fusion, reducing the morbidity, pain, and recovery from an open thoracotomy **(Fig. 19–6)**. A thoracoscopic release can be performed in the lateral decubitus position with single-lung ventilation and a right-sided approach or with low tidal volume dual-lung ventilation in the prone position. The kyphotic spine lends itself to the latter procedure, and the prone-position thoracoscopic approach may save anesthetic time because a standard endotracheal tube can be used, and the patient does not need to be repositioned for the posterior fusion and instrumentation. Rib resected during open thoracotomy or harvested thoracoscopically provides a source of autograft bone. Structural grafting is only necessary for rigid angular kyphosis requiring vertebral body resection for spinal cord decompression, provided posterior instrumentation is planned. We prefer to use allograft fibula or prosthetic cages in this setting. If anterior strut grafting is used, posterior correction must be performed cautiously to minimize the risk of displacing the anterior graft, or simultaneously, allowing adjustment of graft height and position after posterior correction and stabilization. This is especially important across the thoracolumbar junction because any residual kyphosis is poorly tolerated in this area.

Posterior column shortening via compression instrumentation acts to complete kyphotic correction and stabilization, but multilevel posterior osteotomies (Smith-Petersen or, less

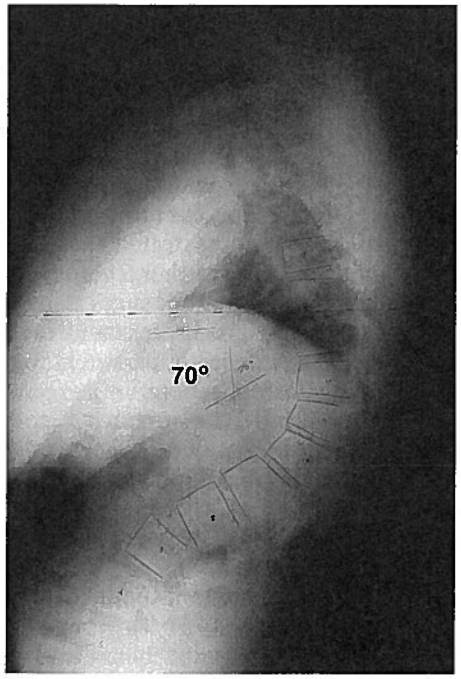

A

Figure 19–6 (A) An erect lateral radiograph of a 16-year-old male with Scheuermann's kyphosis involving the lower thoracic segments and thoracolumbar junction. This deformity was associated with significant back pain.

(Continued)

B

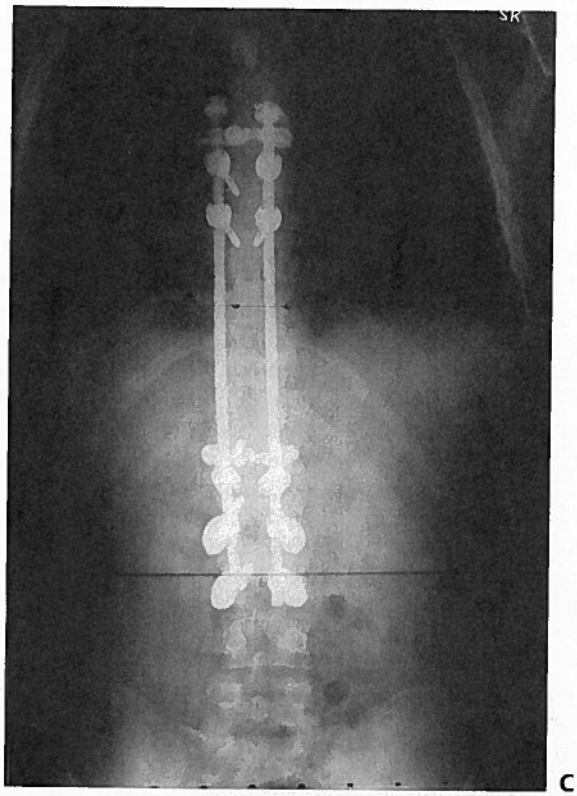

C

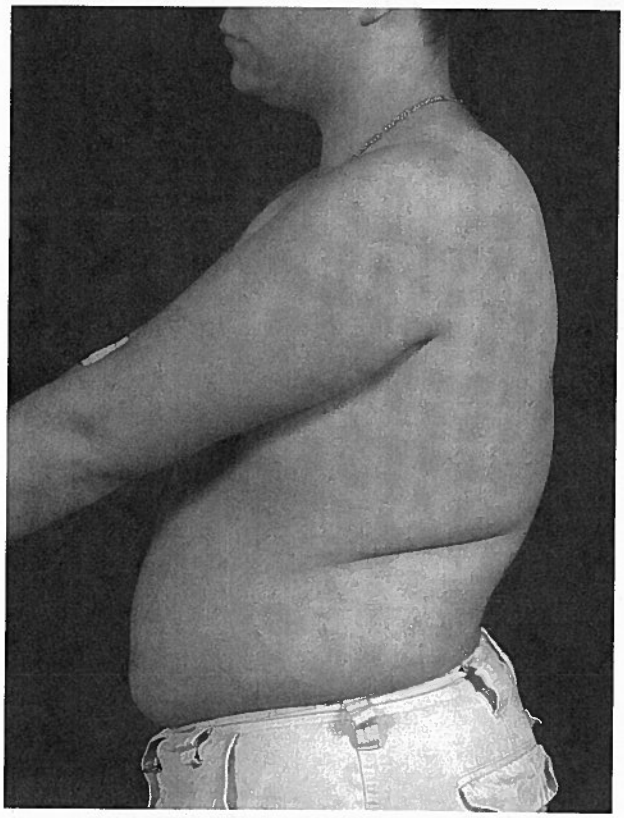

D

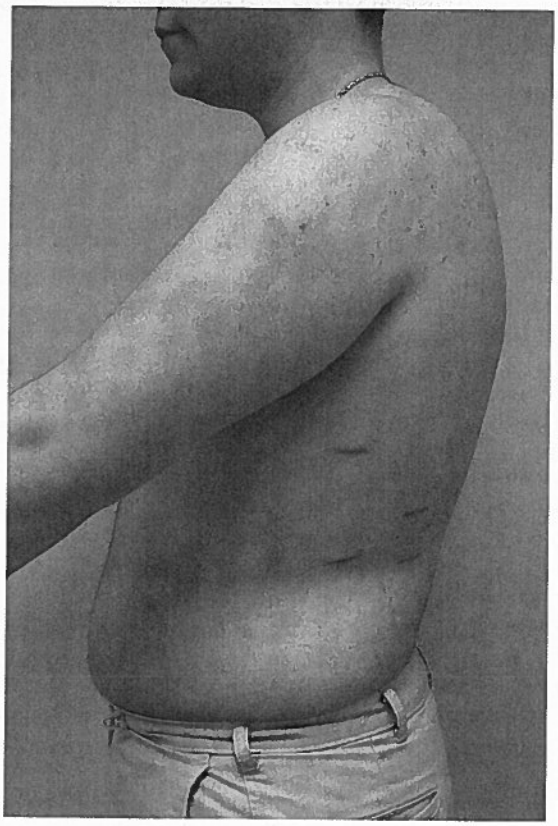

E

Figure 19–6 *(Continued)* **(B)** Postoperative lateral and **(C)** PA radiographs of the same patient after anterior thoracoscopic release, diskectomies, and fusion over the apical levels and posterior spinal fusion from T6 to L3 with segmental instrumentation. Clinical photographs of the patient's sagittal alignment **(D)** preoperatively and **(E)** postoperatively. This patient noted significant improvement in all domains of the Scoliosis Research Society (SRS) outcomes instrument postoperatively, especially self-image, function, and satisfaction.

Figure 19–7 Intraoperative photograph of the spine viewed posteriorly after multiple-level Smith-Petersen osteotomies (Ponte technique) to shorten the posterior column and subsequently correct kyphosis after compression instrumentation.

commonly, pedicle subtraction) can be used for correction of large deformities and may obviate the need for an anterior release. In the Smith-Petersen or Ponte technique,[73] the spinous processes and ligamentum flavum across the dorsal portion of the canal at each interspace are removed. Aggressive facetectomies are performed, and the facets are undercut to the lateral recess with a Kerrison rongeur. As a final step to increase the ability to shorten the posterior column and reduce kyphosis, the pars interarticularis is resected to the foramen, migrating cephalad, to create a chevron-type configuration (**Fig. 19–7**). This resection of bone can result in ~5 degrees of kyphosis correction per level when compressed posteriorly.

Posterior correction and stabilization can be accomplished using multiple available instrumentation systems, each implementing the principle of compression shortening of the posterior column to correct the kyphotic deformity (**Figs. 19–8A and 19–8B**). This is performed by securing multiple fixation points above and below the apex, followed by compressing and cantilevering an anatomic rod from the proximal to distal aspect. The proximal aspect of the instrumentation must extend to include the entire kyphosis and one neutral vertebra above the curvature, so that proximal "fall off" kyphosis does not occur above the

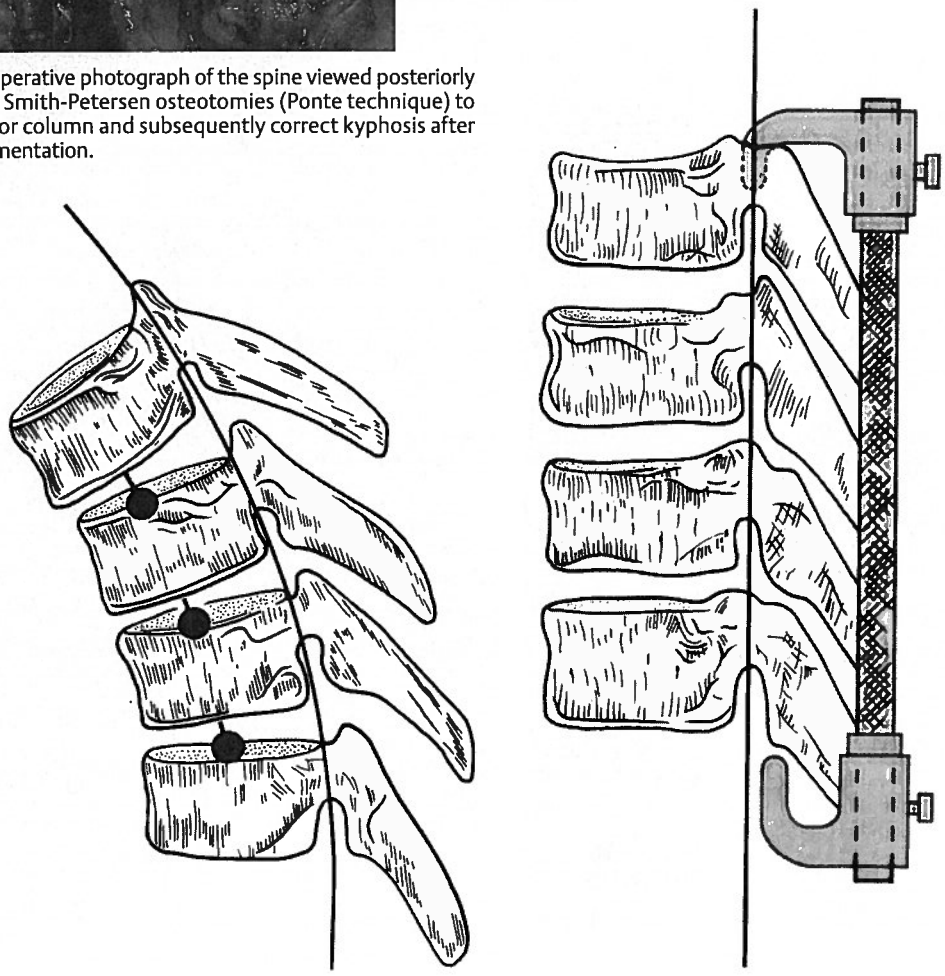

Figure 19–8 (A, B) Compression instrumentation is effective in reducing kyphotic deformity. Posterior instrumentation and Smith-Petersen osteotomies, if needed, shorten the posterior column of the spine and act close to the center of sagittal rotation to correct the deformity.

instrumented segments. Care should be taken to avoid excessive dissection above the highest instrumented vertebra, particularly the interspinous ligament and facet capsule. The lowest instrumented vertebra should be the level of the first lordotic disk, or at least one level below the measured Cobb angle vertebral end plate **(Figs. 19–6, 19–9, and 19–10)**.

Sturm et al.[74] stated that posterior correction forces are sufficient to rupture or attenuate the anterior longitudinal ligament, and if anterior bony bridging is not present, a single-stage posterior procedure is adequate. Hosman et al.[67] concluded that an anterior release was not necessary in most cases and that may actually lead to overcorrection. They stated that most adolescents with kyphotic curves of 70 to 100 degrees can be corrected to a physiologic range of 40 to 50 degrees with a posterior procedure alone.

The preferred method of posterior instrumentation includes placement of proximal fixation (either a multiple claw configuration using hooks or multilevel pedicle screw fixation) to which an anatomically contoured rod is secured. Compression across the apical convexity is combined with cantilever bending to bring the rod to the anchor points below the apex. Both hooks and pedicle screws are safe and efficacious as distal anchor points, but most surgeons prefer the mechanical advantage afforded by pedicle screw fixation to correct spinal deformity **(Figs. 19–9 and 19–10)**. We prefer at least six pedicle screws as distal anchor points to distribute the considerable cantilever forces on the construct after correction, especially in large male patients. The multilevel pedicle screws, when used distally, also allow segmental restoration of lumbar lordosis with compression, and polyaxial screws are particularly helpful in this application. Horton has recently reported on a method to reduce strain on the proximal and distal screw foundations seen in cantilever loading by using temporary apical cantilever rods and then sequentially increasing the length of the correcting rod, alternating side to side.[75] The final, full-length rods are then secured when the kyphotic spine is almost fully corrected; segmental compression is then performed to fine-tune the correction. Overcorrection past physiologic kyphosis should be avoided, as this has been implicated in postoperative decompensation, instrumentation failure, and junctional complications.

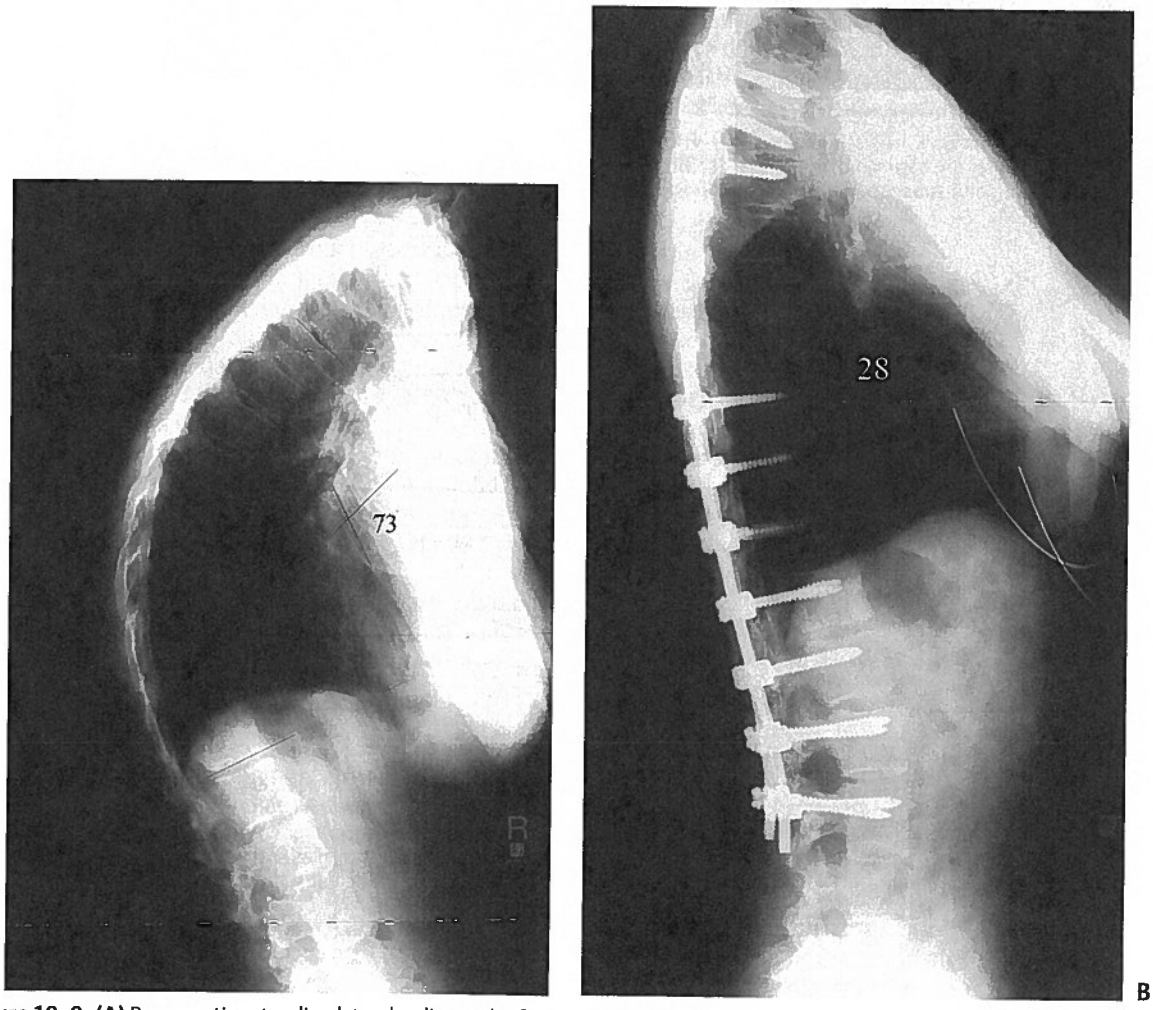

Figure 19–9 **(A)** Preoperative standing lateral radiograph of a 16-year-old female with a 73-degree thoracic kyphosis due to Scheuermann's disease. **(B)** Postoperative standing lateral radiograph 2 years after multiple-level Smith-Petersen osteotomies and posterior spinal fusion from T2 to L3 with posterior pedicular screw instrumentation. Her kyphosis was corrected to 28 degrees.

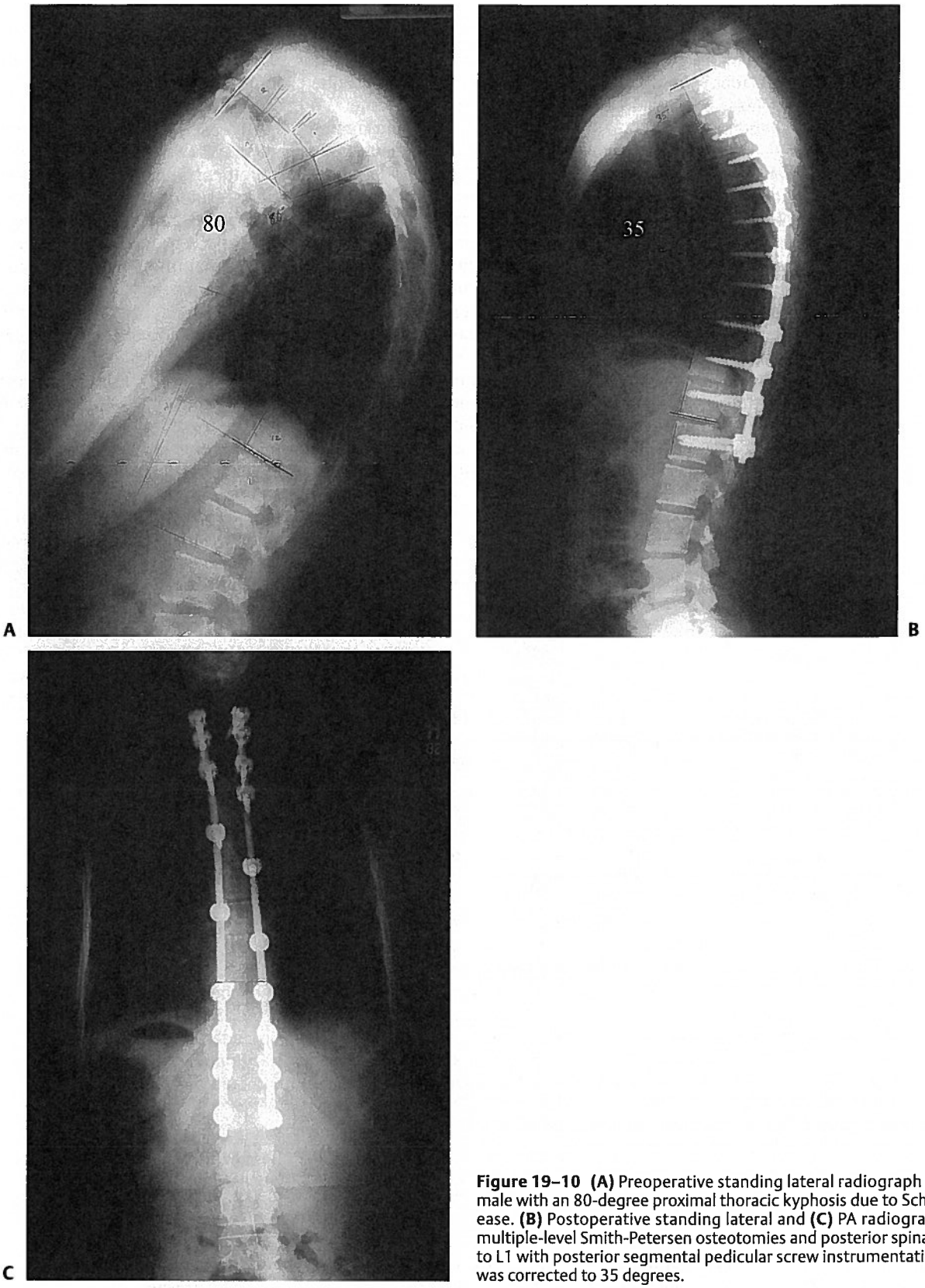

Figure 19–10 **(A)** Preoperative standing lateral radiograph of a 15-year-old male with an 80-degree proximal thoracic kyphosis due to Scheuermann's disease. **(B)** Postoperative standing lateral and **(C)** PA radiographs 1 year after multiple-level Smith-Petersen osteotomies and posterior spinal fusion from T2 to L1 with posterior segmental pedicular screw instrumentation. His kyphosis was corrected to 35 degrees.

Gaines and others have reported short-term results of the anterior-only treatment of Scheuermann's kyphosis, citing the advantages of a short segment fusion and superior control of the sagittal alignment.[76] The disks of the diseased levels are removed circumferentially back to the posterior longitudinal ligament, kyphosis is segmentally corrected with strut grafts, vertebral body screws are inserted, and the fusion is stabilized with dual-rod anterior instrumentation. Loss of correction and junctional kyphosis complications are virtually nonexistent, but longer follow-up is required.

Spinal cord monitoring (transcranial electric motor evoked potentials and somatosensory evoked potentials) is used in all cases to detect impending neurologic compromise. Acute or prolonged hypotension is to be avoided during kyphosis correction, as it may compromise spinal cord blood flow and induce spinal cord ischemia.[56] Meticulous facetectomies and decortication are performed to avoid pseudarthrosis. Postoperative bracing is seldom necessary in adolescents or adults with normal bone and satisfactory fixation. Should bracing be required in a given situation, a TLSO fabricated with a high sternum and low posterior profile is recommended, such as a Cash orthosis.

Results

Outcomes after surgery are generally good, provided certain principles are followed. Daentzer et al. studied 10 patients with severe kyphosis from Scheuermann's disease who underwent posterior spinal fusion with excellent pain relief and return to function, including sports and physical labor.[77]

Poolman et al.[78] authored a prospective study of 23 consecutive patients with a median kyphosis of 70 degrees treated with anterior and posterior arthrodesis and instrumentation with minimum 2-year follow-up. Postoperatively, kyphosis improved to 39 degrees, and lumbar lordosis was corrected to 49 degrees. This correction was maintained well at 2-year follow-up, but at final follow-up (mean 6 years), the median sagittal corrections deteriorated to a significant extent, to 55 degrees (range 36 to 65 degrees) of kyphosis and 57 degrees (range 44 to 70 degrees) of lumbar lordosis. The authors postulated that this was due primarily to removal of instrumentation and occurred despite documentation of solid fusions and recommended that instrumentation not be routinely removed. Using the SRS outcomes instrument, they showed patients had improved self-image and pain scores.

Lowe and Kasten[52] reported on preoperative and postoperative sagittal curves in patients with Scheuermann's kyphosis undergoing spinal fusion with CD instrumentation with specific attention to long-term correction, changes in sagittal balance, and junctional complications. Thirty-two patients with kyphosis preoperatively averaging 85 degrees were corrected to 43 degrees, with excellent maintenance of correction at long-term follow-up (average 4 degrees loss of correction). Lumbar lordosis was reduced spontaneously from 75 degrees to 55 degrees. Sagittal balance was negative in most patients and became slightly more negative postoperatively. Patients were satisfied with postoperative pain relief and deformity correction, as indicated by improved SRS outcomes scores. Proximal junctional kyphosis was associated with overcorrection (>50%) of the kyphosis or not fusing proximally to the measured vertebra of the Cobb kyphosis angle. Distal junctional kyphosis occurred in patients who were fused short of the first lordotic segment. This risk factor for distal junctional kyphosis was reported previously by Reinhardt and Bassett, who also described loss of correction at the distal junction in some patients.[79]

Lim and coauthors[80] retrospectively reviewed 23 consecutive patients with Scheuermann's kyphosis treated operatively with modern posterior multisegmental instrumentation and concluded that surgical treatment was safe and effective. Preoperative kyphosis averaged 83 degrees; 20 of the 23 underwent anterior release/fusion and posterior fusion with instrumentation, and the remaining 3 patients underwent posterior fusion with instrumentation. The typical construct was a proximal fusion to T2, T3, or T4, and hook fixation in a claw configuration with distal fusion to the level below the first lordotic disk (usually L2 or L3) and pedicle screw distal foundation with Isola Galveston or CD instrumentation. The postoperative kyphosis was reduced to 46 degrees, and at a mean follow-up of 38 months, the average kyphosis was 51 degrees, for a final average correction of 32 degrees. There were no pseudarthroses or neurological injuries as a result of treatment, and most patients reported relief of back pain. The minor complication rate was 43% (pleural effusions, superficial wound infections, etc.) and the major complication rate was 17% (those requiring prolonged or surgical treatment). Three patients required reoperation for loss of fixation, two had hook dislodgments, and one had caudal pedicle screw failure, which the authors postulate was an error of fusing one level short of the first lordotic disk. Three patients had proximal junctional kyphosis over 10 degrees; none had distal junctional kyphosis. When compared with earlier studies using Harrington instrumentation, this cohort fared well, and the authors attribute this to the advances in instrumentation and the increased awareness of complications.

Selection of fusion levels remains an important and challenging aspect of kyphosis surgery, and overcorrection should be avoided. Current segmental hook, screw, and rod instrumentation systems give the surgeon better ability to obtain and maintain intraoperative corrections and make overcorrection and shorter fusions more seductive. The lessons learned from the earlier literature must not be ignored; and long-term studies of our current techniques are needed before we consider modern techniques "better."

Other reported complications include death, postoperative neurological deficit, infection, intraoperative and postoperative instrumentation failure, pseudarthrosis, hardware prominence, superior mesenteric artery syndrome, intestinal obstruction, pleural effusion, pneumothorax, pulmonary embolus, and persistent back pain.[27,48,49,52,61,68,69,80]

♦ Conclusion

There are multiple causes of kyphotic spinal deformity. A careful, thorough history and physical examination and a complete radiographic analysis will usually delineate the etiology of the disorder. The most common causes of increased thoracic kyphosis include Scheuermann's kyphosis, postural round-back, post-traumatic kyphosis, and senile kyphosis.

Irrespective of the etiology, surgical intervention is indicated in those with intractable pain, progressive deformity, neurologic impairment, and inability to perform activities of daily living. The goals of operative treatment are the enhancement of function, alleviation of pain, improvement of physical appearance and self-esteem, and restoration of sagittal balance.

It is incumbent upon the treating physician to recognize that nearly all kyphotic deformities of the spine result from failure of the anterior column under compression and the posterior column under tension. Surgical management should emphasize elongation of the anterior column (but not distraction of the spinal cord) and compression shortening of the posterior column, all hinging around the posterior longitudinal ligament. Prevention of recurrence requires stabilization of the entirety of the kyphotic curve and meticulous fusion technique with rigid instrumentation. Despite recent advances in the understanding, diagnosis, and treatment of the various etiologies of kyphotic deformity, management of spinal kyphosis remains a clinical and technical challenge. Surgical treatment of kyphosis carries with it a high rate of complications, but with careful planning, attention to detail, and adherence to principles, patient satisfaction and outcome can be excellent.

References

1. Winter RB, Hall JE. Kyphosis in childhood and adolescence. Spine 1978;3: 285–308
2. Boseker EH, Moe JH, Winter RB, Koop SE. Determination of "normal" thoracic kyphosis: a roentgenographic study of 121 "normal" children. J Pediatr Orthop 2000;20:796–798
3. Bradford DS, Lonstein JE, Ogilvie JW, Winter RB. Scoliosis and Other Spinal Deformities, 2nd Ed. Philadelphia: WB Saunders; 1987
4. Fon GT, Pitt MJ, Thies AC Jr. Thoracic kyphosis: range in normal subjects. AJR Am J Roentgenol 1980;134:979–983
5. Lambrinudi C. Adolescent and senile kyphosis. BMJ 1934;2:800–804
6. White AA, Panjabi MM. The clinical biomechanics of kyphotic deformities. Clin Orthop Relat Res 1977;128:8–17
7. Winter RB. Congenital kyphosis. Clin Orthop Relat Res 1977;128:26–32
8. Winter RB, Moe JH, Lonstein JE. The surgical treatment of congenital kyphosis. Spine 1985;10:224–231
9. Heine J, Starch R, Matthiass HH. Ergbinesse der operativen behand-lung des morbus Scheuermann. Orthop Ihre Grenzgeb 1984;122(6):734–749
10. Yablon JS, Kesdon DL, Levine H. Thoracic cord compression in Scheuermann's disease. Spine 1988;13:896–898
11. Fager CA. Laminectomy and kyphotic deformity. J Neurosurg 2001;95: 157–158
12. Lonstein JE. Post-laminectomy kyphosis. Clin Orthop Relat Res 1977;128: 93–100
13. Lonstein JE, Winter RB, Moe JN, et al. Neurologic deficits secondary to spinal deformity: a review of the literature and report of 43 cases. Spine 1980;5:331–355
14. Bradford DS, Garcia A. Neurological complications in Scheuermann's disease. J Bone Joint Surg Am 1969;51:567–572
15. Scheuermann HW. Kyphosis douselis juveniles. Orthop Chir 1921; 41:305
16. Scheuermann HW. Kyphosis douselis juveniles. Ugeskr Leager 1920; 82:385
17. Scheuermann HW. Kyphosis juveniles (Scheuermann's kaukheit). Clin Orthop Relat Res 1977 Oct;128:5–7
18. Schmorl G, Junghans H. Die Gesunde und Kranle Wirbel-sqeule in Roentgenbild. Leipzig: Thieme Verlag; 1932
19. Sorensen KH. Scheuermann's Juvenile Kyphosis: Clincal Appearances, Radiography, Aetiology, and Prognosis. Copenhagen: Enjar Munksgaard Forlag; 1964:214–222
20. Wenger DR, Frick SL. Scheuermann kyphosis. Spine 1999;24:2630–2639
21. Ascani E, Borelli P, Larosa G, Montanaro A, Tuturro F. Malattia di Scheuermann. I Studio Ormonale. Progresi in Petologia vertebrale. Le Cifosi Bologna: A. Gaggi; 1982.
22. Ascani E, Montanaro A. Scheuermann's disease. In: Bradford DS, Hensinger RN, eds. The Pediatric Spine. New York: Thieme Medical Publishers; 1985
23. Ascani E, Salsano V, Giglio GC. The incidence and early detection of spinal deformities. Ital J Orthop Traumatol 1977;3:111–117
24. Murray PM, Weinstein SL, Spratt KF. The natural history and long-term follow-up of Scheuermann's kyphosis. J Bone Joint Surg Am 1993;75: 236–248
25. Clark CE, Shufflebarger HL. Cotrel-Dubosset instrumentation for Scheuermann's kyphosis. Paper presented at: Annual Meeting of the American Academy of Orthopaedic Surgeons; 1994; New Orleans, LA
26. Ryan MD, Taylor TKF. Acute spinal cord compression in Scheuermann's disease. J Bone Joint Surg Br 1982;64:409–412
27. Tribus CB. Scheuermann's kyphosis in adolescents and adults: diagnosis and management. J Am Acad Orthop Surg 1998;6:36–43
28. Montgomery S, Erwin W. Scheuermann's kyphosis – long-term results of Milwaukee brace treatment. Spine 1981;6:5–12
29. Riddle EC, Shah SA, Bowen JR, Moran E, Lawall HJ. The duPont kyphosis brace for the treatment of adolescent Scheuermann kyphosis. J South Orthop Assoc 2003;12:135–140
30. Halal F, Gledhill RB, Fraser FC. Dominant inheritance of Scheuermann's juvenile kyphosis. Am J Dis Child 1978;132:1105–1107
31. Skogland LB, Steen H, Trygstad O. Spinal deformities in tall girls. Acta Orthop Scand 1985;56:155–157
32. Stoddard A, Osborn JF. Scheuermann's disease or spinal osteochondrosis: its frequency and relationship with spondylosis. J Bone Joint Surg Br 1979;61:56–58
33. Lesoin F, Rosseaux M, Viaud C, et al. Syndrome radicul-medullaire au cours de la maladie de Scheuermann. Rev Rhum Mal Osteoartic 1985;52:57–60
34. Lowe TG. Scheuermann disease. J Bone Joint Surg Am 1990;72:940–945
35. Bradford DS, Brown DM, Moe JH, et al. Scheuermann's kyphosis: a form of osteoporosis. Clin Orthop Relat Res 1976;118:10–17
36. Jones ET, Hensinger RN. Spinal deformity in idiopathic juvenile osteoporosis. Spine 1981;6:1–8
37. Kanis JA. Treatment of osteoporotic fractures. Lancet 1984;1:27–33
38. Ippolito E, Ponseti IV. Juvenile kyphosis: histological and histochemical studies. J Bone Joint Surg Am 1981;63:175-182
39. Muller G, Gshneud N. Endocrine storungen und morbus Scheuermann. Arch Orthop Unfallchir 1969;65:357–362
40. Nathan L, Kuhas JG. Epiphysitis of the spine. J Bone Joint Surg Am 1940; 22:55–62
41. McKenzie L, Sillence D. Familial Scheuermann disease: a genetic linkage study. J Med Genet 1992;29:41–45
42. Carr AJ. Idiopathic thoracic kyphosis in identical twins. J Bone Joint Surg Br 1990;72:144
43. Graat HCA, van Rhijn LW, Schrander-Stumpel CT, van OOij A. Classical Scheuermann disease in male monozygotic twins. Spine 2002;27: E485–E487

44. Loder RT. The sagittal profile of the cervical and lumbosacral spine in Scheuermann thoracic kyphosis. J Spinal Disord 2001;14:226–231

45. Bouchez B, Arnott G. Compression medullaire par hernie discale dorsale. Rev Neurol (Paris) 1986;142:154–158

46. Fisk JW, Baigent ML, Hill PD. Incidence of Scheuermann's disease: preliminary report. Am J Phys Med 1982;61:32–35

47. Fisk JW, Baigent ML, Hill PD. Scheuermann's disease: clinical and radiological series of seventeen and eighteen year-olds. Am J Phys Med 1984; 63:18–30

48. Herndon WA, Emans JB, Micheli LJ, Hall JE. Combined anterior and posterior fusion for Scheuermann's kyphosis. Spine 1981;6:125–130

49. Otsuka NY, Hall JE, Mah JY. Posterior fusion for Scheuermann's kyphosis. Clin Orthop Relat Res 1990;251:134–139

50. Paajanen H, Erkintalo M, Kuusela T, et al. Magnetic resonance study of disk degeneration in young low back pain patients. Spine 1989;14: 982–985

51. Taylor TC, Wenger DR, Stephen J, Gillespie R, Bobechko WP. Surgical management of thoracic kyphosis in adolescents. J Bone Joint Surg Am 1979;61:496–503

52. Lowe TG, Kasten MD. An analysis of sagittal curves and balance after Cotrel-Duboussett instrumentation for kyphosis secondary to Scheuermann's disease. Spine 1994;19:1680–1685

53. Klein DM, Weiss RL, Allen JE. Scheuermann's dorsal kyphosis and spinal cord compression: case report. Neurosurgery 1986;18:628–631

54. Lesoin F, Leys D, Rousseaux M. Thoracic disk herniation and Scheuermann's disease. Eur Neurol 1987;26:145–152

55. Bohlman HH. Late progressive pain following fractures of the thoracic lumbar spine. J Bone Joint Surg Am 1976;58:728

56. Othman Z, Lenke LG, Bolon SM, Padberg A. Hypotension-induced loss of intraoperative montoring data during surgical correction of Scheuermann kyphosis: a case report. Spine 2004;29:E258–E265

57. Cobb JR. Outline for the study of scoliosis. In: Edwards JW, ed. Instructional Course Lectures, 5th Ed. Ann Arbor, MI: American Academy of Orthopaedic Surgeons; 1948:261–275

58. Winter WA, Veraart BE, Verdegaal WP. Bone scintigraphy in patients with juvenile kyphosis. Diagn Imaging 1981;50:186–190

59. Wood KB, Garvey TA, Gundry C, Heithoff KB. Magnetic resonance imaging of the thoracic spine: evaluation of aymptomatic individuals. J Bone Joint Surg Am 1995;77:1631–1638

60. Salminen JJ, Erkintalo MO, Pentti J, et al. Recurrent low back pain and early disk degeneration in the young. Spine 1999;24:1316–1326

61. Bradford DS, Moe JN, Montalvo FJ. Scheuermann's kyphosis: results of surgical treatment by posterior spine arthrodesis in twenty-two patients. J Bone Joint Surg Am 1975;57:439–448

62. Sachs B, Bradford DS, Winter RB, et al. Scheuermann's kyphosis: follow-up of Milwaukee brace treatment. J Bone Joint Surg Am 1987;69:50–54

63. Donk R, Harms J, Hack HP, Zielke K. Correction and stabilization of angular kyphosis. Clin Orthop Relat Res 1990;258:56–61

64. Lonstein JE, Winter RB. The Milwaukee brace for the treatment of adolescent idiopathic scoliosis: a review of one thousand and twenty patients. J Bone Joint Surg Am 1994;76:1207–1221

65. De Smedt A, Fabry G, Mulier JC. Milwaukee brace treatment of Scheuermann's kyphosis. Acta Orthop Belg 1975;41:597-605

66. Somhegyi A, Ratko I, Gomor B. [Effect of spinal exercise on spinal parameters in Scheuermann disease (Hungarian).] Orv Hetil 1993;134:401–403

67. Hosman AJ, Langeloo DD, de Kleuver M, et al. Analysis of the sagittal plane after surgical management for Scheuermann disease: a view on overcorrection and the use of an anterior release. Spine 2002;27: 167–175

68. Bradford DS, Ahmed KB, Moe JH, Winter RB, Lonstein JE. The surgical management of patients with Scheuermann's disease: a review of twenty-four cases by combined anterior and posterior spine fusions. J Bone Joint Surg Am 1980;62:705–712

69. Speck GR, Chopin DC. The surgical treatment of Scheuermann's kyphosis. J Bone Joint Surg Br 1986;68:189–193

70. Soo CL, Noble PC, Esses SI. Scheuermann kyphosis: long term follow up. Spine J 2002;2:49–56

71. Papagelopoulos PJ, Klassen RA, Peterson HA, Dekutoski MB. Surgical treatment of Scheuermann's kyphosis with segmental compression instrumentation. Clin Orthop Relat Res 2001;386:139–149

72. de Jonge T, Illes T, Belleyi A. Surgical correction of Scheuermann's kyphosis. Int Orthop 2001;25:70–73

73. Ponte A, Siccardi GL, Ligure P. Scheuermann kyphosis: posterior shortening procedure by segmental closing wedge osteotomies. J Pediatr Orthop 1995;15:404

74. Sturm PF, Dobson JC, Armstrong GW. Scheuermann's disease. Spine 1993;18:685–691

75. Horton WJ. Sequential temporary apical rod technique for segmental reduction of thoracic kyphosis: results in 26 consecutive adult patients. Paper presented at: 39th Annual Meeting of the Scoliosis Research Society; 2004; Buenos Aires

76. Gaines RW. Anterior instrumentation for Scheuermann kyphosis. Paper presented at: Innovative Treatment Options in Spine Surgery: One Day Course. 39th Annual Meeting of the Scoliosis Research Society; 2004; Buenos Aires

77. Daentzer D, Schloz M, von Strempel A. [Sports and physical load bearing capacity after spondylodesis in patients with Scheuermann kyphosis (German).] Sportverletz Sportschaden 1999;13:22–29

78. Poolman RW, Been HD, Ubags LH. Clinical outcome and radiographic results after operative treatment of Scheuermann's disease. Eur Spine J 2002;11:561–569

79. Reinhardt P, Bassett GS. Short segmental kyphosis following fusion for Scheuermann's disease. J Spinal Disord 1990;3:162–168

80. Lim M, Green DW, Billinghurst JE, et al. Scheuermann kyphosis: safe and effective surgical treatment using multisegmental instrumentation. Spine 2004;29:1789–1794

Chapter 20

Technological Advances in Spinal Deformity Surgery

Max C. Lee and Daniel H. Kim

The technological advances made within spinal surgery have increased dramatically within the past two decades. This advancement has progressed to the field of spinal deformities, leading to less invasive and more accurate placement of instrumentation. This advancement has been seen in patient satisfaction, with minimally invasive procedures causing less physical harm to tissue. Technological advances include optics in three dimensions and high definition (HD), instrumentation, image guidance, intraoperative imaging, intraoperative monitoring, and use of robotics. This chapter is divided into three main sections: minimally invasive surgery, image guidance, and robotics.

♦ Minimally Invasive Surgery

Innovative techniques, from the use of the operating microscope to image guidance, have changed our approach to problems in the operating room. In addition, improved instrumentation (from odontoid screws and lateral mass screws to sacropelvic fixation) has improved the surgical management of countless patients. It is these changes that have collectively led to the advancement of spinal surgery and subsequent improved outcomes.

One of the major advances within the past decade has been in the development of minimally invasive spinal surgery. Since its inception, progress has been very rapid. From percutaneous procedures to multilevel fusions, the advances in this field have been unparalleled. Furthermore, similar technology and techniques have been used in the treatment of spinal deformity. Advances in this arena include thoracoscopic and laporacopic decompressions, releases, placement of instrumentation, and deformity correction.

Thoracoscopic Approach and Placement of Minimally Invasive Instrumentation for Deformity Correction

Indications and Surgical Considerations

The indications for anterior surgery for the correction of spinal deformity are discussed in another chapter. This section will focus on the minimally invasive approaches for scoliosis reduction. Although the goals of minimally invasive surgery (MIS) are the same as the goals for open reduction, added benefits include less tissue trauma, decreased blood loss, decreased pain and time for rehabilitation, and smaller incisions. This approach, however, requires special attention to details and has a large training curve—as with other MIS procedures.[1] Therefore, the minimally invasive spine surgeon should be well versed in open techniques and other endoscopic spine procedures.[2]

Anterior thoracic scoliosis correction is kyphogeneic by nature.[3] Thus, it finds a niche with adolescent idiopathic scoliosis (AIS), which is generally hypokyphotic with an anterior column overgrowth. In addition to curves greater than 40 degrees but less than 80 degrees, the curve pattern should be amenable to instrumentation from T4 to L1. For patients demonstrating angles greater than 70 degrees, combined approaches may allow for more adequate reduction.

Because anterior scoliosis correction is kyphogenic contraindications include patients with kyphosis at that level. Angles greater than 30 degrees should be avoided because of the potential for instrumentation failure and neurologic injury. In addition, the pleural cavity should be amenable to thoracoscopic surgery. As with any thoracoscopic procedure, contraindications include pneumonia, pleural effusion, pleural adhesions, and inability to tolerate single-lung ventilation.

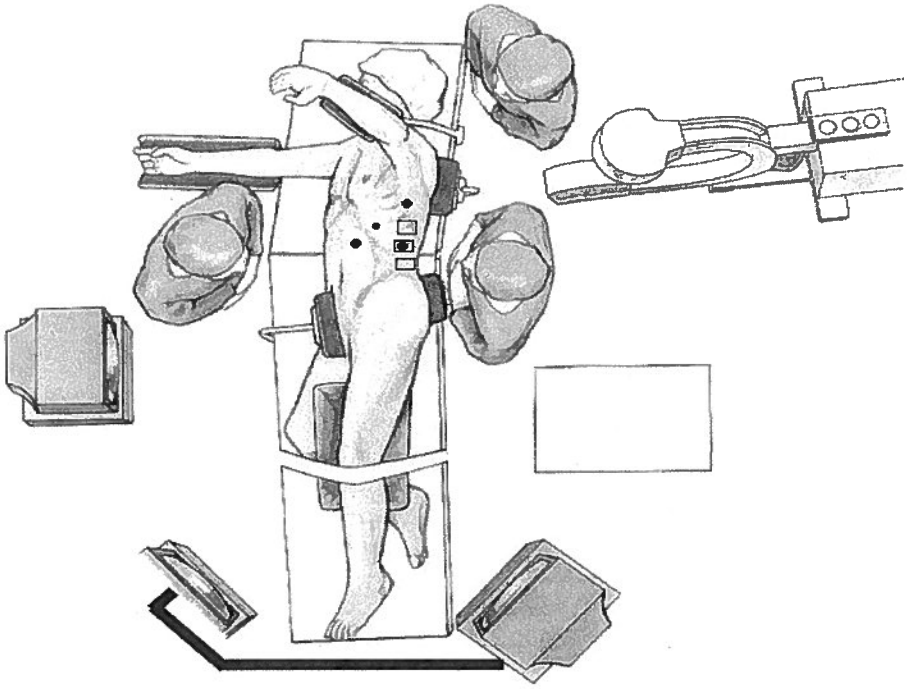

Figure 20–1 A graphical depiction of a patient positioned within the operating room.

Surgical Procedure

As is true for all of spine surgery, positioning and patient preparation is essential. In addition to thoracoscopic instruments, surgical equipment should include high-quality endoscopes and cameras, two monitors, and a radiolucent table. Intraoperative somatosensory evoked potentials (SSEPs) and motor evoked potentials (MEPs) are obtained. Anesthesia is induced with the capabilities of single-lung ventilation. The patient is placed in a lateral decubitus position on a radiolucent table with the convex side of the scoliotic curve facing upward. After the pressure points, axilla, head, and neck are addressed, the patient can be secured to the table **(Fig. 20–1)**.

The surgeon should stand opposite to the assistant, and both should feel comfortable with the table height and position of the monitors. Fluoroscopy may be used to visualize the level, and skin marks are made at selected levels and for future portal sites. Generally, one or two portals along the anterior axillary line will facilitate scope placement. On occasion, a fan retractor is placed for lung retraction.

Circumferential spine exposure is then accomplished with cautery. K-wires may facilitate fluoroscopic verification of the level involved. The segmental vessels are carefully dissected and may be sacrificed with clips **(Fig. 20–2)**. Then, disk excision is accomplished.

Placement of instrumentation is facilitated with the surgeon's familiarity of anatomy and fluoroscopic verification. As an optimal entry point is along the midvertebral body just anterior to the rib head, an awl is used to define an entry point. Tapping facilitates screw placement, and screw length can be determined by probing the depths of a tapped hole. Optimal screw length engages into the contralateral cortex, with the understanding that proper trajectory is essential. Cannulated screws may be used with a trajectory

Figure 20–2 Thoracoscopic scoliotic deformity reduction. Dissection and clipping of segmental vessels.

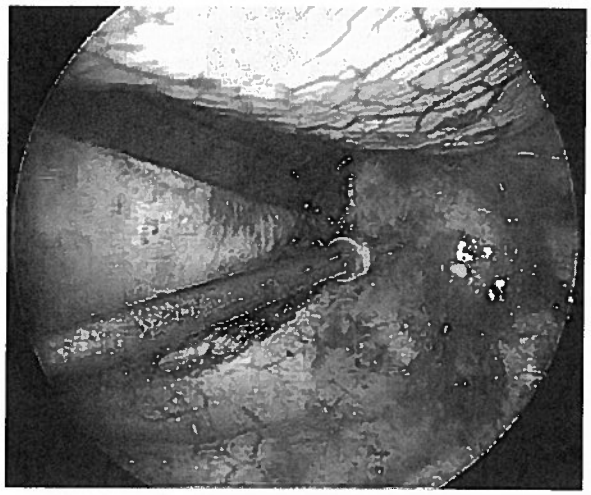

Figure 20–3 Endoscopic placement of thoracic anterior screws with a cannulated screw system. Placement of K-wire.

Figure 20–5 Thoracoscopic view of the diaphragm: defining the outer margin of the diaphragm.

set by a K-wire placed within the vertebral body. In this situation, calibrated K-wires facilitate screw length choice **(Fig. 20–3)**.

Rod length is determined with a ball-cable ruler or calibrated malleable template. Placed along the convex side, the shortening of the spine must be taken in consideration in the rod measurements. The rod is secured to the caudal screw via a screw cap. After an interbody spacer (allograft or autograft) is placed within the disk space above, the subsequent rostral screw is secured with compression. Fixating the rod to more rostral screws may be difficult because of the convexity of the spine. On these occasions, an approximator-cap inserter tool is used. Aggressive manipulation of the rod-screw construct may lead to weakening of the screw-bone interface **(Fig. 20–4)**.

After deformity correction, hemostasis, and irrigation, a chest tube is placed and closure is started. While the lung is reinflating, pleural closure can be accomplished directly or with an endoscopic stitching device. Then, standard closure of all of the incisions is finished.



Figure 20–4 Graphical representation of rod fixation with segmental compression.

Thoracoscopic Approach and Minimally Invasive Instrumentation for Deformity Correction of the Thoracolumbar Spine

Surgical Procedure

Through a thoracoscopic approach and retraction of the diaphragm, exposure to L2 is possible. On occasion, the diaphragm is split to facilitate more caudal exposure[4] **(Figs. 20–5 and 20–6)**. When more caudal exposure is necessary for deformity correction, a retroperitoneal or laparoscopic approach to the anterior lumbar spine may be accomplished. MIS of the anterior lumbar spine has also advanced with thoracoscopic surgery.

Attention has turned to minimally invasive retractors. Unfortunately, there is no system that has prevailed. The systems that have been marketed are balloon technology,[5] Laprolift (Origin Medsystems, Menlo Park, California)[6] and CO_2 inflation.

Combined Prone Position Anterior Release and Posterior Instrumentation

Indications and Surgical Considerations

Although thoracoscopic anterior fixation was demonstrated to be effective in idiopathic scoliosis that was hypokyphotic, combined approaches may allow for posterior fixation to correct kyphotic deformities within the sagittal plane.

In addition to the thoracoscopic methods mentioned above in a lateral decubitus position, thoracic anterior release has been accomplished in a prone position.[7] This facilitates the use of posterior instrumentation while releasing anteriorly in the same setting. The same indications and contraindications for MIS in the lateral decubitus position are true for the prone position. In addition, a small anteroposterior diameter of the chest wall and small scoliotic curvature may hamper proper placement of the thoracic trocars and working channels. Although curves greater than 40 degrees may require anterior release, curves less than 75 degrees may have rib interspaces that are too small to tolerate a 10-mm-diameter endoscopic portal.

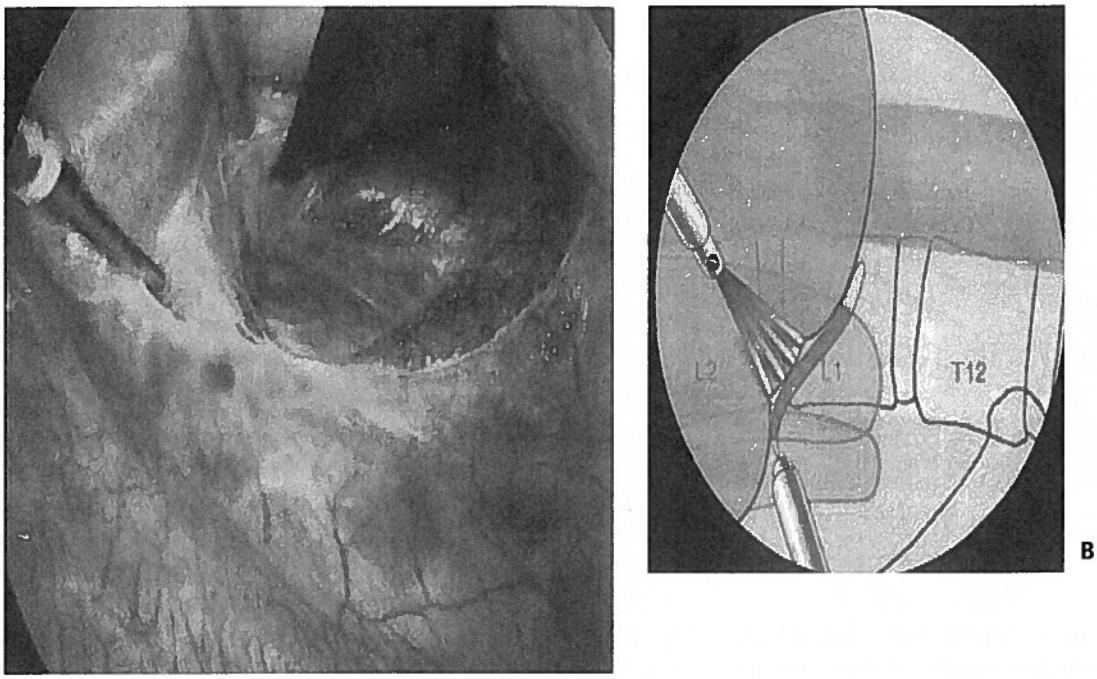

Figure 20–6 Thoracosopic view of the diaphragm split. **(A)** Intraoperative image with the diaphragm retracted caudally. **(B)** Graphical representation of normal diaphragm anatomy with caudal retraction after an incision along the lateral aspect of the muscle.

When the patient is positioned prone, the patient is prepared to the anterior axillary line. When the patient is in a lateral decubitus position, the convex side is placed upward; when the patient is in a prone position, the surgeon may enter the convex or concave side for kyphosis correction. Although the convex side may allow easier access to the disk spaces and provide a larger rib interspace for entering, the convexity leads to difficulty in releasing the extreme rostral and caudal interspaces.

After the first portal is placed, the remaining portals may be placed in a V or L shape. A prone position facilitates lung retraction, as the lung and mediastinal organs relax. After proper localization, diskectomies are performed. Diskectomies may be facilitated with distraction using the posterior instrumentation. Once the anterior release is accomplished, interbody spaces are placed. Spacers include allograft or autograft.

Finally, a chest tube is placed and closure is accomplished in a similar fashion to that mentioned above.

Conclusion

With increasing thoracoscopic/laparoscopic experience, improvements have been made in surgical techniques, implants, and instrumentation. While these improvements continue, so will the advancement of MIS for anterior thoracoscopic deformity correction **(Figs. 20–7 and 20–8)**.

Figure 20–7 Preoperative anteroposterior x-ray film of a patient with a scoliotic deformity.

♦ Computer Assistance and Image Guidance

As stated previously, MIS can reduce morbidity relative to traditional open procedures. As surgery performed through small incisions is often less traumatic than open procedures,

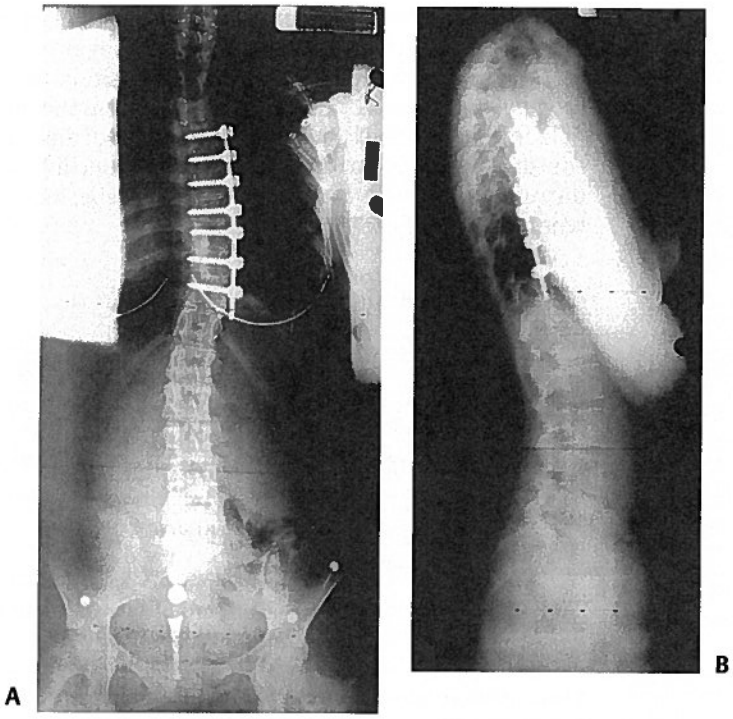

Figure 20–8 Postoperative x-ray films of a patient with a scoliotic deformity. **(A)** Anteroposterior x-ray image and **(B)** lateral x-ray image.

there is reduced postoperative pain, shortened hospital stay, and reduction in surgical complication rate. Unfortunately, these advantages do not come without cost. In addition to limitations of dexterity and tactile sensory feedback, there exists difficulty in depth perception and spatial orientation. These problems are due to a variety of factors, including monocular vision, a limited field of view, peripheral image distortions, and the projection of a natural three-dimensional (3D) surgical scene on a two-dimensional (2D) display.

Image-guided surgery (IGS) systems are widely used in a variety of cranial and open spine procedures. Such systems have the promise of addressing some of the visualization problems inherent with MIS and open surgery.

Fluoroscopy-Based Image-Guided Surgery

Fluoroscopy-based IGS overcomes some limitations and disadvantages of conventional C-arm fluoroscopy. Such systems track surgical instruments and display their position in real time on one or more previously acquired fluoroscopic images. The main components of a fluoroscopy-based IGS are a computer workstation with a monitor, a conventional C-arm fluoroscope with a calibration device that attaches to the imaging head of the fluoroscope, a tracking system including a spine clamp with a dynamic reference frame, and a variety of optically tracked instruments.

An optical tracking system consists of two or more optical sensors or cameras that detect infrared light-emitting diodes (IREDs), photoreflective spheres, or photoreflective disks that are mounted on the calibration devices, the dynamic reference frame (DRF), and the surgical instruments. Using mathematical principles of localization by triangulation, the system determines the spatial position and orientation of the instruments to provide real-time navigation. Multiple instruments can be tracked simultaneously during a procedure. In the case of actively tracked instruments using IREDs, each instrument IRED array is strobed by the tracking system. In the case of passively tracked instruments, the tracking system can identify different instruments with distinct marker configurations.

At the beginning of surgery, the fluoroscope is positioned in the usual fashion, the calibration device is attached to the imaging head, and the fluoroscope is draped within the field **(Fig. 20–9)**. The DRF is attached to the spinous process adjacent to the area of interest **(Fig. 20–10)**. One or more fluoroscopic images are obtained with the vertebral segments of interest centered in the field of view to minimize the effects of parallax. Each fluoroscopic image is transferred at the time of acquisition from the fluoroscope to the computer workstation through a standard video cable. The optical tracking system simultaneously determines the position of the calibration device and the DRF and determines the position of the C-arm relative to the patient and the time of image acquisition. The computer digitizes the acquired fluoroscopic image and calibrates the image using the positions of the radiopaque calibration markers that appear in the fluoroscopic image and the position of the C-arm relative to the patient. During the calibration process, the computer constructs a mathematical model of the fluoroscopic image formation process, which describes where a given position relative to the patient projects onto the fluoroscopic image. The mathematical model can be different for every acquired image for



Figure 20–9 FluorNav (Medtronic, Louisville, Colorado) Calibration Target allows for localization with the C-arm.

a variety of reasons. Because of this, the calibration device is left on the imaging head, and calibration is performed independently for every acquired fluoroscopic image. After the fluorosopic images are acquired and calibrated, the optical tracking system determines the positions of the instruments and the DRF. It then uses the relative instrument positions plus the image formation model to overlay a graphic representation of the tracked instruments on all preacquired fluoroscopic images. In addition, additional information can also be displayed, such as the trajectory of the instrument.

Advantages of fluoroscopy-based IGS include, first a reduction in radiation exposure.[8,9] Although surgical instruments are tracked and their positions placed on previously acquired images, it is not necessary to acquire a temporal sequence of images. Second, it is possible to acquire images in different orientations, eliminating the need to reposition the fluoroscope. Third, the C-arm may be removed from the operative field improving the ergonomics of the surgical environment. Fourth, IGS provides additional information including trajectory and linear/angular measurements. Finally, IGS does not require previously acquired images.

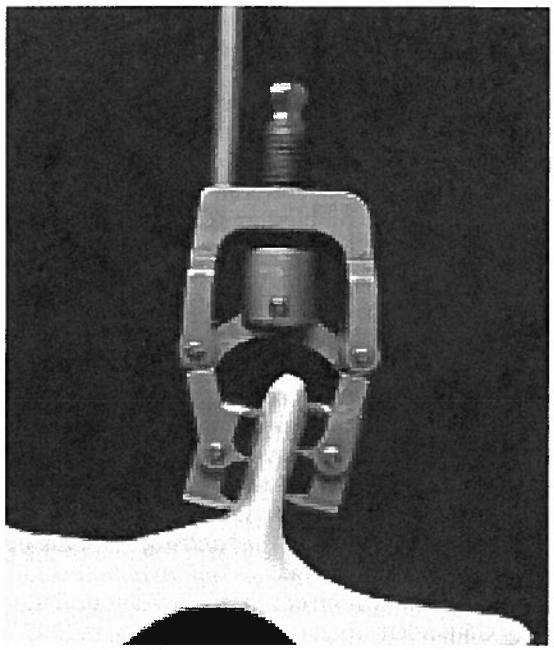

Figure 20–10 In open image-guided spine surgery, the dynamic reference frame (DRF) is attached to the spinous process.

CT-Based Image-Guided Surgery

CT-guided IGS enables real-time positioning and orientation on 3D renderings. Steps are similar to fluoroscopy-based system. Preoperative CT images are transferred to the IGS computer workstation. Preoperative planning is performed at the IGS computer workstation. The software is used to reconstruct the images. Two-dimensional reformatted imagers are available as well. In addition, the 3D rendering can be rotated, colored, and altered. This software allows for screw placement (entry point, trajectory, and screw dimensions).

The main components of a CT-based IGS system are similar to the fluoroscopy-based system mentioned above, with the exception of a C-arm. The DRF is secured to the spinous process and registration is performed. Then, navigation can be performed.

Image to physical registration is one of the most fundamental steps in image-guided interventions. Meanwhile, rapid and accurate registration remains as one of the major technical difficulties of CT-based spinal IGS procedures. Registration is commonly performed using geometric features; which include anatomical landmarks, surfaces, and fiducials. Whereas the use of fiducials and frames are common for cranial surgery, they are impractical and/or produce high error in spinal application. Thus, in open spinal IGS procedures, point-based registration is popular. This involves finding the coordinates of corresponding points in the preoperative CT image and the physical space of the patient. Such bony anatomical landmarks as the tip of the spinous or transverse process are identified in the preoperative CT images and localized in physical space by touching the landmarks with a tracked probe. For localization of anatomical landmarks, manual localization of landmarks is typically more accurate if the same person localizes the landmarks in both the image and the physical space. The registration procedure is typically faster if the surgeon localizes these points on the preoperative CT before the procedure.

To maximize accuracy, the points should be picked according to a few simple guidelines. Use as many markers as feasible—three linear markers are required mathematically, but error decreases with increased markers.[10,11] Markers may be placed circumferentially to the area of interest. Markers should be placed as far apart as possible. There should be an avoidance of linear marker configurations. Another registration method is surface-based registration. In this case, the probe is moved along the surface of the vertebra, and the recorded surface points are matched to the vertebral bone surface model extracted from the CT image. Registration accuracy is largely dependent on the surgeon carefully performing the surface mapping process. A casual approach to this step may create substantial error. The surface-based registration requires an accurate segmentation,

takes substantially more time to collect the surface information, and requires a thorough soft-tissue debridement of the exposed spinal surface. On the other hand, point information can be used with surface information to improve accuracy.

These point- and surface-based registration approaches are only applicable for open IGS procedures. With minimally invasive techniques such as percutaneous and endoscopic spinal surgery, these techniques lose their applicability. Although techniques have been developed to augment this problem (such as preoperative DRF placement and ultrasound probed points), currently marketed techniques involve registering the preoperative 3D image to an intraoperative 2D fluoroscopic image.

Feature-based 2D-3D analysis is based on image contours. It requires segmentation of the object surface in preoperative CT images and the object contour in intraoperative projection x-ray images. This is performed by minimizing a distance-based cost function between the 3D surface model and the back projection lines stemming from the 2D contour points. Algorithms based on contours have adequate execution speed for use in a clinical context, but the interactive selection of object contours on the x-ray images is difficult and time consuming. In addition, the accuracy of the registration is highly dependent on the contour segmentation.

Intensity-based 2D-3D analysis integrates one or more x-ray projections with the preoperative CT image. This involves computing a synthetic x-ray image (digitally reconstructed radiographs; DRRs) by casting rays using known camera geometry through the CT image. The DRR pixel values are simply the summations of the CT values encountered along the projection ray. The pose (position and orientation) of the CT image is adjusted until the DRR it produces is most similar to the x-ray projection image. The accuracy of intensity-based 2D-3D image registration has been validated for the head and approaches 1 mm. It is inherently more difficult to register the spine than the cranium because of the smaller size. Nonetheless, this method is promising—achieving accuracy within 1 to 2 mm within the spine.

♦ Robotics for Spine Surgery

Robotic Spine Surgery

Although innovations in minimally invasive spine surgery for scoliotic deformity continue to advance, these procedures have yet to gain widespread adoption due to the challenges of mastering the endoscopic technique. Difficulties remain in achieving dexterity and precision of instrument control within the confines of a limited operating space, further compounded by the need to operate from a 2D video image. The application of robotic technology has the potential to contribute significantly to the advancement of endoscopic spine surgery.

Although MIS techniques have revolutionized many surgical procedures, the introduction of MIS has also brought with it certain unique complexities that are not present with conventional open surgery. First, MIS instruments work through cannulas, or ports, in the body wall. These ports act as pivot points that consequently reverse the direction of motion of the instrument tip in relation to the motion of the instrument handle. For instance, to move the tip to the left inside the body cavity requires the surgeon to move his or her hands to the right outside the body, and so on. This reversal of motion creates nonintuitive control of the instruments that is mentally taxing, especially as the complexity of the surgical task increases.

Second, the majority of MIS instruments consist of an end effector mounted to the tip of a long, rigid shaft. The endoscopic cannula allows these instruments to pivot around the fixed point within the body wall, but it restricts motion laterally. The six degrees of freedom of position and orientation (defined as motion along the X, Y, and Z axes and rotation about each of these axes) of open instruments is therefore reduced to 4 degrees of motion (i.e., pitch, yaw, roll, and insertion) for MIS procedures. An additional two degrees of freedom could be restored to MIS instruments by constructing articulations at the distal end, past the location of the cannula pivot point; however, the precise and dynamic control of these distal articulations would be difficult to coordinate without the assistance of computer control.

The long shafts of MIS instruments force a separation of the surgeon's hands from the operative anatomy, which significantly decreases the amount of tactile sensation and force reflection available. The extended length of the instruments also significantly magnifies any existing hand tremor. Furthermore, the excursion of an instrument tip is highly dependent on its depth of insertion. For instance, an instrument that is shallowly inserted requires comparatively large hand movements to accomplish a given instrument movement inside the body; a deeply inserted instrument requires much less hand movement to sweep the instrument tip around. As a result, the dynamics of the instrument change constantly as it is inserted and retracted throughout a procedure. Overall, all these factors can lead to less precise and less predictable movements when compared with standard, open surgical instruments.

The introduction of an endoscope forces a surgeon to be visually guided by a video image instead of direct vision. The video monitor is often located on the far side of the patient, and the differences in orientation between the endoscope, instruments, and monitor requires the surgeon to perform a difficult mental transformation between the visual and motor coordinate frame. This problem is further exacerbated whenever an angled endoscope is used.

The majority of conventional endoscopes are built around a single lens train that is only capable of displaying images in a flat 2D format. This removes much of the depth cues of normal binocular vision, complicating such tasks as dissection between tissue planes. Some stereoscopic vision systems exist, but their performance is limited in resolution and contrast due to the endoscope itself as well as the display technology. In addition to these limitations, conventional endoscopes often require a dedicated assistant to hold and manipulate them. The natural tremors and movements of the handling assistant are exacerbated by the magnified image.

The first recorded application of robotics in a surgical procedure was for CT-guided stereotactic brain biopsy in 1987.[12] Since then, technological advances have led to the development of several different robotic systems. These systems vary

significantly in complexity and function. Robots can interact with surgeons in many ways. One classification of robots is in terms of the level of autonomy exercised by the robot. One class operates autonomously in that the robots carry out a preoperative plan without any immediate control from the surgeon. The tasks performed are typically focused or repetitive, but they require a degree of precision not attainable by human hands. The second class of robots operates as surgical-assist devices, meaning that the surgeon and the robot share control. In the final class of robots, every function is explicitly controlled by the surgeon. The hand motions of the surgeon at the control console are tracked by the electronic controller and then relayed to the slave robot in such a manner that the instrument tips perfectly mirror every movement of the surgeon. Because the control console is physically separated from the slave robot, these systems are referred to as *teleoperators.*

ROBODOC

Orthopaedic surgery was one of the first areas of surgery to adopt the use of robotics. In comparison with soft tissue, bones deform minimally during cutting and are more amenable to image-guided technology. The result is that robotic procedures can result in far better agreement with a preoperative plan than the analogous manual procedure.

The ROBODOC (Integrated Surgical Systems, Davis, California) system began development in 1986 to address potential human errors in performing cementless total hip replacement.[13] In this procedure, the hip joint is disarticulated, and the femoral head and acetabular cup are resected. The acetabular cup is replaced by a metal and polymer prosthetic. The femoral implant consists of a long metal shaft that is inserted into a deep cavity that must be milled along the longitudinal axis of the femur. These femoral implants were originally cemented in place; however, long-term data showed that the cement was prone to cracking, loosening, or causing osteolysis that would ultimately lead to failure of the implant. Newer cementless implants have a porous metal surface and rely on natural bone ingrowth for fixation. This ingrowth requires close proximity between the implant and the bone surface, so long-term success is highly dependent on a tight fit between the two.

The ROBODOC system provides two advantages over the manual procedure. First, several clinical trials have confirmed that the robotically milled femoral pockets are more accurately formed.[7,8] Second, the preoperative CT images that are used to plan the bone-milling procedure allow the surgeon to optimize the implant size and placement for each patient.

Cyberknife

Another excellent example of an autonomous robotic system is the Cyberknife (Accuracy Incorporated, Sunnyvale, California). The system was first developed in 1994 as a noninvasive means to align treatment beams precisely for frameless stereotactic radiosurgery of brain tumors.[14] There are three fundamental differences from conventional frame-based radiosurgery. The delivery of an image-guided radiosurgery treatment follows a "step-and-shoot" sequence. Once the patient is placed in a position approximating the preoperative CT scan, the imaging system acquires a pair of alignment radiographs to determine the initial treatment site in the robot coordinate system. The robotic arm then moves the x-ray linear accelerator through a series of predetermined positions, or nodes, surrounding the patient. At each node, the robotic arm stops and reacquires a new pair of images from which the target position is redetermined. After the position of the target is confirmed, the arm adapts beam pointing to compensate for any movement, and the linear accelerator delivers the preplanned radiation dose for that direction. The complete process is repeated for each node. In the typical case, the system will deliver 6 to 30 Gy at the tumor margin, distributed among 100 intersecting beams. Remeasurement intervals between delivery doses are between 20 and 40 seconds.

Surgical-Assist Devices

The second classification of surgical robotic systems currently in use is the surgical-assist device. One example is a robotic system for bone cutting in knee joint replacement procedures. The surgeon grasps the cutting tool at the end of a low-impedance robot manipulator and moves the tool to reshape the bone to fit the prosthetic joint. The robot monitors the surgeon's actions and permits free motion in the appropriate cutting region but applies forces to prevent motion into regions where bone should not be removed. This allows the surgeon to supervise and control the robot, using human sensing and judgment, while it also provides active constraints that increase safety and accuracy of the cutting process.

AESOP

The most widely used example of this type of robot is AESOP (Automatic Endoscopic System for Optimal Positioning; Computer Motion, Inc., Goleta, CA, USA). In essence, AESOP is a voice-activated robotic endoscope holder and manipulator. It allows a surgeon to attach a scope to a robotic arm that provides a steady image by eliminating the natural movements inherent in a live camera holder. The surgeon is then able to reposition the camera by voice commands. In addition, the surgeon has the ability to preset camera positions, enabling rapid repositioning of the image to different areas of the operative field. Today, AESOP is used in many different surgical disciplines, including general surgery, gynecologic surgery, cardiothoracic surgery, and urology.

To date, several studies have evaluated the effects of such robotic surgical-assist devices as the AESOP system on such specific parameters as operative time and operative outcomes. Overall, these studies appear to conclude that although such camera manipulating assist systems do not significantly alter operative times, patient length of stay, or operative morbidity, they do provide the subjective sense that there is less inadvertent movement of the laparoscope. In addition, the studies conclude that such systems may be beneficial in that they decrease the need for an operative assistant assigned to hold the laparoscope, thereby enabling "solo" laparoscopic surgery in some cases.

Teleoperators

In the realm of true operative procedures, there currently are only two systems commercially available: the da Vinci Surgical

System by Intuitive Surgical, Inc. (Sunnyvale, CA, USA) and the Zeus system by Computer Motion, Inc. Although these systems are popularly referred to as surgical "robots," this is a misnomer, as the term *robot* implies autonomous movement. In neither da Vinci nor Zeus does the system operate without the immediate control of a surgeon. A better term may be *computer-enhanced telemanipulators.* For the sake of consistency with published literature, however, this chapter will continue to refer to such systems as robots.

The integration of computer technology into both the da Vinci and Zeus systems helps to resolve many of the limitations of MIS. By scanning the surgeon's hand motions, information is relayed to the instruments to move them in the corresponding direction and orientation. Intuitive nonreversed instrument control is therefore restored while also preserving the noninvasive nature of the MIS approach.

The presence of a computer control system allows one to filter out inherent hand tremor, thus making the motion of the instrument tips steadier than it is with the unassisted hand. In addition, the system allows for variable motion scaling from the surgeon's hand to the instrument tips. For instance, a 3:1 scale factor maps 3 cm of movement of the surgeon's hand into 1 cm of motion at the instrument tip. In combination with image magnification from the video endoscope, motion scaling makes delicate motions easier and more precise. In both systems, the instruments are also engineered with articulations at the "wrist" distally that increases their dexterity compared with simpler MIS tools. The da Vinci system alone possesses instruments capable of the full 6 degrees of freedom of the human wrist.



Figure 20–11 The da Vinci system 4th Arm Patient Side Cart. Image provided by Intuitive Surgical, Inc. (Sunnyvale, CA, USA).

The Zeus System

The Zeus system is a telemanipulator system that consists of a surgeon's console and three robotic arms. The surgeon operates from a console several feet away from the operating table. There the surgeon uses handheld manipulators to control the two robotic arms and surgical instruments, a foot pedal to activate the computer-driven system, and voice commands to direct a camera controlled by an AESOP arm. Like the da Vinci system, the Zeus system offers tremor reduction and motion scaling.

The Zeus system consists of three modular, freestanding robotic arms that are attached to the operating table. This design allows the system to be oriented to many different configurations. The Zeus system also features 3.5- to 5.0-mm instruments, several of which are capable of increased articulation through the Zeus Microwrist. This joint provides the instrument with an additional degree of freedom at the wrist, giving a total of five degrees of freedom. The Zeus system also features the ability to accommodate a variety of visualization options (3D and 2D) and scope sizes. Although these options are available, 3D visualization does not appear to be a core feature of this system. The Zeus system is similarly compatible with a variety of instruments from several off-the-shelf manufacturers.

The Da Vinci System

The da Vinci system is made up of two major components **(Fig. 20–11)**. The first is the surgeon's console, which houses the visual display system, the surgeon's control handles, the user interface buttons, and the electronic controller. The second component is the patient side cart, which consists of two arms that control the operative instruments, and a third arm, which controls the video endoscope.

The operative surgeon is seated at the surgeon's console, which can be located up to 10 m away from the operating table. Within the console are located the surgeon's control handles, or masters, which act as high-resolution input devices that read the position, orientation, and grip commands from the surgeon's fingertips. They also act as haptic displays that transmit forces and torques back to the surgeon's hand in response to various measured and synthetic force cues. This control system also allows for computer enhancement, enabling motion scaling and tremor reduction.

The image of the operative site is projected to the surgeon through a high-resolution stereo display system that uses two medical-grade cathode ray tube (CRT) monitors to display a separate image to each of the surgeon's eyes. The surgeon's brain then fuses the two separate images into a virtual 3D construct. The image plane of the stereo viewer is superimposed over the range of motion of the masters, which restores visual alignment and hand-eye coordination. In addition, because the image of the endoscopic instrument tip is overlaid on top of where the surgeon senses his or her hands, the end effect is that the surgeon feels that his or her hands are virtually inside the patient's body.

Since its inception in 1995, the da Vinci system has received generalized clearance for surgery under European CE guidelines; in the United States it has received clearance for general, thoracic surgery, and urologic procedures such as the radical

prostatectomy. In addition, the da Vinci system recently received FDA clearance for cardiac procedures involving a cardiotomy. To date, thousands of surgical procedures in multiple disciplines have been performed using the da Vinci system.

Application of Robotics to Endoscopic Spine Surgery

Procedures such as thoracoscopic diskectomy, vertebrectomy, and interbody fusion can all be performed using existing endoscopic equipment; however, mastery of these techniques in an endoscopic environment is challenging. Compared with open surgery, few would argue with the assertion that significant sacrifices are made in terms of the maneuverability and dexterity of the instrument tips, the precision and delicacy of dissection, and the sheer ease with which procedures may be accomplished.

There are several distinct and compelling advantages associated with the use of the surgical robot, which suggests that this particular technology is capable of significantly enhancing current operative technique. Unlike conventional instrumentation, which requires manipulation in reverse, the proportional movement of the robotic device allows the instruments to follow the movement of the surgeon's hands directly. The intuitive control of the instruments is particularly advantageous for the novice endoscopist. In addition to mimicking the surgeon's movements in an intuitive manner, the robotic instruments offer six degrees of freedom plus grip, two more than conventional instruments. This technology permits a large range of motion and rotation that follows the natural range of articulation of the human wrist and may be particularly helpful when working space is limited. The electronic control system is capable of filtering out hand tremors as well as motion scaling, whereby gross hand movements at the surgeon's console may be translated to much finer movement of the instrument tips at the operative site. The 3D vision system adds a measure of safety and surgical control beyond what is available with the traditional endoscope. The 3D display improves depth perception, and the ability to magnify images by a factor of 10 allows extremely sensitive and accurate surgical manipulation. The alignment of the visual axis with the surgeon's hands in the console further enhances hand-eye coordination to a degree uncommon in traditional endoscopic surgery.

♦ Future Direction

Although the current robotic systems represent great strides in technology, the possibilities for innovation are virtually endless.

The use of a video image that is processed through a computer system rather than direct vision allows for the overlay of any number of images or information. For instance, vital signs and other patient data may be projected directly in front of the surgeon's eyes while he or she is operating. A 3D image of a tumor may be directly overlaid on top of the operative field as the dissection is performed. Virtual models of heart valves, orthopaedic implants, or vascular conduits may be test fitted before the costly objects are requisitioned.

Because the computer systems may be made aware of both the patient's anatomy and the position of the operative instruments, a virtual "safety envelope" may be defined. The system can then track the surgeon's hand movements and prevent inadvertent damage to collateral tissue.

One of the "holy grails" of robotic surgery is to endow the systems with true force reflection and haptic feedback; however, the presence of the numerous mechanical joints inherently imparts additional friction to the entire kinematic chain. It is therefore difficult to distinguish friction that originates from the robotic system and forces from living tissue. This limitation will be overcome with the development of newer computer algorithms and microsensors that can be positioned at the tips of the instruments. The control handles of such a system as the da Vinci both sense a surgeon's hand movements and are electronically powered and can relay force information back to the surgeon. Tissue tension can be delivered, as in conventional surgery, as can any range of biological data. For instance, the pulsations of a diminutive artery can be enhanced and magnified such that it is palpable to the surgeon at the console. Other variables that are not in the average realm of human perception (e.g., oxygen tension, temperature, and density) may also be conveyed, as demonstrated by the U.S. National Aeronautics and Space Administration Smart Probe project.

The fact that robotic systems can track a surgeon's hand movements brings with it the ability to record that wealth of data. Thus, every nuance of a master surgeon's performance, as well as the visual information from the operation, may be preserved. All that information may then be replayed in its entirety for those in training. Rather than stumble through an operation step by step, a novice may be able first to mimic, then to perform, an operation as it was meant to be. This "player piano" model may be invaluable in surgical education and could change the manner in which future generations learn to operate.

Computer systems are also much more facile than the human mind at processing complex coordinate frames of reference. For example, the operative instruments can be programmed to always align with the axis of view of the endoscope. Thus, wherever the endoscope is angled, it would appear to the surgeon that he or she is positioned at the end of the endoscope. For instance, an angled endoscope inserted into the mouth and directed back toward the nasopharynx could establish a vantage point for the operative instruments such that one could seem to operate through the back of the patient's head.

A much-popularized idea is the concept of telesurgery, whereby a surgeon can perform an operation from a distance by means of a remote interface. This concept, first conceived for military applications, would allow for the delivery of surgical care to remote or inhospitable areas. It also allows a surgeon the ability to perform operations far beyond his or her immediate geographical vicinity. The world's first transatlantic laparoscopic cholecystectomy has been performed remotely, in which a surgeon located in New York operated on a patient in Strasbourg, France. This concept, however, is still severely limited by the capability of current bandwidth as well as the speed of light. A less ambitious application is telementoring, whereby an experienced specialist can observe and advise a surgical team operating in a remote location. A growing number of procedures have already been accomplished using this technology.

The advent of minimally invasive surgery has brought with it a wealth of potential benefits for patients and the health care system; however, the inherent limitations of operating in an endoscopic setting pose significant challenges for the surgeon, and this is only magnified as procedures become more complex (e.g., those encountered in spine surgery). The incorporation of robotic and computer technology has the potential to contribute significantly to the advancement of this area. As the technology continues to be refined, its ultimate acceptance will demand that issues of cost, training, safety, efficacy, and clinical utility all be addressed. There remains much work to be done yet also much good to be gained.

References

1. Newton PO, Shea KG, Granlund KF. Defining the pediatric spinal thoracoscopy learning curve: sixty-five consecutive cases. Spine 2000;25(8): 1028–1035
2. McAfee PC, Regan JR, Zdeblick T, et al. The incidence of complications in endoscopic anterior thoracolumbar spinal reconstructive surgery. A prospective multicenter study comprising the first 100 consecutive cases. Spine 1995;20(14):1624–1632
3. Millner PA, Dickson RA. Idiopathic scoliosis: biomechanics and biology. Eur Spine J 1996;5(6):362–373
4. Beisse R, Potulski M, Temme C, Buhren V. [Endoscopically controlled division of the diaphragm. A minimally invasive approach to ventral management of thoracolumbar fractures of the spine.] Unfallchirurg 1998; 101(8):619–627
5. Olinger A, Hildebrandt U, Mutschler W, Menger MD. First clinical experience with an endoscopic retroperitoneal approach for anterior fusion of lumbar spine fractures from levels T12 to L5. Surg Endosc 1999;13(12): 1215–1219
6. Hannon JK, Faircloth WB, Lane DR, et al. Comparison of insufflation vs. retractional technique for laparoscopic-assisted intervertebral fusion of the lumbar spine. Surg Endosc 2000;14(3):300–304
7. Lieberman IH, Salo PT, Orr RD, Kraetschmer B. Prone position endoscopic transthoracic release with simultaneous posterior instrumentation for spinal deformity: a description of the technique. Spine 2000;25(17): 2251–2257
8. Rampersaud YR, Foley KT, Shen AC, Williams S, Solomito M. Radiation exposure to the spine surgeon during fluoroscopically assisted pedicle screw insertion. Spine 2000;25(20):2637–2645
9. Foley KT, Simon DA, Rampersaud YR. Virtual fluoroscopy: computer-assisted fluoroscopic navigation. Spine 2001;26(4):347–351
10. Maurer CR Jr, Fitzpatrick JM, Wang MY, Galloway RL Jr, Maciunas RJ, Allen GS. Registration of head volume images using implantable fiducial markers. IEEE Trans Med Imaging 1997;16(4):447–462
11. West JB, Fitzpatrick JM, Toms SA, Maurer CR Jr, Maciunas RJ. Fiducial point placement and the accuracy of point-based, rigid body registration. Neurosurgery 2001;48(4):810–817
12. Young RF. Application of robotics to stereotactic neurosurgery. Neurol Res 1987;9(2):123–128
13. Bargar WL, Bauer A, Borner M. Primary and revision total hip replacement using the Robodoc system. Clin Orthop Relat Res 1998;354: 82–91
14. Adler JR Jr, Murphy MJ, Chang SD, Hancock SL. Image-guided robotic radiosurgery. Neurosurgery 1999;44(6):1299–1307

Chapter 21

Surgery for Adult Spinal Deformity

John P. Kostuik, D. Greg Anderson, and Khaled M. Kebaish

♦ Adult Scoliosis

Definition and Features

Adult scoliosis may be defined as a lateral curvature of the spine in a skeletally mature individual. Adult scoliosis can further be subdivided into curves that began prior to skeletal maturity including idiopathic, congenital, and paralytic curves and those that arise de novo after skeletal maturity including those secondary to degenerative disease, iatrogenic causes, post-tramatic causes, and osteoporotic/osteomalacic curves. The largest proportion of patients seeking treatment by a spinal specialist will have curves that began as adolescent idiopathic scoliosis or those due to degenerative scoliosis. Although idiopathic scoliosis rarely leads to significant symptoms in the child, adults more commonly experience pain, changes in sagittal balance, and curve progression as the result of degenerative changes in the spine. Many investigators have shown that idiopathic curves have the potential to progress after skeletal maturity, which may lead to clinical symptoms.[1–5]

In addition to the symptoms of increasing back pain and truncal imbalance, older adults commonly experience symptoms related to osteoporosis and spinal stenosis. Some patients present for management of complications resulting from a prior operation to treat their spinal deformity, such as an iatrogenic flat back, pseudarthrosis, or a degenerated adjacent spinal segment. In the past, conservative measures were the mainstay of treatment recommendations for adult deformities because surgical correction for major spinal deformity presented substantial risks. In 1968, Nachemson estimated the risks related to adult deformity correction to include a 5% risk of death, 6% risk of a major neurologic deficit, 20% risk of significant correction loss, 10% risk of a deep infection, and a 40% risk of a major medical complication.[6] Fortunately, the techniques for achieving and maintaining correction of spinal deformities have improved significantly since that time as have the perioperative management strategies. However, correction of a major spinal deformity in an older adult remains one of the most challenging procedures in the field of surgery.

The history of modern surgical techniques for spinal deformities began with the advent of Harrington rods[7,8] and included many pioneers such as Dwyer,[9] Luque,[10–12] Zielke,[13] and Cotrel-Dubousset[14,15] who played a role in the development of spinal instrumentation systems and in providing an ever-improving understanding of the treatment for spinal deformities. Although the Harrington system worked reasonably well for a simple thoracic deformity, fusions of the lumbosacral region often resulted in loss of lordosis or pseudarthrosis. In 1978, a review undertaken on behalf of the Scoliosis Research Society demonstrated significant loss of lumbar lordosis in 4% of scoliosis fusions, a problem that often led to poor clinical outcomes.

After the recognition in the late 1970s that posterior distraction of the lumbosacral spine using Harrington rods commonly led to a flat-back deformity, posterior segmental fixation systems and pedicle screws with contoured rods were developed and have significantly reduced the incidence of this problem. Parallel to the improvements in surgical technique have been improvements in anesthesia techniques, spinal cord monitoring, and perioperative medical management and postoperative care, which have dramatically increased the sophistication and safety of modern spinal deformity correction. The modern approach to adult deformities involves a team of specialists including the reconstructive spinal surgeon, anesthesiologist, intensive care specialist, physical therapist, nutritionist, rehabilitation physician, and orthotist. In this chapter, we will discuss the scope and approach to the adult with a spinal deformity.

Incidence and Function

Shands and Eisberg studied 194,060 chest radiographs in the state of Delaware in 1953 (82.2% of the entire state population over the age of 14) and found a spinal curve in 1.9% including 1.4% with mild curves (10 to 19 degrees), 0.3% with moderate curves (20 to 29 degrees), and only 0.2% with curves greater than 30 degrees.[16] Kostuik and Bentivoglio reported a 3.9% prevalence of structural curves in the adult thoracolumbar and lumbar spine during a review of 5000 intravenous pyelograms.[17]

The risk of curve progression after skeletal maturity for idiopathic scoliosis has been studied by Weinstein and Ponsetti[18] who followed a cohort of 102 patients with idiopathic scoliosis an average of 40.5 years and reported that 68% of curves progressed in adulthood. Although curves less than 30 degrees tended not to progress, curves between 50 and 75 degrees had a high risk of progression over the follow-up period. Risk factors for curve progression included a lumbar curve, a curve involving a poorly seated fifth lumbar vertebra, and apical vertebral rotation of more than 33%. Other risk factors for progression include significant trunk imbalance, sharp angular curves in the lumbar spine, and curves emanating from the lumbosacral junction. Because these patterns often present the greatest technical difficulty for correction in later adult life, they are best treated surgically at an earlier age, if possible.

Fowles and Drummond[19] studied the effected of untreated scoliosis on quality of life in adults and concluded that the presence of a severe spinal deformity could be disabling. Although most patients experienced some back pain, up to one quarter of the patients in their study experienced disabling symptoms as a result of their deformity. In addition, many adults with spinal deformities reported embarrassment as a result of their spinal deformity, and women, in particular, were less likely to marry. The authors also noted socioeconomic consequences in adults with scoliosis. In contrast, Weinstein et al.,[20] Nachemson,[6,21] and Nilsonne and Lundgren[22] believed that disabling pain was rarely a significant clinical problem in the adult with scoliosis.

In one study, the overall prevalence of pain in adults with idiopathic lumbar and thoracolumbar scoliosis was found to be 60%, a rate similar to age-matched controls.[17] However, the prevalence and severity of pain complaints increased significantly for curves that were greater than 45 degrees and for curves involving the lumbar spine. In contrast, thoracic curves were much less likely to be the source of significant pain symptoms but led to significant pulmonary dysfunction when associated with thoracic lordosis. The highest incidence of pain complaints is normally observed between the fifth and seventh decades of life in the scoliotic population. Although the majority of patients with scoliosis are able to carry out productive lives, the adult deformity population is less likely to function well in highly physically demanding forms of work and is more likely to miss work or become disabled due to back problems compared with the general population.

Guigui studied factors affecting the function of adults with scoliosis and identified three anatomic elements associated with a declining function. These included the development of thoracolumbar kyphosis, increased rotatory translation of lumbar vertebral segments, and degenerative changes in the lumbosacral area.[23] In a similar study, Schwab et al. found that lateral vertebral olisthesis, L4 end-plate obliquity, poor lumbar lordosis, and thoracolumbar kyphosis significantly correlated with symptoms of pain.[24] Engsberg et al. found that gait was affected in adults with scoliosis leading to lower walking velocities for patients with lumbar deformities compared with age-matched controls.[25]

Deviren et al. found that curve magnitude and age were the greatest predictors of curve stiffness and pain symptoms. Curves greater than 40 degrees demonstrated decreased flexibility with every 10-degree increase in coronal deformity resulting in diminished flexibility by 10%. Similarly, each decade of life diminished curve flexibility by 5% in the major curve and 10% in the lumbosacral fractional curves.[26]

♦ Patient Evaluation

History

During the history, the physician must gain a thorough understanding of the location and severity of any symptoms and should assess the effectiveness of prior treatments for the condition. It is important to understand how the deformity affects the patient's life including the effect on activities of daily living, occupation, social function, recreation, and sexual functioning. Some patients will have significant concerns about the aesthetics of the deformity, and these issues should be discussed. A family history of progressive deformity should be sought, and the onset and progression of the patient's deformity should be defined. Clinical clues to deformity progression can include changes in height, clothing fit, or body shape (rib hump or altered waistline). Ideally, a more precise documentation of curve progression should be obtained from serial radiographs if available.

The visual analogue scale can be used to quantify pain symptoms. Pain drawings are useful in eliciting the location and radiation of symptoms. Pain at the apex of the curve should be differentiated from pain at a remote site. Often, a radicular or referred component to the pain will be present in older adults. When assessing leg symptoms, scleratomal referred pain should be differentiated from a true radiculopathy, which generally indicates neural element compression. Patients with severe thoracic or thoracolumbar curves may present with intercostal neuralgia due to the associated deformities of the rib cage. Bladder or bowel dysfunction may occasionally be present in the setting of severe spinal stenosis.

The general impact of the spinal condition on a patient's health and mental functioning may be assessed using validated outcome measures. Schwab et al. analyzed SF-36 scores in adult scoliosis patients and found lower scores in seven of eight categories including physical functioning, role physical, bodily pain, general health, vitality, social functioning, role emotion, and mental health compared with the general U.S. population.[24] Patients with lumbar deformities and loss of lordosis demonstrated particularly poor values in the social function, role emotion, and overall general health categories. In another study, Berven et al. analyzed the modified Scoliosis Research Society outcomes instrument (SRS-22) and the SF-36 in adults with scoliosis and found significantly

lower scores compared with unaffected controls in every domain of these scales.[27]

Physical Examination

Physical examination should include a broad assessment of the musculoskeletal and neurologic systems. The three-dimensional characteristics the spine such as the magnitude and location of the spinal curves, the sagittal plane balance (e.g., kyphosis or lordosis relative to normal), the rib hump, the degree of decompensation, curve flexibility, pelvic obliquity and hip mobility should be determined. Older adults with severe deformities may complain of pain from abutment of the rib cage against the iliac wing, which can be determined by physical examination.

The neurologic examination should be thorough and include a search for subtle neurologic abnormalities associated with spinal cord dysfunction. Example of significant findings may include a left thoracic curve, mild clawing of the toes, asymmetry of the abdominal reflexes, or subtle balance/gait difficulties, which could indicate a syringomyelia, tethered cord, or neuromuscular syndrome.

Body habitus is important to assess and can affect the treatments offered. Obese patients often benefit from weight loss, which may improve the symptom of axial pain. Poor nutrition is commonly seen in the elderly spinal deformity population and should be corrected prior to any planned surgical intervention to diminish the odds of infection and other perioperative complications.

Imaging Studies

The initial radiographic studies include 36 in., standing posterior/anterior (PA), and lateral radiographs. It is important to ensure that the patient straightens their knees during the lateral radiograph to allow the detection of sagittal imbalance. Focal or coned views of specific regions of the spine are helpful to evaluate facet arthritis, congenital anomalies, and disk-space narrowing. Oblique radiographs using Stagnara views are useful to assess kyphosis in the setting of severe rotational deformities.[28,29]

Lateral bending radiographs may be used to predict a curve's flexibility but do not necessarily predict the degree of surgical correction obtained at surgery. Flexion and extension views are useful in assessing the flexibility of a sagittal plane deformity and may reveal levels with abnormal motion or instability. Traction films, push-prone films, and supine films taken with a bolster under the apex of a kyphosis can be used to assess flexibility or response to a corrective maneuver.

If radicular pain or neurologic findings are present, an advance three-dimensional imaging should be performed. In the setting of a major spinal deformity, we prefer CT/myelography over MRI because the latter test is frequently difficult to interpret due to the nonorthogonal nature of the deformed spine. It is particularly important to assess sites of actual or potential cord compression prior to surgery when corrective maneuvers are planned that might compromise the neural elements. Adults with spinal deformities involving the lumbar spine often benefit from MRI of this region to assess the health or degeneration status of the lower lumbar disks. Unfortunately, there is a poor correlation between the appearance of the lower lumbar disks on imaging studies and the presence of pain, and therefore provocative diskography has been useful in our hands to assess the lumbosacral region if fusion to this area is contemplated.

Ancillary Tests Including Diskography and Facet Blocks

The senior author experienced a 30 to 35% rate of persistent pain even after attaining a solid fusion in adult deformity patients in his early years of practice. However, in recent years, the number of adult deformity patients with persistent pain has declined. One reason for this change is believed to be the use of diskography to assess for painful segments that should be included in the fusion.[30–32] Specifically, the L3-L4, L4-L5, and L5-S1 levels are generally assessed with diskography and the information gained is used to help in planning the distal fusion level (**Figs. 21–1A, 21–1B, and 21–1C**).

Facet blocks are also occasionally employed to assist in defining painful segments (especially L5-S1) that should be included in the fusion. At the lumbosacral junction, the sacrum is included in the fusion if diskography produces significant pain and facet blocks relieve the pain. However, a degenerated segment that is not painful with diskography or relieved with facet blocks is not incorporated into the fusion.

♦ Nonoperative Treatment

The basic approach to nonoperative care for adult deformity patients is similar to the treatment of nondeformity patients. Useful modalities include exercise, patient education, nonsteroidal anti-inflammatory drugs (NSAIDs), and activity modifications. It is important for the patient to understand that conservative care will not prevent curve progression but may improve function, stamina, and quality of life. In particular, low-impact aerobics, cycling, and swimming are useful in older adults with painful spinal deformities. Active exercises also help to prevent osteoporosis, a condition that serves to worsen an existing spinal deformity. Patients at risk for osteoporosis should be screened with bone densiometry and started on pharmacologic treatment when low bone density is documented.

Although there is no evidence to suggest that bracing will prevent curve progression in adults, the use of orthotics may occasionally be helpful. Orthotic choices range from soft corsets to rigid, underarm braces carefully fitted to the patient's deformity. Unfortunately, patient tolerance with rigid bracing is generally poor.

♦ Surgical Treatment

Indications for Surgical Treatment

General

The general indications for surgery in the adult deformity patient include (a) persistent pain, unresponsive to conservative measures; (b) significant deformity progression; or (c)

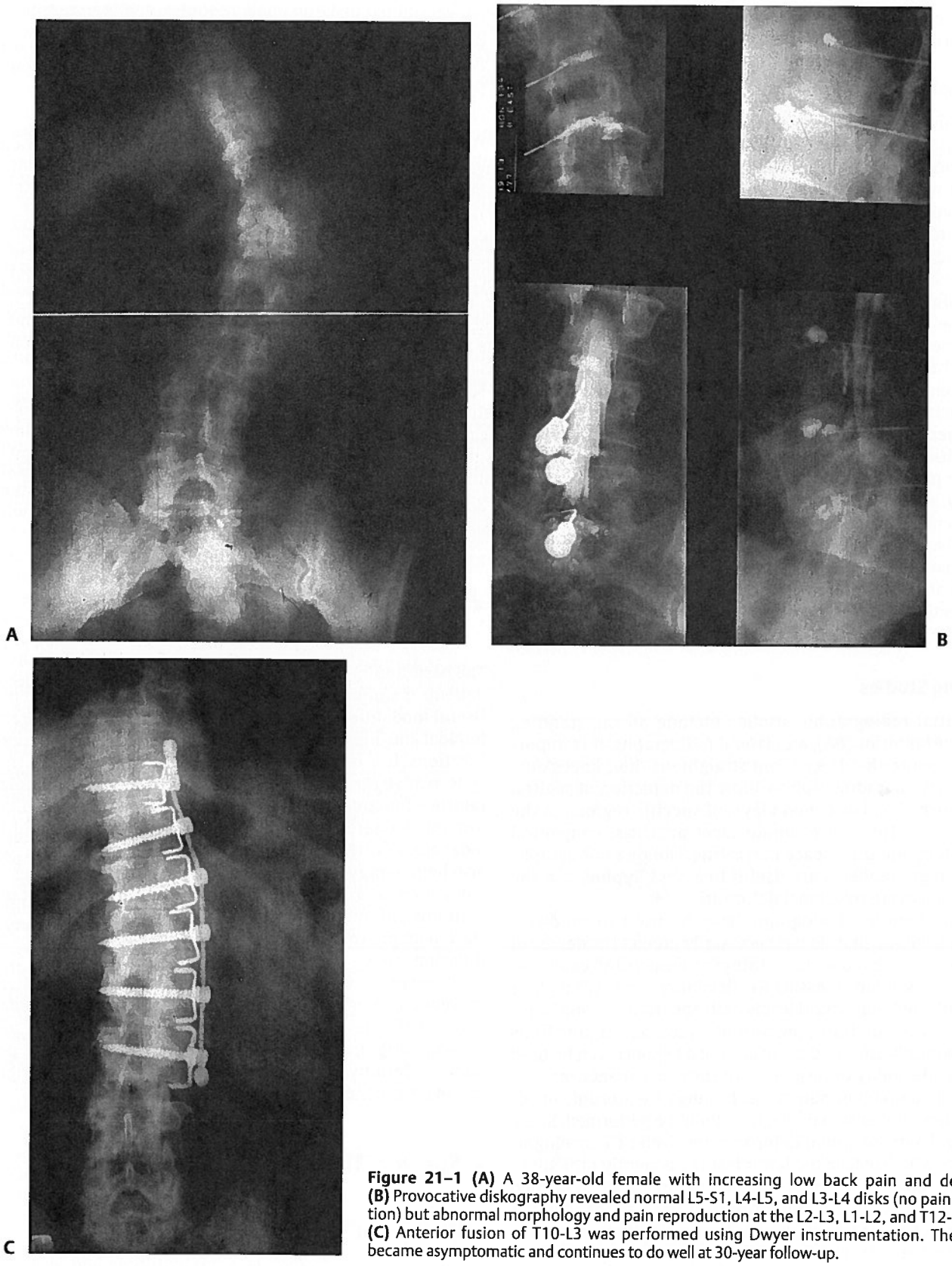

Figure 21–1 **(A)** A 38-year-old female with increasing low back pain and deformity. **(B)** Provocative diskography revealed normal L5-S1, L4-L5, and L3-L4 disks (no pain on injection) but abnormal morphology and pain reproduction at the L2-L3, L1-L2, and T12-L1 levels. **(C)** Anterior fusion of T10-L3 was performed using Dwyer instrumentation. The patient became asymptomatic and continues to do well at 30-year follow-up.

neurologic involvement. A lesser concern that may be considered is the perception of very poor cosmetic appearance on the part of the patient.

Pain

Pain is the most common indication for surgical intervention in adults and is the major factor for which surgery is considered in ~85% of adult deformity surgical cases. Unfortunately, determining the exact sources of pain and predicting pain relief after surgery is a great challenge. As with other painful conditions of the spine, the more certain a surgeon can be as to the cause of pain, the more likely surgical intervention is to be successful.

Progressing Deformity

The exact indications for surgery in the asymptomatic adult deformity patient with evidence of curve progression remain controversial. In most cases, adult deformity patients with significant curve progression will have other symptoms such as pain. It is our opinion that two groups of patients are particularly good candidates for surgery as a result of curve progression. The first group is the young adult (generally below the age of 35 years) with a thoracolumbar curve that has progressed beyond ~45 degrees. Such a patient is at very high risk for continued curve progression and will generally develop pain and even frank kyphoscoliosis in time as the lumbar region loses lordosis due to degenerative disease. To prevent this from happening and to avoid a more difficult future operation, surgical intervention is warranted. These patients are often amenable to a single approach (anterior or posterior) as opposed to a circumferential approach, which will likely be required in the future as the curve worsens and becomes more rigid.

The second group where early surgery is warranted is the younger patient with significant truncal imbalance (3 to 4 cm or more) especially when the major curve extends to L3 or L4 and is accompanied by a compensatory curve at L4, L5, or sacral level. In this instance, a more limited fusion of the lower curve may allow the restoration of spinal balance and avoid further decompensation, which is inevitable without treatment. In this instance, the patient should be aware that extension of the fusion may be required at a later date. The average degree of correction of the major curve in the experience of the senior author has been more than 40%.

Neurologic Deficit

Neurologic deficits or neurologic symptoms are occasionally seen as deformities progress and degenerative stenosis ensues and are an indication for surgical intervention. In early series dating back to 1979, very few patients undergoing surgery for spinal deformity required decompression.[1,33] However, older patients with spinal stenosis may require decompression if focal neural compression is causing symptoms or places a region of the neural axis at risk for compromise during a deformity correction maneuver. In a more recent series of 101 adults with idiopathic scoliosis treated in the late 1980s, 22 required decompression for neural compression.[34]

Cosmesis

Cosmesis is generally thought to be an uncommon indication for surgery in the adult scoliosis patient. However, from the perspective of the patient, cosmetic improvements may play a significant role in their desire for surgical treatment of the spinal deformity. In a 100-patient series, 10 years after spinal fusion for pain, many reported that body image and cosmesis had played a significant role in their decision to have surgery even though this was rarely discussed prior to surgery.[35] Careful discussion of the patient's goals with treatment are important prior to surgery. In certain cases, the poor aesthetics associated with a severe, poorly balanced spinal deformity may be a source of major concern to the patient and should be a consideration in the decision for surgery. The spine surgeon in this situation should spend ample time discussing the risks and benefits of surgical intervention and provide a realistic picture of the expected outcome to ensure that the patient understands the magnitude of the surgery that will be required to correct the deformity. With modern techniques utilizing posterior segmental instrumentation, cosmetic improvements can be expected for poorly balanced curves. In addition, thoracoplasty (partial rib excision over four to six levels) may be used as an additional technique to diminish an unsightly rib hump. When performing thoracoplasty, the rib excision should extend to the posterior axillary line to avoid a sharp, angular protrusion at the ends of the resected ribs.

Surgical Techniques

Surgical techniques for spinal deformity correction have changed significantly over the years as improved instrumentation systems became available. Posterior segmental instrumentation systems now provide greater control, correction, and ease of postoperative care compared with Harrington instrumentation. In adult deformity surgery, the single most important factor is to achieve proper sagittal balance at the conclusion of the operation. This allows the patient to achieve neutral positioning in a standing position with their head balanced over their trunk and their trunk balanced over their pelvis. Such a position lowers the energy expenditure of upright posture and is effective in limiting the pain and fatigue seen in patients with thoracolumbar kyphosis and positive sagittal balance.

Although thoracoscopic and minimally invasive techniques are making inroads in pediatric deformity surgery, these techniques have not been validated for adult scoliosis where the magnitude of the spinal deformities and the rigidity of the curves make treatment with such techniques more difficult. The approach to specific curve types will be discussed.

Thoracic Deformities

Compared with lumbar deformities, the indication for treatment of thoracic deformities is more often due to progression of the deformity and/or cosmesis. The surgical techniques employed in this region of the spine are similar to those used for adolescent scoliosis surgery. The use of thoracoplasty is often helpful in adults with rigid deformities, where a limited correction can be achieved. Patients with

Figure 21–2 Multiple pedicle screw construct in adult scoliosis patient.

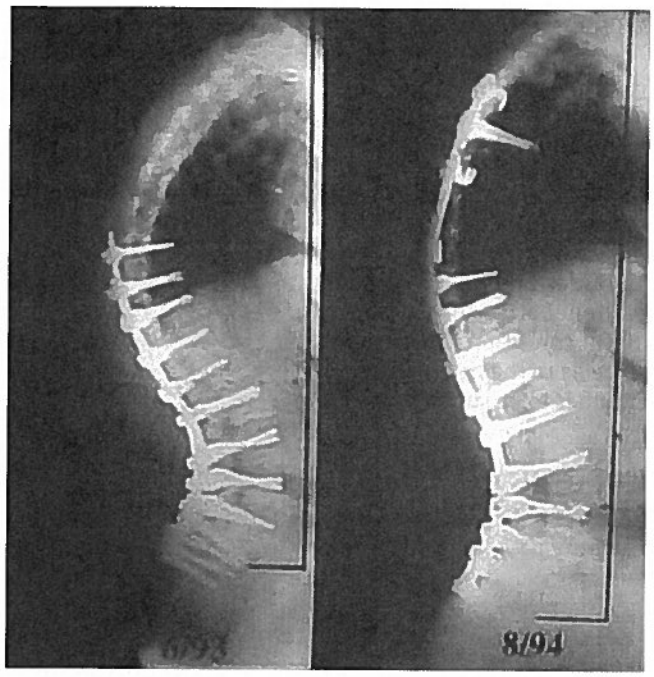

Figure 21–3 Patient with junctional kyphosis due to stopping of fusion over the apex of the thoracic kyphosis. The patient was revised to extend the fusion above the apex of the kyphosis.

hypokyphosis may benefit from an anterior release assuming their pulmonary function is acceptable. Alternatively, wide facetectomies with multiple Smith-Peterson type osteotomies can be used as a posterior column shortening technique to diminish excessive kyphosis in the thoracic region.

Although the use of screws versus hooks as spinal anchors continues to be debated, it is generally our strategy to use multiple screws in the thoracic region **(Fig. 21–2)**. In the older adult, the use of pedicle screws has resulted in a lower rate of anchor dislodgment and lamina fracture compared with hooks constructs. To prevent the development of kyphosis proximal to the fusion, the constructs usually begin at the T2 or T3 level. By employing pedicle screws at the upper segment, the ligamentum flavum and interspinous ligaments between the upper fused vertebrae and the supra-adjacent level can be spared. We believe that this helps to prevent the development of a junctional deformity **(Fig. 21–3)**. At the current time, autologous iliac crest bone graft continues to be our preferred graft source for fusion, although bone graft extenders and alternatives are growing in popularity. Rigid, severely rotated spines with a curve magnitude of 70 degrees or more generally require an anterior release prior to the posterior segmental instrumentation to allow adequate correction of the deformity.

Lumbar/Thoracolumbar Curves

In the lumbar spine, symptoms of pain and hypolordosis are more frequently the indication for surgery. Therefore, pain relief and restoration of balance are major considerations with the treatment of lumbar curves. The choice of surgical approach depends largely on the degree of flexibility of the curve and the location of pain generators. If the curve is limited to the lumbar region, the fusion may begin proximally at about T10, to avoid ending the fusion at the thoracolumbar junction (T12-L1), which invites the onset of a junctional kyphosis. Deformity fusions should not end in the middle of a kyphotic region (midthoracic spine), thus thoracolumbar curves often require fusion to the upper thoracic region.

We classify lumbar curves into four groups depending on the curve flexibility and the status of the lumbosacral junction. Group 1 patients have a flexible curve that does not require fusion to the sacrum. Group 2 patients have more rigid deformities often with kyphosis or hypolordosis but have a well-maintained lumbosacral joint (healthy, painless disk and minimal deformity) and thus do not require fusion of the sacrum. Group 3 patients have flexible curves but a painful or deformed lumbosacral joint (15 degrees or more of scoliosis at L5-S1), which require fusion to the sacrum. Group 4 patients are the most challenging curves because they have rigid, generally kyphotic curves and require fusion to the sacrum. As the population ages, this later group appears to be increasingly common.

Treatment for group 1 patients can generally be achieved with an isolated anterior or posterior technique using segmental instrumentation. In younger adults (ages 20 to 40) without contraindications, we believe that the morbidity is

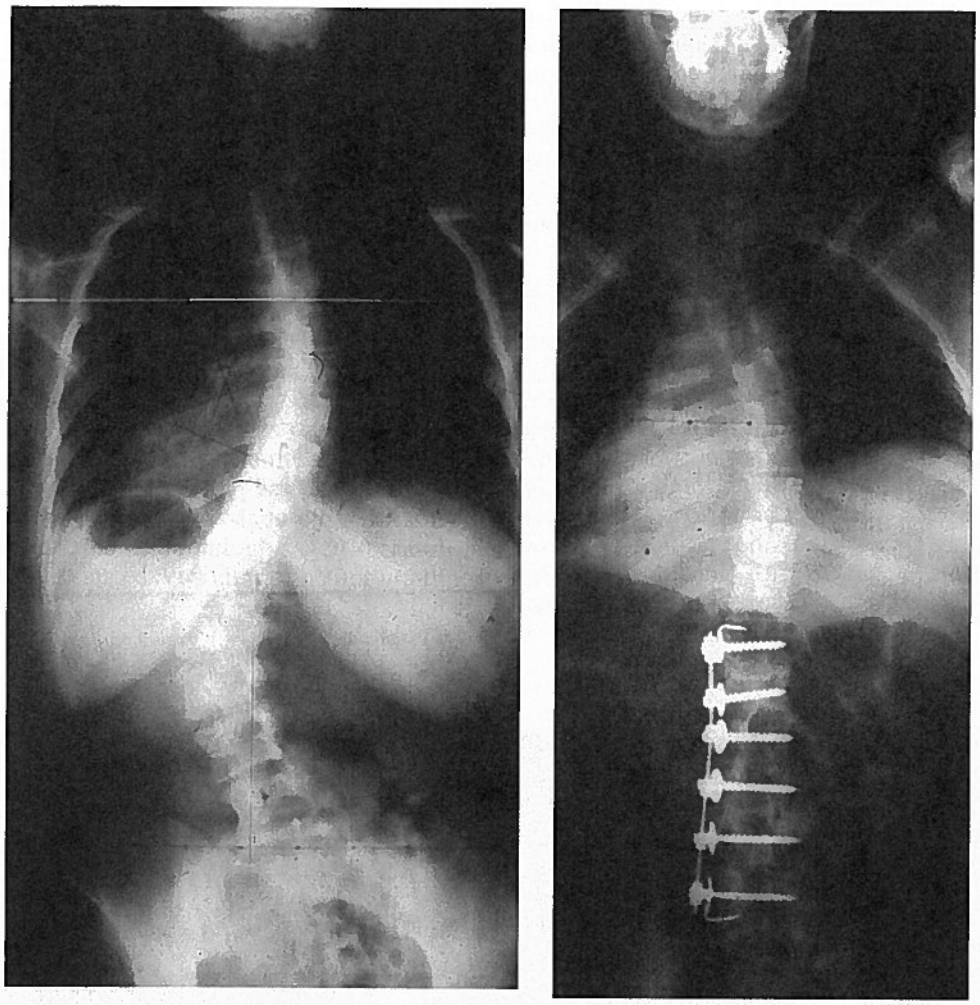

A B

Figure 21–4 **(A)** A 44-year-old female with painful, progressive, flexible thoracolumbar deformity. Although L5 appears oblique to the sacrum, bending radiographs reveal horizontalization of L5. Diskography of L5-S1 disk demonstrates painless injection and normal morphology. **(B)** Anterior Zielke instrumentation and fusion of T12-L5 with excellent correction and horizontalization of L5. Although degeneration of L5-S1 disk developed radiographically over time, she remains asymptomatic.

less from the anterior approach **(Figs. 21–4A and 21–4B).** In this group, the risk of incisional hernia, abdominal bulge, weakness, and umbilical shift appears to be less likely than in older patients. Also, older patients often have osteopenic bone, which limits the purchase of vertebral body fixation and may allow recurrence of the deformity as fixation is lost in the postoperative period.

In adults, the entire curve should be fused if an anterior approach is elected. Once the levels to be fused have been exposed, the disk spaces are cleared, including the cartilaginous end plates, back to the posterior longitudinal ligament. Complete disk exposure is essential so that an accurate angle of insertion of the screws can be achieved. If at all possible, the screws should be angled toward the contralateral junction of the pedicle and vertebral body. To ensure that the opposite cortex is penetrated, a depth gauge may be used to measure the disk space depth. Adding 2 mm to this depth provides a good rule of thumb for selecting screw length. Cooled methylmethacrylate bone cement can be used to enhance fixation in osteopenic bone or to augment the ends of the construct where the stresses are higher. Autogenous rib grafts are used for fusion and can be mixed with allograft bone as needed to achieve an adequate bone graft volume for the number of levels fused. To avoid creating kyphosis as the convex side of the spine is compressed, a structural graft should be placed in the anterior portion of the disk spaces. Rib struts, cages, or cortical allograft can be used for this purpose.

Kostuck et al. reported their results with the first 57 patients treated with Zielke instrumentation. Initially, a 62% curve correction was achieved, with a final correction loss of only 4 degrees. No pseudarthroses were encountered. The noninstrumented proximal thoracic curves improved by 28% and remained stable over the 2-year follow-up period. Correction in the frontal plane was 60% in patients over 50 years.[36]

Group 2 patients have rigid, often kyphotic lumbar spines, and thus an anterior approach is necessitated for release of the deformity. In most cases, such a deformity requires a combined approach with a release of the anterior spine followed by posterior segmental instrumentation and fusion. Both approaches may be done on the same day or the procedures may be staged, depending on the patient's age, medical status, and the blood loss from the first portion of the procedure.

Group 3 patients have flexible curves but require fusion to the sacrum, generally due to the presence of a painful joint at the L5-S1 level. In adults, posterolateral fusion alone to the sacrum is associated with a high rate of pseudarthrosis. Therefore, an anterior fusion at the lower two segments is generally advisable. In cases with adequate flexibility, the posterior fusion may be performed first, providing deformity correction and fixation to the sacrum. This can be followed (generally the same day) by an anterior interbody fusion using structural grafting of the lower two vertebral segments. The senior author also advocates the use of anterior instrumentation in most cases at the L4-L5 and L5-S1 levels **(Figs. 21–5A to 21–5C).**

Group 4 patients have rigid deformities, often associated with lumbar kyphosis, which require fusion to the sacrum. These cases require circumferential surgery, which is often staged for older patients. In the first stage, the anterior spine is released, morcelized graft is placed in the upper lumbar segments, and structural interbody grafting is performed at the L4-L5 and L5-S1 levels. In the second stage, the posterior spine is fused and correction is gained with posterior segmental pedicle fixation. During this stage, the spine must be derotated and lumbar lordosis must be regained **(Figs. 21–6A to 21–6D).**

In the lumbar region of the spine, segmental pedicle screw constructs have largely replaced hooks and sublaminar wire constructs.[11,12] Pedicle screws offer several advantages including rigid fixation, improved ability to derotate curves, and the ability to use the pedicle for fixation even in the absence of the lamina.

Fusions to the Sacrum

In adolescents under the age of 20 years, fusion to the L4 or L5 segment results in a high rate of subsequent painful disk degeneration within 10 years.[37] However, primary fusion to the sacrum poses a special challenge to the spinal deformity surgeon. Kostuik and Hall reported loss of lumbar lordosis in ~50% and pseudarthrosis in 40% of patient undergoing fusion to the sacrum.[36] Boachie-Adjei et al. also experienced a high rate of pseudarthrosis (41%) at the lumbosacral junction in adults fused anteriorly and posteriorly with Luque-Galveston instrumentation.[38]

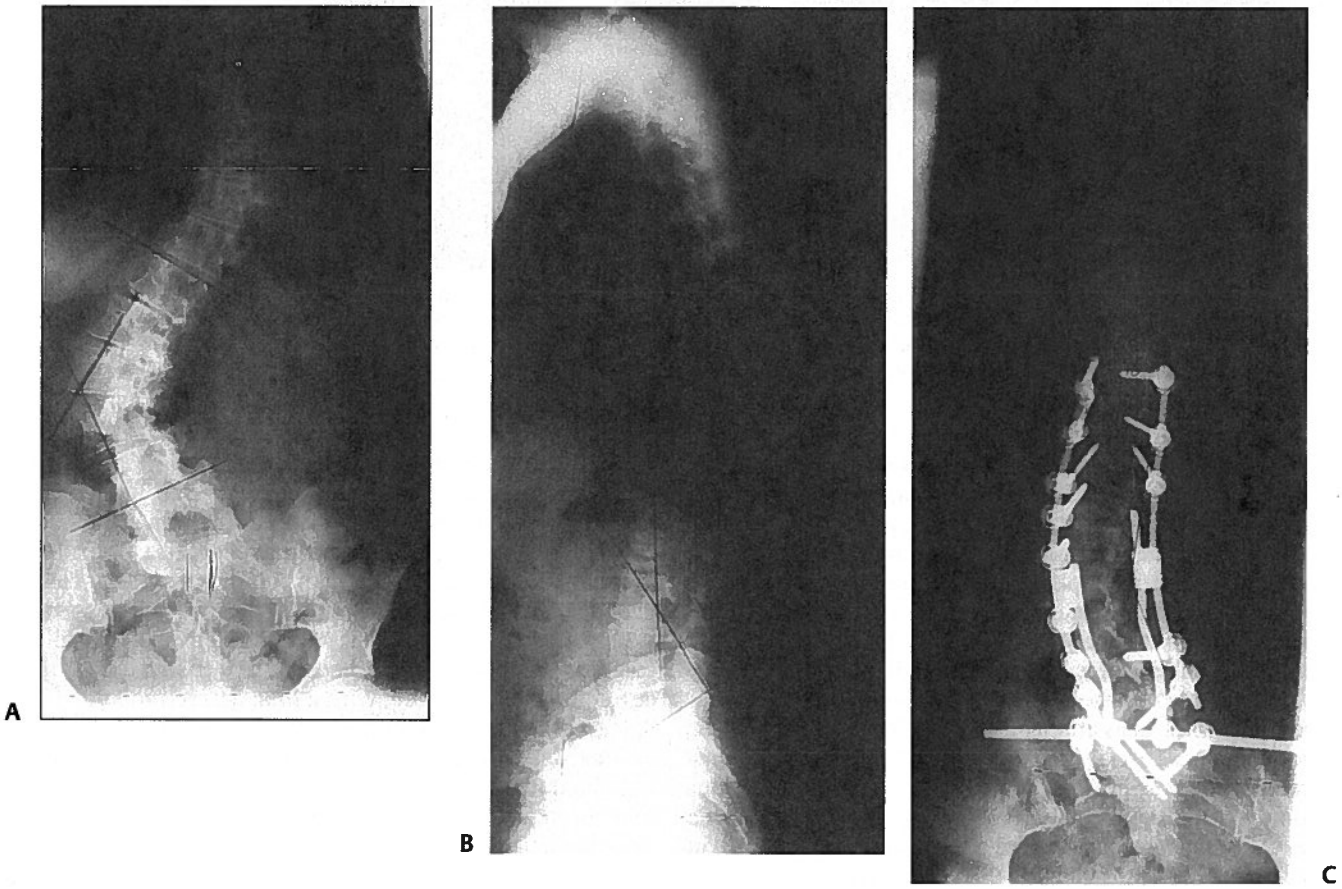

Figure 21–5 **(A)** Posteroanterior and **(B)**lateral radiograph of a 66-year-old female with progressive lumbar deformity and incapacitating back pain. Other medical problems include hypertension and hypothyroidism. Diskography was positive for severe, reproduction of back pain at the L5-S1 level. **(C)** Posteroanterior and lumbar radiograph of surgical result. Patient underwent a staged procedure with an anterior release through a thoracoabdominal approach. Morselized graft was placed at the T12-L5 levels and a structural graft was used at the L5-S1 level. Lag screws were placed at the L5-S1 level to enhance the construct rigidity in this region. At the second stage, the patient underwent posterior fusion from T10 to the sacrum with pelvic fixation including sacral screws in S1 and a trans-iliac bar. Morcelized autogenous bone was used in the posterior region of the spine.

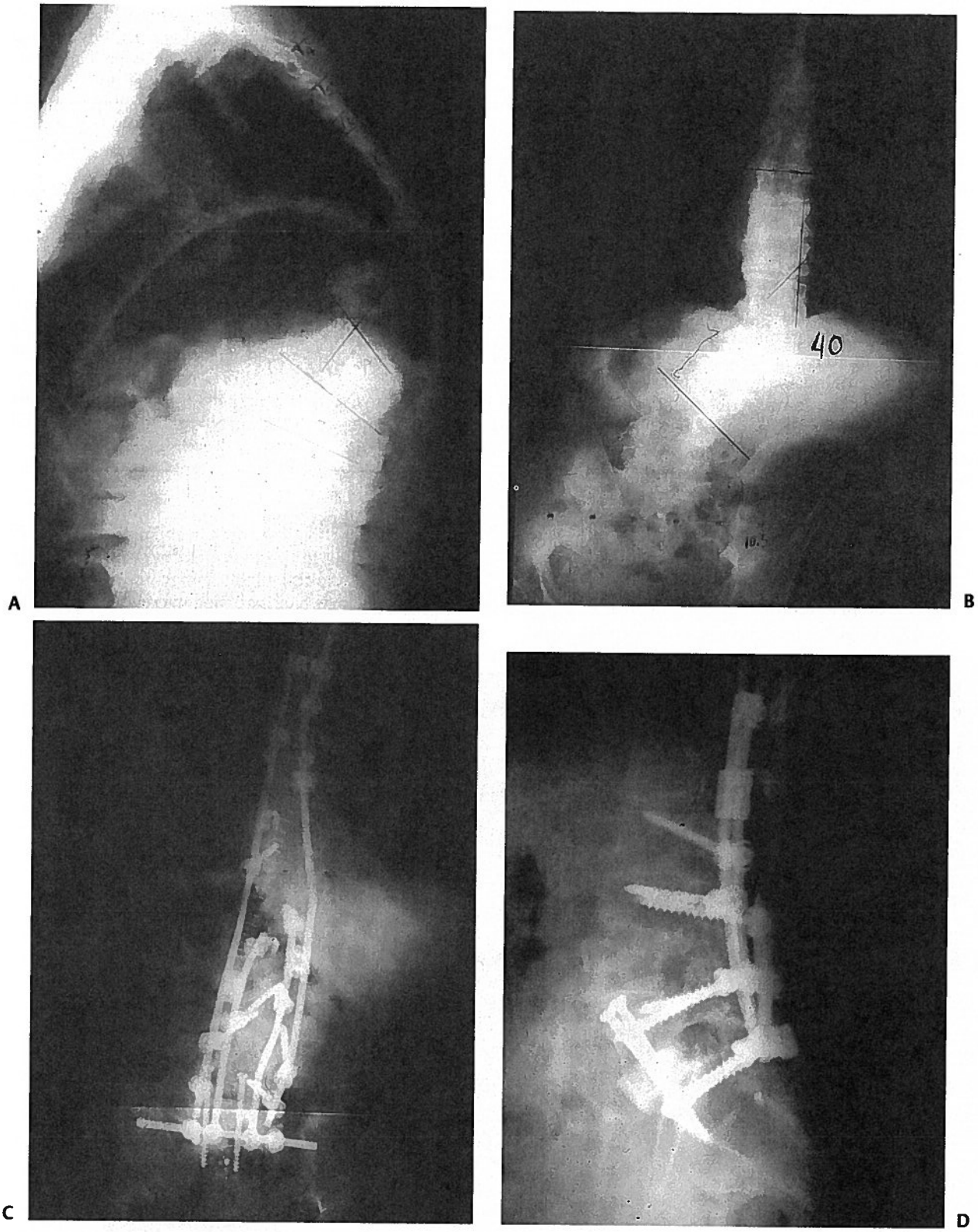

Figure 21–6 **(A, B)** A 63-year-old female with progressive deformity of the thoracolumbar spine with rigid kyphosis and sagittal and frontal imbalance. **(C, D)** Postoperative radiographs reveal excellent restoration of sagittal balance after an osteotomy at the kyphotic segment and fusion to the sacrum. Trans-iliac bar and femoral ring allograft are used in conjunction with anterior lag screws at the L5-S1 level.

Due to the high rate of pseudarthrosis and other complications, the distal stopping point for many fusions remains controversial with some surgeons advocating ending the construct proximal to the sacrum whenever possible.[39] Unfortunately, there are many situations where fusion to the sacrum is clearly required. For instance, symptomatic spondylolisthesis at L5/S1 requires lumbosacral fusion. A more common reason to include the sacrum in an adult deformity operation is the presence of an oblique take-off of the L5 vertebra (greater than 15 degrees) or the presence of severe and symptomatic degenerative disk disease at the L5-S1 level in an adult requiring fusion to the lower lumbar spine. Another indication includes fixed sagittal imbalance, where lumbosacral fusion is required to reconstruct lumbar lordosis. Although concern with subsequent degeneration of the sacroiliac joints after lumbosacral fusion has been raised, this has not been a major problem in the experience of the senior author where only 2% of patients were noted to complain of pain in the sacroiliac joint region and very few have required a sacroiliac fusion.

Fortunately, the advent of segmental instrumentation, in conjunction with the Galveston technique for iliac fixation, substantially improved the maintenance of lordosis and enhanced rates of fusions at the lumbosacral junction.[11,12] In recent years, the use of structural grafting and anterior instrumentation of the lumbosacral junction have led to further improvements in the fusion rates in this difficult region of the spine.[40] Interbody support is mandatory, in our view, when performing lumbosacral fusion in the adult deformity patient. Although this could theoretically be achieve through a posterior approach using a transforaminal or posterior interbody fusion, we find that anterior interbody lumbar fusion provides better structural support of the lumbosacral segment and minimizes the blood loss and time necessary to achieve interbody fusion of the segment.

Significant improvements in lumbosacral fixation are now possible using multiple points of fixation to the sacrum or pelvis. Examples of sacropelvic constructs include four sacral screws, Jackson intrasacral rods **(Fig. 21–7A, B)**, iliac screws or rods, or the use of a modified transiliac bar **(Fig. 21–6C)**. In addition to posterior fixation, the senior author has advocated the use of anterior fixation at the lumbosacral junction with lag screws, which enhanced construct stiffness in flexion and extension **(Figs. 21–5 and 21–6)**. The addition of anterior fixation has improved the success rate of structural interbody fusion of the lumbosacral junction compared with structural allografts alone.

Revision Surgery

Some of the most challenging cases in the deformity realm are revision operations in the adult deformity population. In many cases, fixed sagittal plane imbalance requires osteotomies through areas of prior fusion mass where anatomic

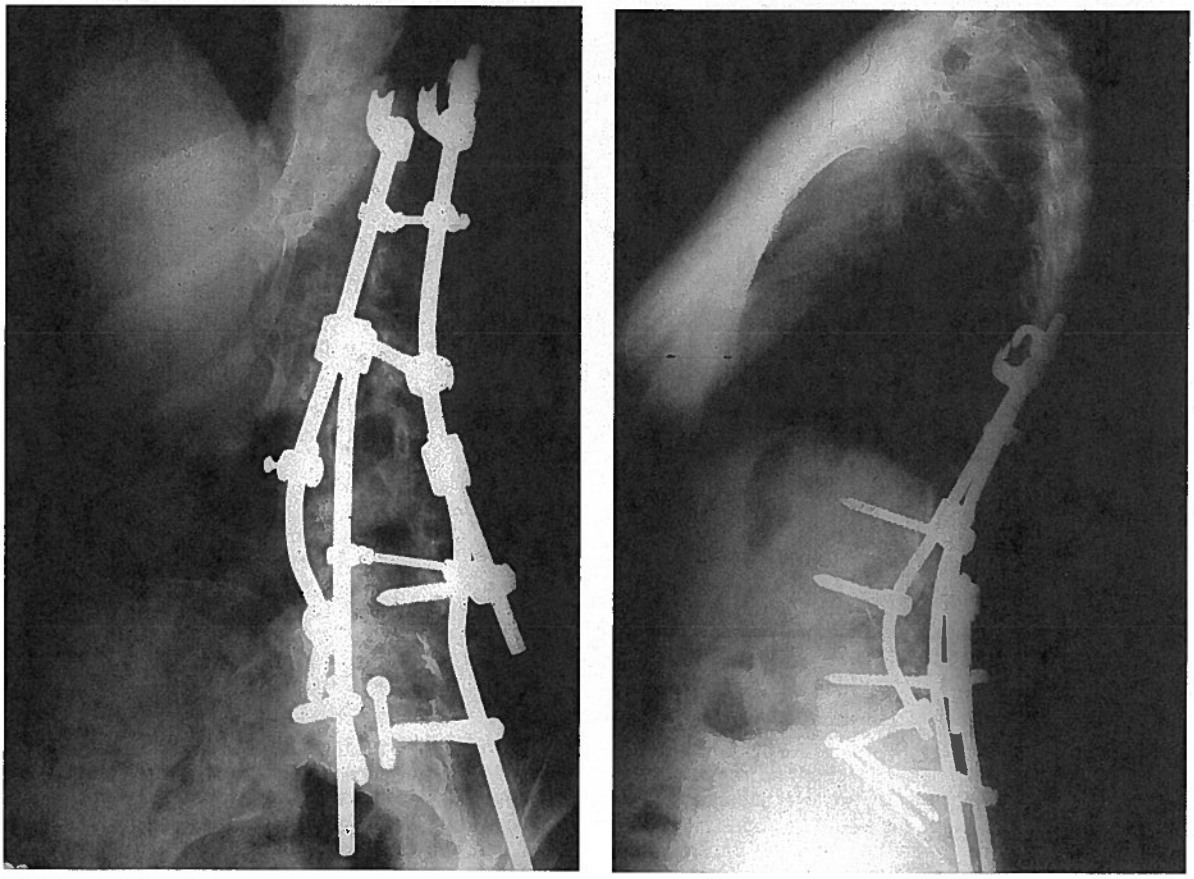

A B

Figure 21–7 (A, B) Radiographs of construct with Jackson intrasacral rod technique for sacropelvic fixation. Anterior structural grafting is used to augment construct.

landmarks for instrumentation are obscured. Frequently, dural adhesions increase the risk of dural tear during decompressive surgery. Finally, these operations are often prolonged with large amounts of blood loss, thus increasing the risk of infection or medical complications.

The approach to revision surgery in the lumbosacral region is dictated by whether or not the lumbosacral joint must be included in the fusion. When the lumbosacral joint is not involved, an anterior and posterior fusion with instrumentation may suffice. This is done with anterior instrumentation, structural interbody grafting, and posterior pedicle fixation. To improve lordosis, a pedicle subtraction or Smith-Peterson–type osteotomy may be required. Pedicle subtraction osteotomies through the midlumbar region or fusion mass at about L3 are a powerful way to achieve lumbar lordosis. Multiple points of fixation on each side of the osteotomy must be achieved to lessen the risk of construct failure.

The senior author reviewed 81 scoliotic patients who had undergone a mean of two prior spinal procedures requiring extension of a prior fusion to the sacrum between 1975 and 1992.[32] The average follow-up in this group was 137 months. The average age in this cohort was 48 years. Most of the prior fusions ended in the mid or lower lumbar region. Decompression was required in 32% of the patients. There was an evolution of treatment over this time period that was reflected in the improved results in recent years.

Between 1975 and 1978, six patients underwent posterior Harrington instrumentation with extension of the fusion to the sacrum. Five of these six patients developed pseudarthroses. This experience in part led to the recognition that distraction instrumentation even with prolonged postoperative recumbency was not a satisfactory solution to this problem. Between 1978 and 1982, 18 additional patients were treated with anterior and posterior fusions using a variety of instrumentation systems with a dramatically improved pseudarthroses rate of 11%. Between 1986 and 1992, 32 additional patients were treated with pedicle screw systems in conjunction with anterior fusion and instrumentation with two 6.5-mm lag screws. This approach produced a pseudarthrosis rate of just 6%. Since 1990, an additional 200 such cases have been performed with similar satisfactory results.

Intraoperative Management

Adult scoliosis correction is a major operation and often associated with significant blood loss and fluid shifts. The anesthesiologist should be experienced in the care of such patients and should be alerted to the anticipated requirement for blood productions. Intraoperative fluid management is crucial due to the risk of increased intensive care stay in patients overloaded with crystalloid fluids during spinal deformity surgery.[41]

Blood, in the form of packed red cells, should be administered early in the operative procedure, certainly by the time the estimated loss reaches 800 to 1000 cc. The use of cell-salvage is advocated; however, large volumes of cell-salvaged blood may lead to coagulopathy due to loss of clotting factors. Therefore, the team must be ready to provide replacement of coagulation factors for cases with a blood loss in the 1800 to 2000 cc range. These can be supplied through the transfusion of fresh frozen plasma, calcium, and, in some cases, platelets.

Modern spinal cord monitoring has become routine during deformity correction and appears to decrease the risk of neurologic injury. Somatosensory evoked potentials, motor evoked potentials, and free-running EMG are all useful in the hands of a competent neurophysiologist during surgery. Motor evoked potentials appear to have the highest sensitivity for the early detection of intraoperative neurologic compromise during deformity corrective maneuvers. Stimulated EMG has been shown to be useful when placing transpedicular screws. This technique depends on the high impedance of cortical bone and can be used to confirm screw path integrity by documenting adequate thresholds between the pedicle site and the surrounding soft tissues.

♦ Postoperative Care

Postoperatively, a neurologic assessment of lower extremity function should be documented as soon as feasible. We do not perform a Stagnara interoperative wake-up test unless there has been an aberration in intraoperative spinal cord monitoring.[28,29,42]

Patients are generally admitted into an intensive care unit for the first 24 to 48 hours. Patients are encouraged to mobilize to a chair and begin ambulation as soon as possible after surgery. Urinary catheters are removed and oral liquids are begun as soon as abdominal bowel sounds are present. Until that time, patients are only allowed ice chips to moisten their mouths, thus reducing the risk of prolonged abdominal ileus. Hospital stays depend on the patient's age, comorbidities, and the presence of any perioperative complications. Younger adults are generally discharged within 5 to 7 days of surgery, while older adults often require longer stays especially when the procedure has been staged. The senior author does not use bracing except in cases where the instrumentation purchase is suboptimal. Abdominal binders are used after anterior abdominal approaches.

Patients are allowed to drive in general once they have eliminated the use of narcotics. Return to work varies widely from 6 weeks to 1 year. Full activities including athletic endeavors are generally allowed 6 to 12 months postoperatively assuming the radiographs show adequate evidence of consolidation.

It has been our practice to see patients for follow-up visits at the 6 weeks, 3 months, 6 months, 9 months, 12 months, 18 months, and 2 years postoperative time points. The patients are then advised to follow up every 1 to 2 years.

♦ Outcomes

Kostuik and Musha studied 110 adult scoliosis patients at an average postoperative follow-up of 12.5 years. Although most noted back pain, it was rarely disabling. Patients married at a lower rate than the general population but experienced no childbearing problems as a result of the spinal deformity. Seventy percent of this cohort participated in recreational activities. Only 11% were receiving disability payments at the

time of follow-up. Eighty-five percent of this cohort reported that given the results of their operation, they would elect to undergo surgery again for the same condition; 64% reported that surgery had fully met their goals and expectations.[43,44]

Jackson et al. reported a similar incidence of pain in 197 adults with idiopathic scoliosis when compared with a control group of 180 adults without deformity, although the severity of the pain was greater in the adult deformity patients. Pain was especially noted in adults with lumbar curves or lumbosacral fractional curves and correlated with the magnitude of the deformity. At an average follow-up of 5 years after corrective surgery, 83% of the patients reported early, significant relief of pain.[45]

Gotze et al. assessed quality of life and back pain in 82 adults an average of 16.7 years after corrective surgery for a spinal deformity and compared the results with age-matched controls from the healthy population. No significant differences in the physical component of the SF-36 scale were found, and the majority (79%) reported either no or only occasional back pain. Interestingly, adult deformity patients achieved significantly lower scores on the psychological component of the SF-36 scales in the areas of vitality, general mental health, and role activities. Surgical variables including the type of curve, time since surgery, or extent of the fusion did not correlate with outcome. However, 40% of this cohort was legally defined as severely handicapped under the German system, suggesting that the disability status may affect the psychological status of adults after corrective surgery.[46]

Kumar et al. studied incidence of adjacent segment degeneration after fusions for spinal deformities in 83 patients. Overall, 36% demonstrated radiographic changes in adjacent segments. No difference was noted between those who had posterior-only versus anterior/posterior fusions. Patients with good balance in the sagittal plane and normal sacral inclination had significantly less adjacent level changes.[47]

♦ Conclusion

The adult deformity population represents a diverse and challenging group of patients that require the full set of skills of an experienced spinal reconstructive surgeon. Fortunately, with a methodical approach to these patients and careful selection, rewarding results can be achieved in most patients. Surgery in this population is challenging and requires an experienced team to manage the many technical and medical issues that arise. The single most important concept in adult deformity reconstruction is to achieve proper sagittal plane alignment. Other keys are to use structural interbody support at the lower lumbar region and to ensure stable fixation using segmental instrumentation. When fusing to the sacrum, a minimum of four points of fixation should be achieved. Adult curves are generally stiff, and the surgeon should strive more for balance and symptom relief than correction.

References

1. Kostuik JP, Israel J, Hall JE. Scoliosis surgery in adults. Clin Orthop Relat Res 1973;93:225–234
2. Ponsetti IV. The pathogenesis of adult scoliosis. In: Zorab PA, Cansation E, Livingston S, eds. Proceedings of the Second Symposium on Scoliosis. Edinburgh; Livingstone, 1968
3. Reckling C, Ogilvie J, Cohen M. Lumbar fusions in the elderly. Paper presented at: Scoliosis Research Society, 28th Annual Meeting; September 18–23, 1993; Dublin
4. Robin GC, Span Y, Steinberg R, et al. Scoliosis in the elderly. A follow-up study. Spine 1982;7:355–359
5. Visscher W, Lonstein JE, Hoffman DA, Mandel JS, Harris BS III. Reproductive outcomes in scoliosis patients. Spine 1988;13(10):1096–1098
6. Nachemson A. A long-term follow-up study of non-treated scoliosis. Acta Orthop Scand 1968;39:466–476
7. Dickson JH. An eleven-year clinical investigation of Harrington instrumentation. A preliminary report on 5/8 cases. Clin Orthop Relat Res 1973;93:113–130
8. Schwab F, Dubey A, Pagala M, Gamez L, Farcy JP. Adult scoliosis: a health assessment analysis by SF-36. Spine 2003;28(6):602–606
9. Dwyer AF. Experience of anterior correction of scoliosis. Clin Orthop Relat Res 1973;93:191–214
10. Allen BL Jr, Ferguson RL. The Galveston technique for L-rod instrumentation of the scoliotic spine. Spine 1982;7:276–284
11. Luque ER. The anatomic basis and development of segmental spinal instrumentation. Spine 1982;7:256–259
12. Luque ER. Segmental spinal instrumentation for correction of scoliosis. Clin Orthop Relat Res 1982;163:192–198
13. Zielke K, Stunkat R, Beujean F. Ventrale derotations-spondylodese. Arch Orthop Unfallchir 1976;85:257–277
14. Cotrel Y. Instrumentation for Surgery of the Spine. Freud Publishing House, Ltd; 1986.
15. Cotrel Y, Dubousset J, Guillaumat M. New universal instrumentation in spinal surgery. Clin Orthop Relat Res 1988;227:10–22
16. Shands AR Jr, Eisberg HV. The incidence of scoliosis in the state of Delaware. J Bone Joint Surg Am 1955;37:1243–1249
17. Kostuik JP, Bentivoglio J. The incidence of low back pain in adult scoliosis. Spine 1981;6:268–273
18. Weinstein SL, Ponsetti IV. Curve progression in idiopathic scoliosis. J Bone Joint Surg Am 1983;65:447–455
19. Fowles JV, Drummond DS, L'Ecuyer S, Roy L, Kassab MT. Untreated scoliosis in the adult. Clin Orthop Relat Res 1978;134:212–217
20. Weinstein SL, Zavala DC, Ponseti IV. Idiopathic scoliosis: long-term follow-up and prognosis in untreated patients. J Bone Joint Surg Am 1981;63(5):702–712
21. Nachemson A. A long-term follow-up study of non-treated scoliosis. J Bone Joint Surg Am 1969;50:203–204
22. Nilsonne U, Lundgren KD. Longterm prognosis in idiopathic scoliosis. Acta Orthop Scand 1968;39:455–465
23. Guigui P. Spinal deformity in the adult. Presse Med 1999;28(37): 2075–2085
24. Schwab FJ, Smith VA, Biserni M, Gamez L, Farcy JP, Pagala M. Adult scoliosis: a quantitative radiographic and clinical analysis. Spine 2002; 27(4):387–392
25. Engsberg JR, Bridwell KH, Reitenbach AK, et al. Preoperative gait comparisons between adults undergoing long spinal deformity fusion surgery (thoracic to L4, L5, or sacrum) and controls. Spine 2001; 26(18):2020–2028
26. Deviren V, Berven S, Kleinstueck F, Antinnes J, Smith JA, Hu SS. Predictors of flexibility and pain patterns in thoracolumbar and lumbar idiopathic scoliosis. Spine 2002;27(21):2346–2349

27. Berven S, Deviren V, Demir-Deviren S, Hu SS, Bradford DS. Studies in the modified scoliosis research society outcomes instrument in adults: validation, reliability, and discriminatory capacity. Spine 2003;28(18): 2164–2169; discussion 2169

28. Stagnara P. Scoliosis in adults. Surgical treatment of severe forms. Excerpta Med Found Int Cong 1969;192

29. Stagnara P. Utilization of Harrington's device in the treatment of adult kyphoscoliosis above 100 degrees. Fourth International Symposium, 1971. Stuttgart: George Thieme Verlag;1973

30. Kostuik JP. Treatment of scoliosis in the adult thoracolumbar spine with special reference of fusion to the sacrum. Orthop Clin North Am 1988;19:371–381

31. Kostuik JP, Hall BB. Spinal fusions to the sacrum in adults with scoliosis. Spine 1983;8:489–500

32. Kostuik JP. Adult scoliosis. In: Frymoyer J, ed. Adult Spine. New York: Raven Press; 1991

33. Kostuik JP. Decision making in adult scoliosis. Spine 1979;4:521–525

34. Kostuik JP, Mhaidli H, Finkenberg J, Nugent J, Skubic J. The surgical results of the first 100 adult idiopathic scoliosis patients treated with Cotrel-Dubousset instrumentation. Paper presented at: Scoliosis Research Society; Sept. 1993; Kansas City, MO

35. Kostuik JP, Worden HR, Salo P. Long term functional outcome following surgery for adult scoliosis. Paper presented at: American Orthopaedic Association June meeting; 1990; Boston, MA

36. Kostuik JP, Carl A, Ferron S. Anterior Zielke instrumentation for spinal deformity in adults. J Bone Joint Surg Am 1989;71:898–912

37. Cochran T, Irstam L, Nachemson A. Long-term anatomic and functional changes in patients with adolescent scoliosis treated by Harrington rod fusion. Spine 1983;8:576–584

38. Boachie-Adjei O, Gupta M, Marrero G. C-D sacro-pelvic fixation for adult spinal deformity. Results of primary and salvage reconstruction. Paper presented at: Scoliosis Research Society, 28th Annual Meeting; September 18–23, 1993; Dublin

39. Bridwell KH, Edwards CC 2nd, Lenke LG. The pros and cons to saving the L5–S1 motion segment in a long scoliosis fusion construct. Spine 2003;28:S234–S242

40. Islam NC, Wood KB, Transfeldt GE, et al. Extension of fusion to the pelvis in idiopathic scoliosis. Spine 2001;26(2):166–173

41. Nahtomi-Shick O, Kostuik JP, Winters BD, Breder CD, Sieber AN, Sieber FE. Does intraoperative fluid management in spine surgery predict intensive care unit length of stay? J Clin Anesth 2001;13(3):208–212

42. Stagnara P, Fleury D, Fauchet R, et al. Major scoliosis, over 100 degrees, in adults. 183 surgically treated cases. Rev Chir Orthop Reparatrice Appar Mot 1975;61:101–122

43. Kostuik JP, Musha Y. Fusion to the sacrum in adult idiopathic scoliosis using Cotrel-Dubousset instrumentation (1986–1990). Paper presented at: Scoliosis Research Society Annual Meeting; September 1994; Portland, OR

44. Kostuik JP, Musha Y. Extension of previous fusion to the sacrum in adult scoliosis. Paper presented at: Scoliosis Research Society Annual Meeting; September 1994; Portland, OR

45. Jackson RP, Simmons EH, Stripinis D. Incidence and severity of back pain in adult idiopathic scoliosis. Spine 1983;8:749–756

46. Gotze C, Slomka A, Gotze HG, Potzl W, Liljenqvit U, Steinbeck J. Long-term results of quality of life in patients with idiopathic scoliosis after Harrington instrumentation and their relevance for expert evidence. Z Orthop Ihre Grenzgeb 2002;140(5):492–498

47. Kumar MN, Baklanov A, Chopin D. Correlation between sagittal plane changes and adjacent segment degeneration following lumbar spine fusion. Eur Spine J 2001;10(4):314–319

Chapter 22

Osteotomies and Vertebral Column Resections for Complex Spinal Deformities

Elias C. Papadopoulos and Oheneba Boachie-Adjei

The decompensated spine, either in coronal, sagittal, or both planes, remains a challenge to the spinal surgeon when symptomatic and meriting treatment. Risks, benefits, and the patient's expectations should be considered before attempting any reconstruction procedure.

Important milestones in the surgical treatment of complex spine deformity were the introduction of spinal osteotomy techniques and the use of instrumentation in spine fusion. In 1945, Smith-Petersen et al.[1] first performed a wedge osteotomy in the lumbar spine. Lichtblau and Wilson[2] were first to use instrumentation for the fixation. Mason et al.[3] and Urist[4] in the 1950s also introduced the cervical spine osteotomy.

For the purpose of this chapter, complex spine deformity is characterized by multiplanar spine deformity with one or more features of scoliosis, kyphosis, or lordosis resulting in spinal imbalance that lacks flexibility between the vertebrae and cannot be balanced with manipulation of soft tissue but requires a form of bony resection/osteotomy to restore physiologic global and segmental spinal balance. Such deformities can be analyzed in two arbitrary categories: (1) predominantly sagittal imbalance and (2) multiplanar deformity with coronal and sagittal imbalance.

♦ Preoperative Planning and Patient Evaluation

To benefit from these physiologically demanding surgeries, the patients have to be physiologically young and without substantial medical comorbidities. Careful consideration should be made for the older patients who are subjected to such complex procedures because of a high incidence of pseudarthrosis and other postoperative complications.

Careful history and clinical examination are necessary to select patients appropriately for the procedures, identify underlying comorbidities, and to assess the overall appearance and balance of the patient. This is done in conjunction with radiographic studies to assess the most suitable osteotomy site and the flexibility of the deformity and to provide a basic differential diagnosis and treatment plan. A multidisciplinary approach is necessary to obtain preoperative clearance as needed from medicine, cardiopulmonary, and neurology specialists.

Imaging studies include plain standing anteroposterior and lateral radiographs. On the lateral x-ray, sagittal imbalance (SI) is determined with the patient standing fully erect with hips and knees in extension and the arms supported horizontally on an intravenous pole. A plumb line is dropped from C7 to S1 and the horizontal distance from the posterior corner of the L5-S1 disk to this line is measured to represent the sagittal vertical axis (SVA). Frontal balance is determined on the anteroposterior radiograph by measuring the distance from the center of the sacrum to a plumb line that is dropped from the center of the seventh cervical vertebra. Overextension over a bolster at the apex of the kyphotic deformity and lateral bending films are necessary to estimate the rigidity of the deformity. If spondylolisthesis is suspected, flexion-extension lateral radiographs should be obtained. Computed tomography (CT) is useful to estimate the integrity of a fusion mass. Magnetic resonance imaging (MRI) would assess both the neurologic structures and the vertebrae in cases of possible infection; if MRI is contraindicated, a myelo-CT scan can be obtained to evaluate the neural canal. Finally, in older patients, the bone mineral density should be assessed.

♦ Sagittal Imbalance

In the upright posture, the spinal column develops normal sagittal curves that tend to balance to position the head directly over the pelvis. There is considerable variation in the

normal range of values for lumbar lordosis and thoracic kyphosis, therefore the absolute value is not as important as the overall sagittal balance of the spine.[5] This is best reflected by measurement of the distance from the sacrum to a plumb line that is dropped from the center of the seventh cervical vertebra[6] and has a normal range of ±2 cm. Absolute values are used for estimation of required correction, and rule of thumb is that the patient has to have at least 30 degrees more lumbar lordosis than thoracic kyphosis.[7]

Sagittal imbalance is also classified in two types: Type I represents a hypolordotic or kyphotic lumbar segment, whereby the patient compensates by hyperextension of the thoracic spine and remains in balance. Type II deformity is characterized by global imbalance, whereby the spine is flat due to loss of segmental lordosis or kyphosis and the patient is out of balance and unable to compensate; the plumb line falls in front of the S1 superior end plate.[8]

Etiology

Until the evolution of spinal instrumentation, systemic diseases, mainly ankylosing spondylitis, were the most common cause of fixed sagittal deformity.[9–17] Nevertheless, the iatrogenic flat-back syndrome is currently more often encountered, mainly because the patients treated for scoliosis in the 1960s and 1970s with Harrington distraction instrumentation are now becoming symptomatic. The syndrome was first recognized in 1973 by Doherty[18] who recognized the reduction of the physiological lumbar lordosis (flat back) and the subsequent development of sagittal imbalance. Patients are unable to maintain the erect position without hip and knee flexion. This results in back pain, generalized to the lumbar and thoracolumbar spine, and fatigue that develops as the day proceeds. Cervical pain may develop from exacerbation of the cervical lordosis in the patient's effort to assume a horizontal visual field; thigh and knee pain develop from the quadriceps muscle strain.[19] These patients who were treated with distraction Harrington instrumentation to the lower lumbar spine and sacrum[6,19–21] were able to compensate for the loss of lumbar lordosis during adolescence and young adult age. Later, reduced muscle strength, adjacent disk degeneration, and hip and pelvic disease all combine to decrease the patient's ability to compensate and may result in increase disability.[19] The same effect in the lumbar spine is also associated with the use of anterior compression instrumentation (Dwyer or Zielke) without structural interbody grafting that shortens the anterior column.[8] Iatrogenic fixed sagittal imbalance may also result from pullout of posterior segmental spinal instrumentation or settling of anterior spinal column long fusion done without structural grafting. Vertebral fractures, either osteoporotic or traumatic, can either heal naturally or be surgically fused in kyphosis. Finally, severe lumbar degeneration may be associated with rigid lumbar kyphosis. Nevertheless, spinal stenosis usually coexists with lumbar kyphosis after a posterior fusion associated with either adjacent level breakdown or an area of pseudarthrosis within the fusion mass.[22] Less common causes are neuromuscular, congenital, and infectious conditions.[23–26] Conditions not related to the spine, such as hip or knee flexion contractures, can also present with sagittal malalignment and must be ruled out.

Indications for Surgical Treatment

Lumbar spine osteotomies are the mainstay of treatment in fixed sagittal decompensation secondary to excessive thoracic kyphosis, loss of lumbar lordosis, and combinations of sagittal malalignment. In symptomatic flat-back syndrome, osteotomies should be reserved for the failure of conservative means.[8] The goal of the osteotomy is to restore the sagittal balance so the plumb line intersects the posterior superior corner of the S1 vertebra, enabling the patient to resume a more erect posture, restore the horizontal visual field, relieve lung compression by the abdominal viscera, improve diaphragmatic excursion, and, finally, improve appearance.

Surgical Techniques

Smith-Petersen Osteotomy

The surgical correction of the kyphosis deformity was first described by Smith-Petersen et al. in 1945.[1] Multiple posterior osteotomies were performed after resection of the spinous processes and removal of the edges of the laminae with the ligamentum flavum. They were performed with an osteotome through the synostosed articular processes. This resulted in extension and opening through the disk spaces, rupture of the anterior longitudinal ligament, and elongation of the anterior spine to produce lordosis. La Chapelle[27] in 1945 described a two-stage osteotomy with combined approaches. In 1947, Briggs et al.[9] reported a posterior wedge osteotomy with bilateral intervertebral foraminotomy. All these procedures as well as various modifications of the Smith-Petersen osteotomy (SPO)[9,11,16,27–30] represent a shortening of the posterior column and lengthening of the anterior column with the posterior margin of the intervertebral disk as a pivot of angulation. The elongation of the anterior column has caused major complications, including paraplegia from cauda equina stretching, aortic rupture from stretching of the abdominal aorta, and high intestinal obstruction from tensing the superior mesenteric artery across the duodenum.[2,15,29,31–33]

Instead of a monosegmental SPO that may produce a dangerous kinking, Hehne et al. had recommended a polysegmental SPO.[16] With each SPO, a 10- to 15-degree per segment correction should be expected, ~1 degree of lordosis for each resected millimeter.[8,16,34] The disk space must be mobile and of adequate height. Young patients with good bone stock are preferred for the secure anchoring of the segmental instrumentation. In Type I kyphosis, the deformity site determines the osteotomy site. In Type II, it is better to correct the deformity in the lower spine because the lever arm correcting the axis of view is greater and the complication rate is smaller. In addition, in ankylosing spondylitis patients, the correction is not hindered by the fixed ribs.[16]

The patient should be positioned prone on a four-poster frame and provision of spine extension and hip extension should be made to close the osteotomy site at the end of the operation. Fixation points should be obtained above and below the osteotomy sites. Starting the osteotomy at the interlaminar space, the neural arch is undercut to avoid neural structure compression at the closure of the osteotomy. Extending laterally in a V-shape fashion over the foraminal space both articular processes are excised (**Fig. 22–1**). After positioning of the rods, a combination of compression and cantilever maneuvers is

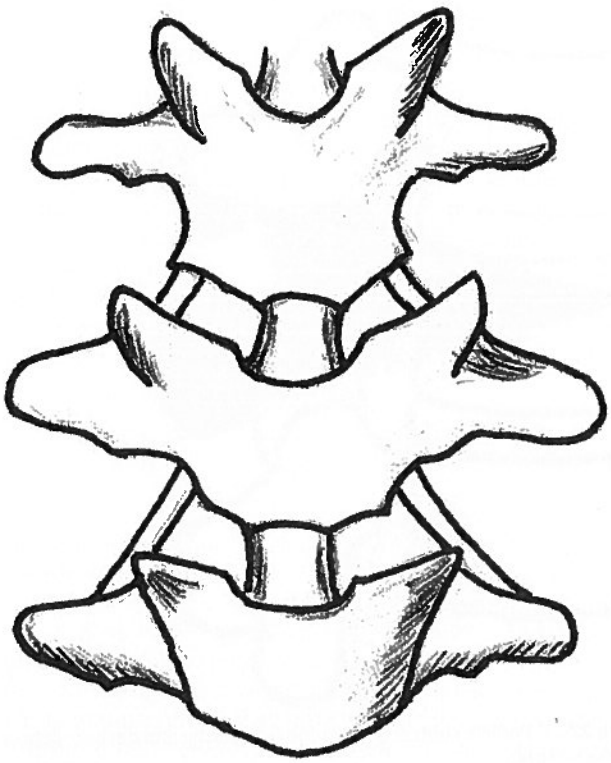

Figure 22–1 Technique of Smith-Petersen osteotomy demonstrating the V-shape laminar and facet resection

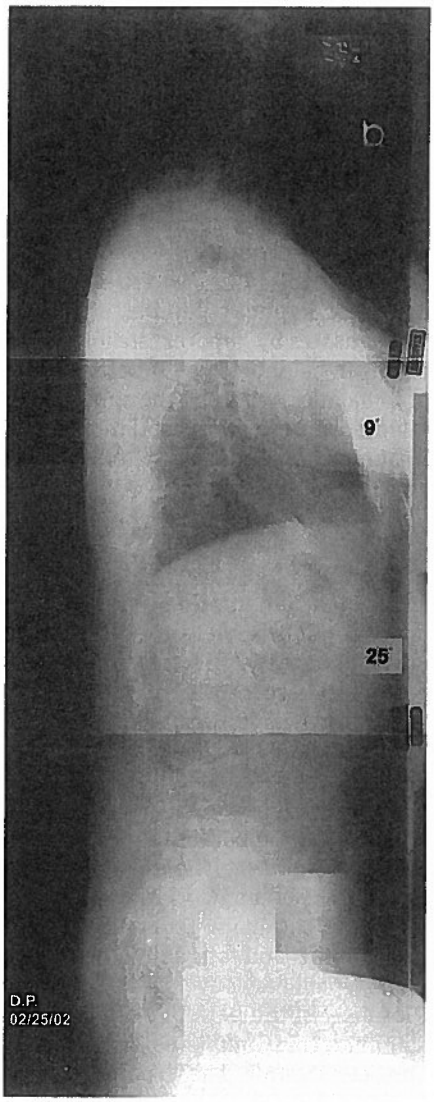

Figure 22–2 Preoperative lateral standing radiograph of a 41-year-old patient with lumbar Scheuermann's kyphosis and sagittal imbalance treated with posterior Smith-Petersen osteotomy (SPO).

applied to close the osteotomy sites. SPOs can be performed in conjunction with anterior diskectomies and fusion **(Figs. 22–2 and 22–3)** or with similar technique over a fusion mass.[6,35]

It is critical to identify and spare the pedicle, which in case of no discernible normal anatomy is feasible either by the transverse process visualization or by fluoroscopy. The V-shape of the osteotomy provides rotational control and enhances the segmental interlocking. Caution should be taken when the osteotomy is performed in patients with scoliotic deformity that exceeds 45 degrees because there is a tendency to push the patient off to the concavity. Nevertheless, asymmetrical resection can be done to improve coronal deformities. It should also be avoided in patients with spinal stenosis, especially foraminal stenosis, because the osteotomy decreases the foraminal space.[22] A SPO that is not closing suggests the anterior column is stiff; then the only alternative is to perform a pedicle subtraction osteotomy between two adjacent SPOs with resection of the pedicles and the vertebral body between them.[36]

Pedicle Subtraction Osteotomy, or Eggshell Osteotomy

Transpedicular decancellation of the vertebral bodies was initially described by Michelle and Krudger as a biopsy technique for the diagnosis of vertebral lesions.[37] Based on this technique, two original three-column osteotomies were described. Heinig[38] introduced the eggshell procedure as a one-stage operation for correction of rigid deformities that permits protection of the neurologic elements and vascular structures. Heinig described removal of the superior end plate and intervertebral disk and fracture of the anterior cortex permitting compression rather than wedge closure. Thomasen modified the osteotomy[39] and described a circumferential wedge excision rather than decancellation and compression with vertebral body collapse **(Figs. 22–4 and 22–5)**. Both transpedicular approaches are closing wedge osteotomies with an anterior apex of correction and shortening of the spine rather than elongation. They create a large neural foramen through removal of the pedicles. Because the surfaces of the osteotomy are cancellous bone, they heal rapidly and effectively.

Pedicle subtraction osteotomy (PSO) consists of removal of cancellous bone of the selected vertebral body through both pedicles to weaken the vertebral body and creation of posterior compression of the laminae and posterior aspect of the vertebral body with minimal force. The posterior arches of the adjacent vertebrae are approximated under direct vision by manipulation of the table, extension of the spine, and cantilever forces on the spine with the instrumentation.

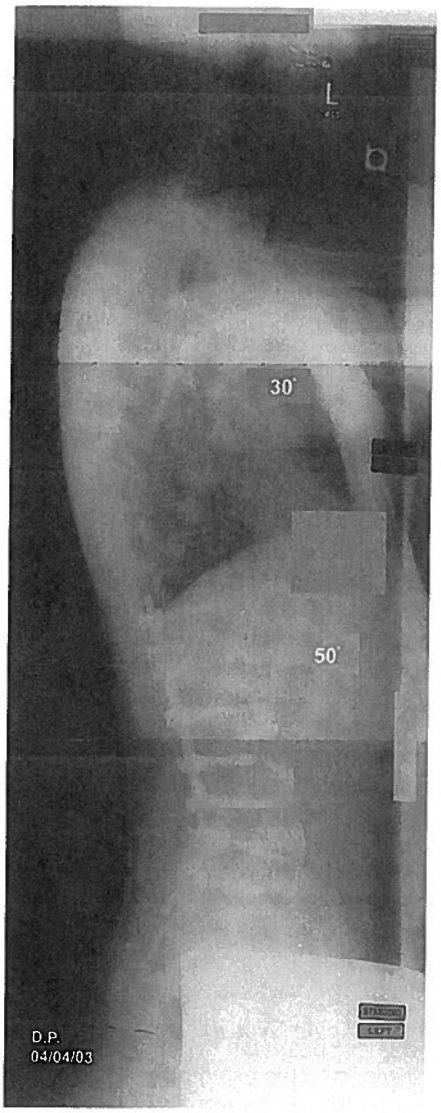

Figure 22–3 Postoperative lateral standing radiograph of a 41-year-old patient with lumbar Scheuermann's kyphosis and sagittal imbalance treated with posterior Smith-Petersen osteotomy (SPO); demonstrates restoration of lordosis and sagittal imbalance.

The amount of the correction should be estimated on standing full-length lateral spinal radiographs. Approximately 30 degrees to 50 degrees of correction can be achieved per osteotomy[13,17]; a 6- to 13.5-cm correction of the SVA is also anticipated.[40,41] It can be performed in rotated scoliotic segments, preferably at the apex, which can be corrected if a trapezoidal shape is given to the osteotomy. The osteotomy is best placed at the midlumbar spine to avoid working around the spinal cord and to allow adequate proximal and distal fixation points. If possible, the level has to be parallel to the sacrum to avoid osteotomy translocation at the completion of the procedure. Again, good bone stock is a prerequisite to secure the segmental instrumentation. Ideally, the osteotomy is performed in an area of previous fusion.[22,42] If performed through a motion segment, then neither the bone stock nor the stability after the procedure are ideal and may compromise the fusion outcome.

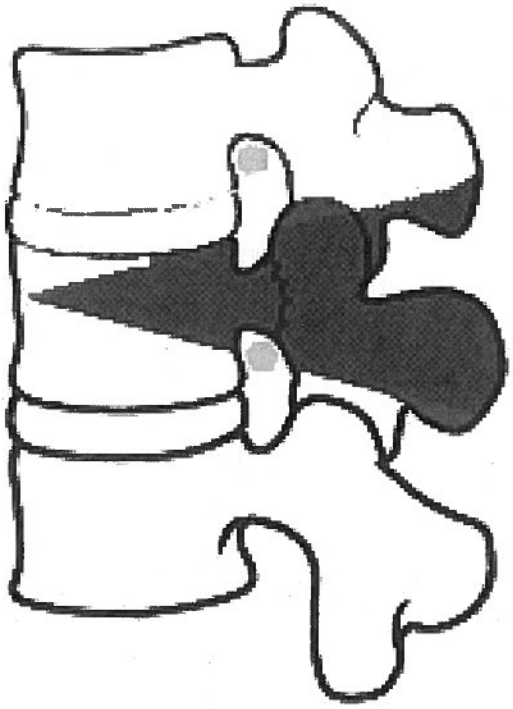

Figure 22–4 Pedicle subtraction wedge osteotomy and decancellation of spinal column.

The patient is positioned in a similar fashion as for SPO, and provision is made for extension at the osteotomy site. The authors prefer three levels of rigid transpedicular fixation both above and below the level of the osteotomy that

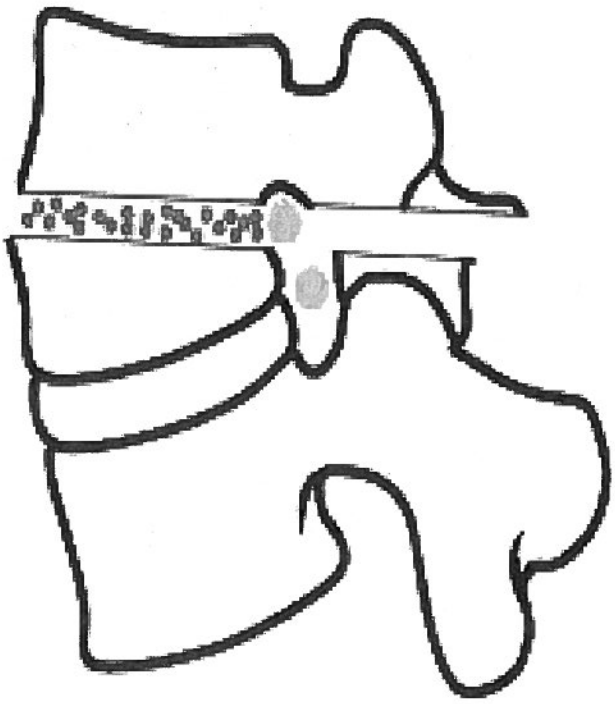

Figure 22–5 Closure after pedicle subtraction wedge osteotomy.

should be placed before any destabilization of the spine is performed. The entire neural arch of the selected level and a portion of the cephalad and caudal neural arches are also resected. To avoid central canal stenosis at the closure of the osteotomy, it is safer to perform extended central laminectomy. The dura and the nerve roots above and below the pedicle that is planned to be resected are freed. Transverse processes and their muscle attachments are detached from the vertebra. At this point, one may proceed with decancellation of the vertebral body through the pedicles or directly, excising the entire pedicles and performing the decancellation at the basis of the pedicle. Alternatively, one may preserve the medial pedicle wall for provisional protection of the neural elements. Copious bleeding should be anticipated and can be controlled either with bipolar electrocautery or with the application of gelfoam and thrombin. During the decancellation, it is important to place temporary fixation rods opposite the resection site to prevent inadvertent collapse as the process continues. Finally, the medial pedicle cortex if preserved and the posterior vertebral cortex are resected. For the latter, an adequate amount of bone should have been resected.and is accomplished with Woodson elevators or reverse-angle curettes. At this point, one may choose to resect the proximal intervertebral disk and proceed in eggshell osteotomy fashion causing a type of compression fracture of the vertebral body[38] or to resect the lateral vertebral wall with a rongeur or an osteotome to create a wedge osteotomy.[39] For the latter, the soft tissues should be dissected from the lateral wall either with a curette of with cautery, carefully avoiding the segmental vessels, mainly the ones below the pedicle. Correction is achieved by gradual extension of the operating table and closing the osteotomy site, which allows the remaining superior and inferior posterior arches to oppose. The neurologic elements are visualized directly during closure; the enlarged foramen that was created with the pedicle resection and that contains two nerve roots can be probed with a ball tip probe. Bone graft from the decancellation procedure is placed on the posterior lateral elements, and the rods are secured.

In some instances, the osteotomy may not hinge on the anterior column and can open through the disk spaces above and below, or the bone interposition in the anterior column may not be sufficient. In this case, a cage filled with autograft can be positioned anteriorly, a posterior lumbar interbody fusion can be added to the procedure, or the anterior column can be reconstructed later through an anterior approach. Anterior surgery or posterior lumbar interbody fusion at adjacent segments may be added in cases of compromised bone stock, concomitant pseudarthrosis, or extension to the sacrum. In the latter case and for long fusions, fusion of the two lowest intervertebral disks as well as pelvic fixation should be considered.

♦ Coronal and Multiplanar Imbalance

Despite the effort of early recognition of scoliotic deformities in early stages, patients with severe, neglected rigid scoliosis are still seen. Severe, stiff coronal curves may also result from failed previous deformity surgery or congenital disorders. These patients have commonly concomitant coronal and sagittal imbalance. Surgical correction is indicated for deformity progression, pain refractory to conservative care that in the failed surgery group is related to pseudarthrosis, short primary fusion or adjacent segment decompensation, neurologic deficit, and deterioration of pulmonary function. The presence of decompensation leads to additional specific complaints, such as apparent leg-length discrepancy and imbalance in sitting and standing. Scoliotic deformities in these patients are often very rigid and are not correctable with traditional methods; excessive corrective forces may cause neurologic complications.

♦ Indications for Surgical Treatment

Bridwell[43] classified these patients into two types. In Type A deformity, the shoulders and pelvis are tilted in the opposite direction, and the treatment consists of wedge-type osteotomies, either several or one pedicle subtraction osteotomy. In Type B deformity, both shoulders and pelvis are tilted in the same direction, and a trapezoidal osteotomy can have the opposite desired effect and exacerbate the coronal imbalance; a vertebral column resection (VCR) has been recommended by the surgeons.[43] Berven et al.[40] used as a cutoff the amount of coronal decompensation, treating translation below 6 cm with SPOs and greater than 6 cm with either combined anterior and posterior osteotomies or VCR.

Surgical Techniques

Multiple Osteotomies of The Spine (Type B)

Schmidt and Meiss first reported the osteotomy of the fusion mass for realignment of a spine deformity in the frontal plane.[44,45] Cummine et al.[46] and Floman et al.[47] presented large series of patients treated mainly with staged surgery for fixed decompensated deformity secondary to previous failed surgery. The operation consisted of osteotomies of the posterior fusion mass, subsequent halo-femoral traction, and posterior spine fusion with the use of Harrington rods. In these series, the goal of the operation was to obtain a solid, pain-free fusion mass, with level pelvis and balanced trunk over the sacrum; correction of the deformity was of secondary importance. In a recent report, Voos et al.[48] reevaluated the efficacy of the multiple vertebral osteotomies in a series where almost 50% of the patients had additional anterior osteotomies because of prior anterior fusion or ankylosis; the average scoliosis correction was 40%, whereas the average sagittal imbalance was corrected 6.5 cm and the coronal 2.5 cm, representing 100% and 68% correction, respectively.

The key in multiple vertebral osteotomies is the convex base wedge shape of the bone excision. The number of the osteotomies required is dependent on the degree of the curve, the number of vertebrae incorporated in the fusion mass, and the rigidity of the curve. Anterior osteotomy is required when the intervertebral disk space is previously fused or ankylosed. Anteriorly, the curve is approached on

the convex side. The foramens should be identified and used as guide at the level at which the osteotomy is placed. Multiple instruments are used to completely remove the bone to the epidural space from posterior wall to the concave side of the curve, thus performing a complete dissociation of two adjacent motion segments. Posteriorly a wedge SPO type osteotomy of the fusion mass is then performed at the foraminal level of the corresponding anterior osteotomies.

Vertebral Column Resection

Vertebrectomy was first described by MacLennan as apical resection from a posterior-only approach with postoperative casting for the treatment of severe scoliosis.[49] In 1983, Luque presented eight cases of vertebrectomy in patients with a primary spinal deformity greater than 90 degrees.[50] Luque's original technique consisted of anterior and posterior vertebrectomy, with decancellation of the vertebral body performed through an anterior fenestration without segmental vessel ligation or intervertebral disk excision. The technique was modified by Boachie-Adjei and Bradford,[51] who in 1987 presented 16 patients, all of whom underwent combined anterior and posterior vertebral column resection and arthrodesis with Luque instrumentation for fixed multiplanar deformities.

Indication for a VCR are fixed trunk translation, rigid spinal deformities of greater than 80 degrees in the coronal plane, and asymmetry between the length of the convex column and concave column of the deformity, precluding achievement of balance by plain osteotomy alone.[20] The number of the vertebrae to resect is indicated by the magnitude of the deformity. In sharply angular deformity, one apical vertebra resection may be adequate. If the deformity is long and sweeping, resection of two to three apical vertebrae may be required to achieve balanced correction without stretching the spinal cord. Bradford and Tribus[20] reported 82% correction of the decompensation in the coronal plane and 85% in the sagittal plane; scoliosis improved 52% and the T1 tilt and pelvic obliquity improved to 11.5 and 7 degrees, respectively (65% and 55%, respectively).

The surgical technique consists of combined anterior and posterior approaches, same day or staged. Same day is feasible when the blood loss or the duration of the anterior approach is reasonable and the patient is stable at the conclusion of the anterior surgery. Bradford sets the limit to 1000 mL of blood loss and/or 3 hours duration for the anterior procedure[20]; if that was exceeded, the patient was placed on total parenteral nutrition (TPN) and kept in bed unless a posterior fusion mass was present and stable to permit out-of-bed to chair activity. The posterior approach was performed when the patient was stable (usually within a week).

The anterior surgery consists of an approach on the convex side of the deformity by thoracic or thoracoabdominal approach. The segmental vessels are ligated. An osteoperiosteal flap is then elevated over the vertebral bodies to be resected using an osteotome, and diskectomies are performed back to the posterior longitudinal ligament. The vertebral bodies are removed in a piecemeal fashion back to the dura. The convex pedicle is removed during the anterior procedure; nevertheless, only partial resection of the concave pedicle is safe. The dura is then covered with gelfoam; morcelized bone graft from the resected vertebrae and, if available, from the rib through which the spine was approached is placed loosely into the resected area; and the osteoperiosteal flap is sewn back to contain the bone graft.

At the posterior approach, the decided area to be instrumented is exposed. At this point, a convex throracoplasty is performed; in extreme deformities, concave rib osteotomies are added to facilitate the manipulation of the spine. Fixation points are placed, and the neural arch including the pedicle remnants of the corresponding anterior resected vertebrae are removed. The deformity is then corrected with bilateral rods, if necessary secured to the pelvis with Galveston technique to favor shortening of the vertebral column and definitely to avoid distraction over the resection area.

Hemivertebral Resection–Posterior Vertebral Column Resection

Congenital deformities of the spine and predominantly the most common nonincarcerated hemivertebra, neurofibromatosis, fractures, and infections are the most common causes of severe, stiff, angular kyphoscoliosis. In congenital scoliosis, early recognition and early surgical resection of a hemivertebra mitigates the development of compensatory curves that later may develop characteristics of a structural curve and may have to be treated. In addition, a late correction of the rigid primary curve per se is difficult and associated with high risk. Numerous treatments have been proposed, among them posterior fusion and hemiepiphysiodesis, but the results are variable and unpredictable.

Leatherman[53] described a two-stage anterior and posterior approach for hemivertebral resection with excellent correction. Other publications followed, with the resection of the hemivertebra performed in one or two stages with anterior or posterior approaches.[54,55] Recently, a one-stage, posterior-only hemivertebra resection with instrumentation has been advocated.[56,57] The technique is similar to the eggshell procedure, consisting of decancellation of the vertebral body through the pedicle after excision of the neural arch of the hemivertebra. Removal of the cortex of the hemivertebra is not required, because application of compression forces to the convex side crushes the residual cortical shell. The disks and end plates are resected on each side of the hemivertebra. The resection of the concave part of the disk between the two vertebra that contain the hemivertebra is difficult, but it functions as a hinge preventing critical translation of the spinal column at the completion of the resection. In the thoracic spine, the base part that is attached to the hemivertebrae rib has to be resected. Overall, the procedure is safe because the spinal cord is shifted to the concavity of the curve, which allows enough workspace to perform resection of the pedicle and the vertebral body with a direct view of the spinal cord. The placement of instrumentation allows correction of the deformity through compression and distraction maneuvers. Bone graft is placed both anteriorly and posteriorly; to restore the physiologic sagittal alignment, anterior structural support should be used where necessary. In

cases where the hemivertebra is an isolated congenital deformity, the use of instrumentation permits the restriction of the fusion only to the two levels adjacent to the hemivertebra vertebrae.

Posterior vertebral column resection (PVCR) was introduced for the treatment of severe, rigid, angular kyphosis and kyphoscoliosis.[58–60] As a method, it mitigates the technical difficulties that can be encountered with an anteroposterior, one- or two-stage VCR. In PVCR, the apex of angular curves is exposed in one surgical field with a single posterior approach, and circumferential osteotomy is performed.

The patient is placed in the prone position on a four-poster frame. No provision for spinal extension is made. The apical vertebra is identified and wide exposure is performed, proximally, distally, and laterally, along the surrounding ribs. Transverse processes and 5 cm of the proximal part of the periapical ribs are excised and the parietal pleura is pushed away from the anterior vertebral body. The segmental vessels are identified and ligated, thus freeing the aorta that is carefully detached from the anterior vertebral body. The nerve roots in the lumbar spine have to be spared; nevertheless, the intercostals are severed. Secure fixation points, preferably pedicle screws, are placed bilaterally to the osteotomy site, usually on three vertebrae on each site. The osteotomy consists of laminectomy and wedge-shape resection of the vertebral body. The former should be wide and includes the neural arch of the apical vertebra, and one above and below. During the resection of the vertebrae, spinal stability is secured with provisional prebent rods connected to the pedicle screws on one side. Working on the other side, bone removal is feasible with the use of osteotomies, rongeurs, and curettes; for the bone that is in contact with the dura, a high-speed power drill should be employed and the anterior longitudinal ligament should be preserved. At the completion of the osteotomy, the neural tube is circumferentially exposed in the surgical field **(Figs. 22–6 and 22–7)**. The correction of the deformity is feasible either with in situ bending of the provisional rods or sequential replacement of the provisional rods with precontoured rods to the desired correction. Alternatively, the spine can be manipulated through two correction rods placed unilaterally, fixed cranially and caudally to the osteotomy site, and held with rod holders. To avoid distraction of the neural elements, a compression force is applied to shorten the spinal column and partially close the osteotomy site before any correction is attempted. At this step, care should be taken and, if necessary, the laminectomy should be extended to avoid impingement of the spinal cord that buckles posteriorly. Autologous cancellous bone graft is used for the anterior fusion at the resected area. For a substantial anterior intervertebral gap (more than 5 mm), a structural graft, preferably a titanium mesh cage filled with autograft, should be used, and compression over the cage should be performed to secure it in place. Posterior bone graft at the resection area may be used, although it has been reported to cause complications, such as wound hematoma.[60] The reported anticipated mean correction in the coronal plane ranges from 52.9 to 61.9%.[58,60]

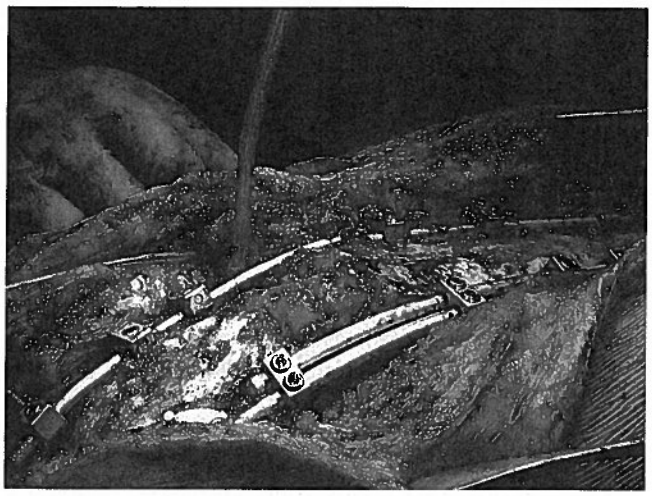

Figure 22–7 Photo taken after circumspinal resection and closure with multiple-rod cantilever instrumentation.

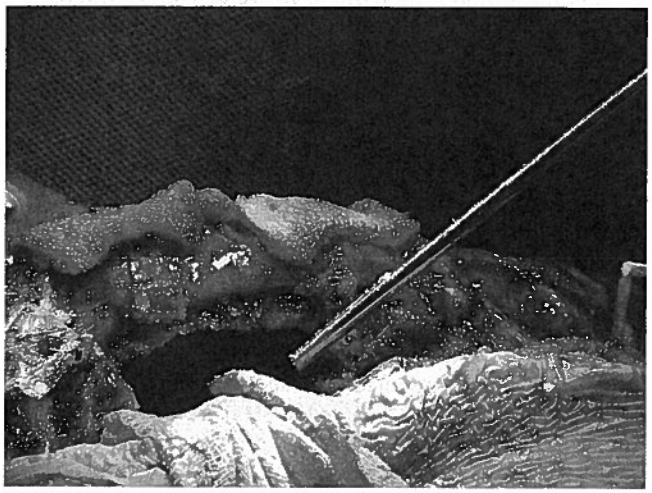

Figure 22–6 Intraoperative photo: postvertebral column resection of vertebral body and lamina. Lamina bridge of the vertebral body wall is intact with spinal cord on top.

♦ Intraoperative Management of Osteotomies and Vertebral Column Resections

During spinal osteotomies, somatosensory evoked potentials (SSEPs) should be employed to monitor the integrity of the spinal cord. The lumbar nerve roots should be monitored with spontaneous electromyogram (spEMG) recordings during the placement of the pedicle screws. If available, transcranial motor evoked potentials may provide accurate monitoring of the spinal cord motor tracks. Multiple wake-up tests can also be performed, especially at the completion of each manipulation maneuver.

Substantial blood loss should be anticipated in all the osteotomies, either from the epidural veins or from the cancellous bone. Careful positioning of the patient with the

abdomen free of any pressure, meticulous hemostasis with bipolar cautery, and packing with gelfoam soaked in thrombin are usually successful to control the hemorrhage. Hemodilution anesthesia, autologous transfusion, and cell saver are commonly employed measures for the mitigation and replacement of the blood loss.

The evolution of segmental instrumentation increased dramatically the potential of corrective surgeries in complex deformity. As general guideline, placement of the pedicle screws or any fixation points before the completion of an osteotomy is recommended to provide reliable intraoperative stability to the vertebral column before the destabilization takes place and to offer a grip for the vertebral column during the manipulative correction. Moreover, because osteotomies are associated with rapid, difficult to control blood loss, all time-consuming steps of the operation should have been completed in advance.

Nutrition must be optimized both preoperatively and postoperatively. In staged anteroposterior surgery, the use of total parenteral nutrition (TPN) appears to favorably modify nutritional depletion.[61–63] Because depletion of nutritional parameters appears to correlate with an increased likelihood of perioperative infectious complications, TPN may reduce their incidence.

Both same-day and staged operations have proponents that espouse the safety of the technique, the decreased complication rate, and the overall favorable outcome for the patient.[63,64] It is the authors' preference to perform same-day antero-posterior osteotomies, but it is prudent to stage the operation when the first part exceeds a certain blood loss and/or is protracted to lessen the hemodynamic injury sustained by the patient.

Postoperatively, most patients are fitted with a thoracolumbosacral orthosis (TLSO) or a three-point extension orthosis for a variable period, based on the amount of bone resected and the destabilizing effect of the osteotomy, as well as the bone quality and strength of the fixation points.

♦ Complications of Osteotomies

In 1979, for a multiple osteotomy series for failed scoliosis, Cummine et al. reported a 71% complication rate and a 3.4% mortality rate.[46] The contemporary danger of death is remote, but surgery for complex deformity is definitely associated with a high complication rate that is reasonable and expected considering the magnitude and the severity of the deformities. Neurologic injury varies from spinal cord injury (SCI) to nerve root injury and usually is transient. Permanent, complete SCI was reported in patients neurologically compromised before the operation.[60] Despite the common belief, segmental vessel ligation is not associated with SCI, provided it is unilateral, at the convexity of the curve, performed at the midvertebral body level, and hypotensive anesthesia is avoided.[65] Dural tears are reported in almost all series and have been related mainly to scarring of the dura mater secondary to previous operations; they are of minor consequence. Historically reported as high as 17% and 10%, wound infection and hematoma may be prevented with meticulous technique and optimal nutrition status. Preservation of the instrumentation is possible for infections treated with multiple debridement surgeries and intravenous antibiotics. Deep wound hematoma may present with cauda equina syndrome, resolving after decompression.[66] Several medical complications are reported relative to intraoperative cardiopulmonary strain, blood loss–related coagulopathy, and the postoperative immobilization. Because the anterior column elongation procedures have been abandoned, severe vascular injuries are not anticipated. Nevertheless, Bradford[20] reported two superior mesenteric artery syndromes with the VCR procedure.

Due to the cancellous bone contact at the vertebral body level, pseudarthroses are not often encountered. Most are reported at the adjacent levels that the fusion had to extend, such as the thoracic spine in lumbar PSOs.[8,34] Related instrumentation complications such as failure of fixation or prominent screws may occur. Proximal degeneration with recurrence of the deformity occurs more often in sagittal imbalance realignment and if related to compression fractures can potentially be treated conservatively.[34,40]

Overall, the complication rate in patients with complex deformity undergoing revision surgeries is not necessarily greater than in patients who have primary antero-posterior surgery for adult spinal deformity.[61]

♦ Outcomes

Various validated instruments have been used in the recent literature to assess patient outcome and identify predictive factors. Pain, function, and self-image improvement are high in most series where outcome studies were performed, although in general below the population norms. Satisfaction reported with the operation varies from 73 to 86%.[8,48,67] Satisfaction was not related to postoperative complications[40] but to the development of pseudarthrosis.[8] Although Booth et al. found satisfaction relative to radiographic parameters such as sagittal correction and coronal balance,[8] other investigators found the improvement of lumbar lordosis to be the sole predictive factor of the overall patient satisfaction outcome score.[68]

References

1. Smith-Petersen MN, Larson CB, Aufranc OE. Osteotomy of the spine for correction of flexion deformity in rheumatoid arthritis. J Bone Joint Surg Am 1945;27:1–11
2. Lichtblau PO, Wilson PD. Possible mechanism of aortic rupture in orthopaedic correction of rheumatoid spondylitis. J Bone Joint Surg Am 1956;38(1):123–127
3. Mason C, Cozen L, Adelstein L. Surgical correction of flexion deformity of the cervical spine. Calif Med 1953;79(3):244–246
4. Urist MR. Osteotomy of the cervical spine; report of a case of ankylosing rheumatoid spondylitis. J Bone Joint Surg Am 1958;40(4): 833–843

5. Stagnara P, De Mauroy JC, Dran G, et al. Reciprocal angulation of vertebral bodies in a sagittal plane: approach to references for the evaluation of kyphosis and lordosis. Spine 1982;7(4):335–342

6. Lagrone MO, Bradford DS, Moe JH, Lonstein JE, Winter RB, Ogilvie JW. Treatment of symptomatic flatback after spinal fusion. J Bone Joint Surg Am 1988;70(4):569–580

7. Bernhardt M, Bridwell KH. Segmental analysis of the sagittal plane alignment of the normal thoracic and lumbar spines and thoracolumbar junction. Spine 1989;14(7):717–721

8. Booth KC, Bridwell KH, Lenke LG, Baldus CR, Blanke KM. Complications and predictive factors for the successful treatment of flatback deformity (fixed sagittal imbalance). Spine 1999;24(16):1712–1720

9. Briggs H, Keats S, Schlesinger PT. Wedge osteotomy of spine with bilateral, intervertebral foraminotomy: correction of flexion deformity in five cases of ankylosing arthritis of spine. J Bone Joint Surg Am 1947;29:1075–1082

10. Dawson CW. Posterior elementectomy in ankylosing arthritis of the spine. Clin Orthop Relat Res 1957;4(10):274–281

11. Camargo FP, Cordeiro EN, Napoli MM. Corrective osteotomy of the spine in ankylosing spondylitis. Experience with 66 cases. Clin Orthop Relat Res 1986;208:157–167

12. Goel MK. Vertebral osteotomy for correction of fixed flexion deformity of the spine. J Bone Joint Surg Am 1968;50(2):287–294

13. Jaffray D, Becker V, Eisenstein S. Closing wedge osteotomy with transpedicular fixation in ankylosing spondylitis. Clin Orthop Relat Res 1992;279:122–126

14. McMaster MJ. A technique for lumbar spinal osteotomy in ankylosing spondylitis. J Bone Joint Surg Br 1985;67(2):204–210

15. Weatherley C, Jaffray D, Terry A. Vascular complications associated with osteotomy in ankylosing spondylitis: a report of two cases. Spine 1988;13(1):43–46

16. Hehne HJ, Zielke K, Bohm H. Polysegmental lumbar osteotomies and transpedicled fixation for correction of long-curved kyphotic deformities in ankylosing spondylitis. Report on 177 cases. Clin Orthop Relat Res 1990;258:49–55

17. Thiranont N, Netrawichien P. Transpedicular decancellation closed wedge vertebral osteotomy for treatment of fixed flexion deformity of spine in ankylosing spondylitis. Spine 1993;18(16):2517–2522

18. Doherty JH. Complications of fusion in lumbar scoliosis. In: Proceedings of the Scoliosis Research Society. J Bone Joint Surg Am 1973; 55:438

19. Kostuik JP, Maurais GR, Richardson WJ, Okajima Y. Combined single stage anterior and posterior osteotomy for correction of iatrogenic lumbar kyphosis. Spine 1988;13(3):257–266

20. Bradford DS, Tribus CB. Vertebral column resection for the treatment of rigid coronal decompensation. Spine 1997;22(14):1590–1599

21. Farcy JP, Schwab FJ. Management of flatback and related kyphotic decompensation syndromes. Spine 1997;22(20):2452–2457

22. Bridwell KH, Lenke LG, Lewis SJ. Treatment of spinal stenosis and fixed sagittal imbalance. Clin Orthop Relat Res 2001;384:35–44

23. Gertzbein SD, Harris MB. Wedge osteotomy for the correction of posttraumatic kyphosis. A new technique and a report of three cases. Spine 1992;17(3):374–379

24. Pritchett JW, Bortel DT. Degenerative symptomatic lumbar scoliosis. Spine 1993;18(6):700–703

25. Otani K, Satomi K, Fujimura Y, Manzoku S, Shibasaki K. Spinal osteotomy to correct kyphosis in spinal tuberculosis. Int Orthop 1979;3(3):229–235

26. Laroche M, Delisle MB, Aziza R, Lagarrigue J, Mazieres B. Is camptocormia a primary muscular disease? Spine 1995;20(9):1011–1016

27. La Chapelle EH. Osteotomy of the lumbar spine for correction of kyphosis in a case of ankylosing spondylitis. J Bone Joint Surg Am 1945;28:851–855

28. Law WA. Osteotomy of the spine. Clin Orthop Relat Res 1969;66: 70–76

29. MacEwen GD, Bunnell WP, Sriram K. Acute neurological complications in the treatment of scoliosis. A report of the Scoliosis Research Society. J Bone Joint Surg Am 1975;57(3):404–408

30. Simmons EH. Kyphotic deformity of the spine in ankylosing spondylitis. Clin Orthop Relat Res 1977;128:65–77

31. Adams JC. Technique, dangers and safeguards in osteotomy of the spine. J Bone Joint Surg Br 1952;34(2):226–232

32. Horton RE. Arterial injuries complicating orthopaedic surgery. J Bone Joint Surg Br 1972;54(2):323–327

33. Lehmer SM, Keppler L, Biscup RS, Enker P, Miller SD, Steffee AD. Posterior transvertebral osteotomy for adult thoracolumbar kyphosis. Spine 1994;19(18):2060–2067

34. Bridwell KH, Lewis SJ, Lenke LG, Baldus C, Blanke K. Pedicle subtraction osteotomy for the treatment of fixed sagittal imbalance. J Bone Joint Surg Am 2003;85(3):454–463

35. Moe JH, Denis F. The iatrogenic loss of lumbar lordosis. Orthop Trans 1977;1:131

36. Bridwell KH. Smith-Petersen osteotomy. In: Vaccaro AR, Albert TJ, eds. Spine Surgery. Tricks of the Trade. New York: Thieme; 2003:148–149

37. Michelle A, Krudger FJ. A surgical approach to the vertebral body. J Bone Joint Surg Am 1949;31:873–878

38. Heinig CF. Eggshell procedure. In: Luque ER, ed. Segmental Spinal Instrumentation. Thorofare, NJ: Slack; 1984:221–234

39. Thomasen E. Vertebral osteotomy for correction of kyphosis in ankylosing spondylitis. Clin Orthop Relat Res 1985;194:142–152

40. Berven SH, Deviren V, Smith JA, Emami A, Hu SS, Bradford DS. Management of fixed sagittal plane deformity: results of the transpedicular wedge resection osteotomy. Spine 2001;26(18):2036–2043

41. Bridwell KH, Lewis SJ, Rinella A, Lenke LG, Baldus C, Blanke K. Pedicle subtraction osteotomy for the treatment of fixed sagittal imbalance. Surgical technique. J Bone Joint Surg Am 2004;86-A(Suppl 1):44–50

42. Bridwell KH, Lewis SJ, Edwards C, et al. Complications and outcomes of pedicle subtraction osteotomies for fixed sagittal imbalance. Spine 2003;28(18):2093–2101

43. Bridwell KH. Spine osteotomy and resection. In: Dewald RL, ed. Spinal Deformities. The Comprehensive Text. New York: Thieme; 2003: 551–561

44. Schmidt AC. Osteotomy of the fused scoliotic spine and use of Halo traction apparatus. In: American Academy of Orthopaedic Surgeons: Symposium on the Spine. St Louis: C.V. Mosby; 1969:265–282

45. Meiss WC. Spinal osteotomy following fusion for paralytic scoliosis. J Bone Joint Surg Am 1955;37:73–77

46. Cummine JL, Lonstein JE, Moe JH, Winter RB, Bradford DS. Reconstructive surgery in the adult for failed scoliosis fusion. J Bone Joint Surg Am 1979;61(8):1151–1161

47. Floman Y, Penny JN, Micheli LJ, Riseborough EJ, Hall JE. Osteotomy of the fusion mass in scoliosis. J Bone Joint Surg Am 1982;64(9): 1307–1316

48. Voos K, Boachie-Adjei O, Rawlins BA. Multiple vertebral osteotomies in the treatment of rigid adult spine deformities. Spine 2001;26(5): 526–533

49. MacLennan A. Scoliosis. BMJ 1922;2:865–866

50. Luque ER. Vertebral column transposition. Orthop Trans 1983;7:29

51. Boachie-Adjei O, Bradford DS. Vertebral column resection and arthrodesis for complex spinal deformities. J Spinal Disord 1991;4(2):193–202

52. Tokunaga M, Minami S, Kitahara H, Isobe K, Nakata Y, Moriya H. Vertebral decancellation for severe scoliosis. Spine 2000;25(4):469–474

53. Leatherman KD. The management of rigid spinal curves. Clin Orthop Relat Res 1973;93:215–224

54. Bradford DS, Boachie-Adjei O. One-stage anterior and posterior hemivertebral resection and arthrodesis for congenital scoliosis. J Bone Joint Surg Am 1990;72(4):536–540

55. Lazar RD, Hall JE. Simultaneous anterior and posterior hemivertebra excision. Clin Orthop Relat Res 1999;364:76–84

56. Ruf M, Harms J. Posterior hemivertebra resection with transpedicular instrumentation: early correction in children aged 1 to 6 years. Spine 2003;28(18):2132–2138

57. Shono Y, Abumi K, Kaneda K. One-stage posterior hemivertebra resection and correction using segmental posterior instrumentation. Spine 2001;26(7):752–757

58. Shimode M, Kojima T, Sowa K. Spinal wedge osteotomy by a single posterior approach for correction of severe and rigid kyphosis or kyphoscoliosis. Spine 2002;27(20):2260–2267

59. Kawahara N, Tomita K, Baba H, Kobayashi T, Fujita T, Murakami H. Closing-opening wedge osteotomy to correct angular kyphotic deformity by a single posterior approach. Spine 2001;26(4):391–402

60. Suk SI, Kim JH, Kim WJ, Lee SM, Chung ER, Nah KH. Posterior vertebral column resection for severe spinal deformities. Spine 2002;27(21): 2374–2382

61. Linville DA, Bridwell KH, Lenke LG, Vedantam R, Leicht P. Complications in the adult spinal deformity patient having combined surgery. Does revision increase the risk? Spine 1999;24(4):355–363

62. Hu SS, Fontaine F, Kelly B, Bradford DS. Nutritional depletion in staged spinal reconstructive surgery. The effect of total parenteral nutrition. Spine 1998;23(12):1401–1405

63. Dick J, Boachie-Adjei O, Wilson M. One-stage versus two-stage anterior and posterior spinal reconstruction in adults. Comparison of outcomes including nutritional status, complications rates, hospital costs, and other factors. Spine 1992;17(8 Suppl):S310–S316

64. Rhee JM, Bridwell KH, Lenke LG, et al. Staged posterior surgery for severe adult spinal deformity. Spine 2003;28(18):2116–2121

65. Winter RB, Lonstein JE, Denis F, Leonard AS, Garamella JJ. Paraplegia resulting from vessel ligation. Spine 1996;21(10):1232–1234

66. Suk KS, Kim KT, Lee SH, Kim JM. Significance of chin-brow vertical angle in correction of kyphotic deformity of ankylosing spondylitis patients. Spine 2003;28(17):2001–2005

67. Murrey DB, Brigham CD, Kiebzak GM, Finger F, Chewning SJ. Transpedicular decompression and pedicle subtraction osteotomy (eggshell procedure): a retrospective review of 59 patients. Spine 2002;27(21):2338–2345

68. Berven SH, Deviren V, Smith JA, Hu SH, Bradford DS. Management of fixed sagittal plane deformity: outcome of combined anterior and posterior surgery. Spine 2003;28(15):1710–1716

Chapter 23

Adult Spinal Deformity Revision Surgery

Keith H. Bridwell

♦ Reasons for Revision Surgery

The problems that commonly lead to revision surgery in the adult spinal deformity patient include (1) sagittal imbalance, (2) coronal imbalance, (3) combined imbalance, (4) pseudarthrosis, (5) infection, (6) marked degeneration distal to a fusion, (7) marked degeneration proximal to a fusion, and (8) implant failure or pullout, especially at L5 and the sacrum.

It is often debatable whether to perform revisions procedures in 1 or 2 days.[1,2] It is certainly possible to perform anterior and posterior surgery in the same day/same anesthesia. Decisions on 1 day versus 2 days usually center on issues of total blood loss and the time required to complete the procedure. At times, if performing one side of the spine has a substantial neurologic risk, it may be beneficial to perform that side first and be absolutely certain that the patient is neurologically intact before proceeding with the second stage. Although neurophysiologic spinal cord monitoring is quite helpful, it is not 100% accurate.

If staging is advisable, then there are many possible combinations. A posterior-posterior combination has been reported and may be useful in circumstances where there are many potential surgical surprises with the posterior exploration, and segmental posterior spinal instrumentation has to be removed (especially if it is a generation of implants that is difficult to dissemble). Also, the blood loss anticipated with an exploration procedure has to be considered. It is advisable to assume that a pedicle subtraction procedure is going to be associated with a very significant blood loss, although this is not always the case.

Nutritional concerns are important for the revision patient.[3–5] If a substantial revision operation is being considered, it is more likely to be complication-free if the patient is otherwise healthy. An older patient who is perhaps diabetic and perhaps a chronic cigarette smoker is likely to have a much higher risk of early and late complications. Preoperative nutritional supplementation is often useful if the patient is compliant. For staged surgeries, the preference at our institution is to perform parenteral hyperalimentation between operations. Parenteral hyperalimentation is best applied through a subclavian catheter, which we will often have inserted in the interventional radiology suite on an elective basis the day before the operative procedure. When a long day of revision surgery is being contemplated, it is quite critical that the skin incision be made early in the morning. Therein, having the subclavian catheter inserted along with verification of its correct placement in advance of the operative procedure facilitates accomplishing the surgical goals.

Sagittal Imbalance

There is a range of sagittal imbalance from no global imbalance (C7 plumb relative to L5-S1) to a slight sagittal imbalance (0 to 5 cm) to a major imbalance (5 to 15 cm) and to a very major sagittal imbalance (>15 cm).

Our preference is to do Smith-Petersen[6] osteotomies if we are seeing a smooth kyphosis; see Case no. 1 **(Fig. 23–1)**. If there is a sharp, angular kyphosis then our preference is to do a pedicle subtraction osteotomy[7]; see Case no. 2 **(Fig. 23–2)**.

For the slight global sagittal imbalance from 0 to 5 cm, consider increasing lordosis in part by doing anterior fusion with cages or fresh frozen femoral rings at segments distal to the fusion to increase distal lordosis and also consider including two to three Smith-Petersen osteotomies in the midlumbar spine without any anterior surgery. Usually, Smith-Petersen osteotomies will accomplish ~10 degrees of correction per level.

For a moderate imbalance from 5 to 15 cm, consider three or more Smith-Petersen osteotomies or a pedicle subtraction procedure[8–11] **(Fig. 23–3)**. Currently, our preference is the pedicle subtraction osteotomy. We can usually accomplish 10 to 15 cm

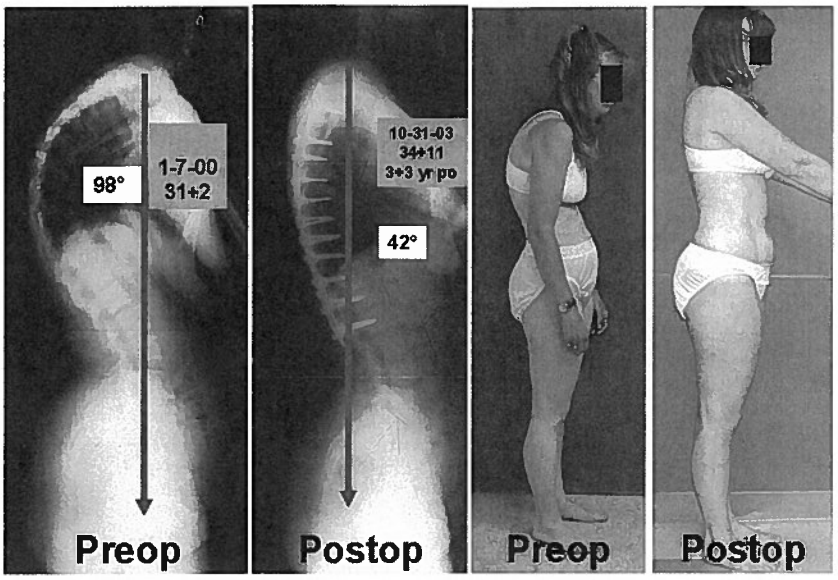

Figure 23–1 Case no. 1: A young adult female presented having had previous surgery for Scheuermann's kyphosis. She initially had a 75-degree kyphosis. She was treated with thoracoscopic releases and anterior fusion at multiple levels and then posterior instrumentation and fusion at another institution. There were problems with the implants posteriorly, so her initial operating surgeons removed those implants. After removal of the implants, her kyphosis then progressed to 98 degrees, substantially more than preoperatively. This 98-degree kyphosis was fixed. Because it was a long sweeping kyphosis, she was treated at our institution with multiple anterior releases through a formal thoracotomy and then multiple Smith-Petersen osteotomies at all levels in the thoracic spine with pedicle screw fixation to achieve the construct that is shown. She is currently 3.5 years post-op.

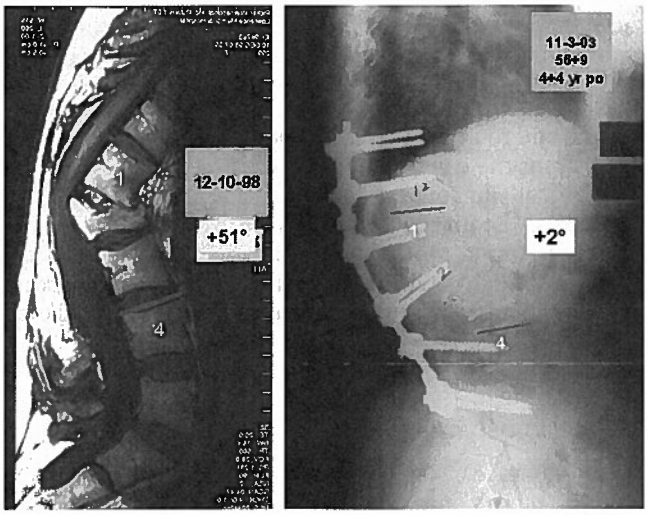

Figure 23–2 Case no. 2: This patient presented with a sharp angular kyphosis. She had a fracture many years ago that was treated with laminectomy and fusion in situ without instrumentation at another institution. Because of the sharp angular nature, she was treated at our institution with a midlumbar pedicle subtraction osteotomy along with fusion and instrumentation. She had evidence of breakdown of the L4-L5 disk and a substantial synovial cyst at that level. Therein, the fusion was extended to L5. She is currently 4.5 years post-op.

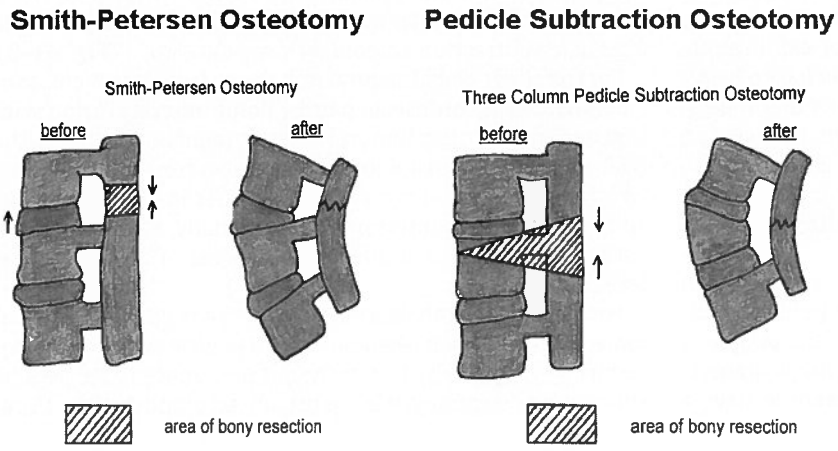

Figure 23–3 Smith-Petersen osteotomy resects bone in the posterior column through the facet joints. This opens up anteriorly at the disk space. Pedicle subtraction osteotomy resects bone through the facet joints, the pedicles, and the vertebral body. It hinges on the anterior cortex. There is theoretically no opening anteriorly.

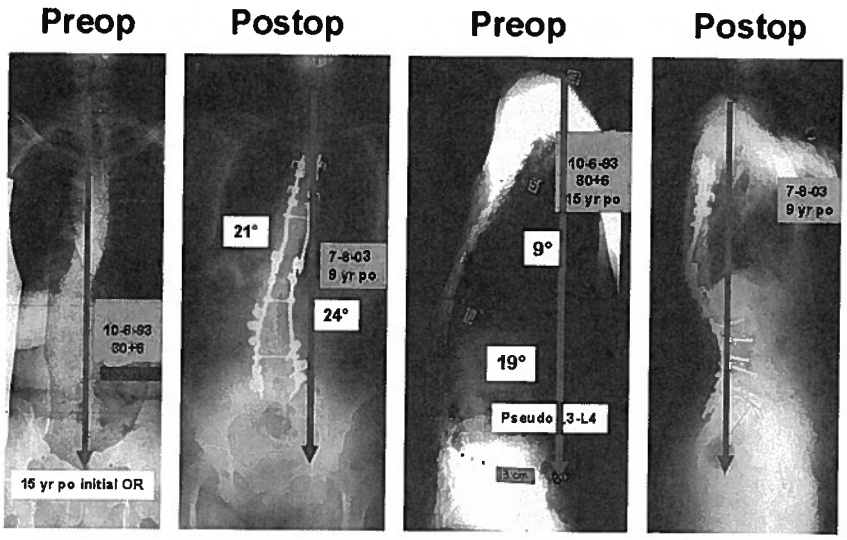

Figure 23–4 Case no. 3: This young adult patient presented with prior surgery for idiopathic scoliosis. She was previously treated with a Harrington rod. There was pseudarthrosis at L3-L4 with some spinal stenosis at that segment. Her coronal balance was excellent. In the sagittal plane, she had very positive sagittal balance. She was treated at our institution with a multiple-level anterior release and fusion along with multiple-level posterior Smith-Petersen osteotomies. The Smith-Petersen osteotomies were performed symmetrically. This provided excellent correction of her sagittal deformity. Unfortunately, it did pitch her to the concavity. This is a risk of doing multiple Smith-Petersen osteotomies through areas of residual scoliosis and rotation. She is currently 9 years post-op.

of correction of the C7 plumb and 35 degrees of correction of kyphosis with this procedure.[12,13] It heals predictably if performed through a fusion mass; see Case no. 3 (**Fig. 23–4**).

For severe imbalance >15 cm, consider combining pedicle subtraction and Smith-Petersen osteotomies; or, in certain extreme circumstances, consider two pedicle subtraction procedures.

One problem with performing multiple Smith-Petersen osteotomies is that the procedure shortens the posterior column and lengthens the anterior column. Therein, if the Smith-Petersen osteotomies are performed through areas of residual scoliosis and rotation, there is a potential of pitching the patient toward the concavity even if the osteotomies are done symmetrically or somewhat bigger on the convex side. This was noted by Booth et al.[14]; see Case no. 4 (**Fig. 23–5**).

We have found that pedicle subtraction procedures are helpful in patients with idiopathic scoliosis and superimposed degenerative changes, degenerative sagittal imbalance,

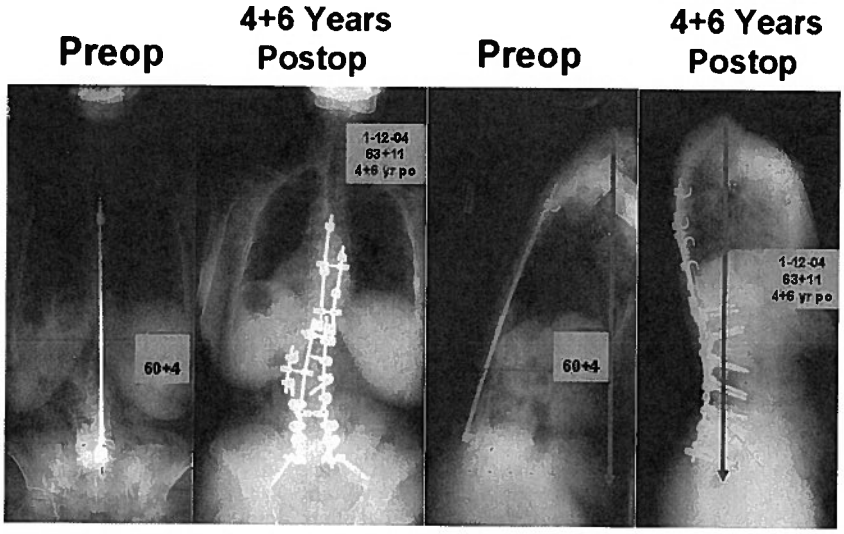

Figure 23–5 Case no. 4: This is a patient with prior idiopathic scoliosis surgery with fusion and instrumentation to L5. She presented to us with severe degenerative disk disease at L5-S1 and inability to stand erect. Surgical treatment at our institution consisted of pedicle subtraction osteotomy in the midlumbar spine and circumferential fusion at L5-S1 with structural support and sacropelvic fixation. Her pedicle subtraction osteotomy was done at the apex of her lumbar scoliosis, through an area of substantial rotation. The osteotomy was performed symmetrically. The sagittal correction was quite good. Note there is no problem with coronal imbalance in this case. The patient is currently 4+6 years post-op.

post-traumatic kyphosis, and ankylosing spondylitis. The degenerative sagittal imbalance patients are those who start off with fusion, instrumentation, and decompression in the distal lumbar spine and then have procedures that include L4-L5 and then L3-L4, a situation of working up rather than down the spine. These patients are somewhat older, usually not as healthy as those with prior idiopathic scoliosis surgery and, therein, are more apt to have complications with their surgical revision.

Three major problems we have found with performing pedicle subtraction osteotomies are (1) non-union of levels added to the fusion, especially proximally if done without anterior surgery, (2) neurologic deficit, usually unilateral one- or two-level root compression not detected by somatosensory potential monitoring, and (3) proximal junctional kyphosis. For that reason, when closing a pedicle subtraction osteotomy, it is essential to watch for subluxation and to enlarge the canal centrally. Then, with a Woodson elevator feel north, south, east, and west to be sure there is no nerve root compression. See steps 1 to 6 for the performance of the pedicle subtraction osteotomy **(Figs. 23–6A to 23–6C; Table 23–1)**.

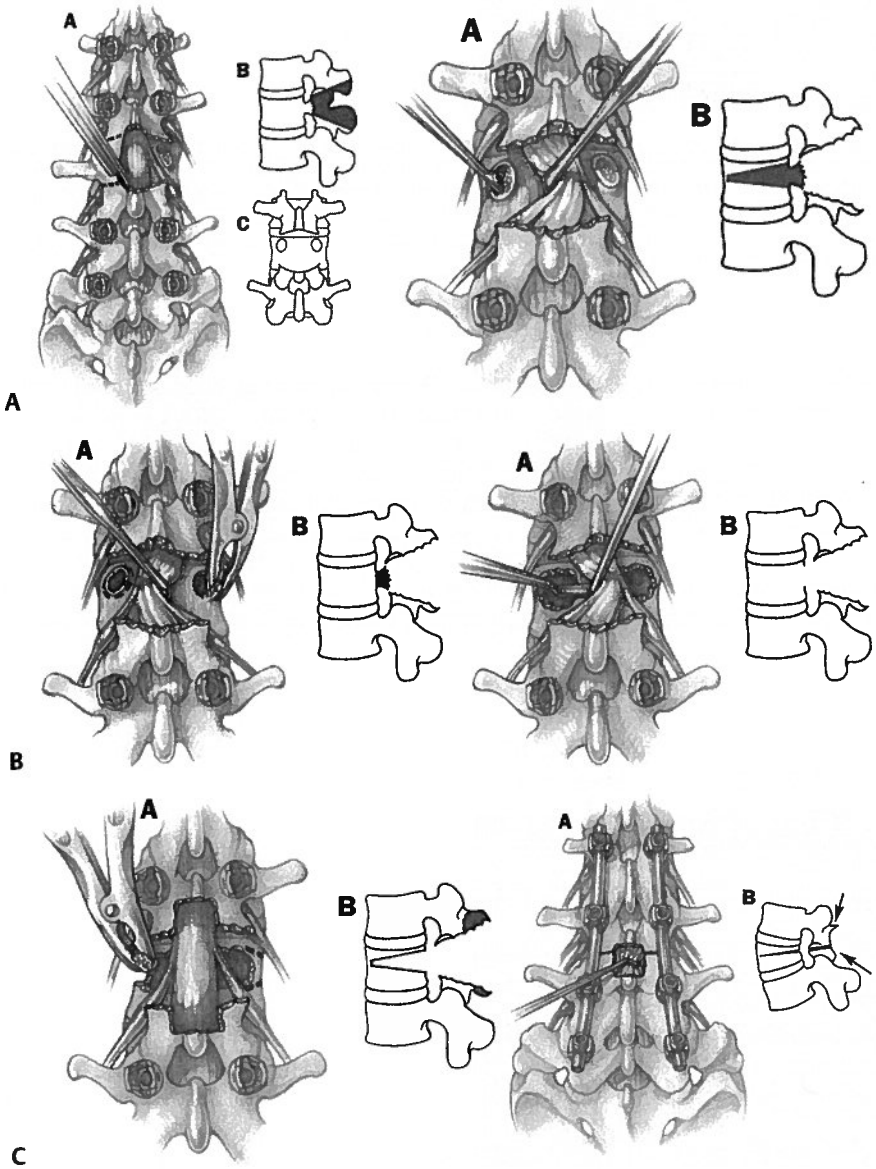

Figure 23–6 **(A)** A symmetrical wedge of bone is resected around the pedicles. Then the pedicles are resected part way into the vertebral body. The vertebral body is decancellated on both sides through the pedicles. **(B)** Next, the posterior vertebral cortex is thinned as much as possible. The posterior vertebral cortex is then green-sticked and resected. **(C)** The central canal is then enlarged somewhat more to facilitate exploration of the spinal canal after the osteotomy is closed. Next, the lateral vertebral walls are resected in a V-shaped fashion and the osteotomy is closed. After closure, it is helpful to place a nerve hook and/or Woodson elevator into the spinal canal and be sure that there is no nerve root impingement. Note the lateral masses are closed together tightly, bone-on-bone. From Bridwell KH, Lewis SJ, Rinella A, Lenke LG, Baldus C, Blanke K. Pedicle subtraction osteotomy for the treatment of fixed sagittal imbalance: surgical technique. J Bone Joint Surg Am 2004;86A(1): 44–50. Reprinted by permission.

Table 23–1 Sagittal Imbalance

Smith-Petersen osteotomies are useful for minor correction, such as 20 degrees or less and change in the C7 plumb of 5 to 6 cm.
Smith-Petersen osteotomies are useful for long sweeping kyphosis curves, especially in the thoracic spine with Scheuermann's or Scheuermann's-like kyphosis.
Pedicle subtraction procedures are most useful for sharp, angular kyphoses.
Pedicle subtraction procedures usually accomplish ~30 to 35 degrees of sagittal correction of a kyphosis and may displace the C7 plumb posteriorly by 12 to 15 cm.

Table 23–2 Coronal Imbalance

Solutions are either shortening the convexity or lengthening the concavity with Type A deformities. Usually, shortening the convexity is preferred.
Shortening the convexity may be performed as several wedges through the facet joints and disks centered on the convexity or a single triangular or trapezoidal wedge performed through bone, mostly commonly through the pedicles.
For a Type B deformity, simply shortening one side of the spine will not rebalance the patient. A vertebral column resection procedure is preferred.

Coronal Imbalance

Frequently, coronal imbalance is related to an oblique take-off from the sacrum. If so, it is necessary to osteotomize that oblique take-off at the lumbosacral junction with closure on the convexity of the fractional curve.

Otherwise, the coronal imbalance may be classified as either Type A or Type B (**Fig. 23–7**). With Type A, the shoulders are tilted in the opposite direction of the pelvis. In this circumstance, the solution is to shorten the convexity. If the shoulders are tilted in the opposite way of the pelvis, then it is necessary to perform something more along the lines of a vertebral resection procedure to rebalance C7 over the sacrum. The goal is to position C7 over the sacrum with the shoulders and pelvis relatively level (**Table 23–2**).

Combined Imbalance

If there is a combined imbalance, then a decision is needed whether to correct both the coronal and sagittal deformities or just the sagittal deformity. Of the two, the sagittal deformity is usually the more disabling. At times, patients will be sick enough that aggressive surgeries to correct both deformities are not possible. And, if so, then it is better to aim for correction of the sagittal deformity.

If the patient is younger, then the options are either a combined surgery or an asymmetric pedicle subtraction procedure; see Case no. 5 (**Figs. 23–8A and 23–8B**). This particular patient had both coronal and sagittal imbalance, and because the shoulders were in the opposite direction of the pelvis, the coronal imbalance could be addressed by shortening the left side of the spine as well as performing the pedicle subtraction osteotomy. It was possible to do the pedicle subtraction osteotomy asymmetrically by performing a bigger wedge on the left side than the right, taking much of the vertebral body all the way around the front to the other side. If the coronal deformity is bigger, then it may be necessary to perform separate anterior and posterior approaches. In this circumstance, the initial anterior approach should be an anterior corpectomy followed by the posterior trapezoidal wedge and then ultimately reconstruction of the anterior column either through that posterior approach or a separate anterior approach. Our preference now is to do an asymmetric pedicle subtraction osteotomy when possible (**Table 23–3**).

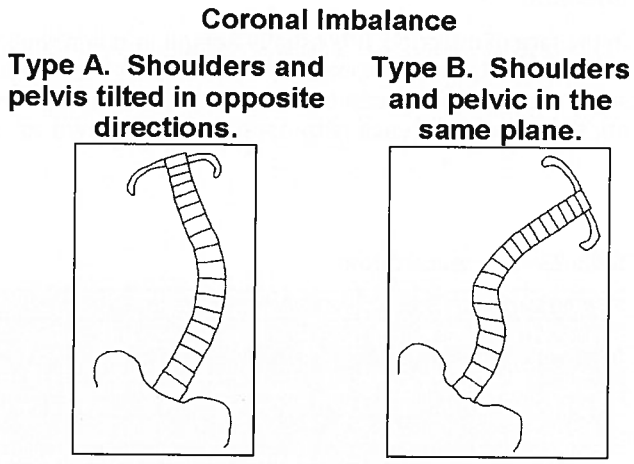

Figure 23–7 Type A and Type B coronal imbalance: For a Type A imbalance, shortening the right-hand side of the spine will correct the problem. For a Type B imbalance, it will not. A vertebral column resection has to be performed in this case. Simply shortening one side or the other of the spine will not rebalance the patient.

Pseudarthrosis

Pseudarthrosis is usually haled by either loss of correction or failure of the implants.[15,16] At times it is straightforward which levels have non-union. In other cases it is not clear. Use of the location of the implant failure, plus standard radiographs, oblique radiographs, bone scans, flexion/extension and side-bending radiographs, including supine and prone hyperextension films, all help identify levels of pseudarthrosis. If it is still not clear, then exploration provides further data.

Circumferential bone grafting is indicated if there are multiple pseudarthroses, postlaminectomy deformity, pseudarthrosis with kyphosis and/or sagittal imbalance. If there is pseudarthrosis with sagittal imbalance, at least part of the equation should be to restore sagittal balance. Autogenous bone graft and bone morphogenetic protein are useful adjuncts.

It is not always necessary to perform combined surgery. If there is no kyphosis at the level of the osteotomy or if the kyphosis can be corrected through a posterior approach, then this may be sufficient. A useful strategy is to perform Smith-Petersen osteotomies through areas of pseudarthrosis,

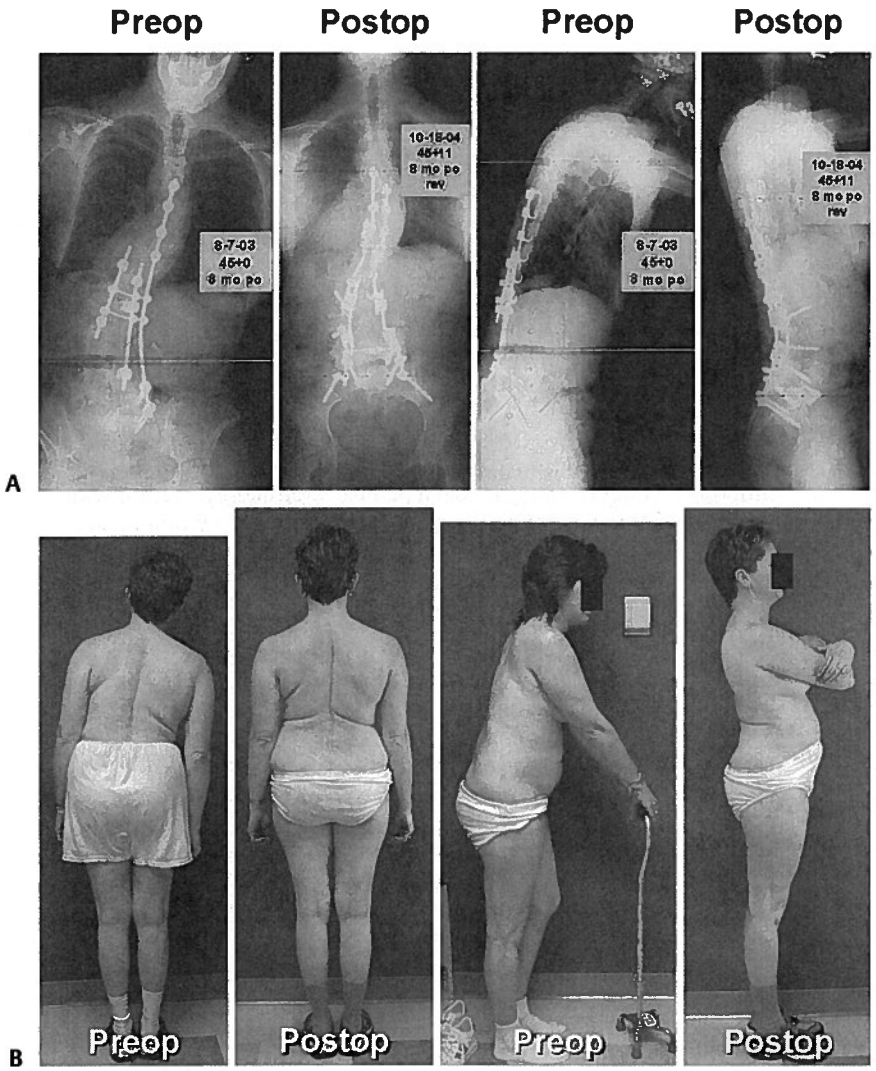

Figure 23–8 Case no. 5: **(A)** Standing long cassette radiographs of a young adult patient who has had 8 prior surgeries on her spine at other institutions. She has fixed coronal and sagittal imbalance. She was treated at our institution with an asymmetric pedicle subtraction osteotomy at L2. Note the coronal and sagittal correction on the pre-op and post-op radiographs. **(B)** The same patient's clinical photographs pre-op and post-op.

especially at the thoracolumbar junction if the kyphosis is mild. After repairing a pseudarthrosis, we only become confident of a solid fusion if the patient is at least 5 years post-op without loss of correction. If multiple pseudarthroses exist with both coronal and sagittal imbalance, then osteotomies and combined surgery will often be useful (**Table 23–4**).

Infection

In the face of infection, it is usually helpful to retain the implants until there is reasonable confidence that the fusion is solid. If an infection presents in the first few months post-op, then our preference is to open the spine down to the

Table 23–3 Combined Imbalance

Shortening the posterior column to correct the sagittal deformity and shortening the convexity to correct the coronal imbalance are recommended.
Assessing the amount of needed correction is more complex.
Asymmetric Smith-Petersen osteotomies at several levels and/or an asymmetric pedicle subtraction procedure are both potential remedies.

Table 23–4 Pseudarthrosis

It is useful to apply compression forces through the pseudarthrosis posteriorly.
Achieving global coronal and sagittal balance is desirable.
Autogenous bone is more useful than allograft.
For difficult pseudarthrosis through a prior laminectomy or multiple-level pseudarthrosis, combined fusions are frequently advisable.
Pseudarthrosis at the lumbosacral junction with a long fusion will usually require anterior and posterior bone grafting with structural grafting anteriorly and 4-point sacropelvic fixation.

Table 23–5 Infection

Early infection should be treated with debridement, suction irrigation, and closure over tubes without removal of the implants.
Early intervention in the operating room with incision and drainage is preferable to delaying such a procedure and only putting a patient on antibiotics.
"Late" infection almost always represents implant infection and not osteomyelitis. It can be addressed by removal of the implants if the surgeon is confident that a fusion is solid.
Be very hesitant to remove implants in an elderly female patient with laminectomies and long fusion as stress fracture can occur through these segments when the implants are removed.

Table 23–6 Marked Degeneration Distal to a Fusion

It is common that teenage idiopathic fusions to L3, L4, or L5 result in eventual degeneration of segments below and ultimately require extension of the fusion to the sacrum.
In many circumstances, osteotomies of the fusion mass will be necessary to realign C7 over the lumbosacral disk.
When extending to the sacrum in this circumstance, it is usually advisable to structurally graft those levels (usually through a paramedian-type of incision).
When extending to the sacrum, 4-point fixation of the sacropelvic unit is advisable. Our institutional preference is bilateral bicortical S1 screws through the promontory and bilateral iliac screws.

implants, debride granulation tissue, and then close over suction irrigation tubes. In this case, we usually institute intravenous antibiotics for six weeks and maintain oral antibiotics until the implants are ultimately removed. Other considerations are the use of wound vacuum suction drains, removing the implants and placing new implants in a simultaneous or staged procedure, and considering surgical fusion on the anterior side of the spine if it has not already been performed. Infection is much more common posteriorly than anteriorly. A potential problem is removing the posterior implants prematurely before being "positive" that there is a solid fusion. It is best for the surgeon to err on the side of retaining the implants and keeping the patient on long-term antibiotics if at all possible. Those at greatest risk for infection are those patients with multiple prior surgeries, noncompliant lifestyle, cigarette smokers, and diabetics (**Table 23–5**).

Marked Degeneration Distal to a Fusion

Marked degeneration distal to a fusion is common, especially with long fusions.[17] In this circumstance, it is best to extend the fusion both anteriorly and posteriorly, either with separate approaches or a TLIF (transforaminal lumbar interbody fusion) procedure to provide structural support anteriorly and to preserve distal lordosis. If the patient's sagittal balance is satisfactory and the segmental lordosis of those segments previously operated is within a normal range, it is not necessary to perform osteotomies. If the patient is in positive sagittal balance and has severe disk degeneration below, then it may be necessary to include osteotomies. In certain cases, there may be substantial spinal stenosis of segments below. If the patient has spinal claudication symptoms, then decompression might also be required (**Table 23–6**).

Marked Degeneration Proximal to a Fusion

We see this commonly in the degenerative sagittal imbalance patient. Often, there is coexistent stenosis proximally. Most commonly, the advisable procedure is to reinstrument the distal lumbar fusion, decompress the proximal levels as needed, and extend the fusion and instrumentation up to a segment that is either without marked degeneration or is within the sagittal stable zone of the patient. If the patient is markedly pitched forward, then a pedicle subtraction osteotomy may be needed through the prior fusion. Precisely when to do a combined versus posterior-only surgery is not entirely clear; see Case no. 6 (**Figs. 23–9A and 23–9B**; **Table 23–7**).

Implant Failure or Pullout (Especially at L5 or the Sacrum)

Ending a long construct at L5 or the sacrum is often associated with minor or major loosening of the implants distally with some potential for pullout.[17] Although the use of pedicle screws has been a major advance, the L5 and S1 pedicles are not ideal for screw placement. With a long construct stopping at L5, it is preferable to place the L5 screws bicortical, although there may be some risk associated with that. When going down to the sacrum, it is definitely necessary to achieve bicortical purchase at S1. If going down to S1, it is also preferable to provide anterior column support at L5-S1 and protection of the sacral screws with either distal sacral fixation points or iliac screws.[18,19]

With loss of fixation at L5, it is often necessary to extend down to the sacrum and pelvis and to perform structural grafting at L4-L5 and L5-S1. With loss of fixation of the sacral screws, it is often then necessary to not only extend down to the sacrum and pelvis but also to perform anterior column support at L5-S1 and to potentially perform osteotomies to rebalance the patient (**Table 23–8**).

♦ Conclusion

The most common problems leading to revision of the adult spinal deformity patient are pseudarthrosis, sagittal imbalance, marked degeneration proximal or distal to a fusion, and implant failure, especially distally at L5 and the sacrum.

Remedies include a combination of further segmentalization of the instrumentation, protection of L5 and sacral screws with anterior column support and iliac screws, Smith-Petersen osteotomies, and pedicle subtraction procedures.

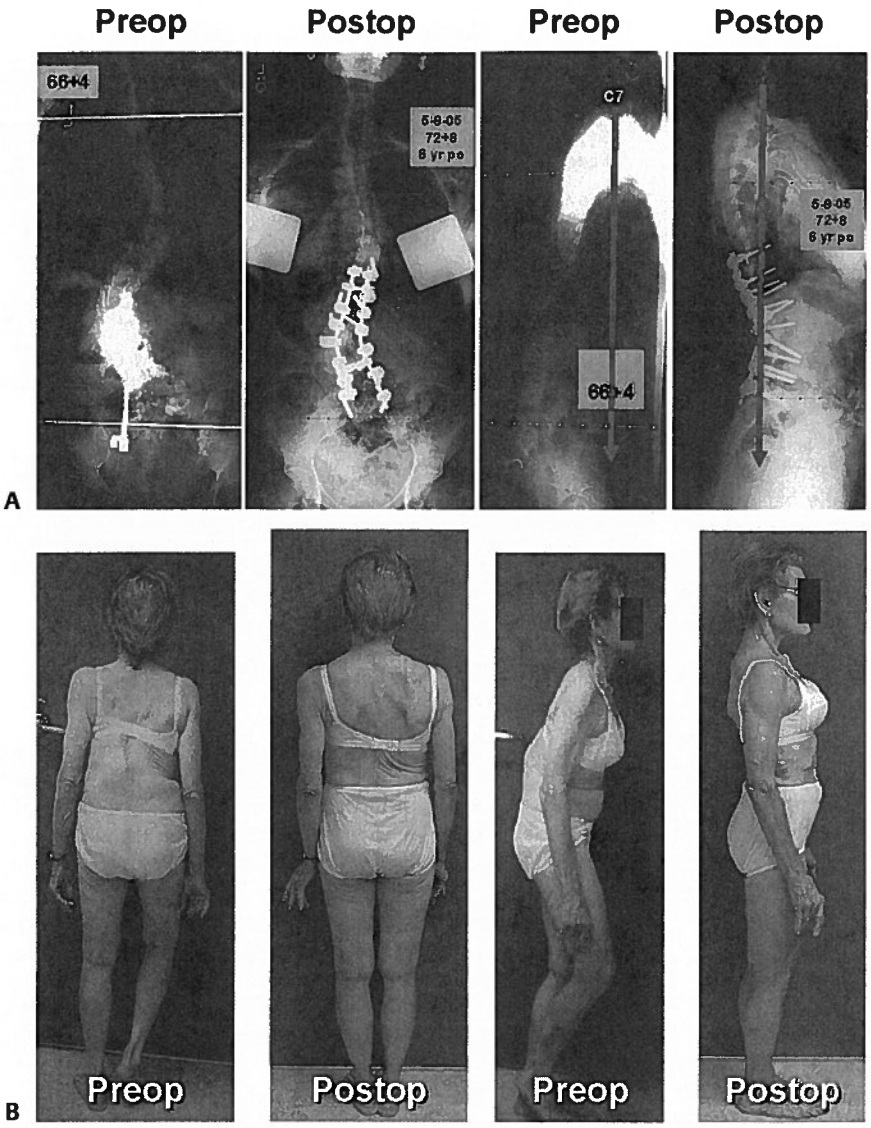

Figure 23–9 Case no. 6: **(A)** Standing long cassette radiographs on an elderly female pre-op and 4.5 years post-op. She presented to us having had fusion and instrumentation from L3 to the sacrum. There was pseudarthrosis at L3-L4. She developed a progressive kyphosis and spinal stenosis above. This is a degenerative sagittal imbalance classification. She was treated at our institution with the appropriate spinal stenosis decompressions and also pedicle subtraction osteotomy through the midlumbar spine and extension of the fusion and instrumentation up to the distal thoracic spine. **(B)** Pre-op and post-op clinical photos of this patient. She is currently close to 5 years post-op.

Table 23–7 Marked Degeneration Proximal to a Fusion

Usually seen in patients with a degenerative sagittal imbalance. This is usually an older group of patients, more osteoporotic and with more comorbidities than the idiopathic group that degenerates distal to a fusion.
Pedicle screw implants are very helpful.
The exact role for posterior-only surgery versus combined surgery is not clear. Pseudarthrosis in the distal thoracic spine is quite common.
Osteotomies through the distal fusion mass are often needed.

Table 23–8 Implant Failure

For long fusions to L5, implant failure at L5 is not uncommon. The L5 pedicles are short and cancellous. If doing a long fusion to L5, it is probably preferable to place L5 screws in a bicortical fashion and/or to consider load sharing at L4-L5.
When performing a long fusion to the sacrum on an adult ambulatory patient, our institutional preference is to always structurally graft at L5-S1 and to perform 4-point fixation of the sacrum and pelvis. Even if the patient has had prior iliac harvesting, it may still be possible to place iliac screws.

References

1. Rhee JM, Bridwell KH, Lenke LG, Baldus C, Blanke K, Berra A. Staged posterior surgery for severe adult deformity. Spine 2003;28(18): 2116–2121
2. Shufflebarger HL, Grimm JO, Bui V, et al. Anterior and posterior spinal fusion: staged versus same-day surgery. Spine 1991;16:930–933
3. Lapp MA, Bridwell KH, Lenke LG, Baldus C, Blanke K, Iffrig TM. Prospective randomization of parenteral hyperalimentation for long fusions with spinal deformity: its effect on complications and recovery from postoperative malnutrition. Spine 2001;26(7):809–817
4. Mandelbaum BR, Tolo VT, McAfee PC, et al. Nutritional deficiencies after staged anterior and posterior spinal reconstructive surgery. Clin Orthop Relat Res 1988;234:5–11
5. Hu SS, Fontaine F, Kelly B, et al. Nutritional depletion in staged spinal reconstructive surgery: the effect of total parenteral nutrition. Spine 1998;23(12):1401–1405
6. Smith-Petersen MN, Larson CB, Aufranc OE. Osteotomy of the spine for correction of flexion deformity in rheumatoid arthritis. Clin Orthop Relat Res 1969;66:6–9
7. Thomasen E. Vertebral osteotomy for correction of kyphosis in ankylosing spondylitis. Clin Orthop Relat Res 1985;194:142–152
8. Kostuik JP, Maurais GE, Richardson WJ, Okajima Y. Combined single staged anterior and posterior osteotomy for correction of iatrogenic lumbar kyphosis. Spine 1988;13(3):257–266
9. Lagrone MO, Bradford DS, Moe JH, Lonstein JE, Winter RB, Ogilvie JW. Treatment of symptomatic flatback after spinal fusion. J Bone Joint Surg Am 1988;70(4):569
10. Farcy J-PC, Schwab FJ. Management of flatback and related kyphotic decompensation syndromes. Spine 1997;22:2452–2457
11. Berven SH, Deviren V, Smith JA, Emami A, Hu SS, Bradford DS. Management of fixed sagittal plane deformity: results of the transpedicular wedge resection osteotomy. Spine 2001;26:2036–2043
12. Bridwell KH, Lewis SJ, Lenke LG, Baldus C, Blanke K. Pedicle subtraction osteotomy for the treatment of fixed sagittal imbalance. J Bone Joint Surg Am 2003;85(3):454–463
13. Bridwell KH, Lewis S, Edwards C, et al. Complications and outcomes of pedicle subtraction osteotomies for fixed sagittal imbalance. Spine 2003;28(18):2093–2101
14. Booth KC, Bridwell KH, Lenke LG, Baldus CR, Blanke KM. Complications and predictive factors for the successful treatment of flatback deformity (fixed sagittal imbalance). Spine 1999;24(16):1712–1720
15. Edwards CC II, Bridwell KH, Patel A, Rinella A, Berra A, Lenke LG. Long adult deformity fusions to L5 and the sacrum: a matched cohort analysis. Spine 2004;29(18):1996–2005
16. Rinella A, Bridwell K, Kim Y, et al. Late complications of adult idiopathic scoliosis primary fusions to L4 and above. The effect of age and distal fusion level. Spine 2004;29(3):318–325
17. Edwards CC II, Bridwell K, Patel A, et al. Thoracolumbar deformity arthrodesis to L5 in adults: the fate of the L5–S1 disk. Spine 2003; 28(18):2122–2131
18. Kuklo TR, Bridwell KH, Lewis SJ, et al. Minimum 2-year analysis of sacropelvic fixation and L5–S1 fusion using S1 and iliac screws. Spine 2001;26(18):1976–1983
19. Saer EH 3rd, Winter RB, Lonstein JE. Long scoliosis fusion to the sacrum in adults with nonparalytic scoliosis: an improved method. Spine 1990;15:650–653

Chapter 24

Surgical Treatment of Spondylolisthesis

Ronald L. DeWald and Christopher J. DeWald

Spondylolisthesis is the ventral displacement of the proximal spinal column to the distal spinal column. Taillard[1,2] describes spondylolisthesis as a "forward slippage of the vertebral body together with its pedicles, transverse processes, and upper articular processes engendered by a break in the continuity or an elongation of the pars interarticularis." The most common location of spondylolisthesis is the lumbosacral junction, although it may be found anywhere in the spine.

The spine that is slipping carries the trunk along with it. Spondylolisthesis is the end result of different pathologic processes. These processes result in similar deformities because of the morphology and biomechanics of the lumbosacral junction. Stability of the lumbosacral junction in the human is dependent on the pelvic incidence (the sum of the sacral slope and the pelvic tilt) and an intact bone, disk ligamentous complex. The pelvic incidence does not change and is the pelvic morphology that will determine stance attitudes of the spine. The spatial orientation of L5 to the sacrum invites shear forces. The shear forces are resisted by the disk and the posterior bony elements. The pars interarticularis is the bony bridge between L5 and the sacrum and is the weak link. Once the tension band or bony hook is lost by either fracture or dysplasia, the anterior column can migrate forward.

Every surgeon who sees patients with spondylolisthesis knows that most do not progress, some progress a great deal, some are not painful, some are very painful, and most are not deforming, whereas some are very deforming. Some respond to in situ posterior-lateral fusion whereas some progress and have multiple pseudarthoses. It is most important for the surgeon to carefully analyze each case and gain as much information as possible before proposing a surgical intervention.

The condition was first described by Herbiniaux,[3] a Belgium obstetrician who found the dislocation impeded a normal delivery. Few topics in spinal pathology have such varied clinical and anatomic aspects as spondylolisthesis. There are few pathologic conditions of the spine for which there are so many controversial procedures.

♦ Classification

The classification of spondylolisthesis is important to study. It is important to classify and analyze each individual patient's spondylolisthesis. Newman[4] and Wiltse[5,6] have their classifications, but we believe the Marchetti-Bartolozzi[7] (1994) classification is the best to date (**Table 24–1**).

This classification divides the spondylolisthesis into two groups: developmental and acquired. This is fundamental and will make studying this condition easier to understand.

The developmental group is further divided into high and low dysplasia both with lysis or elongation of the pars. The low dysplastic group is not as difficult to treat as the high dysplastic group. The high dysplastic group with L5 rolling forward was once thought of as congenital, but that would be as rare as a teratologic hip dislocation. These slips have the potential to progress to a spondyloptosis if untreated or mismanaged.

The presence of an intact neural arch in these high dysplastic cases presents with a high risk of cauda equina syndrome prior to or at the time of surgical intervention.

The acquired forms are self-evident and the most common are the athletic, the postsurgical, and the degenerative groups. The degenerate group may be seen with or without a lytic defect of the pars (**Fig. 24–1**).

Table 24–1 Spondylolisthesis Marchetti-Bartolozzi Classification (1994)

Developmental	Acquired
Low dysplasia	Traumatic
Lysis or elongation	Acute
High dysplasia	Stress
Lysis or elongation	Postsurgery
	Pathologic

References

1. Rhee JM, Bridwell KH, Lenke LG, Baldus C, Blanke K, Berra A. Staged posterior surgery for severe adult deformity. Spine 2003;28(18): 2116–2121
2. Shufflebarger HL, Grimm JO, Bui V, et al. Anterior and posterior spinal fusion: staged versus same-day surgery. Spine 1991;16:930–933
3. Lapp MA, Bridwell KH, Lenke LG, Baldus C, Blanke K, Iffrig TM. Prospective randomization of parenteral hyperalimentation for long fusions with spinal deformity: its effect on complications and recovery from postoperative malnutrition. Spine 2001;26(7):809–817
4. Mandelbaum BR, Tolo VT, McAfee PC, et al. Nutritional deficiencies after staged anterior and posterior spinal reconstructive surgery. Clin Orthop Relat Res 1988;234:5–11
5. Hu SS, Fontaine F, Kelly B, et al. Nutritional depletion in staged spinal reconstructive surgery: the effect of total parenteral nutrition. Spine 1998;23(12):1401–1405
6. Smith-Petersen MN, Larson CB, Aufranc OE. Osteotomy of the spine for correction of flexion deformity in rheumatoid arthritis. Clin Orthop Relat Res 1969;66:6–9
7. Thomasen E. Vertebral osteotomy for correction of kyphosis in ankylosing spondylitis. Clin Orthop Relat Res 1985;194:142–152
8. Kostuik JP, Maurais GE, Richardson WJ, Okajima Y. Combined single staged anterior and posterior osteotomy for correction of iatrogenic lumbar kyphosis. Spine 1988;13(3):257–266
9. Lagrone MO, Bradford DS, Moe JH, Lonstein JE, Winter RB, Ogilvie JW. Treatment of symptomatic flatback after spinal fusion. J Bone Joint Surg Am 1988;70(4):569
10. Farcy J-PC, Schwab FJ. Management of flatback and related kyphotic decompensation syndromes. Spine 1997;22:2452–2457
11. Berven SH, Deviren V, Smith JA, Emami A, Hu SS, Bradford DS. Management of fixed sagittal plane deformity: results of the transpedicular wedge resection osteotomy. Spine 2001;26:2036–2043
12. Bridwell KH, Lewis SJ, Lenke LG, Baldus C, Blanke K. Pedicle subtraction osteotomy for the treatment of fixed sagittal imbalance. J Bone Joint Surg Am 2003;85(3):454–463
13. Bridwell KH, Lewis S, Edwards C, et al. Complications and outcomes of pedicle subtraction osteotomies for fixed sagittal imbalance. Spine 2003;28(18):2093–2101
14. Booth KC, Bridwell KH, Lenke LG, Baldus CR, Blanke KM. Complications and predictive factors for the successful treatment of flatback deformity (fixed sagittal imbalance). Spine 1999;24(16):1712–1720
15. Edwards CC II, Bridwell KH, Patel A, Rinella A, Berra A, Lenke LG. Long adult deformity fusions to L5 and the sacrum: a matched cohort analysis. Spine 2004;29(18):1996–2005
16. Rinella A, Bridwell K, Kim Y, et al. Late complications of adult idiopathic scoliosis primary fusions to L4 and above. The effect of age and distal fusion level. Spine 2004;29(3):318–325
17. Edwards CC II, Bridwell K, Patel A, et al. Thoracolumbar deformity arthrodesis to L5 in adults: the fate of the L5–S1 disk. Spine 2003; 28(18):2122–2131
18. Kuklo TR, Bridwell KH, Lewis SJ, et al. Minimum 2-year analysis of sacropelvic fixation and L5–S1 fusion using S1 and iliac screws. Spine 2001;26(18):1976–1983
19. Saer EH 3rd, Winter RB, Lonstein JE. Long scoliosis fusion to the sacrum in adults with nonparalytic scoliosis: an improved method. Spine 1990;15:650–653

Chapter 24

Surgical Treatment of Spondylolisthesis

Ronald L. DeWald and Christopher J. DeWald

Spondylolisthesis is the ventral displacement of the proximal spinal column to the distal spinal column. Taillard[1,2] describes spondylolisthesis as a "forward slippage of the vertebral body together with its pedicles, transverse processes, and upper articular processes engendered by a break in the continuity or an elongation of the pars interarticularis." The most common location of spondylolisthesis is the lumbosacral junction, although it may be found anywhere in the spine.

The spine that is slipping carries the trunk along with it. Spondylolisthesis is the end result of different pathologic processes. These processes result in similar deformities because of the morphology and biomechanics of the lumbosacral junction. Stability of the lumbosacral junction in the human is dependent on the pelvic incidence (the sum of the sacral slope and the pelvic tilt) and an intact bone, disk ligamentous complex. The pelvic incidence does not change and is the pelvic morphology that will determine stance attitudes of the spine. The spatial orientation of L5 to the sacrum invites shear forces. The shear forces are resisted by the disk and the posterior bony elements. The pars interarticularis is the bony bridge between L5 and the sacrum and is the weak link. Once the tension band or bony hook is lost by either fracture or dysplasia, the anterior column can migrate forward.

Every surgeon who sees patients with spondylolisthesis knows that most do not progress, some progress a great deal, some are not painful, some are very painful, and most are not deforming, whereas some are very deforming. Some respond to in situ posterior-lateral fusion whereas some progress and have multiple pseudarthoses. It is most important for the surgeon to carefully analyze each case and gain as much information as possible before proposing a surgical intervention.

The condition was first described by Herbiniaux,[3] a Belgium obstetrician who found the dislocation impeded a normal delivery. Few topics in spinal pathology have such varied clinical and anatomic aspects as spondylolisthesis. There are few pathologic conditions of the spine for which there are so many controversial procedures.

♦ Classification

The classification of spondylolisthesis is important to study. It is important to classify and analyze each individual patient's spondylolisthesis. Newman[4] and Wiltse[5,6] have their classifications, but we believe the Marchetti-Bartolozzi[7] (1994) classification is the best to date **(Table 24–1)**.

This classification divides the spondylolisthesis into two groups: developmental and acquired. This is fundamental and will make studying this condition easier to understand.

The developmental group is further divided into high and low dysplasia both with lysis or elongation of the pars. The low dysplastic group is not as difficult to treat as the high dysplastic group. The high dysplastic group with L5 rolling forward was once thought of as congenital, but that would be as rare as a teratologic hip dislocation. These slips have the potential to progress to a spondyloptosis if untreated or mismanaged.

The presence of an intact neural arch in these high dysplastic cases presents with a high risk of cauda equina syndrome prior to or at the time of surgical intervention.

The acquired forms are self-evident and the most common are the athletic, the postsurgical, and the degenerative groups. The degenerate group may be seen with or without a lytic defect of the pars **(Fig. 24–1)**.

Table 24–1 Spondylolisthesis Marchetti-Bartolozzi Classification (1994)

Developmental	Acquired
Low dysplasia	Traumatic
Lysis or elongation	Acute
High dysplasia	Stress
Lysis or elongation	Postsurgery
	Pathologic

A

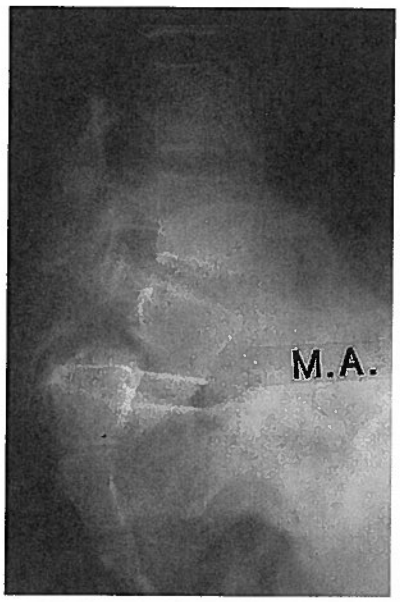

B

Figure 24–1 These x-ray images illustrate the difference between developmental and acquired spondylolisthesis. The acquired form in **(A)** has a translational slip and no deformity of the sacrum and/or L5. The developmental form **(B)** has the forward roll of L5, the deformity of the sacrum, the elongated and separated pars. These cases are very different types of spondylolisthesis. The deformity and the appearance of the sacrum in the developmental type can be explained by the histology of the condition seen in **Fig. 24–3**. The doming of the sacrum is the result of the epiphysiolysis and the Hueter-Volkman epiphyseal pressure rule.

♦ Diagnosis

The diagnosis is usually made on x-ray imaging. Sometimes it will be discovered incidentally on genital-urinary or bowel x-ray films. The fact that someone thought enough of the complaints to warrant an x-ray indicates that the condition is symptomatic at some times.

Many young patients are brought in with x-ray films and say they have no complaints. These patients need close observation and some physical training.

The usual x-ray types are the standard anterior/posterior (AP), lateral (Lat.), both obliques, and spot lateral. Standing lateral is needed, and an MRI is important if an intervention is contemplated. With this information, the surgeon should be able to decide if the spondylolisthesis is developmental or acquired. If the developmental form is diagnosed, the degree of dysplasia is determined. The quality of the pedicles, pars, and inferior facets of L5 are noted. The sacral facets are noted along with the presence of spina bifida. These elements make up the bony hook. The age of the patient is important as progression will be seen in young, high dysplastic patients. The standing lateral x-ray will help determine the degree of lordosis and the gravity line. Pelvic incidence may be measured. The sacrum may be deformed and should be noted. Sometimes the sacrum will appear bent and look like a shrimp.[8] The height, hydration, and competency of the disk are ascertained **(Fig. 24–2)**.

It is vital to know all these facts when making a diagnosis and planning treatment. It is not just simply another "isthmic spondylolisthesis."

♦ Age of Patient

Spondylolisthesis in patients with an open vertebral apophysis occurs through the growth plate. MRIs in children dramatically illustrate this pathology. Research by Sairyo et al. has demonstrated the slip occurring through the growth plate and the subsequent growth changes.[9] They created a surgical defect in the pars of young animals and then studied the sacrums after a period of time. They have histological evidence of the slip through the growth plate, causing an alteration of growth.[10] To the authors' minds, this explains the changes seen in the L5 and sacral bodies in young children with spondylolisthesis **(Fig. 24–3)**.

Patients with less dysplasia or with a stronger bone, disk ligamentous complex have more resistance to shear. Less shear force in children means less growth plate slip. Likewise in patients with less lordosis, there will be less shear force. On the other hand, patients with a large lordosis and high dysplasia (poor bony hook) are set up for large slips and/or bony deformity of the sacrum and L5.

♦ Etiology

There are many theories of etiology for spondylolisthesis.[11–20] The most prevalent one is shear stress across the lumbosacral joint. Upright posture causes shear. Physical activity causes shear. These forces alone may lead to a stress fracture of otherwise healthy pars. The stress is now on the disk or growth plate (depending on age) and a slip may occur.

If the pars is dysplastic and the lordosis severe, slipping will occur.

The common denominator is the verticality of the sacral plateau, quality of the bony hook, and stress. Lordosis is correlated with the sacral slope.

♦ Anatomy

To study anatomy of spondylolisthesis, one must understand several variables. The place to start is stance and the gravity line. A normal spine in stance phase in the coronal plane is

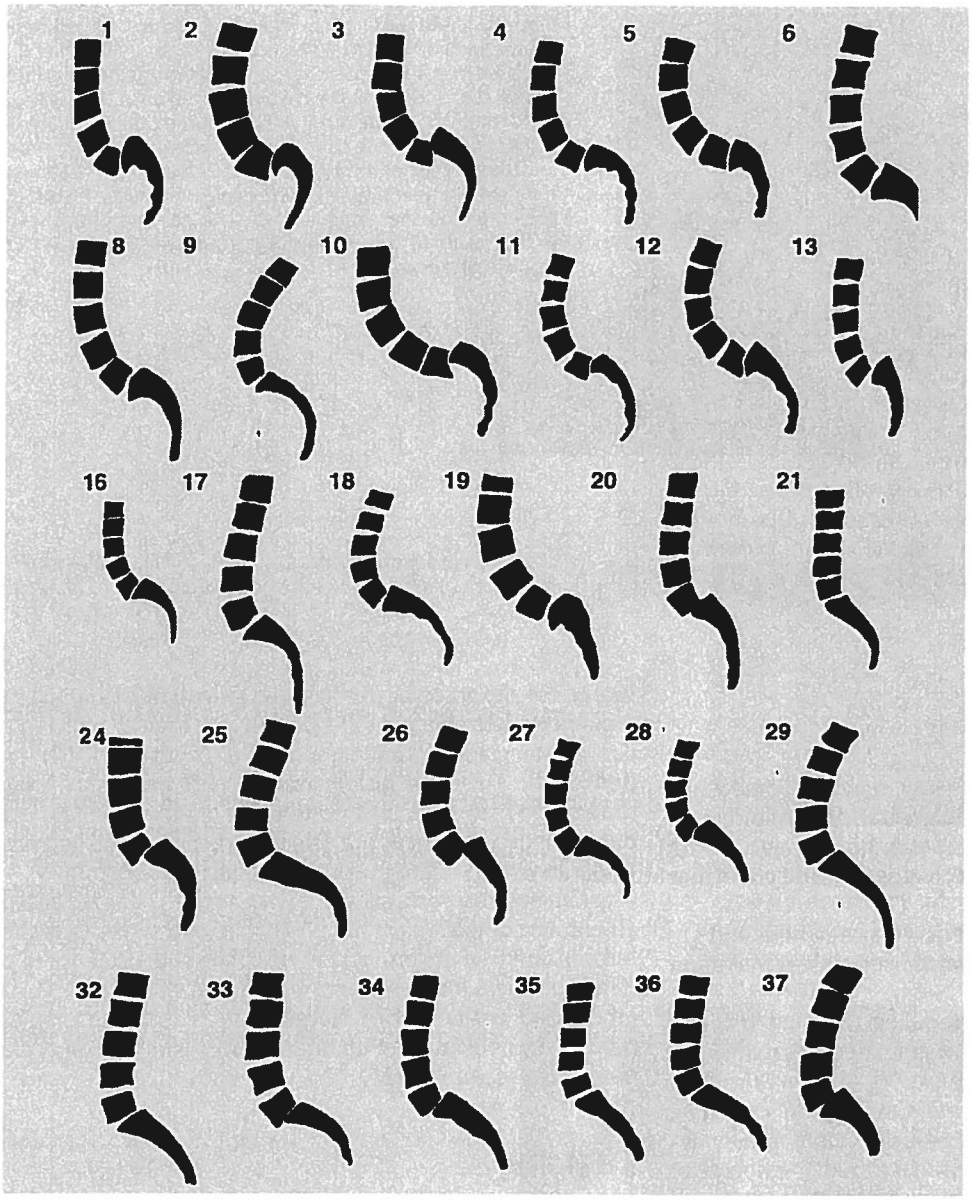

Figure 24–2 These tracings illustrate the variety of sacral shapes seen in spondylolisthesis. The actual final shape of the sacrum and the degree of slip is probably predetermined by the amount of lordosis, the verticality of the sacral slope, and the quality of the posterior tether. The result can be a slip of various degrees, a bent sacrum, or both. All of theses factors are dependent on the morphology of the sacrum. Pelvic incidence is a way to measure the morphology of the pelvis.

straight and in the sagittal plane has several curves. The variety of curves in the sagittal plane has been well described by several authors[21–29] and is illustrated by Stagnara's famous drawing **(Fig. 24–4)**.

Why are there so many normal variations of sagittal configuration of the spine?

Spinopelvic sagittal balance in normal persons is a combination of spinal and pelvic shape parameters. To best determine pelvic morphology, Legaye et al. and Duval-Beaupere et al.[30–34] have described *pelvic incidence* as a fundamental anatomic parameter that is constant and specific for each individual. It determines pelvic orientation and lumbar lordosis. Pelvic incidence (PI) is the angle between a line perpendicular to the sacral plate and a line joining the sacral plate to the axis of the femoral heads **(Fig. 24–5)**.

The *sacral slope* (SS) is defined as the angle the sacral plate makes with the horizontal. *Pelvic tilt* (PT) is defined as the angle of a line from the midpoint of the sacral plate to the vertical. The sum of SS + PT = PI.

Pelvic incidence is a constant and sacral slope and pelvic tilt are variable. Lordosis is dependent on the sacral slope and also on the dorsal kyphosis. These are also variable parameters. Generally, the spinal shape follows the pelvic shape. The more slope, the more lordosis. The more the pelvic incidence increases, the higher will be the sacral slope and the higher the lumbar lordosis.[35,36] However, the lumbar lordosis also must conform with the dorsal kyphosis **(Fig. 24–6)**.

The global gravity line in most normal people lies just anterior to the axis of the femoral heads. The sagittal vertical axis line falls from C7 in front of T7 behind L3 and across

Figure 24–3 **(A)** Three-week postoperative x-ray image of young rat. **(B)** Histologic evaluation reveals the nucleus shifted posteriorly and the normal growth layer disturbed anteriorly; **(C)** reveals magnifcation of the growth plate disturbance.

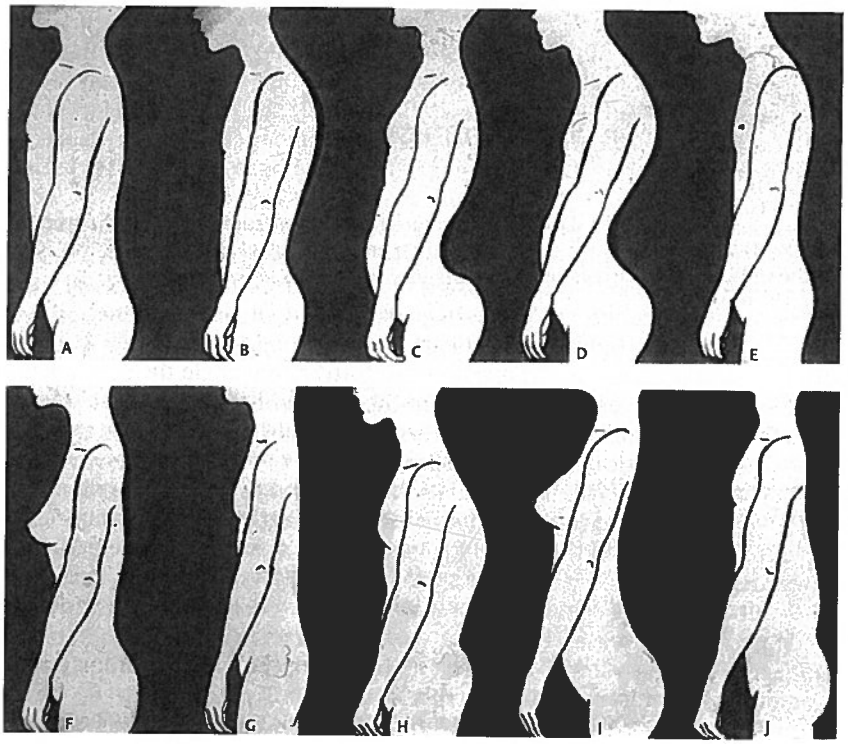

Figure 24–4 This drawing illustrates the possible sagittal variations. These variations are related to the pelvic incidence, the gravity line, the balance between the dorsal kyphosis and lumbar lordosis, femoral anteversion, and probably the trochanter knee ankle line.

PELVIC INCIDENCE

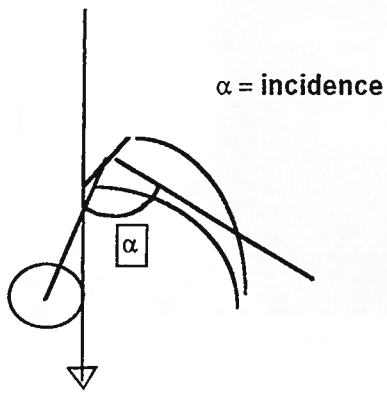

Figure 24–5 Pelvic incidence (PI) is the angle between a line perpendicular to the sacral plate and a line joining the sacral plate to the axis of the femoral heads.

S2.This lines helps to ascertain the global balance of the spine, which is variable.

Vertebral growth continues until ages 16 to 18. Longitudinal growth is by enchrondral ossification. Latitudinal growth is through membranous bone formation, modeling, and remodeling, all of which are biomechanical responsive patterns.[37]

Once we have ascertained the position of the pelvis in space, we can relate the lordosis of the spine to it. Biomechanical studies have continued to show stress concentrations on the pars. It would seem obvious that the more lordotic the spine, the more stress force on the pars.

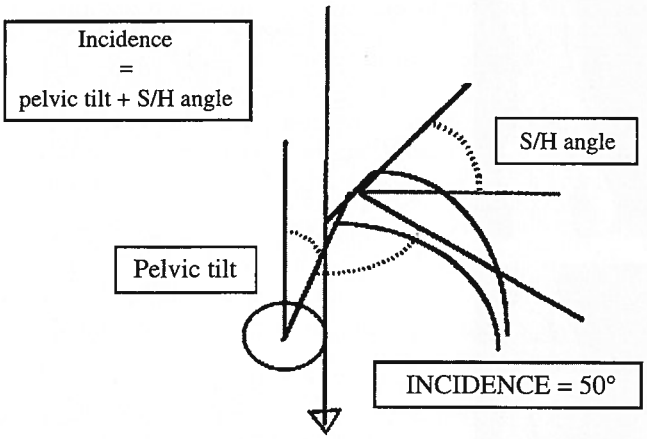

Figure 24–6 The sacral slope (SS) is defined as the angle the sacral plate makes with the horizontal. Pelvic tilt (PT) is defined as the angle of a line from the midpoint of the sacral plate to the vertical. The sum of SS + PT = PI. Pelvic incidence (PI) is a constant, and sacral slope and pelvic tilt are variable. Lordosis is dependent on the sacral slope and also on the dorsal kyphosis. These are also variable parameters. Generally, the sagittal spinal shape follows the pelvic shape.

The lumbar vertebra 5 has strong attachments to the pelvis through the ilio-lumbar ligaments. When L5 is deep in the pelvis or has sacralization, forces may cause the spondylolisthesis to be at the next cephalad level. When attempting to reduce a spondylolisthesis, releasing the contracted ilio-lumbar ligament will aid reduction by mobilizing the segment.

We do not know if other authors have attempted to grade the amount of dysplasia.

We attempted to grade the dysplasia on a 1 to 4 basis.[38] We noted the spina bifida of L5 and sacrum, the quality of the inferior facets of L5, the quality of the sacral facets, the shape of L5 and sacrum, and the elongation or break in the pars. This helped us determine high or low dysplasia.

Another finding not previously studied was the shape of the sacrum. Some sacrums are severely bent, which makes the sacral plateau vertical.[8] This makes reduction difficult and will increase the lordosis if attempted. We believe the sacrum bends because of the degree of lordosis, degrees of the sacral slope, and a good bony hook. This situation is dependent on the pelvic incidence. The stress is present, but if the hook is sound, the sacrum deforms through the growth plate and bends.

The degree of slip continues to be measured by the Meyerding method. It is not the best method but seems to be universally accepted. When the sacrum is domed and L5 wedged, it is difficult to have an accurate measurement. Usually in these cases, the spondylolisthesis will be graded lower than it is, and the surgeon may feel there is time to wait, watch, and see.

The spine is very adaptable; many developmental severe spondylolisthesis may adapt and the clinical appearance will be acceptable and the pain level low. Observation may be the best treatment.

♦ Biomechanics

The body's gravity line falls anterior to the lumbosacral junction. As a result, there is a great shear stress on this joint.[39–47] If the stress cannot be controlled, the spine will slip forward and rotate into flexion around the sacral dome. The pars resist this stress and if deficient from repeated stress fractures and elongation or from dysplasia will not be able to stop the slip. The anterior shear will degenerate the disk and cause further slip. Soon the gravity line is further anterior and the stress forces are increased. Depending on the age of the patient, the pelvic position, quality of the pars, degree of dysplasia, and the bone, disk ligamentous complex strength, the deformity will progress to a predetermined position. Recognizing those that will progress is the most important aspect of treating spondylolisthesis **(Fig. 24–7)**.

Understanding the sagittal contour of the patient is vital to preventing a biomechanical cause for progression. Posterior fusion restores the posterior bony hook and stabilizes the condition.

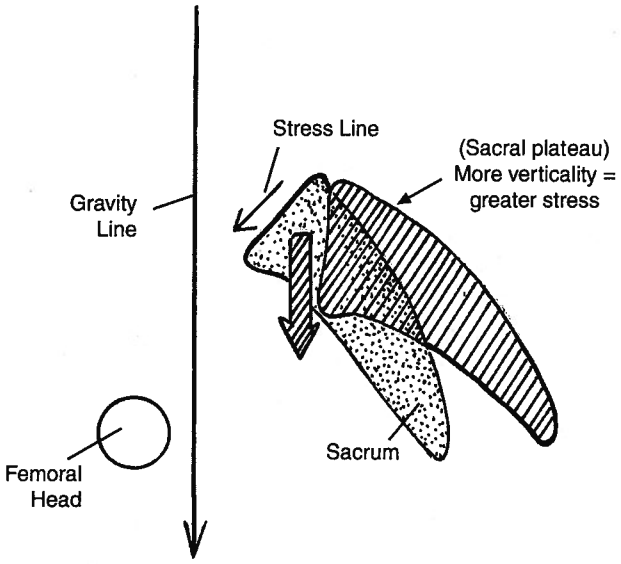

Figure 24–7 This drawing illustrates the shear force at the lumbosacral junction. The more vertical the sacral slope is, the more shear force is present.

♦ Pain Generators

Pain is present for a variety of reasons in spondylolisthesis. It is often repeated in textbooks that patients with developmental spondylolisthesis do not have pain. We think they must have enough pain for someone to obtain an x-ray. Children do not know how to interpret pain. Most never have a toothache or earache. The slowly progressive spondylolisthesis may be painful sometimes but then may abate for a while.

Probably the earliest pain symptom may be from the stress fractures that occur microscopically. Fractures hurt, and some surgeons even suggest local anesthetic infiltration for diagnostic and therapeutic reasons. These fractures heal and refracture so the pain may come and go. For the time the patient is seen in the office, the pain may be gone. Stress fractures may account for the elongation of the pars. These also are intermittingly painful. Sometimes the pars may have an acute fracture superimposed on a chronic stress fracture, which will cause acute pain. The condition is similar to an acute slipped femoral epiphysis on a chronic slip.

Once the shear stress enters the disk bond, pain may again be intermittent as the disk stretches or the epiphyseal plate separates. Disk degeneration is painful, and the nerve root can become entrapped. If the posterior elements are intact, the cauda may become entrapped.

♦ Natural History

The natural history of the different forms of spondylolisthesis are similar, but there are enough dissimilarities to discuss them separately.

The acquired forms are very common and many are probably not recognized. Those that are recognized are generally treated nonoperatively. Children with the acquired form usually do well with nonoperative treatment and behavior modification.[48–53] This may be difficult to achieve in gymnasts or football players. The patient may well become symptomatic later in life as the disk fails and the slip increases and traps the nerve root. If that happens, it is probably best to reduce this slip, support the anterior column, and fuse the both sides of the spine with fixation.

The low-grade dysplastic variety mimics the acquired stress fracture spondylolisthesis and frequently is difficult to distinguish.[54–56] The treatment is generally nonoperative with behavior modification. It is important to recognize this variety if the surgeon attempts to simply try to get the pars to heal. The dysplasia and the pelvic attitude suggest that pars healing is extremely unlikely. As the disk degenerates, the slip may increase. Surgical treatment is the same as above: reduction, fixation, and fusion with anterior support.

Traumatic spondylolisthesis is rare, and usually there are multiple other injuries that take precedence. Many times it may be overlooked. If recognized within a few weeks, it can be reduced, fixed, supported, and fused. When we use the term *supported* we mean a structural graft or prosthesis in the disk space. This helps to restore normal disk height and proper lordotic relationship of the motion segment.

Iatrogenic or postsurgical spondylolisthesis is not an uncommon situation. Overaggressive laminectomy may result in a slip. Long fusions without regard for the contour of the spine can result in spondylolisthesis. These cases are difficult to manage because the starting point is unknown. The principles are the same. Restore patency of the spinal canal, restore alignment, provide support, and be sure the construct is stable.

Degenerative spondylolisthesis is usually seen at the L4-L5 area but also may be seen at the L5-S1 level. The disk is degenerated, and the facets joints are arthritic and loose. Frequently, the loose joints are apparent on MRI or CT scan. There may be an isthmic defect but usually it is not seen. Many patients have this condition. Pain is usually present and becomes severe when the stenosis is severe or the nerve root is trapped. Generally, if surgical treatment is indicated, reduction, fixation, anterior support, and fusion is readily accomplished.

Pathologic spondylolisthesis is seen with a variety of metastatic and primary tumors. Once the diagnosis is made, it is important to image the entire spine for other pathologic conditions. Again, the principles of patency, alignment, stability, and support are vital.

High-grade dysplastic spondylolisthesis is the crucial diagnosis. These patients present as children, and it is necessary to make the appropriate x-rays, CT scan, and MRI to fully evaluate this patient. These patients may not be complaining of pain, but careful observation will show the high pelvic incidence and the increased lumbar lordosis.[57–61] If these findings are seen with dysplasia of the bony hook, watch out for progression.[62–69] If surgical intervention is needed, be sure to restore the anatomy as carefully as possible or progression will continue.

♦ Nonoperative Treatment and Indications for Surgical Treatment

Observation is the *sine qua non* for this condition as progression can be silent.

It is difficult to obtain consistent image studies, but it is worth trying. All the patients want to know is if the condition is getting worse. It can be difficult to judge if the studies are not consistent.

Nonoperative treatment may mean some type of brace.[70–74] There are reports of pars fractures healing in a brace, but it is rare in our experience. Bracing is a good place to start with patients with an acquired spondylolysis and hot bone scan. Behavior modification is equally as important as bracing. If repeated stress from gymnastics is the cause of the lysis, it would seem prudent once the pars is healed not to return to gymnastics.

Operative treatment is indicated when progression is imminent or present or when nonoperative treatment is no longer satisfactory.

The goals of operative treatment are normal canal patency, proper alignment, stable spine, and structural anterior support.

♦ Surgical Treatment

Pars Repair

Pars repair may be indicated in rare situations. A patient with an acquired lysis without slip and a good disk is the ideal candidate. It is essential to fix the pars securely and use bone graft from the transverse process across the pars to the spinous process bilaterally. Postoperative lordotic bracing is important.[75–79]

Fusion in Situ

Fusion in situ has many proponents and can be useful in stable situations (**Fig. 24–8**). It should not be used in unstable situations or in high-grade slips.[59,66,67]

Dowel Graft

The dowel technique where a fibula or prosthesis is inserted through the sacrum into L5 either anteriorly or posteriorly is probably not as physiologic a procedure as vertebrectomy of L5 and reducing L4 to the sacrum. Resection and reduction is a more sound biomechanical result than the dowel graft, which is usually horizontal and subjected to the shear forces.[80]

Console Fusion Technique

This technique is useful in high-grade slips after reduction to increase the plateau of the sacrum (**Fig. 24–9**). The sacrum is rounded in high-grade slips, and after reduction and removal of the dome, the anterior part of the sacrum can be made larger by this technique. It is similar to a shelf procedure for hip dislocation.[81]

Reduction and Fusion Anterior and Posterior

Acquired forms of spondylolisthesis slip transversely and have fairly normal sacrum and L5. It is relatively easy to reduce these and support the spine anteriorly (**Fig. 24–10**). This is accomplished using pedicle screws of the surgeon's choice.[82–85]

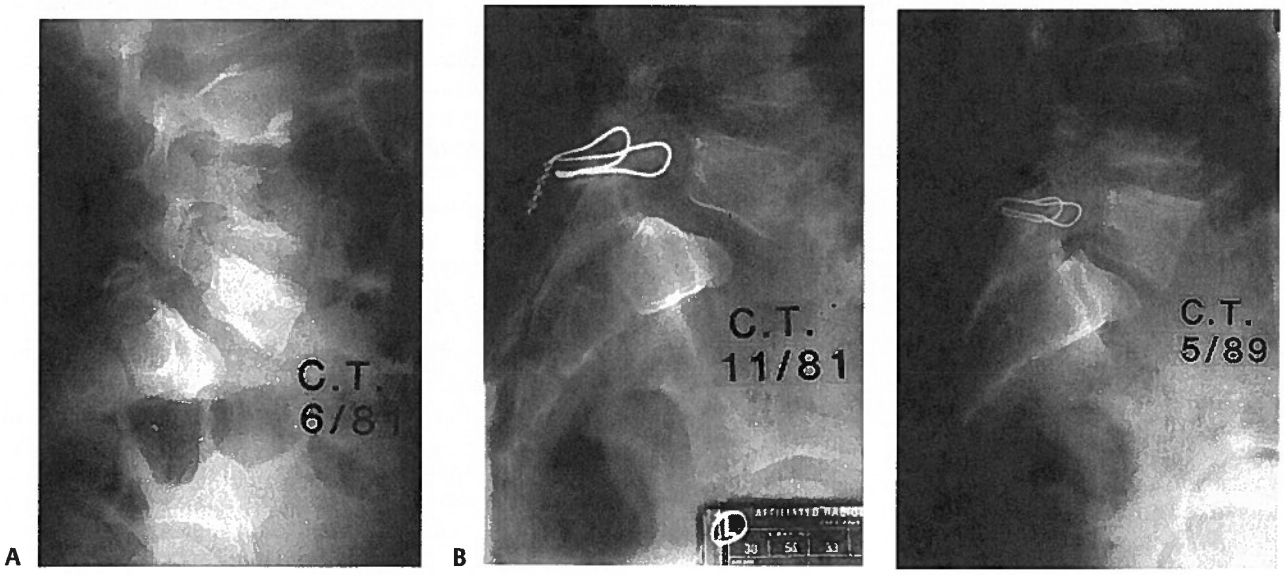

Figure 24–8 These x-ray images are of an 11-year-old boy with a 1-year history of intermittent pain and spondylolysis who now has a spondylolisthesis. **(A)** The patient has a marked lordosis, and the diagnosis is acquired spondylolisthesis. **(B)** Surgery was fixation and grafting of the pars and posterior-lateral fusion. **(C)** This x-ray image was taken 7 years later and illustrates the effect of the strong posterior tether on the appearance of the lumbosacral junction. This early stabilization has restored the spine to a more normal equilibrium.

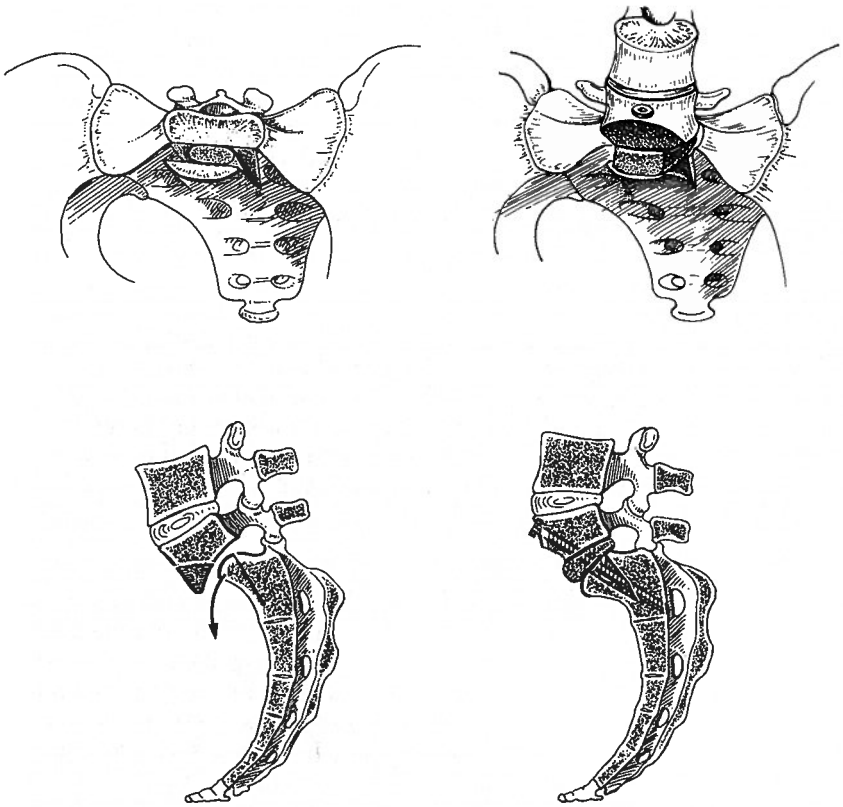

Figure 24–9 These drawings illustrate the technique of console fusion where the sacral plateau is enlarged to help support the spine.

It is important to do the procedure this way because the surgeon can restore patency, correct the alignment, stabilize the spine, and support the anterior column. The disk is usually degenerated, and L5 needs to be brought back into the correct anatomic position. All pathology is addressed and corrected and all the goals of surgery are met.

Reduction and Fusion Anterior and Posterior and Shortening the Spine

This procedure is indicated in severe developmental slips grades 3 to 4. The usual patient is young and has a large lordosis and pelvic incidence.[86–89]

The procedure begins with Gill laminectomy and location of the L5 roots. The L5 pedicles and their particular anatomy are noted. The L5-S1 disk space is visualized, and partial removal of the disk is performed. Sacral bicortical screws are inserted. Offset hooks are inserted under the L1 lamina with care to preserve the capsules of the facet joints. Distraction from S1 to L1 then brings L5 into better view. Also, the L5-S1 disk space is more visible and can be removed. The dome of the sacrum and the inferior body of L5 can also be removed. This aids in reduction and prevents too much stretch on the L5 roots. Spondylolisthesis reduction screws are inserted into the L5 pedicles. By translation, L5 is brought back into proper alignment. Sometimes L4 reduction screws are needed to better reduce the spine. Many times, some type of structural graft can be inserted from the same approach. On occasion, anterior placement of the structural grafts may be preferred if the sacrum is small and rounded (**Fig. 24–11**). The surgeon can increase the plateau by the console method. After reduction, the patient will continue to have a large lordosis because of the large pelvic incidence seen in this population of spondylolisthesis.

Reduction by Vertebrectomy

This procedure, vertebrectomy and reduction of the spine, has specific conditions that must be observed before consideration of surgery.[90,91] The L5 body must be below the sacrum. We prefer to see the L4-L5 disk at the same level as the L5-S1 disk. The removal of L5 can be accomplished from the anterior approach and the dysplastic posterior elements from the posterior approach. L4 and the spine can then be reduced onto the sacrum-pelvis. Sometimes a structural graft is needed in the L4-S1 disk space. This results in a more superior biomechanical construct than an in situ fusion or partial reduction and fusion. We have on occasion not been able to reduce the spine and have gone to plan B where we do the L5 vertebrectomy and reduction.

A

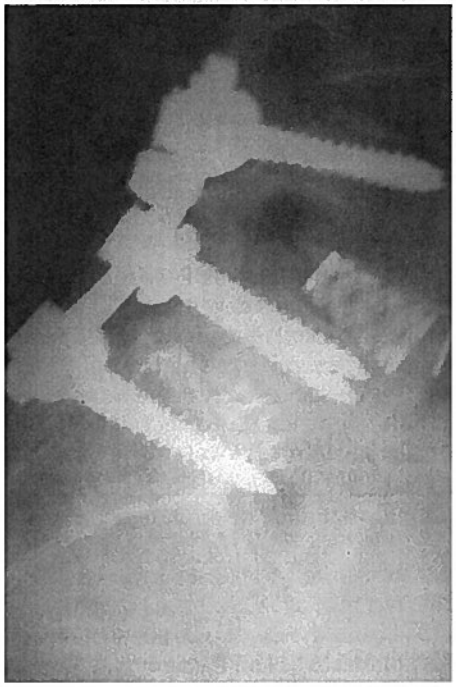

B

Figure 24–10 These two x-ray images illustrate an acquired spondylolisthesis in a 45-year-old surgical nurse. **(A)** The slip is translational and the disk space is very narrow. As the slip increased, the roots become trapped. **(B)** Reduction, decompression, stability, and support have been achieved.

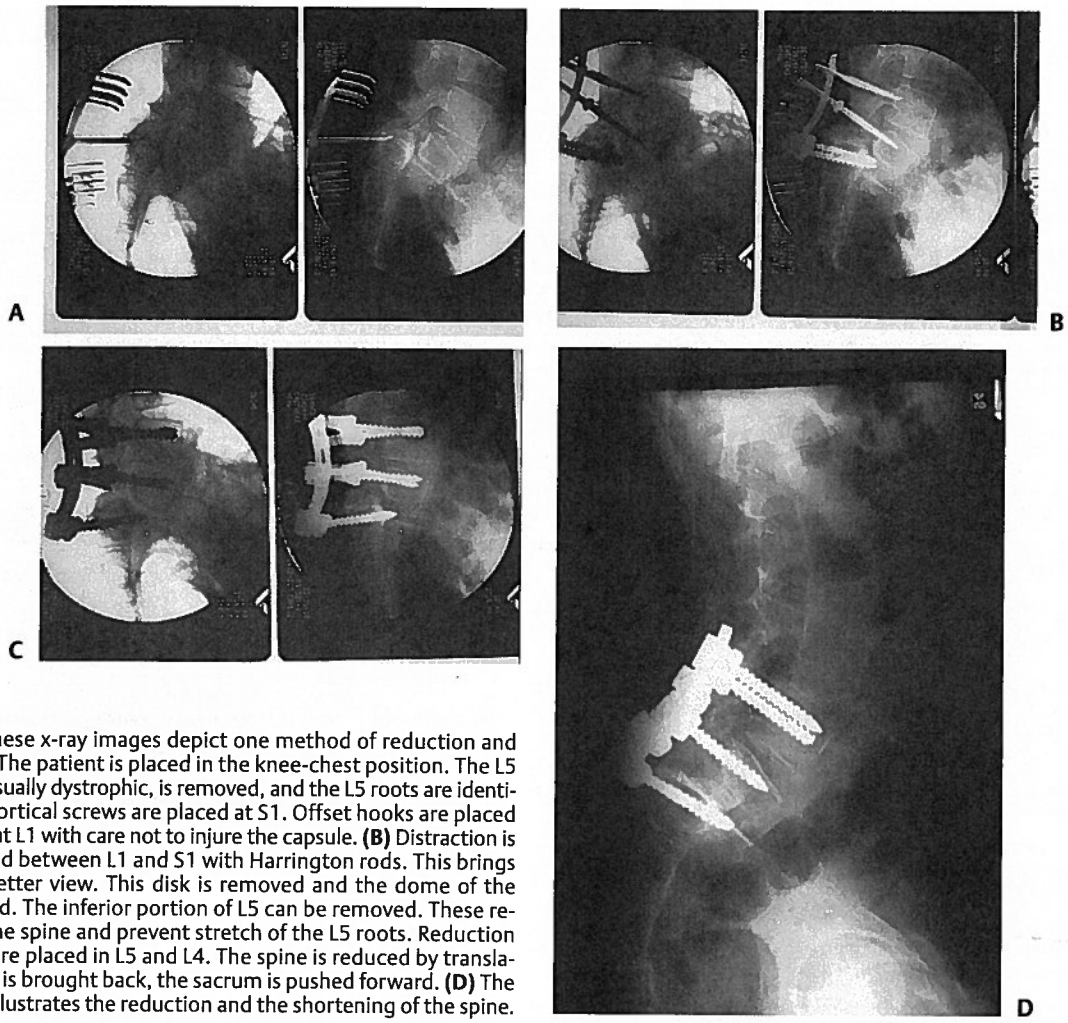

Figure 24–11 These x-ray images depict one method of reduction and stabilization. **(A)** The patient is placed in the knee-chest position. The L5 lamina, which is usually dystrophic, is removed, and the L5 roots are identified. Polyaxial bicortical screws are placed at S1. Offset hooks are placed under the lamina at L1 with care not to injure the capsule. **(B)** Distraction is then accomplished between L1 and S1 with Harrington rods. This brings L5-S1 disk into better view. This disk is removed and the dome of the sacrum is removed. The inferior portion of L5 can be removed. These removals shorten the spine and prevent stretch of the L5 roots. Reduction polyaxial screws are placed in L5 and L4. The spine is reduced by translation. **(C)** As the L5 is brought back, the sacrum is pushed forward. **(D)** The final x-ray image illustrates the reduction and the shortening of the spine.

♦ Conclusion

It is clear that most spondylolisthesis patients with either acquired or low-grade dysplastic types will be managed very well. If they persist with symptoms, they can be easily stabilized with an in situ posterior-lateral fusion. For those patients with acquired or low dysplastic spondylolisthesis with nerve root compression and a degenerated disk, we prefer reduction decompression, fixation, fusion, and support.

It is most important to recognize the high dysplastic variety with a large pelvic incidence and treat them early and restore stability. Stability depends on correct biomechanical anatomy to counter the shear forces involved.

References

1. Taillard W. Les spondylisthesis chez l'enfant et l'adolescent. Acta Orthop Scand 1955;24:115–144
2. Taillard WF. Etiology of spondylolisthesis. Clin Orthop Relat Res 1976;117:30–39
3. Herbiniaux G. Traite sure divers accouchemens labprieux. Et sur polyps de la matrice. Brussels: JL DeBoubers; 1782
4. Newman PH, Stone KH. The etiology of spondylolisthesis. J Bone Joint Surg Br 1963;45:39–59
5. Wiltse LL, Widell EH Jr, Jackson DW. Fatigue fracture: the basic lesion in isthmic spondylolisthesis. J Bone Joint Surg Am 1975;57:17–22
6. Wiltse LL, Newman PH, McNab I. Classification of spondylolysis and spondylolisthesis. Clin Organi Med 1994;79:85–91
7. Marchetti PG, Bartolozzi P. Classification of spondylolisthesis as a guideline for treatment. In: Bridwell KH, DeWald RL, eds. Textbook of Spinal Surgery, 2nd Ed. Philadelphia: Lipincott-Raven; 1997:1211–1254
8. Antoniades SB, Hammerberg KW, DeWald RL. Sagittal plane configuration of the sacrum in spondylolisthesis. Spine 2000;25(9):1085–1091
9. Sairyo K, Goel VK, Grobler LJ, et al. The pathomechanism of isthmic lumbar spondylolisthesis. A biomechanical study in immature calf spines. Spine 1998;23:1442–1446

10. Sakamaki T, Sairyo K, Katoh S, et al. The pathogenesis of slippage and deformity in the pediatric lumbar spine: a radiographic and histologic study using a new rat in vivo model. Spine 2003;28(7):645–650

11. Willis T. The separate neural arch. J Bone Joint Surg Am 1931;13:709–711

12. Wiltse LL, Widell E Jr., Jackson DW. Fatigue fracture: the basic lesion in isthmic spondylolisthesis. J Bone Joint Surg Am 1975;57:17–22

13. Albanese M, Pizzutillo PD. Family study of spondylolysis and spondylolisthesis. J Pediatr Orthop 1982;2:496–499

14. Teitz CC. Sports medicine concern in dance and gymnastics. Pediatr Clin North Am 1982;29:1399–1421

15. Ferguson RJ, McMaster JH, Stanitski CL. Low back pain in college football lineman. J Sports Med 1974;2:63–69

16. Jackson DW, Wiltse LL, Cirincoine RJ. Spondylolysis in the female gymnast. Clin Orthop Relat Res 1976;117:68–73

17. Rosenberg NJ, Bargar WL, Friedman B. The incidence of spondylolysis and spondylolisthesis in nonambulatory patients. Spine 1981; 6:35–37

18. Turner RH, Bianco A Jr. Spondylolysis and spondylolisthesis in children and teen-agers. J Bone Joint Surg Am 1971;53:1298–1306

19. Wynne-Davies R, Scott JH. Inheritance and spondylolisthesis: a radiographic family survey. J Bone Joint Surg Br 1979;61:B301–305

20. Stewart T. The age incidence of neural arch defects in Alaskan natives, considered from the standpoint of etiology. J Bone Joint Surg Am 1953;35:937–959

21. Bernhardt M, Bridwell KW. Segmental analysis of the sagittal plane alignment of the normal thoracic lumbar spines and thoracolumbar junction. Spine 1989;14:717–721

22. Stagnara P, DeMauroy JC, Dran G, et al. Reciprocal angulation of vertebral bodies in the sagittal plane. Approach to references for the evaluation of kyphosis and lordosis. Spine 1982;7:335–342

23. Duval-Beaupere G. Visualization on full spine radiographs of the anatomical connections of the centers of the segment body mass supported by each vertebra and measured in vivo. Int Orthop 1987;11:261–269

24. Duval-Beaupere G, Schmidt C, Cosson P. A barycentremetric study of the sagittal shape of spine and pelvis: the condition required for an economic standing position. Ann Biomed Eng 1992;20:451–462

25. Gelb DE, Lenke LG, Bridwell KH, Blanke K, McEnery KW. An analysis of sagittal spinal alignment in 100 asymptomatic middle and older aged volunteers. Spine 1995;20:1351–1358

26. Gracovetsky S, Farfan H. The optimum spine. Spine 1986;11:543–573

27. Jackson RP, Peterson MD, McManus AC, Hales C. Compensatory spinopelvic balance over the hip axis and better reliability in measuring lordosis to the pelvic radius on standing lateral radiographs of adult volunteers and patients. Spine 1998;23:1750–1767

28. Korovessis PG, Stamatakis MV, Baikousis AG. Reciprocal angulation of vertebral bodies in the sagittal plane in an asymptomatic Greek population. Spine 1998;23:700–705

29. Korovessis P, Stamatakis M, Baikousis A. Segmental roentgenographic analysis of vertebral inclination on sagittal plane in asymptomatic versus chronic low back pain patients. J Spinal Disord 1999;12:131–137

30. Legaye J, Duval-Beaupere G, Hecquet J, Marty C. Pelvic incidence: a fundamental pelvic parameter for three-dimensional regulation of spinal sagittal curves. Eur Spine J 1998;7:99–103

31. Duval-Beaupere G, Hecquet J, Dubousset J, Graf H, Tabuteau P, Roche P. Centre of mass supported by each vertebra on a 3D-image of the spine. In: Ninth Annual Conference of the Engineering in Medicine and Biology Society. Boston; 1987:844–845

32. Duval-Beaupere G, Robain G. Les rapports anatomiques du point d'application de la masse du segment corporel supporte par chaque etage vertebral. Ann Kinesither 1989;16:1–7

33. Duval-Beaupere G, Robain G. Visualization on full spine radiographs of the anatomical connections of the centers of the segmental body mass supported by each vertebra and measured in vivo. Int Orthop 1987;11: 261–269

34. Duval-Beaupere G, Schmidt C, Cosson P. Sagittal shape of the spine and pelvis. The conditions for an economic standing position. Barycentremetric study. Proceedings of the Scoliosis Research Society (24th Annual Meeting) combined with the European Spinal Deformity Society; September 1989; Amsterdam

35. Vaz G, Roussouly P, Berthonnaud E, Dimnet J. Sagittal morphology and equilibrium of pelvis and spine. Eur Spine J 2002;11:80–87

36. Rajnics P, Templier A, Skalli W, et al. The association of sagittal spinal and pelvic parameters in asymptomatic persons and patients with isthmic spondylolisthesis. J Spinal Disord Tech 2002;15:24–30

37. Ogden JA, Ganey TM. Development and maturation of the spine and spinal cord. In: Bridwell KH, DeWald RL, eds. The Textbook of Spinal Surgery, 2nd Ed. Philadelphia: Lippincott-Raven; 1997:54–71

38. Curylo LJ, Edwards C, DeWald RL. Radiographic markers in spondyloptosis: implications for spondylolisthesis progression. Spine 2002; 27(18):2021–2025

39. Farfan HF, Osteria V, Lamy C. The mechanical etiology of spondylolisthesis. Clin Orthop Relat Res 1976;117:40–55

40. Troup JD. Mechanical factors in spondylolisthesis and spondylolysis. Clin Orthop Relat Res 1976;117:59–67

41. McCarroll JR, Miller JM, Ritter MA. Lumbar spondylosis and spondylolisthesis in college football players. Am J Sports Med 1986;14:404–406

42. Semon RL, Spengler D. Significance of lumbar spondylolysis in college football players. Spine 1981;6:172–174

43. Loder RT. Profiles of the cervical, thoracic and lumbosacral spine in children and adolescents with lumbosacral spondylolisthesis. J Spinal Disord 2001;14:465–471

44. Cyron BM, Hutton WC. Variations in amount and distribution of cortical bone across the pars interarticularis of L5. A predisposing factor in spondylolysis? Spine 1979;4:163–167

45. Pfeil E. Experimentelle untersuchungen zur frage der entstehung der spondylolyse. Z Orthop 1971;109–231

46. Lamy C, Bazergui A, Kraus H, et al. The strength of the neural arch and the etiology of spondylolysis. Orthop Clin North Am 1975;6: 215–231

47. Grobler LJ, Novotny JE, Wilder DG, et al. L4–5 isthmic spondylolisthesis. A biomechanical analysis comparing stability in L4–5 and L5–S1 isthmic spondylolisthesis. Spine 1994;19:222–227

48. Osterman K, Schlenzka D, Poussa M, et al. Isthmic spondylolisthesis in symptomatic and asymptomatic subjects epidemiology, and natural history with special reference to disk abnormality and mode of treatment. Clin Orthop Relat Res 1993;297:65–70

49. Friberg O. Instability in spondylolisthesis. Orthopedics 1991;14: 463–466

50. Harrington PR, Tullos HS. Spondylolisthesis in children: observations and surgical treatment. Clin Orthop Relat Res 1971;79:75–84

51. Hensinger R, Lang J, MacEwen G. Surgical management of the spondylolisthesis in children and adolescents. Spine 1976;1:207–216

52. Jackson DW. Low back pain in young athletes: evaluation of stress reaction and discogenic problems. Am J Sports Med 1979;7:364–366

53. Marchetti PG, Bartolozzi P. Classification of spondylolisthesis as a guideline for treatment. In: Bridwell KH, DeWald RL, eds. The Textbook of Spinal Surgery, 2nd Ed. Philadelphia: Lippincott-Raven; 1997: 1211–1254

54. Bellah RD, Summerville DA, Treves ST, et al. Low back pain in adolescent athletes: detection of stress injury to the pars interarticularis with SPECT. Radiology 1991;180:509–512

55. Seitsalo S, Osterman K, Hyvarinen H, et al. Progression of spondylolisthesis in children and adolescents. A long-term follow-up of 272 patients. Spine 1991;16:417–421

56. Bell DF, Ehrlich MG, Zaleske DJ. Brace treatment for symptomatic spondylolisthesis. Clin Orthop Relat Res 1988;236:192–198

57. Harris IE, Weinstein SL. Long term follow up of patients with grade III and IV spondylolisthesis: treatment with and without posterior fusion. J Bone Joint Surg Am 1987;69:960–969

58. Johnson JR, Kirwan EO. The long term results of fusion in situ for severe spondylolisthesis. J Bone Joint Surg Br 1990;72:43–46

59. Seitsalo S, Osterman K, Hyvarinon H, Schlenzka D, Poussa M. Severe spondylolisthesis in children and adolescents. A long term review of fusion in situ. J Bone Joint Surg Br 1990;72:259–265

60. Maurice HD, Morley TR. Cauda equina syndrome lesions following fusion in situ and decompressive laminectomy for severe spondylolisthesis. Four case reports. Spine 1989;14:214–216

61. Schoenecker PL, Cole HO, Herring JA, Capelli AM, Bradford DS. Cauda equina syndrome after in situ arthrodesis for severe spondylolisthesis at the lumbosacral junction. J Bone Joint Surg Am 1990;72:369–377

62. Bradford DS. Closed reduction of spondylolisthesis: an experience of 22 patients. Spine 1988;13:580–587

63. Bradford DS, Boachie-Adjei O. Treatment of severe spondylolisthesis by anterior and posterior reduction and stabilization. J Bone Joint Surg Am 1990;72:1060–1066

64. Burkus K, Lonstein JE, Winter RB, Denis F. Long-term evaluation of patients treated operatively for spondylolisthesis. J Bone Joint Surg Am 1991;74:693–704

65. O'Brien JP, Mehdian H, Jaffray D. Reduction of severe lumbosacral spondylolisthesis. Clin Orthop Relat Res 1994;300:64–69

66. Ishikawa S, Kumar SJ. Surgical treatment of dysplastic spondylolisthesis. Results after in situ fusion. Spine 1994;19:1691–1696

67. Grzegorzewski A, Kumbar SJ. In situ posterolateral spine arthrodesis for grades III, IV, and V spondylolisthesis in children and adolescents. J Pediatr Orthop 2000;20:506–511

68. Poussa M, Schlenzka D, Seitsalo S, Ylinkoski M, Hurri H, Osteroman K. Surgical treatment of severe isthmic spondylolisthesis in adolescents. Reduction or fusion in situ? Spine 1993;18:894–901

69. Schwend RM, Waters PM, Hay LA, Hall JE, Emans JB. Treatment of severe spondylolisthesis in children by reduction and L4–S4 posterior segmental hyperextension fixation. J Pediatr Orthop 1992;12:703–711

70. Bell DF, Erlich MG, Zaleske DM. Brace treatment for symptomatic spondylolisthesis. Clin Orthop Relat Res 1988;236:192–198

71. Blanda J, Bethem D, Moats W, Lew M. Defects of pars interarticularis in athletes: a protocol for nonoperative treatment. J Spinal Disord 1993;6:406–411

72. Pizzutillo PD, Hummer CD 3rd. Nonoperative treatment for painful adolescent spondylolysis or spondylolisthesis. J Pediatr Orthop 1989;9:538–540

73. Halvorsen TM, Nilsson S, Nakstad PH. Stress fractures. Spondylolysis and spondylolisthesis of the lumbar vertebrae among young athletes with back pain. (Abs). Tidsskr Nor Laegeforen 1996;116:1999–2001

74. Micheli LJ. Back injuries in gymnasts. Clin Sports Med 1985;4:85–93

75. Buck JE. Further thoughts on direct repair of the defect in spondylolysis. J Bone Joint Surg Br 1979;61:123–125

76. Kakiuchi M. Repair of the defect in spondylolysis. Durable fixation with pedicle screws and laminar hooks. J Bone Joint Surg Am 1997;79: 818–825

77. Pellise F, Toribio J, Rivas A, et al. Clinical and CT scan evaluation after direct defect repair in spondylolysis using segmental pedicular screw hook fixation. J Spinal Disord 1999;12:363–367

78. Wu SS, Lee CH L, Chen PQ. Operative repair of symptomatic spondylolysis following a positive response to diagnostic pars injection. J Spinal Disord 1997;12:10–16

79. Kip PC, Esses SI, Doherty BI, Alexander JW, Crawford MJ. Biomechanical testing of pars defect repair. Spine 1994;19:2692–2697

80. Bohlman HH, Cook SS. One-stage decompression and posterolateral and interbody fusion for lumbosacral spondyloptosis through a posterior approach. J Bone Joint Surg Am 1982;64:415–418

81. Marchetti PG, Bartolozzi P. Classification of spondylolisthesis and spondylolisthesis as a guideline for treatment. In: Bridwell KH, DeWald RL, eds. The Textbook of Spinal Surgery, 2nd Ed. Philadelphia: Lippincott-Raven; 1994;1236

82. Harms J, Jeszenszky D, Stoltze D, Bohm H. True spondylolisthesis reduction and monosegmental fusion in spondylolisthesis. In: Bridwell KH, DeWald RL, eds. The Textbook of Spinal Surgery, 2nd Ed. Philadelphia: Lippincott-Raven; 1997:1337–1347

83. Lenke LG, Bridwell KH. Adult spondylolisthesis with lysis. In: Bridwell KH, DeWald RL, eds. The Textbook of Spinal Surgery, 2nd Ed. Philadelphia: Lippincott-Raven; 1997:1269–1298

84. Nooraie H, Ensafdaran A, Arasteh MM. Surgical management of low-grade lytic spondylolisthesis with C-D instrumentation in adult patients. Arch Orthop Trauma Surg 1999;119:337–339

85. Carragee EJ. Single-level posterolateral fusion, with or without posterior decompression, for the treatment of isthmic spondylolisthesis in adults. A prospective randomized study. J Bone Joint Surg Am 1997;79:1175–1180

86. Hu SS, Bradford DS, Transfeldt EE, Cohen M. Reduction of high grade spondylolisthesis using Edwards instrumentation. Spine 1996;21:367–371

87. DeWald RL, Faut MM, Taddonio RF, Neuwirth MG. Severe lumbosacral spondylolisthesis in adolescents and children. J Bone Joint Surg Am 1981;63:619–626

88. Fabris DA, Costantini S, Nea U. Surgical treatment of severe L5–S1 spondylolisthesis in children and adolescents. Results of intraoperative reduction, posterior interbody fusion and segmental pedicle fixation. Spine 1996;21:728–733

89. Molinari RW, Bridwell KH, Lenke LG, Ungaeta FF, Riew KD. Complications in the surgical treatment of pediatric high-grade dysplastic spondylolisthesis. Spine 1999;24:1701–1711

90. Gaines RW, Nichols WK. Treatment of spondyloptosis in two stage L5 vertebrectomy and reduction of L4 onto S1. Spine 1985;10:680–686

91. Lehmer SM, Steffee AD, Gaines RW. Treatment of L5–S1 spondyloptosis by staged L5 resection with reduction and fusion of L4 onto S1 (Gaines procedure). Spine 1994;19:1916–1925

Chapter 25

Prevention and Treatment of Post-traumatic Deformity of the Thoracolumbar Spine

Ahmad N. Nassr, Kern Singh, David W. Wimberley, and Alexander R. Vaccaro

Post-traumatic thoracolumbar spinal deformity presents a difficult challenge for the spine surgeon. These deformities can be difficult to manage nonoperatively or surgically and oftentimes require extensive surgical correction with a high incidence of complications. The incidence of post-traumatic deformity in the setting of thoracolumbar spine injury is not specifically known. However, the recognition of at-risk acute-injury patterns and the timely initiation of appropriate management strategies may significantly decrease the incidence and severity of this spinal disorder. Early and aggressive treatment of these injuries can result in improved functional outcomes with a decrease in the incidence of treatment-related complications. The primary goal of treatment is to restore the spine to a state of permanent stability in anatomic alignment, both coronally and sagittally, while preserving neurologic function, minimizing discomfort, and avoiding complications.

♦ Epidemiology

The incidence of post-traumatic deformities in patients having undergone treatment for thoracolumbar injuries is not known but is assumed to be relatively uncommon. There are ~150,000 spine fractures in North America annually with most being minor and requiring little to no treatment.[1] In the young, thoracolumbar fractures are generally the result of high-energy injuries such as motor vehicle accidents, falls from heights, and penetrating trauma. In both the elderly and those with metabolic bone disease, however, low-energy mechanisms of injury are significantly more common. Thoracolumbar spine injuries occur in a bimodal distribution with the first peak in the second and third decades of life and the second peak occurring in people in their sixth decade of life. In a review of more than 1000 patients by the Scoliosis Research Society, 16% of injuries occurred between T1 and T10, 52% between T11 and L1, and 32% between L1 and L5.[2] The overall incidence of associated neural injury has decreased nationally as a result of the improvement in emergency medical services, on-scene immobilization and rapid transport to specialized trauma centers, as well as safer automobiles and workplace environments.[3] Treatment of these injuries has been associated with complications including neurologic deterioration (1%), spinal instrument failure (2 to 8%), vascular injury, retrograde ejaculation (4% with anterior approach), deformity, chronic pain, and infection (3 to 10%).[4,5] The improvements in the acute management of polytrauma patients who have thoracolumbar spine injuries has ironically resulted in an increased incidence of post-traumatic deformity. This is due to both an increased survival rate in the setting of other associated significant injuries in addition to the presence of a complete or incomplete neurologic injury resulting in unbalanced forces on the spinal axis.[6]

♦ Anatomy

The thoracolumbar spine has several unique characteristics that make it susceptible to injury. The normal thoracic spine is surrounded posteriorly by the paraspinal musculature and laterally and anteriorly by the rib cage and sternum. As a result, the thoracic spine is significantly more resistant to both forward flexion and extension loads when compared with the lumbar spine. This relates to the coronal orientation of the thoracic facet joints that allow for lateral flexion and torsional motion while restricting forward flexion and extension.[7] Additionally, the thoracic spine is kyphotic due to the anterior wedging of the vertebral bodies. Some have suggested that this kyphosis may predispose the thoracic spine to flexion-compression injuries, which may be further aggravated after a

surgical laminectomy or traumatic posterior element disruption.[8] Attainment of stability is paramount in the thoracolumbar region (T11 to L1) because of the large forces focused on this zone of transition from the stiff, kyphotic thoracic spine to the flexible, lordotic lumbar spine.[1]

An anatomic factor of significance in the thoracic spine is the relatively small spinal canal. The spinal canal from T2 to T10 has the smallest ratio of canal to cord diameter of the entire neuroaxis.[9,10] This may help explain the high ratio of complete to incomplete spinal cord injuries in this region. It also emphasizes the need for adequate stability to protect the delicate neuroanatomy of the region.

♦ Clinical Presentation

If initial evaluation fails to recognize and adequately treat "at-risk" injuries or if additional trauma to the injured spinal segment occurs, patients may over time develop a slowly progressive post-traumatic deformity associated with pain and the possibility of a new onset or worsening neurologic deficit. Gradually, a progressive deformity may become evident resulting from a combination of occult instability and normal or abnormal physiologic stresses over time.[11,12]

The most common presenting complaint of post-traumatic deformity is a dull, aching pain at the apex of the deformity.[13,14] Strenuous activity and prolonged sitting or standing generally aggravates the pain.[15] Altered stress patterns on the adjacent vertebral column and soft tissues, as well as early degenerative changes are theorized to contribute to pain in such patients.[16]

Bohlman et al. have shown significant pain relief in 41 of 45 patients after late anterior decompression for chronic pain or paralysis after thoracolumbar injuries at an average of 4.5 years follow-up.[17] Pain is rarely the sole criteria for surgical intervention as the majority of patients also have radiographic evidence of deformity progression, with or without a static or progressive neurologic deficit.

Malcolm and co-workers reported on 48 operatively treated patients with post-traumatic deformity of which 13 (27%) had progressive neurologic deterioration.[15] Other causes of neurologic deterioration included the development of a post-traumatic syrinx or progressive post-traumatic cystic myelopathy.[18,19] These patients must also be evaluated for tethering of the spinal cord, arachnoiditis, spinal cord compression, or microcystic cord degeneration. Treatment for cystic expansile lesions of the spinal cord has had limited success with cerebrospinal fluid shunting procedures resulting in a 50% rate of shunt revision.[20] Nonprogressive spinal kyphotic deformity without evidence of cystic lesions of the spinal cord is also a rare cause of neurologic deterioration. Abel et al. reported on a group of 68 patients without evidence of spinal cord cystic degeneration, but who presented with symptoms of progressive neurologic deterioration in the setting of a post-traumatic deformity.[4] They noted that the incidence of spinal cord cystic degeneration in patients with 15 degrees of kyphosis, or less than 25% spinal canal stenosis, was half that of patients with larger deformities. Neurologic deterioration was instead related to progressive deformity, stenosis, instability, arachnoiditis, and spinal cord tethering.

♦ Radiographic Evaluation

Plain radiographs, including long cassette 36-in standing anteroposterior and lateral radiographs, are essential in assessing the overall coronal and sagittal balance of the spine in the post-traumatic setting. Particular attention should be paid to the status of the posterior elements to evaluate for the presence of splaying of the spinous processes that is frequently associated with insufficiency of the posterior ligamentous complex. Flexion/extension and lateral bending radiographs are also useful in assessing the flexibility of the spinal deformity. Comparison of these films to the immediate postinjury and follow-up films will help clearly document changes in spinal alignment over time.[11]

Sagittal alignment can be evaluated with the use of a plumb line dropped from the external auditory meatus. This line should pass through the anterior portion of the S1 body.[18] Alternatively, this line can also be dropped from the middle of the C7 body and should fall close to the posterosuperior corner of the S1 body.[21] Areas of kyphosis, lordosis, and scoliosis are measured by use of the Cobb technique.[22] Focal kyphotic deformities are best measured using the vertebral body above and below the injury as direct measurement of the fractured vertebrae is subject to significant observer variation.[16,18]

Computed tomography (CT) is an excellent imaging modality to visualize specific bony anatomy, especially the posterior elements and the posterior wall of the vertebral body, which may be difficult to accurately evaluate on plain radiographs. Obtaining 1- to 3-mm axial cuts, along with sagittal and coronal reconstructions, allows for optimum evaluation of all bony landmarks. Computed tomography can also be combined with myelography to assess the status of the neural elements, especially in situations in which MRI cannot be used or is suboptimal, such as in the postsurgical setting or in the presence of internal fixation.

Magnetic resonance imaging (MRI) is most useful in evaluating the spinal cord and soft tissues surrounding the vertebral column. It is also an excellent way to quantify neural element compression, which is critical before undergoing a surgical correction that may cause further spinal cord impingement. Subtle changes within the parenchyma of the spinal cord that may be indicative of edema, fluid collections, or scarring may also be identified. Importantly, MRI allows evaluation of the posterior ligamentous tissues of the spine that may help predict patterns of spinal instability, which is critical in preoperative planning. MRI is also invaluable in diagnosing post-traumatic syringomyelia or progressive cystic myelopathy, which has been reported to have a prevalence between 3.2% and 40% in spinal cord injury patients.[23,24]

♦ Biomechanics

The majority of post-traumatic deformities of the thoracolumbar spine have misalignment of the spinal axis in more than one plane. A three-dimensional deformity involving the

sagittal and or coronal plane may also be associated with a translational and or rotatory deformity. The majority of these deformities, however, are often characterized by the dominant planar deformity. It is imperative, however, for the treating physician to fully appreciate the three-dimensional nature of all post-traumatic spinal deformities.

♦ Classification

Deformity in the Sagittal Plane

Kyphotic Deformity

A focal post-traumatic kyphotic deformity is generally caused by a flexion and compression type injury.[25–27] The deforming force causes a loss of anterior column height and a variable loss of middle column height with or without a distraction-type injury to the posterior column. There is often a compensatory hyperextension of the adjacent spinal motion segments to correct for the altered sagittal alignment. This may result in altered facet joint function, intervertebral shear, and contracture of the posterior spinal ligaments, possibly leading to early degeneration of the adjacent motion segments.[16,18] If the posterior bony-ligamentous column is disrupted at the apex of the kyphotic deformity, the deformity may worsen with time even if properly immobilized. Injuries such as an unstable burst fracture, flexion-compression injury, or flexion-distraction injury are especially prone to post-traumatic deformity. This is especially true at the thoracolumbar junction, even in the setting of appropriate spinal immobilization.[28–31]

Lordotic Deformity

A post-traumatic thoracolumbar sagittal plane lordotic deformity is relatively uncommon. Such a deformity may be seen after a primarily distraction-extension mechanism with disruption of the anterior longitudinal ligament, intervertebral disk complex, and compromise to the osseous posterior elements.

Deformity in the Coronal Plane

Scoliotic Deformity

Asymmetric lateral-flexion and compressive forces in the setting of a compromised spinal axis may lead to a post-traumatic coronal or scoliotic deformity. External compressive loads and asymmetric loss of vertebral height in the coronal plane at one or multiple adjacent levels may contribute to this deformity. Progression of post-traumatic coronal plane deformity is much more prevalent in the setting of a significant neurologic injury especially in younger age groups.[11,32,33]

Additionally, the most significant factor influencing the development of scoliosis in the setting of a spinal cord injury is the age of the patient when the injury occurs. The incidence of scoliosis has been previously reported to be 100% in children with spinal cord injury below the age of 10, 19% in children between 10 and 16, and 12% in patients older than 17.[32,33]

The injury pattern, the degree of skeletal maturity, and the associated neurologic deficits are not the sole causes of coronal plane deformity after a fracture of the thoracolumbar spine. Other reported etiologies include the effect of gravity, trunk muscle imbalance, osteoporosis or other metabolic bone diseases, loss of vertebral strength, hip contractures, and pelvic obliquity.[32,33]

Translational Deformity

Translational deformities are the consequence of a shear type or combined injury mechanism and frequently result in dramatic instability of the vertebral column. This is a result of injury to all three spinal columns.[8,34] Translational post-traumatic deformity of the thoracolumbar spine is rare but may be seen in the presence of shear disruption of the posterior elements (i.e., traumatic spondylolisthesis). These deformities may occur in either the coronal or sagittal planes and most frequently results from either an antero-posterior or laterally directed shear force. A rotatory component to the deformity may or may not be evident. These injuries may occur in isolation or as part of a combined kyphotic or lordotic deformity as the result of a flexion or extension injury, respectively. A translational injury may initially be subtle and easily missed only to present later with marked progression and worsening pain or neurologic compromise. It is important to note that spontaneous reduction of translational deformities may occur at any point after injury. As such, the static evaluation of the vertebral column depicted on initial plain radiographs may fail to demonstrate the full extent of the injury and instability that may actually be present. This is especially true with sagittal plane translational deformities that may spontaneously reduce with the patient in the supine position.

A typical sagittal plane deformity resulting frequently in a complete neurologic deficit is a fracture-dislocation injury.

Combined Deformity

A combined planar deformity is the norm after a thoracolumbar spinal injury. These deformities, especially if fixed, are the most challenging to treat. It is imperative that the treating surgeon has a clear and accurate understanding of the patient's spinal deformity in three dimensions prior to embarking upon any form of treatment, nonoperative or operative.

♦ Causes of Post-traumatic Deformity

Instability

Failure to appreciate potentially unstable injury patterns after trauma to the thoracolumbar spine may lead to inadequate immobilization of, or delay in the surgical stabilization of, an unstable spinal injury. This represents one of the more common reasons for progression of post-traumatic deformity. Keene et al.[12] reported several common reasons for progressive postoperative instability after treatment of thoracolumbar injuries. A common cause for post-traumatic deformity

often involves a laminectomy in injuries with anterior and middle column disruption causing further instability to the intact posterior spinal elements. This complication may be avoided by indirect decompression of the spinal canal, if indicated, through a posterior approach via ligamentotaxis in the acute setting, or a formal anterior decompression of the compressed neural elements, followed by fusion and instrumentation. Laminectomy, without an associated instrumented fusion, has little place in the treatment algorithm of neural compression after a traumatic spinal injury. Incorporation of at least five spinal levels into the fusion mass has been shown to increase stability and improve spinal alignment after a posterior decompression in the setting of a traumatic thoracolumbar spinal injury.[12] When placing segmental spinal instrumentation, preoperative planning should anticipate not ending the fusion at a junctional segment or at the apex of a spinal deformity.

Pseudarthrosis

A nonhealed fracture or fusion may result in progression of a spinal deformity. Failure of fusion with implant fatigue or dislodgment may result in a post-traumatic deformity and has been reported in ~16% of patients after posterior instrumentation.[35–37] Hardware failure is multifactorial and is related to bone density, excessive stress on the instrumentation, technical errors at the time of implantation, infection, nicotine exposure, and noncompliance with prescribed postoperative orthotic use. Surgical intervention is almost universally required in this setting and often involves a circumferential fusion with segmental instrumentation.

Hardware Failure

Implant failure or dislodgment is one of the most frequently reported postoperative complications after treatment for a post-traumatic deformity. This may result in recurrence of the post-traumatic deformity and worsening complaints of back pain and neurologic deficit.

Charcot Spine

Charcot spine is a relatively rare complication after a spinal injury in the setting of a neurologic deficit. This destructive lesion is identified most frequently in patients with paralysis after spinal cord injury. The pathogenesis of this deformity is likely due to the insensate nature of the spine below the level of the injury leading to abnormal movements and stresses on the spine. Progressive destruction of cartilage, subchondral bone damage, and overall degeneration of the spine may mimic infection and frequently leads to pseudarthrosis. Charcot spine has been reported to be a very late cause of progressive deformity and may present as late as 30 years after the original injury.[38,39] Charcot spine is associated with worsening axial or radicular pain, urologic dysfunction, dramatic and progressive deformity, and loss of sitting balance, which may culminate in skin breakdown and decubitus ulcers.[11,39] Radiographically, the early stages demonstrate hypertrophic bone formation around the vertebrae adjacent to and caudal to the level of the cord lesion.[39,40] The disk spaces and end plates may appear fragmented as well. These changes may progress to massive periosteal bone formation and a so-called ball-and-socket pseudarthrosis. Patients may report an audible crepitance or clunk with motion. Anterior fusion with partial resection of the Charcot joint followed by segmental instrumented posterior spinal fusion has resulted in satisfactory results with deformity correction.[39,40]

♦ Surgical Treatment

Kyphotic Deformity

Kyphosis is the most frequently encountered post-traumatic thoracolumbar deformity. This deformity is most often the result of a compression-flexion mechanism of injury. Such deformities are characteristically focal and may at times result in a clinically significant sagittal imbalance of the spine, especially if the deformity is progressive. This deformity, especially if progressive, can be significantly associated with axial and radicular pain in addition to a stable or progressive neurologic deficit. Indications for surgical correction of these deformities include neurologic deterioration, a static deformity greater than or equal to 30 degrees associated with severe pain unresponsive to conservative treatment, and deformity progression.[3] Patients with 30 degrees or greater of a static kyphotic deformity have been shown to have a statistically increased risk for chronic pain in the region of their deformity **(Figs. 25–1 to 25–3)**.[2,15,41]

Operative approaches used in the treatment of post-traumatic kyphosis include anterior, posterior, and combined procedures. One of the most frequent operative approaches used in the treatment of significant kyphotic deformities is an anterior decompression and release with or without deformity correction, followed by a posterior segmental stabilization procedure with or without further deformity correction. Posterior-only procedures are handicapped biomechanically as they are challenged by the requisite large cantilever stresses placed on the spinal instrumentation required for deformity correction. This may result in higher rates of acute or late hardware failure, dislodgment, and ultimate loss of surgical deformity correction. It is preferable to combine a posterior approach with an initial anterior bony and ligament release and reconstruction to achieve improved sagittal plane deformity correction and a more biomechanically sound and balanced spinal construct.

Although a posterolateral (extracavitary) approach may be used to gain access to both the anterior and posterior aspects of the spine simultaneously, several authors have reported significant difficulties and compromised access to the anterior column afforded by this approach.[35,41–43] Although a combined approach strategy requires two separate incisions and approaches, the anterior approach allows superior exposure of the anterior spinal column and affords a more efficient means of neural element decompression and the potential for enhanced neurologic recovery when compared with patients undergoing decompression via a posterolateral approach alone. Most surgeons believe that these outcomes are largely the result of improved spinal visualization with a direct anterior exposure.[43–45]

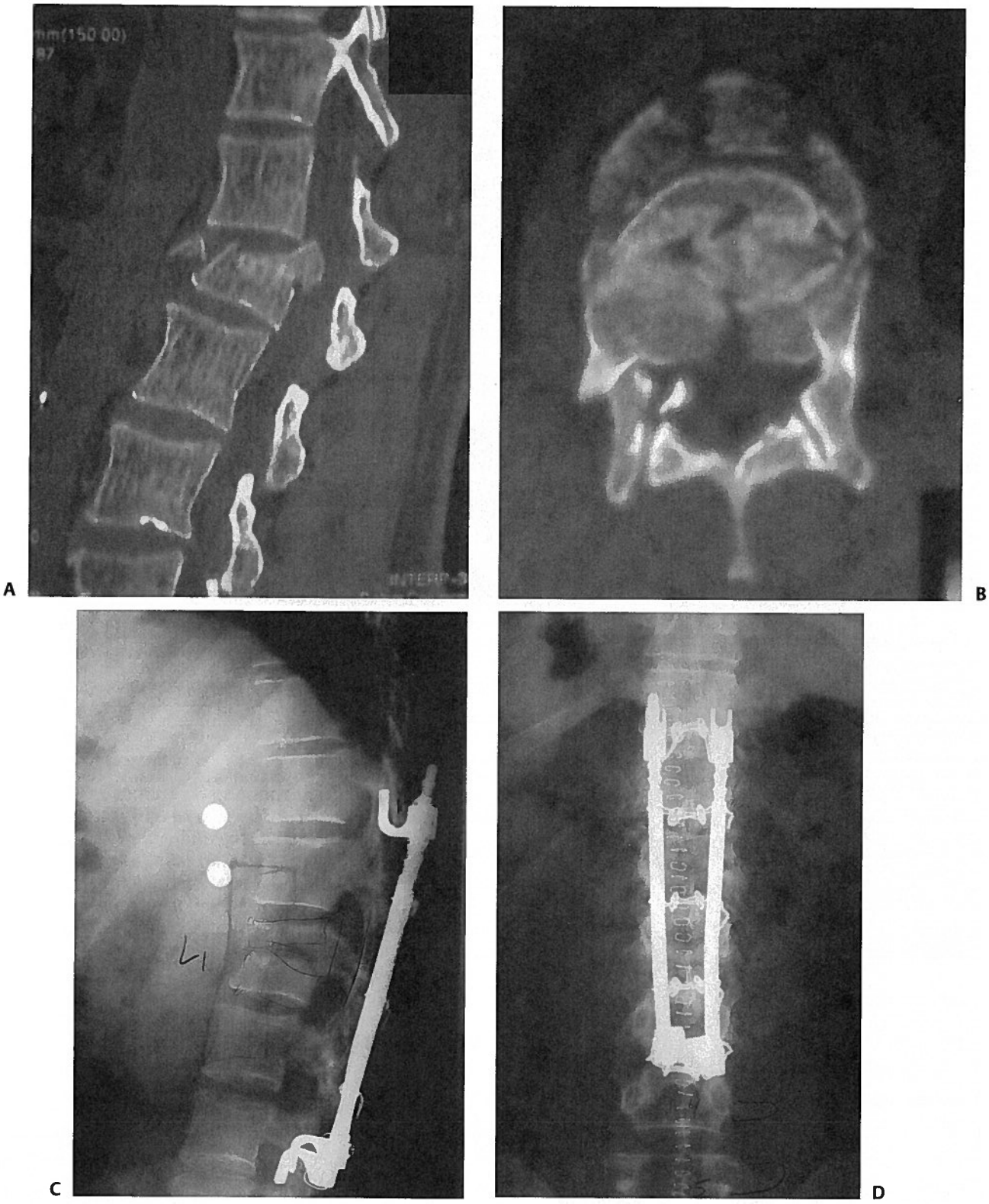

Figure 25–1 A sagittal and axial CT scan of the lumbar spine in a 43-year-old male who presented after a motor vehicle accident. The patient was neuro-intact upon presentation to an outside hospital. The images demonstrate an L1 burst fracture with ~30 degrees of kyphosis **(A)** and 50% canal compromise **(B)**. **(C, D)** The patient was treated with a posterior hook construct with segmental wire fixation from T11 to L3. Note that the rod hook-wire construct was placed in distraction across the zone of injury. (Images courtesy of Kim Hammerberg, M.D., Rush University Medical Center.)

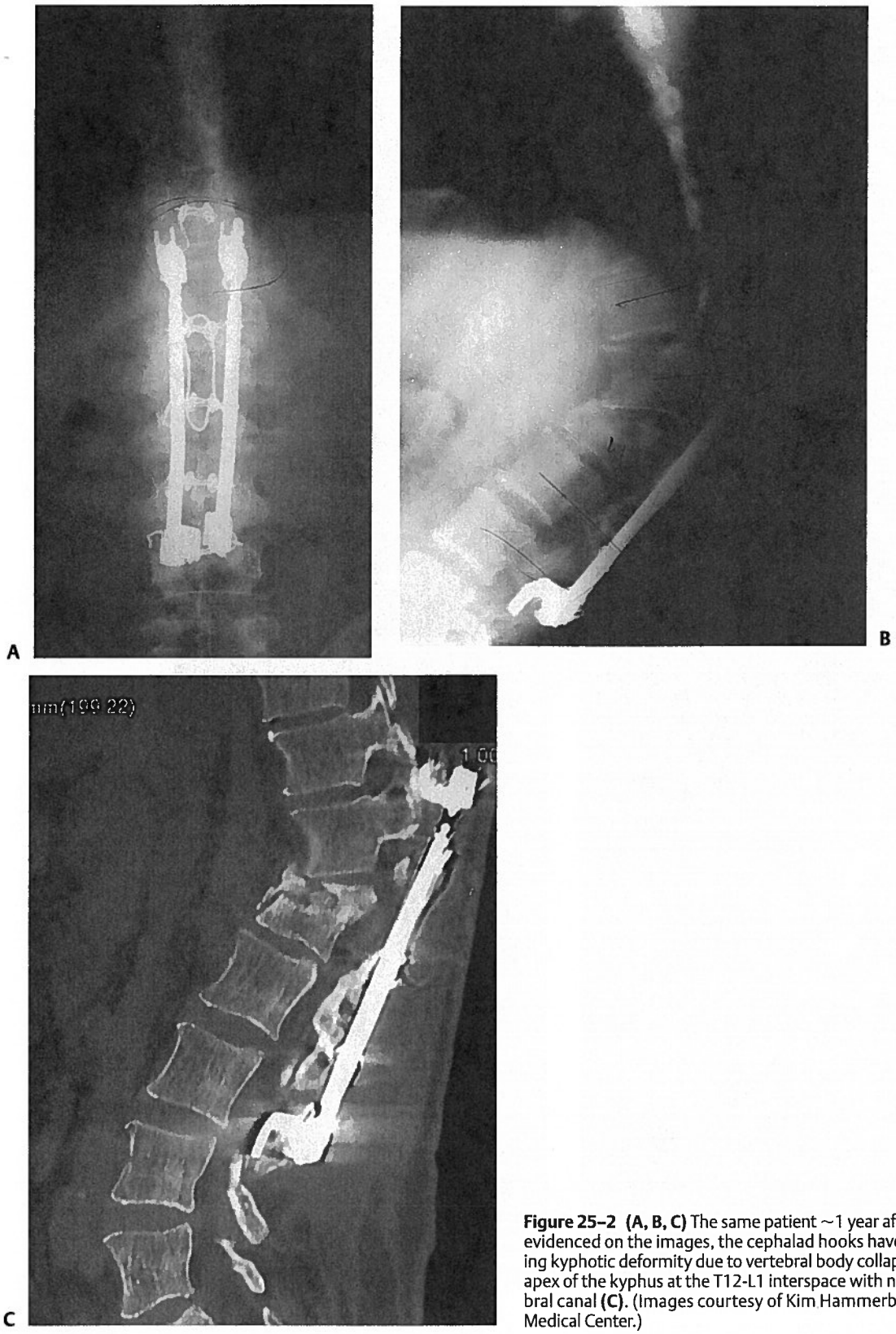

Figure 25–2 **(A, B, C)** The same patient ~1 year after the initial treatment. As evidenced on the images, the cephalad hooks have dislodged with a worsening kyphotic deformity due to vertebral body collapse at the L1 level. Note the apex of the kyphus at the T12-L1 interspace with narrowing of the intervertebral canal **(C)**. (Images courtesy of Kim Hammerberg, M.D., Rush University Medical Center.)

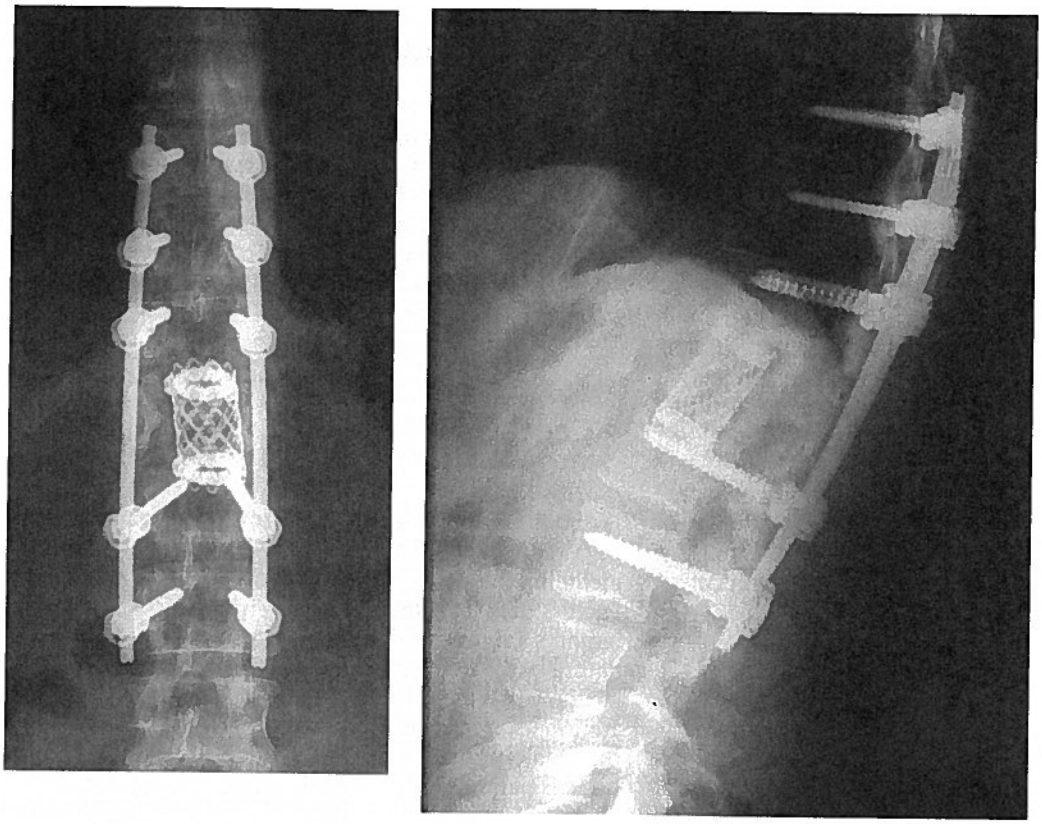

Figure 25–3 (A, B) The patient was taken back to the operating room for revision of his post-traumatic deformity with worsening neurologic injury. An L1 corpectomy was performed anteriorly with anterior soft tissue and bony releases and placement of a cylindrical titanium cage filled with local bone graft. A posterior segmental fusion using pedicular fixation was then perfomed from T10 to L3 with normal sagittal contour being restored. Images courtesy of Kim Hammerberg, M.D., Rush University Medical Center.

Scoliotic Deformity

A scoliotic deformity rarely occurs in the adult patient after thoracolumbar trauma unless associated with a lateral compression deformity of the involved vertebral body. Surgical indications are similar to those for kyphotic deformity and include neurologic deterioration, large fixed or progressive deformity, functional limitations attributable to the deformity, and significant truncal imbalance. Operative procedures are intended to improve spinal alignment and if necessary relieve neurologic compression. To prevent the development of a significant paralytic scoliosis in the immature spine and its undesirable consequences, it is imperative that children with paralysis undergo regular clinical and radiologic assessment. In this age group, orthotic treatment may be beneficial in slowing curve progression.[33,43,46,47] Once the curve magnitude exceeds 40 degrees in a child with a neurogenic scoliosis older than 10 years, a long spinal fusion to the sacrum should be considered. To achieve a well-balanced correction, a staged anterior release, and if necessary a decompression and reconstruction, followed by posterior fusion using segmental instrumentation is often recommended.

Lordotic Deformity

Lordotic deformity after trauma is most frequently the result of a distractive-extension injury resulting in a large anterior fish-mouth deformity. Surgical indications include neurologic deterioration, progressive or large fixed deformities, and spinal instability associated with incapacitating pain unresponsive to conservative treatment.

Translational Deformity

Patients with a fixed translational post-traumatic deformity of the thoracolumbar spine have a significant three-column injury to the spine and often require a multiapproach surgical strategy to improve spinal balance. Once a deformity becomes fixed, a posterior release and or osteotomy followed by an anterior release and fusion followed again by a posterior stabilization procedure may be necessary to correct a significant sagittal plane deformity. Other indications for surgery include neurologic deterioration, a progressive or large fixed deformity, or obvious spinal instability unresponsive to conservative treatment.

Outcomes

The variables affecting the outcomes of surgical management of post-traumatic instability are multifactorial. Factors include the age of the patient, medical comorbidities, type of initial osseoligamentous and neural injury, the time duration between injury and deformity correction, the attainment of fracture or fusion union, and the technical skill of the operating surgeon. Keene et al. reported satisfactory results after the surgical treatment of post-traumatic deformities.[48] The authors noted that

the type of surgical reconstruction had little effect on the overall outcome of these patients. The timing of reconstruction was noted to have an influence on clinical outcomes as patients who were operated on within 12 months of their injury had better outcomes than those treated in a more delayed fashion. Lehmer et al. reported a 93% maintenance of correction and a 100% fusion rate in 38 patients undergoing a posterior closing wedge osteotomy for late thoracolumbar kyphosis.[49] Wu et al. reported on the surgical treatment of rigid post-traumatic kyphotic deformity in 13 patents. They noted an average of 38.8 degrees of kyphotic correction maintained at 2 years after a posterior decompression with instrumentation and fusion of one segment above and below the level of deformity.[49A] Recently, Oner et al. noted that MRI findings of end-plate comminution and vertebral body involvement portended a poor prognosis in thoracolumbar spine fracture patients treated conservatively.[27] They observed that the recurrence of kyphotic deformity in operatively treated patients could be reliably predicted when posterior longitudinal ligamentous complex disruption was present with end-plate comminution and vertebral body involvement on preoperative imaging evaluation.

Complications

The late onset of nerologic worsening after post-traumatic deformity progression is fortunately rare.[50,51] This complication, expectantly, is greater in the surgical management of post-traumatic spinal deformity. Factors such as instrumentation misplacement due to complex anatomic distortion or more commonly spinal cord tethering from deformity correction may explain the increased rate of neurologic injury. Intraoperative spinal cord monitoring is extremely useful in the early detection of changes in neurologic function during surgical manipulation.[50,51]

Patients treated surgically for post-traumatic deformity are often debilitated and chronically colonized by bacteria because of delayed mobilization and prolonged hospitalization. Furthermore, depending on their postinjury neurologic status, these patients may have open decubiti leading to an increased rate of infection with any type of surgical intervention. Postoperative infections in these frequently debilitated polytrauma patients frequently result from less virulent bacteria. In those patients who have had spinal cord injury with lower extremity paralysis and a neurogenic bladder, prolonged inpatient admissions or delay in surgical intervention increases the risk of polymicrobial infections due to urinary tract colonization or line sepsis. Adequate nutrition with parenteral supplementation, early mobilization, removal of indwelling lines and catheters as early as possible, proper hygiene, and local wound care may help decrease the incidence of spinal wound infections.

♦ Conclusion

Traumatic injury to the spinal cord and vertebral column is a devastating injury that is fraught with potential complications including the potential for post-traumatic spinal deformity. Successful management of a post-traumatic spinal deformity requires a thorough understanding of the three-dimensional nature of the deformity and the alterations of normal spinal anatomy that are frequently noted in this group of patients. In addition, a clear understanding of the injury mechanism and the resultant deficiencies of the bony and soft-tissue structures is paramount to the selection of an appropriate treatment regimen. Failure to appreciate potentially unstable injury patterns may result in inadequate immobilization or delay in operative treatment. Once present, the treatment of a post-traumatic deformity should adhere to basic biomechanical principles of deformity surgery including achieving spinal balance and a well-healed spinal fusion. An anterior, posterior, or a combined surgical approach may be necessary depending upon the degree and type of spinal deformity. Care must be taken when manipulating the spinal column such that preexisting spinal cord damage is not further aggravated. Nevertheless, surgical management of post-traumatic deformity is an arduous undertaking. A strict attention to detail and preoperative planning are mandatory to ensure a successful outcome with restoration of spinal stability.

References

1. Vaccaro AR, Jacoby SM. Thoracolumbar fractures and dislocations. In: Fardon DF, Garfin SR, eds. Orthopedic Knowledge Update: Spine. Rosemont, IL: American Academy of Orthopaedic Surgeons; 2002: 263–278
2. Gertzbein SD. Scoliosis Research Society. Multicenter spine fracture study. Spine 1992;17(5):528–540
3. Vaccaro AR, Silber JS. Post-traumatic spinal deformity. Spine 2001; 26(24 Suppl):S111–S118
4. Abel R, Gerner HJ, Smit C, Meiners T. Residual deformity of the spinal canal in patients with traumatic paraplegia and secondary changes of the spinal cord. Spinal Cord 1999;37(1):14–19
5. Been HD, Poolman RW, Ubags LH. Clinical outcome and radiographic results after surgical treatment of post-traumatic thoracolumbar kyphosis following simple type A fractures. Eur Spine J 2004;13(2):101–107
6. Spinal cord injury: facts and figures at a glance. J Spinal Cord Med 2001;24(3):212–213
7. Andriacchi T, Schultz A, Belytschko T, Galante J. A model for studies of mechanical interactions between the human spine and rib cage. J Biomech 1974;7(6):497–507
8. Denis F. The three column spine and its significance in the classification of acute thoracolumbar spinal injuries. Spine 1983;8:817–831
9. Crossman PT, Scott JM. Does 'canal clearance' affect neurological outcome after thoracolumbar burst fractures? J Bone Joint Surg Br 2001;83(1):151–152
10. Korovessis P. The significance of thoracolumbar spinal canal size in spinal cord injury patients. Spine 2001;26(18):2059–2060
11. Bolesta MJ, Bohlman HH. Late sequelae of thoracolumbar fractures and fracture-dislocations: surgical treatment. In: Frymoyer JW, ed. The Adult Spine: Principles and Practice. Philadelphia: Lippincott-Raven; 1997:1513–1533
12. Keene JS, Lash EG, Kling TF Jr. Undetected posttraumatic instability of "stable" thoracolumbar fractures. J Orthop Trauma 1988;2(3):202–211

13. Domenicucci M, Preite R, Ramieri A, Ciappetta P, Delfini R, Romanini L. Thoracolumbar fractures without neurosurgical involvement: surgical or conservative treatment? J Neurosurg Sci 1996;40(1):1–10

14. Illes T, de Jonge T, Doman I, Doczi T. Surgical correction of the late consequences of posttraumatic spinal disorders. J Spinal Disord Tech 2002;15(2):127–132

15. Malcolm BW, Bradford DS, Winter RB, Chou SN. Post-traumatic kyphosis. A review of forty-eight surgically treated patients. J Bone Joint Surg Am 1981;63(6):891–899

16. Oda I, Cunningham BW, Buckley RA, et al. Does spinal kyphotic deformity influence the biomechanical characteristics of the adjacent motion segments? An in vivo animal model. Spine 1999;24(20): 2139–2146

17. Bohlman HH, Kirkpatrick JS, Delamarter RB, Leventhal M. Anterior decompression for late pain and paralysis after fractures of the thoracolumbar spine. Clin Orthop Relat Res 1994;300:24–29

18. Polly DW, Klemme WR, Shawen S. Management options for the treatment of posttraumatic thoracic kypohosis. Semin Spine Surg 2002;12: 110–116

19. Qiu Y, Zhu ZZ, Lu JY, Wang B, Li WG, Zhu LH. Clinical manifestations and significance of post-traumatic thoracolumbar syringomyelia. Chin J Traumatol 2004;7(1):52–55

20. Batzdorf U, Klekamp J, Johnson JP. A critical appraisal of syrinx cavity shunting procedures. J Neurosurg 1998;89(3):382–388

21. Bernhardt M. Normal spinal anatomy: normal sagittal plane alignment. In: Bridwell KH, DeWald RL, eds. The Textbook of Spinal Surgery. Philadelphia: Lippincott-Raven; 1997:185–191

22. DeSmet AA. Radiographic evaluation. In: Radiology of Spinal Curvature. St. Louis: Mosby; 1985:23

23. Curati WL, Kingsley DP, Kendall BE, Moseley IF. MRI in chronic spinal cord trauma. Neuroradiology 1992;35(1):30–35

24. Lee TT, Alameda GJ, Gromelski EB, Green BA. Outcome after surgical treatment of progressive posttraumatic cystic myelopathy. J Neurosurg 2000;92(2 Suppl):149–154

25. Rechtine GR II, Cahill D, Chrin AM. Treatment of thoracolumbar trauma: comparison of complications of operative versus nonoperative treatment. J Spinal Disord 1999;12(5):406–409

26. Resch H, Rabl M, Klampfer H, Ritter E, Povacz P. [Surgical vs. conservative treatment of fractures of the thoracolumbar transition.] Unfallchirurg 2000;103(4):281–288

27. Oner FC, van Gils AP, Faber JA, Dhert WJ, Verbout AJ. Some complications of common treatment schemes of thoracolumbar spine fractures can be predicted with magnetic resonance imaging: prospective study of 53 patients with 71 fractures. Spine 2002;27(6):629–636

28. Vaccaro AR, Blam OG. Adult spine trauma. In: Koval KJ, ed. Orthopaedic Knowledge Update. Rosemont, IL: American Academy of Orthopedic Surgeons; 2002:593–607

29. Shaffrey CI, Shaffrey ME, Whitehill R, Nockels RP. Surgical treatment of thoracolumbar fractures. Neurosurg Clin N Am 1997;8(4):519–540

30. Seljeskog EL. Thoracolumbar injuries. Clin Neurosurg 1983;30:626–641

31. Saboe LA, Reid DC, Davis LA, Warren SA, Grace MG. Spine trauma and associated injuries. J Trauma 1991;31(1):43–48

32. Kerttula LI, Serlo WS, Tervonen OA, Paakko EL, Vanharanta HV. Post-traumatic findings of the spine after earlier vertebral fracture in young patients: clinical and MRI study. Spine 2000;25(9):1104–1108

33. Lancourt JE, Dickson JH, Carter RE. Paralytic spinal deformity following traumatic spinal-cord injury in children and adolescents. J Bone Joint Surg Am 1981;63(1):47–53

34. Denis F. Spinal instability as defined by the three-column spine concept in acute spinal trauma. Clin Orthop Relat Res 1984;189:65–76

35. Kostuik JP, Matsusaki H. Anterior stabilization, instrumentation, and decompression for post-traumatic kyphosis. Spine 1989;14(4):379–386

36. Knop C, Fabian HF, Bastian L, Blauth M. Late results of thoracolumbar fractures after posterior instrumentation and transpedicular bone grafting. Spine 2001;26(1):88–99

37. Moreland DB, Egnatchik JG, Bennett GJ. Cotrel-Dubousset instrumentation for the treatment of thoracolumbar fractures. Neurosurgery 1990;27(1):69–73

38. McBride GG, Greenberg D. Treatment of Charcot spinal arthropathy following traumatic paraplegia. J Spinal Disord 1991;4(2):212–220

39. Standaert C, Cardenas DD, Anderson P. Charcot spine as a late complication of traumatic spinal cord injury. Arch Phys Med Rehabil 1997;78(2):221–225

40. Sobel JW, Bohlman HH, Freehafer AA. Charcot's arthropathy of the spine following spinal cord injury. A report of five cases. J Bone Joint Surg Am 1985;67(5):771–776

41. Roberson JR, Whitesides TE Jr. Surgical reconstruction of late post-traumatic thoracolumbar kyphosis. Spine 1985;10(4):307–312

42. Bohlman HH, Freehafer A, Dejak J. The results of treatment of acute injuries of the upper thoracic spine with paralysis. J Bone Joint Surg Am 1985;67(3):360–369

43. Transfeldt EE, White D, Bradford DS, Roche B. Delayed anterior decompression in patients with spinal cord and cauda equina injuries of the thoracolumbar spine. Spine 1990;15(9):953–957

44. Anderson PA. Late anterior decompression of thoracolumbar spine fractures. Semin Spine Surg 1990;2:54–62

45. Bradford DS, McBride GG. Surgical management of thoracolumbar spine fractures with incomplete neurologic deficits. Clin Orthop Relat Res 1987;218:201–216

46. Vlach O, Bayer M. [Sequelae of injuries of the thoracolumbar spine and indications for surgery.] Acta Chir Orthop Traumatol Cech 1991;58(3): 174–177

47. Willen J, Dahllof AG, Nordwall A. Paraplegia in unstable thoracolumbar injuries. A study of conservative and operative treatment regarding neurological improvement and rehabilitation. Scand J Rehabil Med Suppl 1983;9:195–205

48. Keene JS, Wackwitz DL, Drummond DS, Breed AL. Compression-distraction instrumentation of unstable thoracolumbar fractures: anatomic results obtained with each type of injury and method of instrumentation. Spine 1986;11(9):895–902

49. Lehmer SM, Keppler L, Biscup RS, Enker P, Miller SD, Steffee AD. Posterior transvertebral osteotomy for adult thoracolumbar kyphosis. Spine 1994;19(18):2060–2067

49A. Wu SS, Hwa Sy, Lin LC, Pai WM, Chen PQ, Au MK. Management of rigid post-traumatic kyphosis. Spine 1996 Oct 1;21(19):2260–2266

50. Clohisy JC, Akbarnia BA, Bucholz RD, Burkus JK, Backer RJ. Neurologic recovery associated with anterior decompression of spine fractures at the thoracolumbar junction (T12–L1). Spine 1992;17(8 Suppl): S325–S330

51. Chapman JR, Anderson PA. Thoracolumbar spine fractures with neurologic deficit. Orthop Clin North Am 1994;25(4):595–612

Chapter 26

Bracing and Nonoperative Treatment of Spinal Deformity

Christopher M. Bono

Treatment of spinal deformities can be operative or nonoperative. Surgical treatment involves direct bony manipulation using instrumentation to eventuate fusion in a corrected position. Nonoperative treatment has less lofty, but equally important, goals. Numerous methods of nonoperative treatment have been used, including traction, electrical stimulation, and stretching, though only bracing and casting have demonstrated clinical efficacy. Bracing and casting rely on indirect manipulation of spinal curvatures, with the primary goal usually being arrest or prevention of deformity.

The indications and goals for nonoperative treatment of spinal deformities vary with different diagnoses. For instance, bracing is indicated to treat idiopathic adolescent scoliosis curves between 30 degrees and 45 degrees in a skeletally immature patient. In this instance, cessation of curve progression is a positive result. In conditions such as Scheuermann's kyphosis, bracing may in fact be effective in maintaining a corrected spine. In contrast, bracing patients with spondylolisthesis is usually for symptomatic relief of back pain, although it may aid healing of the lytic defect in some adolescent cases with minimal or no slip.

It is the purpose of this chapter to discuss the available methods, indications, and outcomes of nonoperative treatment. A focus is placed on bracing, a mainstay of nonsurgical management of spinal deformities, with an expanded discussion of its role in idiopathic scoliosis.

♦ Prevention and Early Detection of Spinal Deformity

Prevention of spinal deformity can take many forms. It may be (1) prenatal or preconception, as is the case for myelomeningocele; (2) centered around early diagnosis, such as school screening for idiopathic scoliosis or regular radiographic follow-up after a thoracolumbar burst or compression fracture; (3) intraoperative, such as the decision to fuse after sacrifice of more than 50% of the facet joints and pars interarticularis during posterior decompression.

Genetic counseling may alert prospective parents of a propensity toward specific congenital deformities with proposed hereditary patterns.[1] Preemptively, maternal folate intake prior to conception decreases the chance of congenital neural tube defects (myelomeningocele).[2] After conception, prenatal screening, including α-fetoprotein levels and ultrasound, are useful in the early detection of neural tube defects. In the fetus or neonate, congenital spinal defects should be suspected when other anomalies are present. Genitourinary and cardiac malformations are present in 20% and 12% of children, respectively, with congenital spinal disorders.

In the preteen stage, school screening can help detect mild idiopathic scoliotic curves early on when they may be amenable to nonoperative measures. Regular inspection by a pediatrician can aid early diagnosis of kyphotic disorders such as Scheuermann's disease, which may be correctable with brace treatment in its early stages. Congenital curves are highly progressive and usually necessitate surgical intervention at initial presentation.[3] However, early detection may help lessen the amount and complexity of surgery required.

There are several avoidable iatrogenic causes of spinal deformity. Postirradiation kyphosis can be prevented by excluding the spine from the radiation field, if possible, with nonspinal tumors.[4] Late-onset kyphosis is a common sequelae associated with laminectomy without fusion in the thoracic spine. Postlaminectomy kyphosis can be prevented or minimized by maintaining at least 50% of the facet joint integrity or fusing when this criterion cannot be met.[5] In children, postlaminectomy kyphosis can develop as late as 6 years after surgery, necessitating long-term radiographic follow-up.[6] Iatrogenic postoperative deformities may also occur secondary to either a failed arthrodesis or incorrect selection of fusion levels.[7,8] Bracing has been largely ineffective

in the management of postlaminectomy and postirradiation kyphosis.[4]

Kyphosis is a common radiographic sequelae after nonoperative treatment of thoracolumbar burst fractures. Although the clinical significance of these deformities remains to be defined, early treatment in a hyperextension brace is often employed to prevent collapse at the fracture site.[9] Patients can be treated with a Jewett extension brace or custom-molded thoracolumbar sacral orthosis (TLSO). Interestingly, the efficacy of brace or cast treatment to prevent local kyphosis after compression fractures or so-called stable burst fractures has yet to be demonstrated in a prospective clinical trial.

♦ Biomechanical Principles of Spinal Bracing

General Principles

Spinal bracing attempts to position the vertebral column in a corrected or overcorrected position. This is achieved indirectly through externally applied forces. Forces are applied to the skin and transmitted to subcutaneous skeletal structures that are confluent with the vertebrae. Posteriorly, the spinous processes are largely subcutaneous and accessible for brace contact. Anteriorly, thoracic and abdominal viscera cover the spine. This creates a deficiency of direct contact points. Pelvic structures, such as the iliac crest, can be used to influence the position of the lower lumbar spine. The subcutaneous path of the ribs and sternum make them a viable site for deformity-correcting contact areas. Though no longer popular because of the development of dental deformities in young patients as well as poor compliance,[10] the mandible has also been used as a site of brace contact to enable better control of the upper thoracic spinal column.

Coronal Deformity

Brace correction of a deformity requires a 3-point bending moment applied to a flexible spine. For coronal deformities, a lateral force is applied at the apex of the convexity while contralateral forces above and below the apex are simultaneously applied. With scoliosis, coronal force vectors are produced at the lateral rib cage or iliac wing. In vivo studies have correlated the amount of force exerted through the brace to the percentage of curve correction.[11] The axilla is the upper limit of coronal contact areas, making control of levels above T4 difficult with underarm bracing.[11] Control of upper thoracic scoliosis can include use of mandibular pads (Milwaukee brace). Rotational deformity is not directly corrected by bracing maneuvers but is rather indirectly influenced by coupled lateral flexion-rotational motion.

Sagittal Deformity

Hyperextension bracing or casting can be useful for kyphotic curves. Correction vectors are applied to the sternum, anterior iliac spines, and spinous processes. Broad sternal pads (Jewett-type brace) can deliver a posterior force to the upper thoracic spine while strong anterior forces are delivered to the kyphotic apex through the spinous processes.[12]

Biomechanical Limitations

Braces are limited by several factors. The forces applied must be compatible with tissue survival, as skin breakdown and pressure necrosis are known complications. Contact pads with large surface areas dissipate corrective forces over broader surfaces and relieve concentrated points of pressure. This, and frequent clinical monitoring of the integument, can help prevent these complications.

Braces are also limited in that corrective forces are broadly applied and cannot be precisely directed toward one specific vertebra. In addition, these vectors are applied at a significant distance from the spinal column and thus much of the corrective forces are dissipated within extravertebral tissues.

♦ Brace Types

Charleston Brace

The Charleston brace is a custom-made, underarm TLSO (**Fig. 26–1**). It relies on achieving overcorrection of the scoliotic curve, which is achieved by tightening the straps. It is worn only part-time, usually at night.

Wilmington Brace

The Wilmington brace was developed in an attempt to improve the cosmetic appeal of the brace and, in turn, the wear compliance. It is custom-molded from a single-piece of plastic (**Fig. 26–2**).

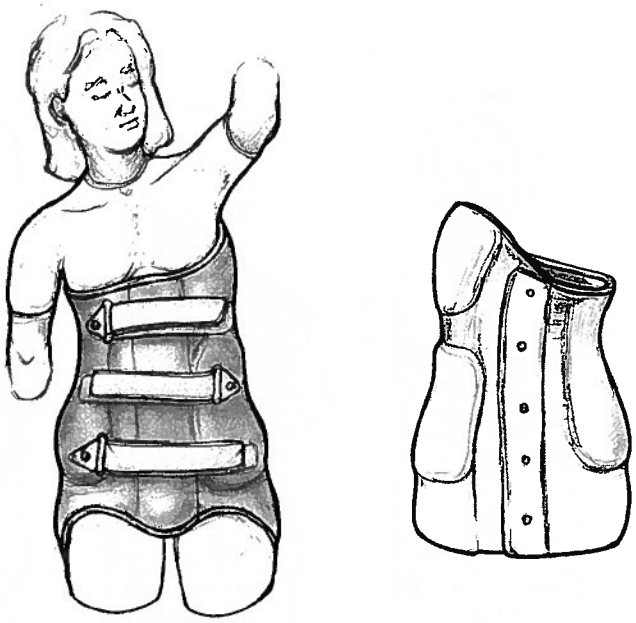

Figure 26–1 The Charleston brace is a custom-made underarm thoracolumbar sacral orthosis (TLSO).

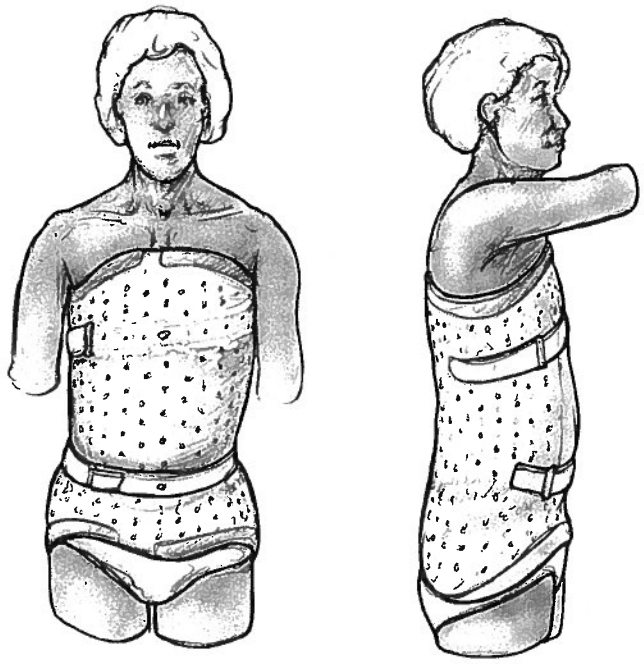

Figure 26–2 The Wilmington brace was developed in an attempt to improve the cosmetic appeal and wear compliance of the brace. It is custom-molded from a single piece of plastic.

Milwaukee Brace

The Milwaukee brace was the first device designed to treat idiopathic scoliosis. It includes a form-fitting apron that rests upon subcutaneous pelvic bony protuberances, notably the iliac crests, anterior and posterior superior iliac spines, and ischial tuberosities. Longitudinal uprights span the abdomen and thorax to support occipital and mandibular pads (**Fig. 26–3**). An adjustable side pad is used to deliver curve correcting force. It is a full-time brace.

Boston Brace

The Boston brace was the first underarm brace introduced to treat scoliosis (**Fig. 26–4**). Lateral correcting forces are delivered above the apex through the underarm bar and below the apex through the apron portion of the brace. This enables a large window cut-out on the concave side of the curve. It is intended to be worn full-time.

Jewett Hyperextension Brace

The Jewett hyperextension brace is an example of an adjustable, non-custom-molded, "off the shelf" device that can be used to correct hyperkyphosis. In comparison with a form-fitting TLSO, it offers little rotational control. It is most often used to treat Scheuermann's kyphosis and some traumatic thoracic or lumbar fractures.

Antilordotic Lumbosacral Brace

The antilordotic brace was designed to hold the lower lumbar spine in a flexed position. It is thought that this posture can relieve the shear stresses on the pars interarticularis and encourage healing in patients with spondylolytic lesions.

♦ Bracing and Nonoperative Treatment for Specific Spinal Conditions

Adolescent Idiopathic Scoliosis

Indications

Nonoperative decision-making for idiopathic scoliosis is influenced by the degree and progressivity of the curve. Scoliotic curves measuring between 10 degrees and 20 degrees

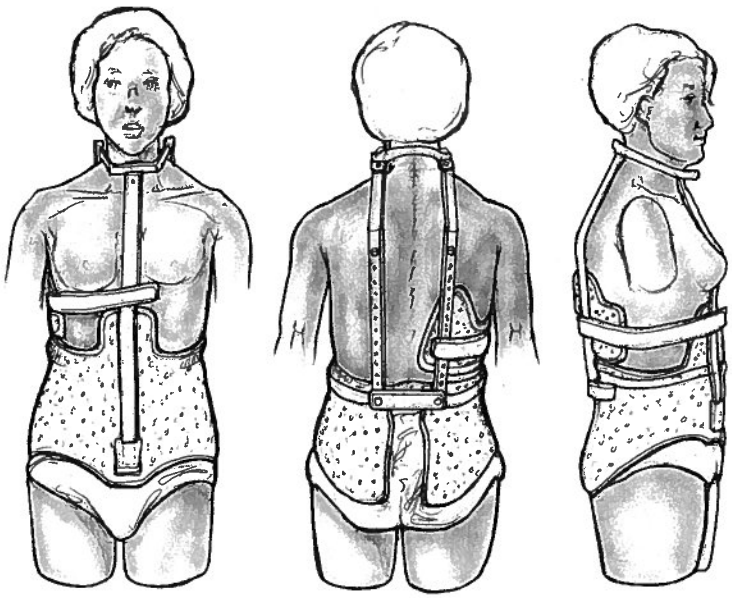

Figure 26–3 The Milwaukee brace includes a form-fitting apron that rests upon subcutaneous pelvic bony protuberances and longitudinal uprights that support occipital and mandibular pads.

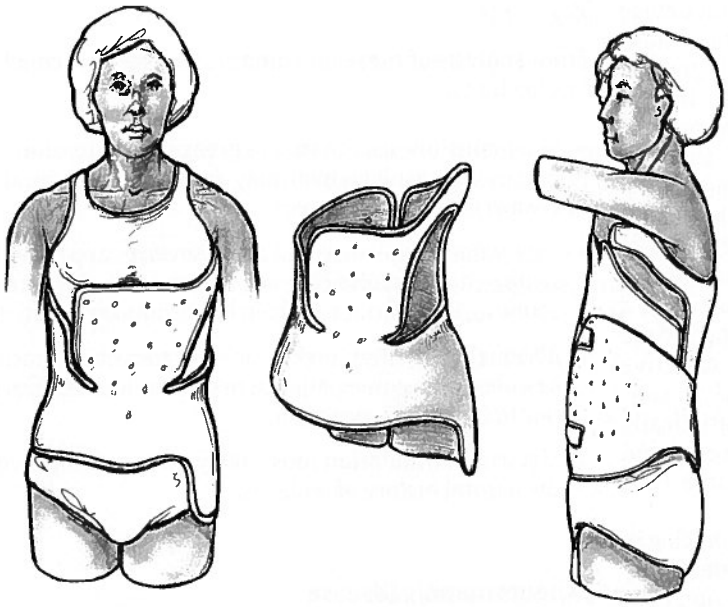

Figure 26–4 The Boston brace was the first underarm brace introduced to treat scoliosis.

warrant close observation. Radiographs should be obtained every 6 to 12 months until skeletal maturity to detect progression of the deformity. For those with curves between 20 degrees and 30 degrees, observation should include radiographs every 4 to 6 months until skeletal maturity.

The indications for brace treatment have varied over the past decade. Recently, the indications for surgery have become more stringent, increasing the number of patients who are "braceable." Brace treatment may be indicated for skeletally immature patients with curves that measure between 30 degrees and 45 degrees. Progressivity can warrant bracing curves that would otherwise be treated by observation alone. Specifically, 5 degrees of radiographically documented progression in a patient with a 25-degree curve may be an indication. Bracing may have a more limited role in boys than in girls, with recent data suggesting that results are inferior in adolescent male patients, most likely because of poor wear compliance.

There is currently minimal to no role for electrical stimulation in the treatment of idiopathic scoliosis because of lack of supporting evidence.

Published Outcomes

Several studies have focused on documenting the effectiveness of brace treatment compared with observation alone. Nachemson and Peterson[13] found bracing to be associated with success in 74% of patients, whereas observation was successful in only 34%. In one of the largest series of brace treatment, encompassing more than 1000 patients, Lonstein and Winter[14] found the rate of failure using a brace to be lower than observation alone. In contrast, Goldberg et al.[15] found no significant difference between bracing and observation. However, the patient groups were small in comparison with other studies, with only 32 patients in each group.

Several investigators have reported results of brace treatment for large curves. Katz and Durrani[16] evaluated their results using the Boston brace in 51 patients with curves greater than 35 degrees. Thirty-one patients (61%) demonstrated no curve progression at the time treatment was stopped. At final follow-up, 8 had progressed greater than 5 degrees, with a total of 16 patients eventually undergoing surgery. For patients with double curves, they found that predictors of curve progression were lumbar-pelvic relationship (12 degrees or more) and the patients' reported compliance. Wiley et al.[17] also concentrated on large idiopathic curves. In their retrospective study of 50 patients with curves between 35 degrees and 45 degrees treated in a Boston brace, only 2 of the 24 patients (8.3%) in the compliant group had progression of more than 5 degrees. Of note, 5 of 14 patients (36%) in the semicompliant group (brace worn 12 to 18 hours per day) and 11 of 12 (92%) in the noncompliant group (0 to 12 hours per day) had curves that progressed more than 5 degrees.

Nighttime bracing has been advocated by several authors. D'Amato et al.[18] performed a prospective study of computer-designed nighttime bracing in 102 female patients with scoliosis. Seventy-five patients (74%) had no progression more than 5 degrees; 27 patients (26%) progressed 6 degrees or more. The curve types most successfully managed were lumbar and thoracolumbar curves (94% and 93%, respectively). Although both large (greater than 35 degrees) and small (less than 35 degrees) curves were included, the available numbers allowed meaningful statistics only for the latter group, indicating that it was an effective means of preventing curve progression. Trivedi and Thomson.[19] found the Charleston nighttime brace to be effective in arresting curve progression in 25 of 42 (60%) patients. Whereas improved compliance has been touted as a major advantage over full-time braces, a recent study has shown that only 18 of 30 (60%) were compliant with a nighttime bracing program of 8 to 10 hours of wear.[20]

Some studies have compared the efficacy of different brace types. In a retrospective review, Howard et al.[21] found

that adolescents treated with a standard underarm device progressed only 1.1 degrees during bracing, whereas those treated with a Charleston or Milkwaukee brace progressed 6.5 degrees and 6.3 degrees, respectively. According to their data, the starting curves and Risser stages were comparable in all three groups. Katz et al.[22] found that the Boston brace was significantly more effective in controlling curves of 36 degrees to 45 degrees than the Charleston brace. Forty-three percent of those treated with the former progressed 5 degrees or more, whereas 83% of those treated with the Charleston device did so. Supportively, a meta-analysis of the available literature found part-time bracing (8 to 16 hours) to be significantly less effective than full-time use of a TLSO or Milwaukee brace.[23] In contrast, Allington and Bowen[24] demonstrated no statistically significant difference in curve progression in those treated with full-time versus part-time wear of the same (i.e., Wilmington) brace.

Recent literature has differentiated the results of bracing in girls from boys with idiopathic scoliosis. In a dedicated study of male patients, Karol[25] found that curve progression of at least 6 degrees occurred in 83 (74%), 52 of whom (46%) went on to surgery. Importantly, they cited a poor wear compliance rate (38%) as a possible explanation of the inferior results.

"Unconventional" methods such as short-segment bracing methods have been suggested. Van Rhijn et al.[26] compared the results of bracing the lumbar curve alone versus standard thoracic bracing methods. In the thoracic brace group, the thoracic and lumbar curves decreased by 9 degrees and 5 degrees, respectively. In the lumbar brace group, the curves decreased by 7 degrees and 12 degrees, respectively. In an earlier study, the same group[27] found that insufficient correction of the lumbar curve could change the King-Moe classification of the curve (from progression of the lumbar curve despite correction of the thoracic curve).

Recently, the use of nonrigid braces to treat idiopathic scoliosis has been reported. In 29 patients with 2-year follow-up, Coillard et al.[28] found that the nonrigid Spine-Cor (Spine Corporation, Derbyshire, United Kingdom) brace resulted in an average 10 degrees correction during treatment (brace wear), 7 degrees at the end of treatment, and 5 degrees correction at 2-year follow-up. Of note, only two patients (7%) had worsened by at least 5 degrees.

At one time, electrical stimulation was a popular means of treatment of idiopathic scoliosis. A myriad of studies, however, has discounted its ability to effect any change on the natural history of scoliosis.[29] Bertrand et al.[30] found 51% of patients progressed 5 degrees or more, which, according their review at the time, did not differ from published reports of no treatment. Similarly, Durham et al.[31] found electrical stimulation to be ineffective in preventing scoliosis progression in 40 adolescents.

An important consideration when interpreting the results of treatment of spinal deformities is the magnitude of radiographic curve changes. Recently, Morrissy et al.[32] found that intraobserver error for coronal measurements of scoliotic deformities was as high as 4.9 degrees. Similarly, Stotts et al.[33] found the intraobserver variance to be 4.3 degrees using the Cobb method of kyphosis measurement in patients with Scheuermann's disease. This should be considered when interpreting studies that report mean differences of 4 or 5 degrees.

Key Points

From analysis of these outcome studies, several conclusions can be drawn.

- Most consider less than 5 degrees of progression to be a successful result, which may represent an actual curve change of ~0 to 10 degrees.
- Poor wear compliance and curve severity appear to be the strongest predictors of brace failure, with the former accounting for inferior results in boys compared with girls.
- Although part-time (nighttime) overcorrection bracing can be effective in some patients, in general its results are inferior to full-time brace wear.
- Electrical stimulation most likely does not improve upon the natural history of scoliosis.

Scheuermann's Disease

Indications

Brace treatment is warranted for most skeletally immature patients with kyphotic curves measuring between 45 degrees and 75 degrees. Optimally, the curve should be flexible, with achievable correction to 50 degrees or less in the brace. Curves greater than 75 degrees may warrant surgical intervention, as they are not effectively controlled by bracing. In adults, it is generally believed that brace treatment offers little benefit.

Published Outcomes

Sachs et al.[34] found bracing to effectively maintain correction in 69% of patients at 5 years follow-up. Consistent brace wear (i.e., better compliance) was associated with a better result. Curves less than 60 degrees had a better result than curves greater than 60 degrees. Kyphosis of greater than 74 degrees at initial presentation was associated with poor results. Long-term, kyphotic correction may not be maintained. Farsetti et al.[35] followed 20 patients for an average of 33 years after brace treatment. The authors reported that, regardless of the initial correction obtained, all curves recurred to initial pretreatment measurements or greater at final radiographic evaluation.

Riddle et al.[36] reported the results with a newly designed duPont brace in 22 adolescent patients with Scheuermann's kyphosis. The advantage of the brace is that it can be worn underneath normal clothing. Nine patients had a mean of 9 degrees of improvement of their curve, whereas seven had no further progression. Six patients (27%) had kyphosis progression with an average curve increase of 9 degrees. Curve flexibility was a predictor of successful nonoperative treatment.

In a retrospective review of 212 patients with juvenile Scheuermann's kyphosis, Platero et al.[37] found that treatment with a body cast and a brace were predictors of a good outcome, as was compliance with treatment. Montgomery and Erwin[38] reported 21 degrees average correction of Scheuermann's kyphosis after treatment with a Milwaukee brace worn for 18 months or more.

Key Points

Considering the results of these published studies, one may conclude:

- In contrast with idiopathic scoliosis, brace treatment of Scheuermann's kyphosis may actually be able to correct the deformity.
- Average curve improvements can range from 9 degrees to 21 degrees after brace treatment, but this can take several months and multiple brace adjustments.
- Better results can be expected with smaller (less than 60 degrees) and more flexible curves.

Isthmic Spondylolisthesis

Indications

Observation is the usual treatment for isthmic spondylolisthesis. In the skeletally immature patient, a lateral radiograph of the lumbar spine should be obtained every 6 months to detect rapid progression of the slip. In the skeletally mature individual, an x-ray image should be obtained on a yearly basis. Abdominal strengthening exercises are believed to be a critical component to nonoperative treatment.

Bracing has a limited role in the treatment of spondylolisthesis. Although slip correction does not appear to be achievable, bracing can ameliorate symptoms, most notably pain. It is thought that bracing may also help heal spondylolytic pars defects. It is unclear if bracing is able to prevent slip progression.

Published Outcomes

Steiner and Micheli[39] used a modified, overlapping brace (Boston Overlap Brace, BBE Health care Ltd., County Louth, Ireland) to treat 67 young patients with symptomatic spondylolysis or grade I spondylolisthesis. This antilordotic brace was designed to hold the lumbar spine in relative flexion. At an average follow-up of 2.5 years, 52 (78%) patients demonstrated a good or excellent result, no pain, and return to full sporting activity. Nine (13%) patients had continued mild pain, and 6 (9%) patients underwent a posterolateral fusion for pain relief.

d'Hemecourt et al.[40] evaluated the results of the Boston Overlap Brace in 73 young athletes with spondylolysis or grade I spondylolisthesis, in addition to a physical therapy program that focused on flexion exercises. Patients returned to sports as early as 4 to 6 weeks if they (1) had no pain with extension on physical examination, (2) wore the brace full-time, and (3) remained pain-free. Fifty-six (77%) athletes demonstrated good or excellent results.

Pizzutillo and Hummer[41] found nonoperative means, including bracing and therapy, to be effective at reducing symptoms in 31 of 82 adolescents with painful lytic lesions or slips. Importantly, only 1 of the 12 patients with a high-grade (III or IV) slip was successfully managed by nonsurgical means, with 11 undergoing surgery.

Key Points

- Pain associated with isthmic spondylolisthesis usually responds to nonoperative treatment, including rest and physical therapy that concentrates on abdominal strengthening and flexion exercises.
- Bracing, particularly with an antilordotic device, in concert with a focused physical therapy program can result in pain resolution in ~80% of cases of spondylolysis or low-grade spondylolisthesis.
- Pain associated with high-grade slips (grades III or IV) is not amenable to bracing.
- There is no data to suggest that bracing can slow or reverse vertebral slippage.

Paralytic and Neurogenic Deformity

Indications

Brace wear can be effective in curve prevention in spastic paralytic disorders (e.g., cerebral palsy). In most types of flaccid paralysis, however, the lack of paraspinal muscle tone limits the efficacy of bracing that often makes early operative stabilization of curves with 25 degrees or more the treatment of choice. Bracing does not appear to have much of a role in treating deformity associated with familial dysautonomia, Friedrich's ataxia, or neurofibromatosis.

Published Outcomes

Bracing may have a role in preventing spinal deformity in children with spinal cord injuries. Brown et al.[42] found that if a quadriplegic child was braced within 6 months of the injury, provided the spine was still of normal curvature, the progressiveness of the curve decreased. Importantly, all those who were younger than 14 years developed a spinal deformity, regardless of treatment. Less optimistically, Johnston et al.[43] found that brace treatment merely simplified eventual spinal fusion surgery (one stage versus two stage) in children with paralytic deformities. In a small series of patients with myelomeningocele, Muller and Nordwall[44] found a Boston brace to be an effective means of preventing progression in 13 of 14 children with scoliosis of 45 degrees or less.

Hayek et al.[45] found bracing to be ineffective in stopping scoliotic, kyphotic, and kyphoscoliotic curves in patients afflicted with familial dysautonomia, a disorder that affects the central, autonomic, and peripheral nervous systems. Fifty-eight of 65 patients (89%) had curve progression despite bracing. Similarly, Cady and Bobechko[46] found bracing to be ineffective in managing scoliosis associated with Friedreich's ataxia.

Connective Tissue Disorders

Several connective tissue disorders can lead to spinal deformity. Sponseller et al.[47] found that scoliotic curves in patients with Marfan's syndrome progressed at a rate of 6 ± 8 degrees per year. Although correction in a brace was relatively easy to achieve (presumably because of ligamentous laxity), the

majority of patients eventually went on to surgery. Only 17 percent of patients had successful brace treatment. They concluded that patients with curves of 25 degrees or more should be advised that the curve will, over time, progress to a surgical range. Despite excellent in-brace corrections, spinal deformities with Ehlers-Danlos syndrome are equally (if not more) difficult to prevent, with most treatment reports being surgical.[48]

References

1. Langer L, Moe J. A recessive form of congenital scoliosis different from spondylothoracic dysplasia. Birth Defects Orig Artic Ser 1975;11:83–86
2. Morrow J, Kelsey K. Folic acid for prevention of neural tube defects: pediatric anticipatory guidance. J Pediatr Health Care 1998;12:55–59
3. Winter R, Lonstein J, Boachie-Adjei O. Congenital spinal deformity. In: Pritchard D, ed. Instructional Course Lectures. Rosemont, IL: American Academy of Orthopaedic Surgeons; 1996:117–127
4. Otsuka N, Hey L, Hall J. Postlaminectomy and postirradiation kyphosis in children and adolescents. Clin Orthop Relat Res 1998;354:189–194
5. Abumi K, Panjabi M, Kramer K, et al. Biomechanical evaluation of lumbar spinal stability after graded facetectomies. Spine 1990;15: 1142–1147
6. Tachdjian M, Matson D. Orthopaedic aspects of intraspinal tumors in infants and children. J Bone Joint Surg Am 1965;47:223–248
7. Lowe T, Kasten M. An analysis of sagittal curves and balance after Cotrel-Dubousset instrumentation for kyphosis secondary to Scheuermann's disease. A review of 32 patients. Spine 1994;19:1680–1685
8. Sasso R, Cotler H. Posterior instrumentation and fusion for unstable fractures and fracture dislocations of the thoracic and lumbar spine. Spine 1993;18:450–460
9. Ohana N, Scheinis D, Rath E, et al. Is there a need for lumbar orthosis in mild compression fractures of the thoracolumbar spine? A retrospective study comparing the radiographic results between early ambulation with and without lumbar orthosis. J Spinal Disord 2000;13: 305–308
10. Logan W. The effect of Milwaukee brace on the developing dentition. Trans Brit Soc Orthod London 1962:1–8
11. Chase AP, Bader DL, Houghton GR. The biomechanical effectiveness of the Boston brace in the management of adolescent idiopathic scoliosis. Spine 1989;14:636–642
12. Colbert AP, Craig C. Scoliosis management in Duchenne muscular dystrophy: propsective study of modified Jewett hyperextension brace. Arch Phys Med Rehabil 1987;68:302–304
13. Nachemson AL, Peterson LE. Effectiveness of treatmetn with a brace in girls who have adolescent idiopathic scoliosis. A prospective, controlled study based on data from the Brace Study of the Scoliosis Research Society. J Bone Joint Surg Am 1995;77:815–822
14. Lonstein JE, Winter RB. The Milwaukee brace for the treatment of adolescent idiopathic scoliosis. A review of one thousand and twenty patients. J Bone Joint Surg Am 1994;76:1207–1221
15. Goldberg CJ, Dowling FE, Hall JE, Emans JB. A statistical comparison between natural history of idiopathic scoliosis and brace treatment in skeletally immature adolescent girls. Spine 1993;18:902–908
16. Katz DE, Durrani AA. Factors that influence outcome in bracing large curves in patients with adolescent idiopathic scoliosis. Spine 2001;26: 2354–2361
17. Wiley JW, Thomson JD, Mitchell TM, Smith BG, Banta JV. Effectiveness of the Boston brace in treatment of large curves in adolescent idiopathic scoliosis. Spine 2000;25:2326–2332
18. D'Amato CR, Griggs S, McCoy B. Nighttime bracing with the Providence brace in adolescent girsl with idiopathic scoliosis. Spine 2001;26: 2006–2012
19. Trivedi JM, Thomson JD. Results of Charleston bracing in skeletally immature patients with idiopathic scoliosis. J Pediatr Orthop 2001;21:277–280
20. Bowen JR, Keeler KA, Pelegie S. Adolescent idiopathic scoliosis managed by a nighttime bending brace. Orthopedics 2001;24:967–970
21. Howard A, Wright JG, Hedden D. A comparative study of TLSO, Charleston, and Milwaukee braces for idiopathic scoliosis. Spine 1998;23: 2404–2411
22. Katz DE, Richards BS, Browne RH, Herring JA. A comparison between the Boston brace and the Charleston bending brace in adolescent idiopathic scoliosis. Spine 1997;22:1302–1312
23. Rowe DE, Bernstein SM, Riddick MF, et al. A meta-analysis of the efficacy of non-operative treatments for idiopathic scoliosis. J Bone Joint Surg Am 1997;79:664–674
24. Allington NJ, Bowen JR. Adolescent idiopathic scoliosis: treatment with the Wilmington brace. A comparison of full-time and part-time use. J Bone Joint Surg Am 1996;78:1056–1062
25. Karol LA. Effectiveness of bracing in male patients with idiopathic scoliosis. Spine 2001;26:2001–2005
26. van Rhijn LW, Veraart BE, Plasmans CM. Application of a lumbar brace for thoracic and double thoracic lumbar scoliosis: a comparative study. J Pediatr Orthop B 2003;12:178–182
27. van Rhijn LW, Plasmans CM, Veraart BE. Changes in curve pattern after brace treatment for idiopathic scoliosis. Acta Orthop Scand 2002;73: 277–281
28. Coillard C, Leroux MA, Zabjek KF, Rivard CH. Spine-Cor—a non-rigid brace for the treatment of idiopathic scoliosis: post-treatment results. Eur Spine J 2003;12:141–148
29. O'Donnell CS, Bunnell WP, Betz RR, Bowen JR, Tipping CR. Electrical stimulation in the treatment of idiopathic scoliosis. Clin Orthop Relat Res 1988;229:107–113
30. Bertrand SL, Drvaric DM, Lange N, et al. Electrical stimulation for idiopathic scoliosis. Clin Orthop Relat Res 1992;276:176–181
31. Durham JW, Moskowitz A, Whitney J. Surface electrical stimulation versus brace in treatment of idiopathic scoliosis. Spine 1990;15:888–892
32. Morrissy RT, Goldsmith GS, Hall EC, Kehl D, Cowie GH. Measurement of the Cobb angle on radiographs of patients who have scoliosis. Evaluation of intrinsic error. J Bone Joint Surg Am 1990;72:320–327
33. Stotts AK, Smith JT, Santora SD, Roach JW, D'Astous JL. Measurement of spinal kyphosis: implications for the management of Scheuermann's kyphosis. Spine 2002;27:2143–2146
34. Sachs B, Bradford D, Winter R, et al. Scheuermann kyphosis. Follow-up of Milwaukee-brace treatment. J Bone Joint Surg Am 1987;69:50–57
35. Farsetti P, Tudisco C, Caterini R, Ippolito E. Juvenile and idiopathic kyphosis. Arch Orthop Trauma Surg 1991;110:165–168
36. Riddle EC, Bowen JR, Shah SA, Moran ER, Lawall H. The duPont kyphosis brace for the treatment of adolescent Scheuermann kyphosis. J South Orthop Assoc 2003;12:135–140
37. Platero D, Luna JD, Pedraza V. Juvenile kyphosis: effects of different variables on conservative treatment outcome. Acta Orthop Belg 1997;63:194–201
38. Montgomery SP, Erwin WE. Scheuermann's kyphosis—long-term results of Milwaukee brace treatment. Spine 1981;6:5–8
39. Steiner ME, Micheli LJ. Treatment of symptomatic spondylolysis and spondylolisthesis with the modified Boston brace. Spine 1985;10: 937–943
40. d'Hemecourt PA, Zurakowski D, Kriemler S, Micheli LJ. Spondylolysis: returning the athlete to sports participation with brace treatment. Orthopedics 2002;25:653–657
41. Pizzutillo PD, Hummer CD. Nonoperative treatment for painful adolescent spondylolysis or spondylolisthesis. J Pediatr Orthop 1989;9:538–540

42. Brown JC, Swank SM, Matta J, Barras DM. Late spinal deformity in quadriplegic children and adolescents. J Pediatr Orthop 1984;4:456–461

43. Johnston CE, Hakal MW, Rosenberger R. Paralytic spinal deformity: orthotic treatment in spinal discontinuity syndrome. J Pediatr Orthop 1982;2:233–241

44. Muller EB, Nordwall A. Brace treatment of scoliosis in children with myelomeningocele. Spine 1994;19:151–155

45. Hayek S, Laplanza FJ, Axelrod FB, Burke SW. Spinal deformity in familiar dysautonomia. Prevalence, and results of bracing. J Bone Joint Surg Am 2000;82-A:1558–1562

46. Cady RB, Bobechko WP. Incidence, natural history, and treatment of scoliosis in Friedreich's ataxia. J Pediatr Orthop 1984;4:673–676

47. Sponseller PD, Bhimani M, Solacoff D, Dormans JP. Results of brace treatment of scoliosis in Marfan syndrome. Spine 2000;25:2350–2354

48. Akpinar S, Gogus A, Talu U, Hamzaoglu A, Dikici F. Surgical management of the spinal deformity in Ehlers-Danlos syndrome type VI. Eur Spine J 2003;12:135–140

Index

Page numbers followed by an italic f or t indicate entries in figures or tables.

A
Aaro-Dahlborn rotation method, 180
Abdominal reflexes, in infantile scoliosis, 115
Adamkiewicz, artery of
  in anterior thoracolumbar approach, 182
  in Scheuermann's disease, 196
Adding on phenomenon, 181
Adolescent deformity. *See also specific types*
  versus adult, 3–4, 76–77
  clinical presentation of, 3
  flexible *versus* fixed, 76, 79–83
Adolescent idiopathic scoliosis (AIS), 94
  adult manifestation of, 217
  anterior-posterior techniques for, 83
  anterior techniques for, 51, 52*f*, 69–70, 82, 178–189
  bodily image in, 94
  bracing for, 272–274
    in boys *versus* girls, 273–274
    compliance with, 274
    efficacy of brace types in, 273–274
    indications for, 272–273
    key points in, 274
    for large curves, 273
    nighttime, 273–274
    non-rigid, 274
    outcomes of, 273–274
  clinical evaluation of, 178–180
  coronal balance in, 68–70, 82
  depression in, 94
  double major curves in (type 3), 47, 47*f*–48*f*, 48*t*, 49*f*
    treatment of, 51, 53*f*, 68–70, 68*f*
  double thoracic curves in (type 2), 47, 47*f*–48*f*, 48*t*
    treatment of, 51, 52*f*–53*f*
  electric stimulation for, 273–274
  flexible *versus* fixed deformity in, 76, 82–83
  ideal classification of, features of, 57
  King classification of, 45–46, 50, 82
  Lenke classification of, 46–57, 82, 181*t*
    benefit of, 55
    curve type in, 46–47, 47*f*–48*f*, 48*t*, 49, 49*f*
    goals of, 46, 57
    lumbar spine modifier in, 46–47, 47*f*, 49*f*
    reliability of, 49–50
    sagittal thoracic modifier in, 46, 47*f*, 49, 50*f*
    treatment directed by, 50–55, 181–182
    triad of components in, 46, 49
  main thoracic curves in (type 1), 47, 47*f*–48*f*, 48*t*
    anterior approach to, 51, 52*f*
    posterior approach to, 50, 50*f*–51*f*
    treatment of, 50–51, 68–70, 68*f*
  major curves in, 47
  minor curves in, 47, 82
  mortality rate in, 94, 96
  natural history of, 94–97
    postskeletal maturity, 96–97
    preskeletal maturity, 95–96, 95*t*
    surgical treatment and, 96–97
  observation of, 272–273
  pedicle screw fixation of, 82, 154
  point P in, 95
  point R in, 95
  posterior surgery for, 50, 51*f*–52*f*, 69, 82–83
  prevalence of, 94
  progression of, 95–97
    age and, 95–96
    curve magnitude and, 95–96, 95*t*
    curve pattern and, 95–96
    growth spurt and, 95, 95*t*
    incidence of, 95, 95*t*
    menarche and, 95–96
    postskeletal maturity, 96–97
    preskeletal maturity, 95–96

Adolescent idiopathic scoliosis *(Continued)*
Risser sign and, 95–96, 95*t*
sex (gender) and, 95–96
pulmonary function in, 26, 94
radiographic evaluation of, 178–180, 273
sagittal balance in, 82
selective thoracic fusion for, 68–70
anterior approach in, 69–70
posterior approach in, 69
preoperative planning for, 70
results of, 69–70
structural *versus* nonstructural curves in, 82
thoracolumbar/lumbar curves in (type 5), 47, 47*f*–48*f*, 48*t*
treatment of, 55, 55*f*–56*f*
thoracolumbar/lumbar-main thoracic curves in (type 6), 47, 47*f*–48*f*, 48*t*
treatment of, 55, 56*f*, 68–70, 68*f*
three-dimensional analysis of, 57
triple major curves in (type 4), 47, 47*f*–48*f*, 48*t*
treatment of, 51, 54*f*
Adult deformity. *See also specific types*
versus adolescent, 3–4, 76–77
clinical presentation of, 3
definition of, 5
flexible *versus* fixed, 76–77, 83–85
pain with, 3, 8, 217–219, 221, 228
versus pediatric, 76–77
progression of, 3, 8
revision surgery in, 226–227, 240–247. *See also* Adult revision surgery
surgery for, 217–228
surgical indications in, 8
treatment challenge of, 3–4
Adult idiopathic scoliosis, 217
coronal balance in, 70–71
double thoracic curves in, treatment of, 70
flexibility *versus* rigidity in, 76–77
flexible *versus* fixed deformity in, 83–85
Lenke classification of, treatment directed by, 70–71
lumbosacral fractional curves in, treatment of, 71
lung function in, 8
single thoracic curves in (type 1), treatment of, 70
thoracolumbar/lumbar curves in (type 5), treatment of, 70
Adult revision surgery, 226–227, 240–247
for combined imbalance, 240, 244, 245*f*, 245*t*
for coronal imbalance, 240, 244, 244*f*, 244*t*
for implant failure or pullout, 240, 246, 247*t*
for infection, 240, 245–246, 246*t*
for marked degeneration distal to fusion, 240, 246, 246*t*
for marked degeneration proximal to fusion, 240, 246, 247*f*, 247*t*
nutritional concerns in, 240
for pseudoarthrosis, 240, 244–245, 245*t*
reasons for, 240
for sagittal imbalance, 240–243, 244*t*
pedicle subtraction osteotomy in, 240, 242–243, 242*f*–243*f*
Smith-Petersen osteotomy in, 240–242, 241*f*–242*f*
staged *versus* one-day, 240
Adult scoliosis
adolescent scoliosis manifesting as, 217
ancillary tests in, 219
body habitus in, 219
bracing for, 219
conservative treatment of, 217, 219
cosmesis in, 221
curve progression in, 218, 221
clinical clues to, 218
family history of, 218
definition of, 217
de novo, 217
diskography of, 219, 220*f*
exercises for, 219
facet blocks for, 219
features of, 217
functional impairment in, 218
idiopathic. *See* Adult idiopathic scoliosis
imaging studies of, 219
incidence of, 218
lumbar/thoracolumbar, surgical treatment of, 222–226
modern approach to, 217
neurologic deficit in, 221
neurologic examination in, 219
nonoperative treatment of, 219
outcome measures for, 218–219
pain in, 217–218, 228
quantification of, 218
as surgical indication, 221
patient evaluation in, 218–219
patient history in, 218–219
pedicle screw fixation of, 222, 222*f*
physical examination in, 219
posterior surgery for, 221
quality-of-life issues in, 218, 228
revision surgery in, 226–227, 240–247. *See also* Adult revision surgery
surgical treatment of, 217–228
anesthesia for, 217, 227
blood loss and administration in, 227
indications for, 219
intraoperative management of, 227
neurophysiologic monitoring in, 227
outcomes of, 227–228
postoperative care in, 227
risks of, 217
techniques of, 221–228
thoracic, surgery for, 221–222
AESOP, 213
Age
and classification of idiopathic scoliosis, 113
and infant scoliosis treatment, 117
and kyphosis, 59–61
and lordosis, 59–61
and progression in adolescent idiopathic scoliosis, 95–96
and Scheuermann's disease, 195
and spondylolisthesis, 250
as surgical issue, 88
Airway development, in infantile scoliosis, 114–115
Airway management, 20–21
AIS. *See* Adolescent idiopathic scoliosis
Akbarnia technique, for infantile scoliosis, 118*t*, 119
Alcohol intake, and osteoporosis, 91
Allogeneic blood transfusion, minimization of, 22–24, 22*f*
Aminocaproic acid, 23–24
Amplitude, of evoked potentials, 31
anesthesia and, 33–34
changes in, pathophysiology of, 31–33
Anatomical variants, with spinal deformity, 38–43
facet joint, 41
pedicle, 39–40, 40*f*
ribs, 39, 40*f*
segmental vessels, 43
spinal cord, 41–42
spinous processes, 40–41
vascular, 42–43
vertebral body, 38–39

Anesthesia, 19–27
in adult scoliosis surgery, 217, 227
hypotensive, 23
in congenital scoliosis, 107
management of, 22–27
and neurophysiologic monitoring, 21–22, 33–34
in pediatric population, 26
preoperative evaluation for, 19–20, 19*f*
quality of recovery from, 27
total intravenous, 22, 30*f*, 34
Ankylosing spondylitis, 85, 90, 231
Anterior fusion. *See also* Anterior surgery
history of, 178
Anterior-posterior surgery, 171–176
for adolescent idiopathic scoliosis, 83
in adult patient, 171
for adult scoliosis, 223–224, 225*f*
anterior approach in, 173–175
diskectomies in, 174, 174*f*–175*f*
fusion in, 174
osteotomies in, 174–175, 174*f*–175*f*
retroperitoneal, 173
thoracoabdominal, 173–174
thoracoplasty in, 175
thoracotomy in, 173
for complex severe multiplanar deformities, 72
for congenital scoliosis, 107–108, 108*f*–109*f*, 111
for degenerative scoliosis, 71
for hemivertebral resection, 235
indications for, 171, 172*f*
for infantile scoliosis, 117
minimally invasive, prone position, 208–209
for neuromuscular scoliosis, 136, 139*f*
in pediatric patient, 171, 172*f*
posterior approach in, 176
postoperative care in, 176
preoperative care for, 173
radiologic evaluation for, 173
for rigid deformities, 171
scheduling of, 171, 173
sequential, 171, 173
simultaneous, 171
for spondylolisthesis, 255–256, 257*f*–258*f*
staged, 171, 173
techniques of, 173–176
for thoracolumbar kyphosis, post-traumatic, 264
for vertebral column resection, 235
vertebrectomy for, 256
Anterior surgery
for adolescent idiopathic scoliosis, 51, 52*f*, 69–70, 82, 178–189. *See also specific anatomic locations*
advantages of, 156
for lumbosacral fixation, 226, 226*f*
for neuromuscular scoliosis, 130, 132*f*–133*f*, 136
versus posterior, 156, 180
for Scheuermann's disease, 198, 199*f*, 203
for selective thoracic fusion, 69–70
for thoracic scoliosis, 144–152
contraindications to, 145
Cotrel-Dubousset method of, 145
indications for, 145
lower instrumented vertebra in, 145
minimally invasive, 148–152
open, 145–148
indications for, 145
perioperative complications of, 148
results of, 145–148
progressive sagittal kyphosis after, 152
pulmonary improvements with, 152
saving of fusion levels in, 145, 146*f*–147*f*, 152
spontaneous correction of lumbar curve in, 152
Suk method of, 145
techniques of, 145–152
thoracoscopic, 148–152, 206–208
bone graft in, 150
cannulated screws in, 207–208, 208*f*
closure in, 208
contraindications to, 149, 206
disk annulus and end plate removal in, 148
diskectomy and release in, 150
flexibility obtained in, 148
indications for, 149, 149*f*, 206
instrumentation placement in, 150–151, 207–208, 208*f*
internal thoracoplasty in, 150
learning curve for, 151–152, 206
neurophysiologic monitoring in, 207
Newton, Betz, Clements technique of, 148
operating room setup for, 207, 207*f*
patient positioning for, 149–150, 207, 207*f*
Picetti technique of, 148–149
postoperative care in, 151
pseudoarthrosis prevention in, 151, 151*f*
results of, 151–152
screw-rod construct in, 150–151, 207–208, 208*f*
segmental vessels in, 207, 207*f*
surgeon positioning for, 207
surgical considerations in, 206
surgical technique in, 149–151, 207–208
for thoracolumbar and lumbar scoliosis, 178–189
adult, 222–223, 223*f*–224*f*, 226
Bitan technique of, 178, 179*t*
bone grafting in, 184–185
closure in, 185–186
comparison of techniques, 179*t*
complications of, 188–189, 189*t*
convex rod compression in, 185–186
curve correction *versus* mobility preservation in, 181
differential foot sweating after, 189, 189*f*
disk space preparation in, 184
dual solid-rod system in, 182, 184, 188
Dwyer technique of, 178, 179*t*, 181, 188
end vertebra-to-end vertebra fusion in, 181, 181*f*
follow-up in, 186–188
Hall technique of, 178
Halm and Zielke technique of, 178
Harrington technique of, 178
implant failure in, 186–189, 189*f*
incision in, 182, 183*f*
indications for, 180
instrumentation avoidance at L4 or below, 180
intervertebral spaces in, 184–185
Kaneda system for, 178, 179*t*, 181, 184
Moe technique of, 178, 179*t*
neurophysiologic monitoring in, 182
patient positioning for, 182, 183*f*
postoperative bracing in, 187
postoperative management in, 186–189
postoperative physical therapy in, 188
postoperative radiographs in, 186, 187*f*
preoperative preparation for, 182
pseudoarthrosis in, 186–189, 189*t*
results of, 179*t*, 188
retroperitoneal approach in, 182
rod placement and derotation in, 184

Anterior surgery *(Continued)*
rotation methods in, 180
selection of fusion levels in, 181–182, 181*t*
spinal exposure in, 182–183
surgical approach in, 182
surgical technique of, 182–189
Texas Scottish Rite Hospital system of, 178
thoracoscopic, 208, 208*f*–209*f*
vertebral screw placement in, 184, 185*f*–186*f*
Zielke technique of, 178, 181, 188
for thoracolumbar kyphosis, post-traumatic, 264
Anteroposterior views
of complex deformities, 230
of infantile scoliosis, 115
of post-traumatic thoracolumbar deformity, 262
of spondylolisthesis, 250
Antibiotics, postoperative, 9
Anticoagulation, for DVT prophylaxis, 88–89
Antifibrinolytic agents, 23–24
Antilordotic lumbosacral brace, 272
Aorta
in pedicle screw fixation, 42–43, 43*f*
variants with spinal deformity, 42–43
Aortic stenosis
spinal pathology associated with, 90
spinal surgery in patients with, 89–90
Aortovertebral angle, 42
Apex of curve, 45, 46*f*
Apical vertebral rotation (AVR), 155–156. *See also* Bilateral apical vertebral derotation
Apical vertebral translation (AVT), 155
Aprotinin, 23–24
Arteria radicularis magna
in anterior thoracolumbar approach, 182
in Scheuermann's disease, 196
Asymmetric pedicle subtraction osteotomy, 244, 245*f*
Atelectasis, postoperative, 90
Athletic spondylolisthesis, 249
Autologous blood transfusion
blood salvage system for, 24
erythropoietin for priming, 23
postoperative reinfusion of salvaged blood, 24
predonation for, 23
Automatic Endoscopic System for Optimal Positioning (AESOP), 213
Autonomous robotic systems, 213
Awake fiberoptic-guided intubation, 20–21
Axial pain
with adult deformity, 3, 8
with coronal plane deformity, 66

B

Bacterial endocarditis prophylaxis, 90
Bat-ear deformity, with infantile scoliosis, 115
BAVD. *See* Bilateral apical vertebral derotation
Bending films, 8
of adolescent idiopathic scoliosis, 82
of adult scoliosis, 219
of congenital scoliosis, 103
of post-traumatic thoracolumbar deformity, 262
Bernstein anterior technique, 179*t*
Bilateral apical vertebral derotation (BAVD), 154, 164–167
case example of, 167, 169*f*
correcting rod placement in, 165, 166*f*
first maneuver in, 164–165, 165*f*
goal of, 164
postplacement correction after screw fixation, 164, 164*f*
results of, 165
second maneuver in, 165, 166*f*
second rod placement in, 165, 167*f*
Bipedal locomotion, 59–60
Bitan anterior technique, 178, 179*t*
Blakemore technique, for infantile scoliosis, 118*t*, 119
Blindness, postoperative, 25
Bloc vertebra, 101
Blood gas monitoring, 21
Blood loss
in adult scoliosis surgery, 227
minimization of, 22–24
antifibrinolytic agents for, 23–24
controlled hypotension for, 23
in osteotomies, 236–237
Blood pressure monitoring, 21
Blood salvage system, 24
Blood transfusion
allogeneic, minimization of, 22–24, 22*f*
autologous
blood salvage system for, 24
erythropoietin for priming, 23
postoperative reinfusion of salvaged blood, 24
predonation for, 23
Boachie-Adjei and Bradford vertebrectomy technique, 235
Bodily image
in adolescent idiopathic scoliosis, 94
in adult scoliosis, 221
Bolster films, of rigid kyphosis, 79, 81*f*
Bone density testing, 8, 91
Bone morphogenetic proteins (BMPs), 10
Boston brace, 272, 273*f*
for adolescent idiopathic scoliosis, 274
for neurogenic deformity, 275
Brachial plexus monitoring, 31, 33*f*
Bracing, 270–276
for adolescent idiopathic scoliosis, 272–274
in boys *versus* girls, 273–274
compliance with, 274
efficacy of brace types in, 273–274
indications for, 272–273
key points in, 274
for large curves, 273
nighttime, 273–274
non-rigid, 274
outcomes of, 273–274
for adult scoliosis, 219
biomechanical principles of, 271
for congenital scoliosis, 106
for connective tissue disorders, 275–276
for coronal deformity, 271
for infantile scoliosis, 116–117
for isthmic spondylolisthesis, 275
indications for, 275
key points in, 275
outcomes of, 275
limitations of, 271
for neuromuscular scoliosis, 129, 275
for paralytic and neurogenic deformity, 275
indications for, 275
outcomes for, 275
postoperative
in anterior thoracolumbar surgery, 187
in osteotomies, 237
in thoracic scoliosis surgery, 151
for sagittal deformity, 271
for Scheuermann's disease, 197–198, 203, 270, 274–275

indications for, 274
key points in, 275
outcomes of, 274
for spondylolisthesis, 255, 270
types of, 271–272
Breech presentation, and infantile scoliosis, 115
Briggs osteotomy, 231
Brodner anterior technique, 179*t*
Bullard laryngoscope, 21
Bullman anterior technique, 179*t*
Bupivacaine/opioid, for epidural analgesia, 26

C

Calcium channels, in neurophysiologic monitoring, 32
Calcium intake, 91
Campbell, Robert, 110
Cannulated screws, in thoracoscopic surgery, 207–208, 208*f*
Cardiopulmonary compromise, in infantile scoliosis, 114–115
Cardiovascular disease, spinal surgery in patients with, 89–90
C-arm fluoroscopy, *versus* fluoroscopy-based image-guided surgery, 210–211
Cash orthosis, for Scheuermann's disease, 203
Cast, for infantile scoliosis, 117
Cauda equina syndrome, 237, 249
Caudal foundation vertebra, 82
Celecoxib, perioperative use of, 26
Center sacral line, 5, 5*f*, 47, 61, 67–68, 68*f*, 155–156
Central venous pressure (CVP), 21
Cerebral palsy
bracing for, 275
neuromuscular scoliosis in, 130, 131*f*
Cerebrospinal fluid (CSF) leak, 10
Cervical kyphosis, 192–193
Cervical lordosis
age and, 60
normal, 61
Cervical spine surgery
intubation prior to, 20–21, 20*f*
preoperative evaluation for, 19–20, 19*f*
Charcot spine, 264
Charleston brace, 271, 271*f*
for adolescent idiopathic scoliosis, 274
Chest excursion, in infantile scoliosis, 115
Chronic obstructive pulmonary disease (COPD), spinal surgery in patients with, 90
Clavicle angle, 67
Clavicle positioning, 78
Closing wedge osteotomy, 232
Cobb angle, 12, 13*f*, 45, 60, 60*f*, 67
in infantile scoliosis, 115–116
in thoracic scoliosis, 144, 144*t*
Cobb method, of scoliosis measurement, 45, 46*f*
Combined anterior-posterior surgery. *See* Anterior-posterior surgery
Compensatory curve, 5, 6*f*
Complete spondyloptosis, 13
Complex deformities, 72–74, 230–237
characterization of, 230
imaging studies of, 230
multidisciplinary approach to, 230
multiplanar, 230
anterior/posterior vertebral osteotomies for, 72
classification of, 234
coronal balance in, 72–74, 234–236
hemivertebral resection for, 235–236
osteotomies for, 72, 73*f*–74*f*, 234–235
surgical treatment of, 72–74, 234–236
indications for, 234
techniques of, 234–236
type A, 234
type B, 234
vertebral column resection for, 72–74, 74*f*, 235–236, 236*f*
patient evaluation in, 230
preoperative planning in, 230
sagittal imbalance, 230–237
etiology of, 231
pedicle subtraction osteotomy for, 232–234, 233*f*
Smith-Petersen osteotomy for, 231–232, 232*f*–233*f*
surgical indications in, 231
surgical techniques for, 231–234
surgical treatment of, 230–237
complications of, 237
intraoperative management of, 235–236
outcomes of, 237
postoperative care in, 237
techniques of, 231–236
Complications, 9–10, 25. *See also specific procedures*
early, 10
late, 10
Compression fractures, osteoporotic vertebral, 91–92
Compression neurapraxia, 25
Computed tomographic myelogram, 8, 16, 17*f*
of adult scoliosis, 219
postoperative, 9
preoperative, for anterior-posterior approach, 173
Computed tomography, 14
advantages of, 12
of complex deformities, 230
evaluation/diagnostic, 77, 77*f*
for fusion assessment, 14
for image-guided surgery, 211–212
components of, 211
feature-based 2D-3D analysis in, 212
intensity-based 2D-3D analysis in, 212
registration in, 211–212
of kyphosis, 194
for pedicle screw fixation, 12, 14
of post-traumatic thoracolumbar deformity, 262
of traumatic deformity, 14, 15*f*
Computer-assisted surgery, 209–212
Computer-enhanced telemanipulators, 214
Concave rib osteotomies, 175
Congenital diaphragmatic hernia, with infantile scoliosis, 114
Congenital kyphosis, 192, 194
flexible *versus* fixed deformity in, 82–83
versus Scheuermann's disease, 196
treatment of, 83
Congenital scoliosis, 45, 101–112
anomalies associated with, 101–102
anterior-posterior arthrodesis for, 107–108, 108*f*–109*f*, 111
anterior-posterior hemiepiphysiodesis and hemiarthrodesis for, 108, 109*f*
classification of, 101
coronal balance in, 71–72
crankshafting phenomenon in, 107, 108*f*
curve progression in, 103
definition of, 101
differential growth in, 101, 102*f*
evaluation of, 101–103, 111
failures of formation, 101
failures of segmentation, 101
flexible *versus* fixed deformity in, 82–83

Congenital scoliosis *(Continued)*
fully segmented hemivertebra in, 101, 102*f*, 103, 104*f*
genetics of, 101
hemivertebra excision and fusion for, 72, 72*f*, 108–110, 110*f*, 235
incarcerated hemivertebra in, 101
magnetic resonance imaging of, 102–103, 103*f*–104*f*
mixed anomalies, 101
natural history of, 103, 111
nonoperative treatment of, 104–106
nonsegmented vertebra in, 101, 103
orthoses for, 106
pedicle screw fixation of, 110
periodic observation of, 104–106
posterior spinal arthrodesis for, 72, 106*f*–107*f*, 107
radiologic evaluation of, 103
semisegmented hemivertebra in, 101, 103, 105*f*
surgical treatment of, 71–72, 83, 106–112
fusion *versus* growth in, 112
hypotensive anesthesia avoided in, 107
neurophysiologic monitoring in, 107
paralysis risk in, 107
techniques of, 107–110
terminology in, 101
thoracic expansion surgery for, 83, 110–111, 111*f*
transpedicular approach in, 110
unilateral unsegmented bar in, 101, 102*f*, 103, 104*f*–105*f*
Connective tissue disorders, bracing for, 275–276
Conservative treatment, 8. *See also* Bracing; Observation
Console fusion technique, for spondylolisthesis, 255, 256*f*
Controlled hypotension, 23
Contusion, spinal cord, evoked potential changes with, 32
Corneal abrasion, 25
Coronal alignment, in scoliosis, measurement of, 45, 46*f*
Coronal balance, 66–74. *See also* Coronal plane deformity
Coronal decompensation, 5, 8
surgical treatment of, 230, 234–236
Coronal plane deformity, 3. *See also specific types of scoliosis*
in adolescent idiopathic scoliosis, 68–70, 82
in adult idiopathic scoliosis, 70–71
associated deformities with, 66
bracing for, 271
causes of, 66
clinical evaluation of, 66–67
in complex multiplanar deformities, 72–74, 234–236
in congenital scoliosis, 71–72
in degenerative scoliosis, 71
four-directional viewing of, 66–67
patient history in, 66
physical findings in, 66–67
post-traumatic thoracolumbar, 263, 267
principles of, 66–74
push-prone technique for, 67–68
radiographic evaluation of, 67–68, 68*f*
revision surgery for, 240, 244, 244*f*, 244*t*
surgical treatment of, 68–74, 230
Coronal plumb line, 5, 6*f*, 8, 66–67, 67*f*–68*f*
Coronary artery disease (CAD), spinal surgery in patients with, 89
Cortical burring, in pedicle screw fixation, 158, 159*f*
Corticospinal tract (CST), TceMEP mediation by, 30, 30*f*
Costovertebral angle, 39, 40*f*
Cotrel-Dubousset system, 217
for Scheuermann's disease, 198, 203
for thoracic scoliosis, 145, 154, 155*f*
Crankshafting phenomenon
in congenital scoliosis, 107, 108*f*
in infantile scoliosis, 117, 119
in neuromuscular scoliosis, 135*f*
in thoracic scoliosis, 145, 152
Critical care management, prolonged, 25–26
CT. *See* Computed tomography
CTLSO brace, for congenital scoliosis, 106
Curve(s)
in adolescent idiopathic scoliosis
double major, 47, 47*f*–48*f*, 48*t*, 49*f*, 51, 53*f*, 68–70, 68*f*
double thoracic, 47, 47*f*–48*f*, 48*t*, 51, 52*f*–53*f*
flexible *versus* fixed, 82–83
Lenke classification of, 46–47, 47*f*–48*f*, 48*t*, 49, 49*f*
main thoracic, 47, 47*f*–48*f*, 48*t*, 50–51, 50*f*–52*f*, 68–70, 68*f*
major, 47
minor, 47, 82
progression of, 95–97
structural *versus* nonstructural, 82
thoracolumbar/lumbar, 47, 47*f*–48*f*, 48*t*, 55, 55*f*–56*f*
thoracolumbar/lumbar-main thoracic, 47, 47*f*–48*f*, 48*t*, 55, 56*f*, 68–70, 68*f*
triple major, 47, 47*f*–48*f*, 48*t*, 51, 54*f*
in adult scoliosis
double thoracic, 70
lumbosacral fractional curves, 71
progression of, 218, 221
single thoracic, 70
thoracolumbar/lumbar, 70
apex of, 45, 46*f*
in congenital scoliosis, progression of, 103
in infantile scoliosis, progression of, 113, 116
progression of, 3, 8
radiographic measurement of, 45, 46*f*
in thoracic scoliosis, 155–156
double major, 144, 144*t*
double thoracic, 144, 144*t*, 155
main thoracic, 144, 144*t*
major, 144
minor, 144
proximal thoracic, 144–145, 144*t*, 156
single thoracic, 155
structural characteristics of, 144, 144*t*
thoracolumbar/lumbar, 144, 144*t*
thoracolumbar/lumbar-main thoracic, 144, 144*t*
triple major, 144, 144*t*
in thoracolumbar scoliosis, 222
Cyberknife, 213
Cyclooxygenase-2 inhibitors
perioperative use of, 26
postoperative use of, 92

D

da Vinci System, 213–215, 214*f*
Deep vein thrombosis, 9–10, 25
incidence of, 88
patients at high risk for, 88
patients at intermediate risk for, 88–89
patients at low risk for, 89
prophylaxis against, 88–89
ultrasound surveillance for, 89
Deformity. *See specific types*
Degenerative scoliosis, 217
conservative therapy for, 71
coronal balance in, 71
decompression for
with anterior-posterior fusion and posterior instrumentation, 71
with posterior fusion and instrumentation, 71
flexible *versus* fixed deformity in, 83–85
radiographic findings in, 71, 71*f*

sagittal balance in, 71
treatment of, 71
Degenerative spondylolisthesis, 249, 254
facet joint variants in, 41
Depression, in adolescent idiopathic scoliosis, 94
Derotation, bilateral. *See* Bilateral apical vertebral derotation
Desflurane, and evoked potentials, 34
Dextroscoliosis, 5, 6*f*
Direct laryngoscopy, unconscious, 21
Disk degeneration, magnetic resonance imaging of, 16, 17*f*
Diskectomy, in anterior approach, 174, 174*f*–175*f*, 184
Diskography, 12, 16
in adult scoliosis, 219, 220*f*
preoperative, for anterior-posterior approach, 173
Distal junctional kyphosis (DJK), 155–156
Double major curves
in adolescent idiopathic scoliosis, 47, 47*f*–48*f*, 48*t*, 49*f*
treatment of, 51, 53*f*, 68–70, 68*f*
in thoracic scoliosis, 144, 144*t*
Double thoracic curves
in adolescent idiopathic scoliosis, 47, 47*f*–48*f*, 48*t*
treatment of, 51, 52*f*–53*f*
in adult idiopathic scoliosis, treatment of, 70
in thoracic scoliosis, 144, 144*t*
Dowel graft, for spondylolisthesis, 255
Drummond wire fixation, 154
Dual-energy x-ray absorptiometry (DEXA), 8
Dual growing rod technique, for infantile scoliosis, 119–120, 120*f*–121*f*
Duchenne's muscular dystrophy, neuromuscular scoliosis in, 124, 129–130, 136
duPont brace, for Scheuermann's disease, 274
Dural tear, 10
D-waves, 30
anesthesia and, 33
Dwyer system, 178, 179*t*, 181, 188, 217, 231
Dynamic radiography, 12–14, 14*f*
Dynamic reference frame (DRF), in fluoroscopy-based image guidance, 210–211, 211*f*

E

Early detection, 270–271
Egg shell osteotomy, 85. *See also* Pedicle subtraction osteotomy
Ehlers-Danlos syndrome, 276
Electric stimulation, 10
for adolescent idiopathic scoliosis, 273–274
Electromyography (EMG), 29, 31
in adult scoliosis surgery, 227
anesthesia and, 34
changes in, pathophysiology of, 31–33
for pedicle screw fixation, 31, 32*f*, 33
in pedicle screw fixation, 161–163, 162*f*
spontaneous, 31
stimulus-evoked, 31
End fusion technique, for infantile scoliosis, 119
Endocarditis prophylaxis, 90
Endoscopic surgery. *See* Minimally invasive surgery
Endotracheal intubation, 20–21, 20*f*
End vertebra, 4, 4*f*, 45
End vertebra-to-end vertebra fusion, 181, 181*f*
Enteral nutrition, 9, 89
Epidural analgesia
perioperative, 26
side effects of, 26
Epidural injections, 8
Epsilon aminocaproic acid (EACA), 23–24
Erb point, 31
Erythropoietin (EPO), 23
Esmolol, for hypotension induction, 23
Evoked potentials, 21–22, 29–35. *See also* Motor evoked potentials; Somatosensory evoked potentials; Transcranial electric motor evoked potentials
amplitude of, 31
anesthesia and, 33–34
changes in, pathophysiology of, 31–33
latency of, 31
morphology (shape) of, 31
voltage of, 31
Exercises, 8
Expansion surgery, thoracic
for congenital scoliosis, 83, 110–111, 111*f*
for neuromuscular scoliosis, 130
Extension-based exercises, 8
Extracavitary approach, for thoracolumbar kyphosis, post-traumatic, 264
Eye injury, 25

F

Facet blocks, for adult scoliosis, 219
Facetectomy, in pedicle screw fixation, 157, 158*f*
Facet injections, 8
Facet joint(s), variants with spinal deformity, 41
Facet joint resection, for fixed deformities, 82
Familial dysautonomia, bracing for, 275
Feature-based 2D-3D analysis, CT-based image guidance, 212
Females, skeletal maturity in, 5
Fenoldopam, for hypotension induction, 23
Fentanyl, for awake fiberoptic-guided intubation, 21
Fiberoptic-guided intubation
awake, 20–21
unconscious, 21
Fixed-angle pedicle screws, 161
Flat-back deformity, 3, 7, 62, 62*f*, 217, 231
causes of, 62
global (type II), 85
segmental (type I), 85
surgical correction of, 62, 85
symptoms of, 7
Flexible *versus* fixed deformities, 76–85
adult, 76–77, 83–85
and anterior-posterior approach, 171
fulcrum-bending films of, 79
global assessment of, 77–78
in kyphosis, 79, 82–83, 194
pediatric and adolescent, 76, 79–83
push-prone radiograph of, 79
radiologic evaluation of, 78–79
in Scheuermann's disease, 79, 83, 195
surgical decision-making in, 77–78, 82
traction films of, 79, 80*f*
Flexion-based exercises, 8
Fluoroscopy, 17
for image-guided surgery, 17, 210–211
advantages of, 211
components of, 210
dynamic reference frame in, 210–211, 210*f*
mathematical model in, 210–211
positioning and draping in, 210, 211*f*
Foot sweating, differential postoperative, 189, 189*f*
Free-hand anatomic technique, of pedicle screw fixation, 155
F-response, 31
anesthesia and, 34
spinal shock and, 33
Friedreich's ataxia, neuromuscular scoliosis in, 124, 130

Fulcrum-bending films
of congenital scoliosis, 103
of flexible *versus* fixed deformities, 79
preoperative, for anterior-posterior approach, 173
Full-length films, preoperative, for anterior-posterior approach, 173
Fully segmented hemivertebra, 101, 102*f*, 103, 104*f*
Fusion. *See also specific procedures and deformities*
adjuncts to, 10
assessment of
computed tomography for, 14
plain film for, 14, 15*f*
failed, 9–10
successful, gold standard for, 9

G

Gaines vertebral bone-on-bone fusion, 179
Gait, 59
Galveston technique, 226
Gearshift probing, in pedicle screw fixation, 158–159, 159*f*
General medical issues, 88–92
Genetic counseling, 270
Genitourinary anomalies, with congenital scoliosis, 102
Glycopyrrolate, for awake fiberoptic-guided intubation, 20–21
Gravity line, in spondylolisthesis, 250–253
Growing rod technique
for infantile scoliosis, 119–120, 120*f*–121*f*
for neuromuscular scoliosis, 130
Growth spurt, and progression of adolescent idiopathic scoliosis, 95, 95*t*

H

Hall anterior technique, 178
Hall-Relton frame, 25
Halm and Zielke anterior technique, 178
Halo-femoral traction, vertebral column resection with, 235
Halo-gravity traction, for neuromuscular scoliosis, 83
Harms, Jürgen, 144
Harrington Rod Instrumentation System, 154
Harrington system
for adult scoliosis, 217, 221, 227
for anterior thoracolumbar surgery, 178
for sagittal deformity, 231
for Scheuermann's disease, 198
Head
assessment, in infantile scoliosis, 115
positioning in space, 60
Head of rib phase, 116, 116*f*
Heart disease, spinal surgery in patients with, 89–90
Hehne osteotomy, 231
Heinig osteotomy, 232
Hemiepiphysiodesis
for congenital scoliosis, 108, 109*f*
for infantile scoliosis, 117–118
Hemimetameric shift, 101
Hemivertebra
in congenital scoliosis, 101, 103
fully segmented, 101, 102*f*, 103, 104*f*
incarcerated, 101
nonsegmented, 101, 103
semisegmented, 101, 103, 105*f*
Hemivertebral excision (resection)
anterior-posterior approach in, 235
for congenital scoliosis, 72, 72*f*, 108–110, 110*f*, 235
for multiplanar deformities, 235–236
posterior approach in, 235–236
Hippocrates, 3
Hodgson anterior approach, 182
Horner's syndrome, epidural analgesia and, 26
H-reflex, 31
anesthesia and, 34
spinal shock and, 33
Hypotension
controlled, 23
neurophysiologic monitoring in, 34–35
Hypotensive anesthesia, 23
avoidance of, in congenital scoliosis, 107

I

Idiopathic scoliosis. *See also* Adolescent idiopathic scoliosis; Adult idiopathic scoliosis
age-based classification of, 113
development of, 94
term, application of, 94
Image-guided surgery, 12, 209–212
CT-based, 211–212
fluoroscopy-based, 17, 210–211
Imaging, 12–17. *See also specific modalities and images*
clinical and financial costs of, 17
evaluation/diagnostic, 8, 77
postoperative, 9
sequence for ordering, 17
Implant failure or pullout
and post-traumatic thoracolumbar deformity, 264
revision surgery for, 240, 246, 247*t*
Incarcerated hemivertebra, 101
Infantile scoliosis, 45, 94, 113–120
abdominal reflexes in, 115
Akbarnia technique for, 118*t*, 119
anatomic and physiologic variants of, 114–115
anterior-posterior fusion for, 117
Blakemore technique for, 118*t*, 119
in boys *versus* girls, 113, 115
breech presentation and, 115
challenges in treatment, 119–120
chest excursion in, 115
clinical evaluation of, 115
Cobb angle in, 115–116
definition of, 113
end fusion technique for, 119
etiologies of, 113
in Europe *versus* North America, 114
fusionless approaches in, 118–119
genetics of, 114
growing rod technique for, 119–120, 120*f*–121*f*
head assessment in, 115
hemiepiphysiodesis for, 117–118
incidence of, 113–114
intrauterine molding and, 114
Klemme technique for, 118, 118*t*
Luque technique for, 118–119, 118*t*
magnetic resonance imaging of, 115, 117
maternal age and, 114
Moe technique for, 118, 118*f*
natural history of, 113–114
nonoperative treatment of, 116–117
phase of rib head in, 116, 116*f*
posterior fusion for, 117
postnatal pressure theory of, 114
progression of, 113, 116
pulmonary development and function in, 114–115
radiologic evaluation of, 115–116
rib-vertebral angle difference of Mehta in, 116, 116*f*
sleep position and, 114

spontaneous resolution of, 113, 116
submuscular rod placement for, 119
surgical treatment of, 117–120
comparison of techniques, 118*t*
goal of, 117
growth preservation in, 118–120
minimally invasive, 117–118
patient age and, 117
techniques of, 117–120
traction for, 117
Infection, revision surgery for, 240, 245–246, 246*t*
Inferior vena cava (IVC) filter, 89
Inhalational anesthesia, and evoked potentials, 34
Injections, therapeutic, 8
Intensity-based 2D-3D analysis, CT-based image guidance, 212
Intervertebral angle, relationship with other parameters, 62
Intraocular pressure, patient positioning and, 25
Intraoperative cell salvage (ICS), 24, 227
Intraoperative imaging, 12, 209–212
CT-based, 211–212
fluoroscopy-based, 17, 210–211
Intraoperative neurophysiologic monitoring (IONM), 21–22, 29–35
in adult scoliosis surgery, 227
anesthesia and, 33–34
changes in, pathophysiology of, 31–33
in congenital scoliosis surgery, 107
in osteotomies, 236
in Scheuermann's disease surgery, 203
as standard of care, 29
techniques of, 29–31
in thoracolumbar scoliosis surgery, 182
in thoracoscopic surgery, 207
Intrauterine molding, and infantile scoliosis, 114
Intubating laryngeal mask airway, 21
Intubation, 20–21
awake fiberoptic-guided, 20–21
prolonged, 25–26
unconscious fiberoptic-guided, 21
Ionizing radiation exposure, 13–14, 16
and kyphosis, 271–272
IONM. *See* Intraoperative neurophysiologic monitoring
IPC (intermittent pneumatic compression), 88
Ischemia, spinal cord, 34–35
evoked potential changes with, 32–33
Isoflurane, 22
and evoked potentials, 34
Isthmic spondylolisthesis
bracing for, 275
indications for, 275
key points in, 275
outcomes of, 275
facet joint variants in, 41
observation of, 275
spinous process variants in, 40–41
vertebral body variants in, 39, 39*f*

J

Jackson surgery table, 24, 182
Jewett hyperextension brace, 271–272
Johnston anterior technique, 179*t*
Jump position, 61
Junctional kyphosis, 10, 155–156, 222, 222*f*
Juvenile scoliosis, 45, 94

K

Kaneda anterior scoliosis system (KASS), 178, 179*t*, 181, 184
Ketorolac, perioperative use of, 26
King classification, of adolescent idiopathic scoliosis, 45–46, 50, 82
Klemme technique, for infantile scoliosis, 118, 118*t*
Knee-chest position, 24
Kyphectomy, for myelokyphosis, 136
Kyphoplasty, for osteoporotic compression fractures, 91–92
Kyphoscoliosis, flexible *versus* fixed deformity in, 79
Kyphosis, 192–194
age and, 59–61
at birth, 192–193, 193*f*
cervical, 192–193
congenital, 82–83, 192, 194
definition of, 3, 192
development of, 59
flexible *versus* fixed deformity in, 79, 82–83, 194
imaging of, 194
junctional, 10, 155–156, 222, 222*f*
measurement of, 60, 60*f*
with myelomeningocele, 136–142, 141*f*–142*f*
normal, 45, 61, 192–193
in osteoporosis, 91–92
pathomechanics of deformities, 193–194, 194*f*
postirradiation, 270–271
postlaminectomy, 270–271
progressive postoperative, in thoracic scoliosis, 152
relationship with other parameters, 62
rigid, bolster films of, 79, 81*f*
Scheuermann's, 192–204. *See also* Scheuermann's disease
thoracic, 45, 60–62, 192–193
thoracolumbar, 192
post-traumatic, 263–264, 265*f*–267*f*, 271
treatment principles in, 192

L

La Chapelle osteotomy, 231
Laminectomy, kyphosis after, 270–271
Laryngeal mask airway, intubating, 21
Laryngoscopy
blade options in, 21
unconscious direct, 21
Latency, of evoked potentials, 31
anesthesia and, 33–34
changes in, pathophysiology of, 31–33
10 percent prolongation rule for, 32
Lateral bending views, 8
of adult scoliosis, 219
of post-traumatic thoracolumbar deformity, 262
Lateral cutaneous femoral nerve injury, 25
Lateral decubitus position, 24
Lateral flexion and extension views, 8
of adult scoliosis, 219
of complex deformities, 230
of post-traumatic thoracolumbar deformity, 262
Lateral views, 8
of adult scoliosis, 219
of complex deformities, 230
of congenital scoliosis, 103
of flexible *versus* fixed deformities, 78–79
of infantile scoliosis, 115
of post-traumatic thoracolumbar deformity, 262
of Scheuermann's disease, 195*f*, 196
of spondylolisthesis, 250
Latitudinal growth, 253
Learning curve for surgeons
in spinal deformity surgery, 10–11
in thoracoscopic procedures, 151–152, 206
Leg lengths, sensation of unequal, 66

Lenke classification
of adolescent idiopathic scoliosis, 46–57, 82, 181*t*
benefit of, 55
curve type in, 46–47, 47*f*–48*f*, 48*t*, 49, 49*f*
goals of, 46, 57
lumbar spine modifier in, 46–47, 47*f*, 49*f*
reliability of, 49–50
sagittal thoracic modifier in, 46, 47*f*, 49, 50*f*
treatment directed by, 50–55, 181–182
triad of components in, 46, 49
of adult idiopathic scoliosis, 70–71
of thoracic scoliosis, 144–145, 144*t*, 155–156
Levoscoliosis, 5, 6*f*
Lichtblau and Wilson osteotomy, 230
Lidocaine, for awake fiberoptic-guided intubation, 21
Ligamentous injury, dynamic radiography of, 13–14, 14*f*
Lighted Intubating Stylet (LIS), 21
Light wand device, for intubation, 21
Longitudinal growth, 253
Long posterior fusion, for neuromuscular scoliosis, 130, 131*f*
Lordosis
age and, 59–61
development of, 59
excessive compensatory, 61
measurement of, 60, 60*f*
normal, 61
pelvic shape and, 62
post-traumatic thoracolumbar, 263
surgical treatment of, 267
reduced, 61
relationship with other parameters, 62
Lowe anterior technique, 179*t*
Lowest instrumented vertebra (LVI), 145, 156, 179, 201
Low-molecular-weight heparin, for DVT prophylaxis, 88–89
Lumbar curves, classification of, 222
Lumbar lordosis
age and, 60–61
excessive compensatory, 61
normal, 61
pelvic shape and, 62
reduced, 61
relationship with other parameters, 62
Lumbar Scheuermann's disease, 196, 197*f*
Lumbar scoliosis. *See also* Thoracolumbar scoliosis
adult, surgical treatment of, 222–226
anterior surgery for, 178–189, 222–223
Lumbar spine modifier, in Lenke scoliosis classification, 46–47, 47*f*, 49*f*
Lumbosacral brace, antilordotic, 272
Lumbosacral fixation, 224–226, 226*f*
Lumbosacral fractional curve, 67, 67*f*
in adolescent idiopathic scoliosis, 180
in adult idiopathic scoliosis, 71
Lumbosacral junction, spondylolisthesis of, 249
Lung function
in adolescent idiopathic scoliosis, 26, 94
in adult idiopathic scoliosis, 8
in infantile scoliosis, 114–115
pedicle screw fixation and, 154
in thoracic scoliosis, postoperative, 152
Luque-Galveston technique, 224
for neuromuscular scoliosis, 83, 134*f*
Luque technique, for infantile scoliosis, 118–119, 118*t*
Luque trolley, 118–119
Luque vertebrectomy technique, 235
Luque wire fixation, 154, 217

M

Macintosh laryngoscope, 21
Magnetic resonance imaging (MRI), 15–16
of adult scoliosis, 219
advantages of, 12
atypical symptoms in, 15
of complex deformities, 230
of congenital scoliosis, 102–103, 103*f*–104*f*
of disk degeneration, 16, 17*f*
evaluation/diagnostic, 8, 77, 78*f*
indications for, 15, 15*f*
of infantile scoliosis, 115, 117
of kyphosis, 194
postoperative, 9
of post-traumatic thoracolumbar deformity, 262
preoperative, for anterior-posterior approach, 173
of Scheuermann's disease, 196
soft tissue assessment with, 15, 16*f*
of spondylolisthesis, 250
Main thoracic curves
in adolescent idiopathic scoliosis, 47, 47*f*–48*f*, 48*t*
anterior approach to, 51, 52*f*
posterior approach to, 50, 50*f*–51*f*
selective thoracic fusion for, 68–70
treatment of, 50–51, 68–70, 68*f*
in thoracic scoliosis, 144, 144*t*
Majd anterior technique, 179*t*
Major curves
in adolescent idiopathic scoliosis, 47
in thoracic scoliosis, 144
Males, skeletal maturity in, 5
Marchetti-Bartolozzi classification, of spondylolisthesis, 249, 249*t*
Marfan's syndrome
bracing for deformities in, 275–276
spinal surgery in patient with, 90
Maturity, skeletal, 5
McCoy laryngoscope, 21
Mean arterial blood pressure (MAP), evoked potential changes with, 32–35, 35*f*
Median nerve stimulation, for SSEP monitoring, 29
Medical issues, general, 88–92
Mehta, Min, 76
Mehta's rib-vertebral angle difference, 116, 116*f*
Menarche, and progression of adolescent idiopathic scoliosis, 95–96
MEPs. *See* Motor evoked potentials
Meralgia paresthetica, 25
Metabolic bone disorders of spine, 91–92
Meyerding grading system, of spondylolisthesis, 13, 253
Michelle and Krudger osteotomy, 232
Midazolam, for awake fiberoptic-guided intubation, 21
Miller laryngoscope, 21
Milwaukee brace, 272, 272*f*
for adolescent idiopathic scoliosis, 274
for congenital scoliosis, 106
for infantile scoliosis, 117
for Scheuermann's disease, 197, 274
Minimally invasive surgery, 10, 206–209. *See also* Thoracoscopic surgery
advances in, 206
benefits of, 206, 209–210
challenges of, 216
for fixed deformities, 82
future directions in, 215–216
learning curve for, 151–152, 206
retractors for, 208
robotics in, 212–215

for Scheuermann's disease, 198, 199*f*
technical costs of, 210
for thoracic scoliosis, 148–152
for thoracolumbar deformity, 208
Minor curves
in adolescent idiopathic scoliosis, 47, 82
in thoracic scoliosis, 144
Mitral stenosis, spinal surgery in patients with, 90
Moe technique
for infantile scoliosis, 118, 118*t*
for thoracolumbar and lumbar scoliosis, 178, 179*t*
Monoaxial pedicle screws, 161
Morphine, perioperative use of, 26
Morphology (shape), of evoked potentials, 31
changes in, pathophysiology of, 31–33
Moskowitz anterior technique, 179*t*
Motion-sparing constructs, 10, 41
Motor evoked potentials (MEPs), 21–22
in adult scoliosis surgery, 227
in congenital scoliosis surgery, 107
neurogenic, 21, 31
in thoracolumbar scoliosis surgery, 182
in thoracoscopic surgery, 207
transcranial electric, 29–30, 30*f*
anesthesia and, 33–34
for brachial plexus monitoring, 31
changes in, pathophysiology of, 31–33
H-reflex and F-response with, 31, 33
mean arterial pressure and, 34–35, 35*f*
in Scheuermann's disease, 203
MRI. *See* Magnetic resonance imaging
Multiaxial pedicle screws, 161
Multiplanar deformities, 230
anterior/posterior vertebral osteotomies for, 72
classification of, 234
coronal balance in, 72–74, 234–236
hemivertebral resection for, 235–236
osteotomies for, 72, 73*f*–74*f*, 234–235
surgical treatment of, 72–74, 234–236
indications for, 234
techniques of, 234–236
type A, 234
type B, 234
vertebral column resection for, 72–74, 74*f*, 234–236, 236*f*
Myelography, 16, 17*f*
of adult scoliosis, 219
computed tomography with, 8–9, 16, 17*f*, 173, 219
evaluation/diagnostic, 8
postoperative, 9
preoperative, for anterior-posterior approach, 173
Myelokyphosis, 136–142, 141*f*–142*f*
Myelomeningocele
bracing for, 275
kyphotic deformity with, 136–142, 141*f*–142*f*
neuromuscular scoliosis with, 126*f*, 133*f*, 136–142, 139*f*–140*f*
anterior-posterior fusion for, 136, 139*f*
instrumentation problems in, 136, 140*f*
short anterior fusion for, 133*f*, 136
prevention and early detection of, 270

N

Narcotics, postoperative use of, 92
Nash-Moe rotation method, 180
National Aeronautics and Space Administration Smart Probe project, 215
Neck posture, and intubation, 20
Neo-Synephrine, for awake fiberoptic-guided intubation, 21
Nerve root blocks, 8
Nerve root injury, evoked potential changes with, 33
Neurogenic deformity, bracing for, 275
Neurogenic descending evoked potentials, 31
Neurogenic motor evoked potentials (NMEPs), 21, 31
Neuromuscular blockade, and evoked potentials, 34
Neuromuscular scoliosis, 45, 124–142
acquired, 124–129
bracing for, 129, 275
contraindications to, 129
patient weight and, 129
successful, 129
with cerebral palsy, 130, 131*f*
classification of, 124–129
developmental, 124–129
with Duchenne's muscular dystrophy, 124, 129–130, 136
etiology of, 124
flexible *versus* fixed deformity in, 82–83
functional impairment in, 124, 129*f*
fusionless approaches for, 130
growing rod technique for, 130
halo-gravity traction for, 83
long posterior fusion and instrumentation for, 130, 131*f*
Luque-Galveston technique for, 83, 134*f*
muscle weakness/flaccidity in, 124, 125*f*
with myelomeningocele, 126*f*, 133*f*, 136–142, 139*f*–140*f*
nonoperative treatment of, 129
pelvic fixation in, 130, 134*f*
pelvic obliquity in, 83, 125*f*, 130, 131*f*, 134*f*
with polio, 124, 125*f*
revision surgery in, 130, 135*f*
sagittal plane deformity in, 83, 124, 128*f*
short anterior fusion and instrumentation for, 130, 132*f*–133*f*, 136
with spinal cord injury, 124, 127*f*, 132*f*, 136, 137*f*–138*f*
surgical treatment of, 130–142
fusion *versus* ambulatory function in, 130–136
fusion *versus* growth (height) in, 130, 136
techniques of, 130–142
vertebral abnormalities in, 124, 126*f*
vertebral stapling for, 130
vertical expandable prosthetic titanium rib for, 130
Neurophysiologic monitoring, 21–22, 29–35
in adult scoliosis surgery, 227
anesthesia and, 33–34
changes in, pathophysiology of, 31–33
in congenital scoliosis surgery, 107
in osteotomies, 236
in Scheuermann's disease surgery, 203
as standard of care, 29
techniques of, 29–31
in thoracolumbar scoliosis surgery, 182
in thoracoscopic surgery, 207
Neutral vertebra, 4, 5*f*, 68
Newman-Wise classification, of spondylolisthesis, 249
Newton, Betz, Clements technique, for thoracic scoliosis, 148
Nicardipine, for hypotension induction, 23
Nighttime bracing, for adolescent idiopathic scoliosis, 273–274
Nitroglycerin, for hypotension induction, 23
Nitrous oxide, 22
and evoked potentials, 34
Nonoperative treatment, 270–276. *See also specific methods and deformities*
goals of, 270
indications for, 270
Nonsegemented hemivertebra, 101, 103

Nonsteroidal anti-inflammatory drugs
avoidance of, postoperative, 9
perioperative use of, 26
postoperative use of, 92
Nonstructural curve, 5, 6*f*
Nutrition, 9, 89, 219, 237, 240, 268

O

Obese patients, 88, 219
Oblique spinal takeoff, 180, 226
Oblique views, of spondylolisthesis, 250
Observation
of adolescent idiopathic scoliosis, 272–273
of congenital scoliosis, 104–106
of infantile scoliosis, 116
of Scheuermann's disease, 198
of spondylolisthesis, 255, 275
Ogiela anterior technique, 179*t*
Opioids, postoperative use of, 26, 92
Orthoses, 270–276
for adolescent idiopathic scoliosis, 272–274
in boys *versus* girls, 273–274
compliance with, 274
efficacy of brace types in, 273–274
indications for, 272–273
key points in, 274
for large curves, 273
nighttime, 273–274
non-rigid, 274
outcomes of, 273–274
for adult scoliosis, 219
biomechanical principles of, 271
for congenital scoliosis, 106
for connective tissue disorders, 275–276
for coronal deformity, 271
for infantile scoliosis, 116–117
for isthmic spondylolisthesis, 275
indications for, 275
key points in, 275
outcomes of, 275
limitations of, 271
for neuromuscular scoliosis, 129, 275
for paralytic and neurogenic deformity, 275
indications for, 275
outcomes for, 275
postoperative
in anterior thoracolumbar surgery, 187
in osteotomies, 237
in thoracic scoliosis surgery, 151
for sagittal deformity, 271
for Scheuermann's disease, 197–198, 203, 270, 274–275
indications for, 274
key points in, 275
outcomes of, 274
for spondylolisthesis, 255, 270
types of, 271–272
Osteoporosis, 91–92
definition of, 91
kyphosis in, 91–92
metabolic workup in, 91
morbidity and mortality in, 91
risk factors for, 91
scoliosis in, 91–92
secondary, 91
severe, 91
spinal surgery in patients with, 91–92
treatment of, 91
vertebral compression fractures in, 91–92
Osteotomy(ies)
in anterior approach, 174–175, 174*f*–175*f*
blood loss in, 236–237
for complex deformities, 72, 230–237
complications of, 237
concave rib, 175–176
history of, 230
intraoperative management of, 236–237
multiple, for multiplanar deformities, 234–235
neurophysiologic monitoring in, 236
nutritional concerns in, 237
outcomes of, 236
pedicle subtraction
amount of correction in, 233
asymmetric, 244, 245*f*
closure in, 233*f*
for combined imbalance, in revision surgery, 244, 245*f*
for complex deformities, 72, 73*f*–74*f*, 232–234
extension of, 233–234
interbody fusion with, 234
for marked degeneration proximal to fusion, 246, 247*f*
medial pedicle preservation in, 234
patient positioning for, 233
placement and level of, 233
problems with, 243
for revision surgery, 226–227
for sagittal plane deformity, 62, 63*f*, 85, 232–234, 233*f*
in revision surgery, 226–227, 240, 242–243, 242*f*–243*f*
for Scheuermann's disease, 198–200
transpedicular fixation with, 233–234
polysegmental, for sagittal plane deformity, 85, 231
postoperative orthoses with, 237
same day *versus* staged, 237
Smith-Petersen, 230
anterior diskectomies and fusion with, 232, 232*f*–233*f*
for complex deformities, 231–232
multiple, problem with, 243, 243*f*
patient positioning for, 231
polysegmental *versus* monosegmental, 231
for pseudoarthrosis, 244–245
for revision surgery, 226–227
for sagittal plane deformity, 62, 63*f*, 85, 231–232, 232*f*–233*f*
in revision surgery, 226–227, 240–242, 241*f*–242*f*
for Scheuermann's disease, 198–200, 200*f*–202*f*
V-shaped resection in, 231–232, 232*f*
Ouellet anterior technique, 179*t*
Outcome measures, 9
for adult scoliosis, 218–219
Overcorrection, 10

P

Pain
with adult deformity, 3, 8, 217–219, 221, 228
with post-traumatic thoracolumbar deformity, 262
with Scheuermann's disease, 195–196
with spondylolisthesis, 254
Pain management
perioperative techniques for, 26
preexisting, in surgical patients, 92
Paralytic deformity, bracing for, 275
Paralytic scoliosis. *See* Neuromuscular scoliosis
Pare, Ambroise, 3
Parenteral nutrition, 89, 237, 240, 268

Pars, in spondylolisthesis
elongation of, 249, 250*f*, 253
lysis of, 249
repair of, 255
Patient-controlled analgesia (PCA), 9, 26, 92
Patient-controlled epidural analgesia (PCEA), 26
Patient history, 7–8
Patient positioning, 24–25. *See also specific procedures*
Pediatric deformity. *See also specific types*
versus adult, 76–77
flexible *versus* fixed, 76, 79–83
Pediatric patients, anesthesia in, 26
Pedicle(s), variants with spinal deformity, 39–40, 40*f*
Pedicle-rib complex, 40
Pedicle screw fixation, 10
of adolescent idiopathic scoliosis, 82, 154
of adult scoliosis, 222, 222*f*
aorta in, 42–43, 43*f*
computed tomographic guidance for, 12, 14
of congenital scoliosis, 110
electromyographic monitoring for, 31, 32*f*, 33
of fixed deformities, 82
of infantile scoliosis, 119
with osteotomy, 233–234, 237
of Scheuermann's disease, 83, 201, 201*f*–202*f*
thoracic and lumbar, 154–169
benefits of, 154
bilateral apical vertebral derotation with, 154, 163–167
complications of, 154
confirmation of interosseous screw in, 161–163, 162*f*
cortical burring in, 158, 159*f*
electromyography in, 161–163, 162*f*
facetectomy in, 157, 158*f*
free-hand anatomic technique of, 155–163
gearshift probing in, 158–159, 159*f*
incision and exposure in, 157, 157*f*
palpation in, 159–160, 160*f*
pedicle length measurement in, 160, 161*f*
plain films in, 161, 162*f*
posterior surgery for, 154–169
pulmonary effects of, 154
repalpation in, 160, 161*f*
rod contouring in, 163
screw placement in, 160–161, 162*f*
starting point in, 157–158, 158*f*
tapping in, 160, 161*f*
Pedicle subtraction osteotomy (PSO)
amount of correction in, 233
asymmetric, 244, 245*f*
closure in, 233*f*
for combined imbalance, in revision surgery, 244, 245*f*
for complex deformities, 72, 73*f*–74*f*, 232–234
extension of, 233–234
interbody fusion with, 234
for marked degeneration proximal to fusion, 246, 247*f*
medial pedicle preservation in, 234
patient positioning for, 233
placement and level of, 233
problems with, 243
for sagittal plane deformity, 62, 63*f*, 85, 232–234, 233*f*
in revision surgery, 226–227, 240, 242–243, 242*f*–243*f*
for Scheuermann's disease, 198–200
transpedicular fixation with, 233–234
Pelvic fixation
in adult scoliosis, 226, 226*f*
in neuromuscular scoliosis, 130, 131*f*, 134*f*
Pelvic incidence, 61, 251, 253*f*
in spondylolisthesis, 250–251
Pelvic inclination, 61
Pelvic obliquity, 61–65, 61*f*, 67
in adult scoliosis, 219
in neuromuscular scoliosis, 83, 125*f*, 130, 131*f*, 134*f*
opposite, 130
regular, 130
Pelvic shape, 251
and lumbar lordosis, 62
Pelvic tilt, 61–65, 251, 253*f*
Pelvic vertebra, 130
Perdriolle rotation method, 180
Perioperative pain management, 26
Peripheral venous pressure (PVP), 21
Peroneal nerve stimulation, for SSEP monitoring, 29–30
Phase of rib head, 116, 116*f*
Physical examination, 7–8
Physical therapy
postoperative, 9
as treatment, 8
Picetti technique, for thoracic scoliosis, 148–149
Plagiocephaly, with infantile scoliosis, 115
Plain films, 13–14
of adolescent idiopathic scoliosis, 179
of adult scoliosis, 219
of congenital scoliosis, 103
evaluation/diagnostic, 8
of flexible *versus* fixed deformities, 78–79
for fusion assessment, 14, 15*f*
of infantile scoliosis, 115–116
in pedicle screw fixation, 161, 162*f*
postoperative, 9, 14, 15*f*
of post-traumatic thoracolumbar deformity, 262
radiation exposure from, 13–14
of Scheuermann's disease, 195*f*, 196
of scoliosis, 12*f*, 13
of spondylolisthesis, 13, 13*f*, 250, 250*f*
of traumatic deformity, 13–14
Player piano model, of robotics, 215
Plumb lines, 5, 6*f*, 8
coronal, 5, 8, 66–67, 67*f*–68*f*
sagittal, 5, 6*f*, 59, 230, 262
Pneumonia, postoperative, 90
Point-based registration, 211–212
Point P, in adolescent idiopathic scoliosis, 95
Point R, in adolescent idiopathic scoliosis, 95
Polio, neuromuscular scoliosis in, 124, 125*f*
Polymethylmethacrylate (PMMA), for osteoporotic compression fractures, 91
Polysegmental osteotomy, for sagittal plane deformity, 85, 231
Ponte technique, for Scheuermann's disease, 200, 200*f*
Positioning of patient, 24–25. *See also specific procedures*
Posterior surgery
for adolescent idiopathic scoliosis, 50, 51*f*–52*f*, 69, 82–83. *See also specific anatomic locations*
for adult scoliosis, 221–222, 226
advances in and evolution of, 154
versus anterior, 156, 180
bilateral apical vertebral derotation in, 154, 164–167
case example of, 167, 169*f*
correcting rod placement in, 165, 166*f*
first maneuver in, 164–165, 165*f*
goal of, 164
postplacement correction after screw fixation, 164, 164*f*
results of, 165

Posterior surgery *(Continued)*
second maneuver in, 165, 166*f*
second rod placement in, 165, 167*f*
for complex severe multiplanar deformities, 72–74, 73*f*–74*f*
for hemivertebral resection, 235–236
for lumbosacral fixation, 226
pedicle screw fixation in, 154–169
benefits of, 154
complications of, 154
confirmation of interosseous screw in, 161–163, 162*f*
cortical burring in, 158, 159*f*
electromyography in, 161–163, 162*f*
facetectomy in, 157, 158*f*
free-hand anatomic technique of, 155–163
gearshift probing in, 158–159, 159*f*
incision and exposure in, 157, 157*f*
palpation in, 159–160, 160*f*
pedicle length measurement in, 160, 161*f*
plain films in, 161, 162*f*
repalpation in, 160, 161*f*
rod contouring in, 163
screw placement in, 160–161, 162*f*
starting point in, 157–158, 158*f*
tapping in, 160, 161*f*
for pseudoarthrosis, 244–245
for Scheuermann's disease, 83, 198–203
for selective thoracic fusion, 69
for thoracic scoliosis, 154–169
correction maneuvers in, 163–167
indications for, 155
perioperative complications of, 148
postoperative management in, 167
selection of fusion levels in, 155–156
techniques of, 156–167
for thoracolumbar kyphosis, post-traumatic, 264
Posterior tibial nerve stimulation, for SSEP monitoring, 29–30, 30*f*
Posterior vertebral column resection
for complex multiplanar deformities, 74, 235–236, 236*f*
patient positioning for, 236
results of, 236
technique of, 236, 236*f*
Posteroanterior views, 8
of adolescent idiopathic scoliosis, 179
of adult scoliosis, 219
of congenital scoliosis, 103
of flexible *versus* fixed deformities, 78–79
Posterolateral approach, for thoracolumbar kyphosis, post-traumatic, 264
Postnatal pressure theory, of infantile scoliosis, 114
Postoperative care, 9. *See also specific procedures*
Postoperative visual loss (PVL), 25
Post-traumatic thoracolumbar deformity, 261–268
anatomy of, 261–262
biomechanics of, 262–263
causes of, 263–264
challenge of, 261
Charcot spine and, 264
classification of, 263
clinical presentation of, 262
combined, 263
coronal plane, 263, 267
cystic lesions with, 262
epidemiology of, 261
goal of treatment, 261
hardware failure and, 264
incidence of, 261
instability and, 263–264
kyphotic, 263, 271
surgical treatment of, 264, 265*f*–267*f*
lordotic, 263
surgical treatment of, 267
neurologic deficit with, 262
nutritional concerns in, 268
pseudoarthrosis and, 264
radiographic evaluation of, 262
sagittal plane, 262–263
scoliotic, 263
surgical treatment of, 267
surgical treatment of, 264–268
complications of, 268
outcomes of, 267–268
techniques of, 264–267
translational, 263
surgical treatment of, 267
Postural round back, 192, 196
Posture, 59. *See also specific aspects of*
Potassium channels, in neurophysiologic monitoring, 32
Predonation (PD) of blood, 23
Preoperative evaluation, 19–20, 19*f*
Prevention, 270–271
Progression of curves, 3, 8
in adolescent idiopathic scoliosis
age and, 95–96
curve magnitude and, 95–96, 95*t*
curve pattern and, 95–96
growth spurt and, 95, 95*t*
incidence of, 95, 95*t*
menarche and, 95–96
postskeletal maturity, 96–97
preskeletal maturity, 95–96
Risser sign and, 95–96, 95*t*
sex (gender) and, 95–96
in adult scoliosis, 218, 221
in congenital scoliosis, 103
in infantile scoliosis, 113, 116
Prolonged critical care management, 25–26
Prone position, 24
for anterior-posterior minimally invasive surgery, 208–209
and intraocular pressure, 25
Propofol, 22
Proximal thoracic curve, in thoracic scoliosis, 144–145, 144*t*, 156
Pseudoarthrosis, 9–10
in anterior thoracolumbar surgery, 186–189, 189*t*
in anterior thoracoscopic surgery, 151, 151*f*
in fusions to sacrum, 224–226
in osteotomies, 236
and post-traumatic thoracolumbar deformity, 264
revision surgery for, 240, 244–245, 245*t*
Smith-Petersen osteotomy for, 244–245
in vertebral column resection, 236
Pseudo-Scheuermann's disease, 196, 197*f*
PSO. *See* Pedicle subtraction osteotomy
Psoas muscle, in anterior thoracolumbar approach, 183
Pulmonary disease, spinal surgery in patient with, 90–91
Pulmonary edema, acute postoperative, 90–91
Pulmonary embolus, 9–10
Pulmonary function
in adolescent idiopathic scoliosis, 26, 94
in adult idiopathic scoliosis, 8
in infantile scoliosis, 114–115
pedicle screw fixation and, 154
in thoracic scoliosis, postoperative, 152
Pulmonary hypoplasia, in infantile scoliosis, 114

Puno anterior technique, 179*t*
Push-prone technique
for adolescent scoliosis assessment, 179
for adult scoliosis, 219
for coronal balance assessment, 67–68
for flexible *versus* fixed deformities, 79

Q

Quality of life, in adult scoliosis, 218, 228
Quality of recovery, from anesthesia, 27

R

Radiation exposure, 13–14, 16
and kyphosis, 270–271
Radicular pain, with adult deformity, 3, 8, 219
Radiography. *See also specific types*
dynamic, 12–14, 14*f*
evaluation/diagnostic, 8
postoperative, 9
Recovery from anesthesia, 27
Regional analgesia, perioperative, 26
Registration, in CT-based image guidance, 211–212
Remifentanil, 22
for hypotension induction, 23
Results, 9–10. *See also specific procedures*
Retroperitoneal anterior approach, 173, 182
Reverse Trendelenburg position, 24
Revision surgery, adult, 226–227, 240–247
for combined imbalance, 240, 244, 245*f*, 245*t*
for coronal imbalance, 240, 244, 244*f*, 244*t*
for implant failure or pullout, 240, 246, 247*t*
for infection, 240, 245–246, 246*t*
for marked degeneration distal to fusion, 240, 246, 246*t*
for marked degeneration proximal to fusion, 240, 246, 247*f*, 247*t*
nutritional concerns in, 240
for pseudoarthrosis, 240, 244–245, 245*t*
reasons for, 240
for sagittal imbalance, 240–243, 244*t*
pedicle subtraction osteotomy in, 240, 242–243, 242*f*–243*f*
Smith-Petersen osteotomy in, 240–242, 241*f*–242*f*
staged *versus* one-day, 240
Rheumatoid arthritis
airway management in patients with, 21
aortic insufficiency with, 90
Rib(s), variants with spinal deformity, 39, 40*f*
Rib humps, 39, 219
Rib-vertebral angle difference of Mehta, 116, 116*f*
Risser sign, and progression in adolescent idiopathic scoliosis, 95–96, 95*t*
ROBODOC, 213
Robotics, 212–215
advantages of, 215
autonomous systems, 213
future directions in, 215–216
haptic feedback with, 215
interaction with surgeon, 213
intuitive control with, 215
player piano model of, 215
proportional movement with, 215
safety envelope with, 215
surgical-assist devices, 213–214
3D vision system in, 215
true force reflection with, 215
Rofecoxib, perioperative use of, 26
Ropivacaine, for epidural analgesia, 26
Round back, postural, 192, 196

S

Sacral inclination, 60–61, 60*f*
Sacral shape, 253
in spondylolisthesis, 250, 251*f*
Sacral slope, 61, 61*f*, 251, 253*f*
relationship with other parameters, 62
Sacropelvic constructs, 226, 226*f*
Sacrum, fusions to, 225–226
challenge of, 224
distal stopping point for, 226
pseudoarthrosis in, 224–226
Sagittal balance, 59–65, 192–194, 193*f*. *See also* Sagittal plane deformity
adult curves in, 192
age and, 59–61
definition of, 59, 59*f*, 60–61
development of, 59
pelvic shape and, 62
radiographic assessment of, 60, 60*f*
relationship of parameters in, 62
restoration of, 62–65
variations in, 250–253, 252*f*
Sagittal decompensation, 5, 7–8, 10
surgical treatment of, 230–234
Sagittal plane deformity, 3, 192–194, 230–234
in adolescent idiopathic scoliosis, 82
in adult scoliosis, 217
bracing for, 271
causes of, 62
classification of, 231
in degenerative scoliosis, 71
etiology of, 231
flexible *versus* fixed, 79–83, 85
measurement of, 45, 46*f*
in neuromuscular scoliosis, 83, 124, 128*f*
osteotomies for, 62–63, 231–234
calculations for, 62, 64*f*
pedicle subtraction, 62, 63*f*, 85, 232–234, 233*f*, 240, 242–243, 242*f*–243*f*
polysegmental, 85
Smith-Petersen, 62, 63*f*, 85, 231–232, 232*f*–233*f*, 240–242, 241*f*–242*f*
post-traumatic thoracolumbar, 262–264
principles of, 59–65
progressive postoperative, in thoracic scoliosis, 152
radiographic assessment of, 60, 60*f*
revision surgery for, 226–227, 240–243, 241*f*–243*f*, 244*t*
surgical treatment of, 62–65, 85, 230–234
complications of, 62
goal of, 231
indications for, 231
techniques of, 62, 231–234
type I, 231
type II, 231
vertebral column resection for, 84*f*, 85
Sagittal plumb line, 5, 6*f*, 59, 230, 262
Sagittal thoracic modifier, in Lenke scoliosis classification, 46, 47*f*, 49, 50*f*
Sagittal vertical axis, 192, 230, 251–253
Salvage system for blood, 24
Scheuermann's disease, 38–39, 192–204
age at presentation, 195
anterior surgery for, 198, 199*f*, 203
bracing for, 197–198, 203, 270, 274–275
indications for, 274
key points in, 275
outcomes of, 274

Scheuermann's disease *(Continued)*
cartilaginous theory of (Schmorl's), 195
clinical findings in, 195–196
versus congenital kyphosis, 196
differential diagnosis of, 196
etiology of, 195
exercises for, 197–198
flexible *versus* fixed deformity in, 79, 83, 195
genetics of, 195
incidence of, 195
instrumentation systems for, 200–203, 200*f*
lowest instrumented vertebra in, 201
lumbar, 196, 197*f*
mechanical theories of, 195
natural history of, 195–197
neurologic symptoms of, 196
nonoperative treatment of, 195, 197–198
pain with, 195–196
pathogenesis of, 195
pathognomonic signs of, 194
pedicle screw fixation in, 83, 198–200, 201*f*–202*f*
pedicle subtraction osteotomy for, 198–200
Ponte technique for, 200, 200*f*
posterior column shortening for, 198–200
posterior surgery for, 83, 198–203
radiographic findings in, 39, 194, 195*f*, 196
Schmorl's nodes in, 39, 194, 195*f*, 196
segmental vessel variants in, 43
Smith-Petersen osteotomy for, 198–200, 201*f*–202*f*
spinal cord variants in, 42, 42*f*
surgical treatment of, 83, 198–204
complications of, 203
goals of, 204
indications for, 198
neurophysiologic monitoring in, 203
results of, 203
selection of fusion levels in, 203
thoracoscopic surgery for, 198, 199*f*
type II, 196, 197*f*
vascular compromise in, 196
vertebral body changes in, 38–39, 39*f*, 194, 195*f*
Schmorl's nodes, 39, 194, 195*f*, 196
School screening, 270
Scoliosis. *See also* Adolescent idiopathic scoliosis; Adult idiopathic scoliosis; Adult scoliosis; Congenital scoliosis; Degenerative scoliosis; Infantile scoliosis; Neuromuscular scoliosis
adolescent, 45
adult, 45, 217–228
anatomical variants in
aorta, 42–43, 43*f*
facet joint, 41
pedicle, 39–40, 40*f*
ribs, 39, 40*f*
segmental vessels, 43
spinal cord, 42, 42*f*
spinous process variants in, 41, 41*f*
vertebral body, 39
classification of
age-based, 45
etiologic, 45
radiographic measurements for, 45, 46*f*
Cobb angle in, 12, 13*f*
congenital, 45, 101–112
costovertebral angle in, 39, 40*f*
definition of, 3, 26
evaluation of, 26
Harrington on, 3
Hippocrates on, 3
idiopathic, 45
infantile, 45, 113–120
juvenile, 45
Moe and Lonstein on, 3
neuromuscular, 45, 124–142
in osteoporosis, 91–92
Pare on, 3
plain film of, 12*f*, 13
progression of, 3, 8
pulmonary function in, 8, 26
syndrome-related, 45
thoracic, 144–152
Weinstein and Ponseti on, 3
Scoliosis Research Society, 3
classification system of, 45
outcome measure of, 9, 218–219
Segmental artery, in anterior thoracolumbar approach, 182
Segmental vessels
in osteotomies, 237
in posterior vertebral column resection, 236
in thoracoscopic surgery, 207, 207*f*
variants with spinal deformity, 43, 43*f*
Selective thoracic fusion, 155–156
for adolescent idiopathic scoliosis, 68–70
anterior approach in, 69–70
posterior approach in, 69
preoperative planning for, 70
results of, 69–70
Semisegmented hemivertebra, 101
Sensory evoked potentials (SEPs), 21–22
Sevoflurane, and evoked potentials, 34
Sex (gender), and progression of adolescent idiopathic scoliosis, 95–96
SF-36 outcome measure, 9, 218–219, 228
Shear stress, and spondylolisthesis, 250, 253–254, 254*f*
Shock, spinal, evoked potential changes with, 33
Short anterior fusion, 178
for neuromuscular scoliosis, 130, 132*f*–133*f*, 136
Shoulder balance, 66–67
Side-bending films
of adolescent idiopathic scoliosis, 179
of thoracic scoliosis, 144, 144*t*
Single thoracic curves, 155
in adult idiopathic scoliosis, treatment of, 70
Sitting, neuromuscular scoliosis and, 124, 129*f*
Skeletal maturity, 5
Sleep position, of infantile scoliosis, 114
Smart Probe project (NASA), 215
Smith-Petersen osteotomy, 230
anterior diskectomies and fusion with, 232, 232*f*–233*f*
for complex deformities, 231–232
patient positioning for, 231
polysegmental *versus* monosegmental, 231
problem with, 72, 243, 243*f*
for pseudoarthrosis, 244–245
for sagittal plane deformity, 62, 63*f*, 85, 231–232, 232*f*–233*f*
in revision surgery, 226–227, 240–242, 241*f*–242*f*
for Scheuermann's disease, 198–200, 200*f*–202*f*
V-shaped resection in, 231–232, 232*f*
Smoking
and osteoporosis, 91
and surgical results, 8, 10, 20, 90
Sodium channels, in neurophysiologic monitoring, 32
Sodium nitroprusside (SNP), for hypotension induction, 23
Soft tissue, magnetic resonance imaging of, 15, 16*f*

Somatosensory evoked potentials (SSEPs), 21–22, 29–30, 30*f*
in adult scoliosis surgery, 227
anesthesia and, 33–34
for brachial plexus monitoring, 31, 33*f*
changes in, pathophysiology of, 31–33
lower extremity, 29
in osteotomies, 236
in Scheuermann's disease, 203
10 percent latency prolongation rule for, 32
in thoracolumbar scoliosis surgery, 182
in thoracoscopic surgery, 207
upper extremity, 29
Spinal cord
in Scheuermann's disease, 42, 42*f*
in scoliosis, 42, 42*f*
variants with spinal deformity, 41–42
Spinal cord blood flow (SCBF), 34
Spinal cord contusion, evoked potential changes with, 32
Spinal cord injury
bracing for, 275
neuromuscular scoliosis with, 124, 127*f*, 132*f*, 136, 137*f*–138*f*
osteotomies and, 237
Spinal cord ischemia, 34–35
evoked potential changes with, 32–33
Spinal deformity. *See also specific entries*
adult *versus* adolescent, 3–4
anatomical variants with, 38–43
conservative treatment of, 8
correction, goals of, 7, 7*f*
evaluation of, 7–8
flexible *versus* fixed, 76–85
prevention and early detection of, 270–271
terms and principles of, 4–7
Spinal deformity surgery. *See also specific procedures and deformities*
adult, indications for, 8
advances in, 76
anesthesia in, 19–27
complications of, 9–10, 25
computer-assisted, 209–212
future developments in, 10
general medical issues in, 88–92
goals of, 3–4, 11, 76
image-guided, 12, 209–212
intubation prior to, 20–21, 20*f*
learning curve for, 10–11
patient positioning for, 24
results of, 9–10
robotics in, 212–215
technological advances in, 206–216
Spinal shock, evoked potential changes with, 33
Spinal shortening, for rigid deformities, 175
Spine-Cor brace, 274
Spinous process(es)
in idiopathic scoliosis, 41, 41*f*
in isthmic spondylolisthesis, 40–41
variants with spinal deformity, 40–41
Spinous process angle, 41
Spondylolisthesis, 249–258
acquired, 249, 249*t*, 254, 258
age of patient with, 250
anatomy of, 250–253, 252*f*–253*f*
athletic, 249
biomechanics of, 253, 254*f*
bracing for, 255, 270
classification of, 249, 249*t*
console fusion technique for, 255, 256*f*
definition of, 249
degenerative, 249, 254
facet joint variants in, 41
degree of slip in, 253
developmental, 249, 249*t*, 254
diagnosis of, 250
dowel graft for, 255
with elongation of pars, 249, 250*f*, 253
etiology of, 250
fusion in situ for, 255, 255*f*
grading systems for, 13, 253
gravity line in, 250–253
high-dysplasia, 249, 254, 258
isthmic
bracing for, 275
facet joint variants in, 41
spinous process variants in, 40–41
vertebral body variants in, 39, 39*f*
low-dysplasia, 249, 254, 258
with lysis of pars, 249
magnetic resonance imaging of, 250
most common location of, 249
natural history of, 254
nonoperative treatment of, 255
observation of, 255, 275
pain generators in, 254
pars repair for, 255
pathologic, 254
pathology of, 249
pelvic incidence in, 250–251, 253*f*
plain film of, 13, 13*f*, 250, 250*f*
postsurgical, 249, 254
progression of, 249, 253
reduction and anterior-posterior fusion for, 255–256, 257*f*–258*f*
sacral shape in, 250, 251*f*
shear stress and, 250, 253–254, 254*f*
spinal shortening for, 256, 258*f*
stance in, 250–253
surgical treatment of, 255–256
goals of, 255
indications for, 255
traumatic, 254
Spondyloptosis, complete, 13
Spontaneous electromyography (spEMG), 31
in osteotomies, 236
Spot lateral view, of spondylolisthesis, 250
SSEPs. *See* Somatosensory evoked potentials
Stable vertebra, 5, 5*f*, 68
Stagnara's drawing, of sagittal variations, 251, 252*f*
Stagnara wake-up test, 21–22, 29, 182
Stance, in spondylolisthesis, 250–253
Stimulus-evoked electromyography, 31
Stretch films, of adolescent idiopathic scoliosis, 179
Submuscular fixation, of infantile scoliosis, 119
Suk method, for thoracic scoliosis, 145
Superior mesenteric artery, in vertebral column resection, 237
Surface-based registration, 211–212
Surgery. *See also specific procedures and deformities*
adult, indications for, 8
advances in, 76
anesthesia in, 19–27
complications of, 9–10, 25
computer-assisted, 209–212
future developments in, 10
general medical issues in, 88–92
goals of, 3–4, 11, 76
image-guided, 12, 209–212

Surgery *(Continued)*
intubation prior to, 20–21, 20*f*
learning curve for, 10–11
patient positioning for, 24
results of, 9–10
robotics in, 212–215
technological advances in, 206–216
Surgical-assist devices, robotic, 213–214
Sweating, differential foot, 189, 189*f*
Sweet anterior technique, 179*t*
Sympathetic chain, in anterior thoracolumbar approach, 183
Syndrome-related scoliosis, 45

T

TceMEPs. *See* Transcranial electric motor evoked potentials
Technological advances, 206–216
Teleoperators, 213–215
Telesurgery, 215
10 percent latency prolongation rule, 32
Texas Scottish Rite Hospital (TSRH) system, 178
Thomasen osteotomy, 232
Thoracic expansion surgery
for congenital scoliosis, 83, 110–111, 111*f*
for neuromuscular scoliosis, 130
Thoracic fusion, selective, 155–156
for adolescent idiopathic scoliosis, 68–70
Thoracic kyphosis, 45, 192–193
age and, 60–61
normal, 61
relationship with other parameters, 62
in Scheuermann's disease, 194–204. *See also* Scheuermann's disease
Thoracic scoliosis
adult, surgical treatment of, 221–222
anterior surgery for, 144–152
contraindications to, 145
indications for, 145
lower instrumented vertebra in, 145
minimally invasive, 148–152
open, 145–148
indications for, 145
perioperative complications of, 148
results of, 145–148
progressive sagittal kyphosis after, 152
pulmonary improvements with, 152
saving of fusion levels in, 145, 146*f*–147*f*, 152
spontaneous correction of lumbar curve in, 152
techniques of, 145–152
thoracoscopic, 148–152
bone graft in, 150
contraindications to, 149
disk annulus and end plate removal in, 148
diskectomy and release in, 150
flexibility obtained in, 148
indications for, 149, 149*f*
internal thoracoplasty in, 150
learning curve for, 151–152
Newton, Betz, Clements technique of, 148
patient positioning for, 149–150
Picetti technique of, 148–149
postoperative care in, 151
pseudoarthrosis prevention in, 151, 151*f*
results of, 151–152
screw-rod construct in, 150–151
surgical technique in, 149–151
bilateral apical vertebral derotation for, 154, 164–167
case example of, 167, 169*f*
correcting rod placement in, 165, 166*f*
first maneuver in, 164–165, 165*f*
goal of, 164
postplacement correction after screw fixation, 164, 164*f*
results of, 165
second maneuver in, 165, 166*f*
second rod placement in, 165, 167*f*
classification of, 144–145
Lenke system of, 144–145, 144*t*, 155–156
Cobb angle in, 144
correction maneuvers for, 163–167
Cotrel-Dubousset system for, 145, 154, 155*f*
double major curves in, 144, 144*t*
double thoracic curves in, 144, 144*t*, 155
main thoracic curves in, 144, 144*t*
major curves in, 144
minor curves in, 144
pedicle screw fixation for, 154–169
benefits of, 154
complications of, 154
confirmation of interosseous screw in, 161–163, 162*f*
cortical burring in, 158, 159*f*
electromyography in, 161–163, 162*f*
facetectomy in, 157, 158*f*
free-hand anatomic technique of, 155–163
gearshift probing in, 158–159, 159*f*
incision and exposure in, 157, 157*f*
palpation in, 159–160, 160*f*
pedicle length measurement in, 160, 161*f*
plain films in, 161, 162*f*
repalpation in, 160, 161*f*
rod contouring in, 163
screw placement in, 160–161, 162*f*
starting point in, 157–158, 158*f*
tapping in, 160, 161*f*
posterior surgery for, 154–169
versus anterior, 156
indications for, 155
perioperative complications of, 148
postoperative management in, 167
selection of fusion levels in, 155–156
techniques of, 156–167
proximal thoracic curves in, 144–145, 144*t*, 156
side-bending films of, 144, 144*t*
single thoracic curves in, 155
structural characteristics of curves in, 144, 144*t*
Suk technique for, 145
surgical indications in, 155
thoracolumbar/lumbar curves in, 144, 144*t*
thoracolumbar/lumbar-main thoracic curves in, 144, 144*t*
triple major curves in, 144, 144*t*
Thoracoabdominal approach, 173–174, 182
Thoracolumbar kyphosis, 192
post-traumatic, 263, 271
surgical treatment of, 264, 265*f*–267*f*
in Scheuermann's disease, 194–204. *See also* Scheuermann's disease
Thoracolumbar/lumbar curves
in adolescent idiopathic scoliosis, 47, 47*f*–48*f*, 48*t*
treatment of, 55, 55*f*–56*f*
in adult idiopathic scoliosis, treatment of, 70
in thoracic scoliosis, 144, 144*t*
Thoracolumbar/lumbar-main thoracic curves
in adolescent idiopathic scoliosis, 47, 47*f*–48*f*, 48*t*
treatment of, 55, 56*f*, 68–70, 68*f*
in thoracic scoliosis, 144, 144*t*

Thoracolumbar scoliosis
adult
anterior-posterior technique for, 223–224, 225*f*
anterior technique for, 222–223, 223*f*–224*f*
classification of curves in, 222
fusions to sacrum in, 225–226
pelvic fixation in, 226, 226*f*
posterior technique for, 222
surgical treatment of, 222–226
anterior surgery for, 178–189
Bitan technique of, 178, 179*t*
bone grafting in, 184–185
closure in, 185–186
comparison of techniques, 179*t*
complications of, 188–189, 189*t*
convex rod compression in, 185–186
curve correction *versus* mobility preservation in, 181
differential foot sweating after, 189, 189*f*
disk space preparation in, 184
dual solid-rod system in, 182, 184, 188
Dwyer technique of, 178, 179*t*, 181, 188
end vertebra-to-end vertebra fusion in, 181, 181*f*
follow-up in, 186–188
Hall technique of, 178
Halm and Zielke technique of, 178
Harrington technique of, 178
implant failure in, 186–189, 189*f*
incision in, 182, 183*f*
indications for, 180
instrumentation avoidance at L4 or below, 180
intervertebral spaces in, 184–185
Kaneda system for, 178, 179*t*, 181, 184
Moe technique of, 178, 179*t*
neurophysiologic monitoring in, 182
patient positioning for, 182, 183*f*
postoperative bracing in, 187
postoperative management in, 186–189
postoperative physical therapy in, 188
postoperative radiographs in, 186, 187*f*
preoperative preparation for, 182
pseudoarthrosis in, 186–189, 189*t*
results of, 179*t*, 188
retroperitoneal approach in, 182
rod placement and derotation in, 184
rotation methods in, 180
selection of fusion levels in, 181–182, 181*t*
spinal exposure in, 182–183
surgical approach in, 182
surgical technique of, 182–189
Texas Scottish Rite Hospital system of, 178
vertebral screw placement in, 184, 185*f*–186*f*
Zielke technique of, 178, 181, 188
post-traumatic, 263
surgical treatment of, 267
thoracoscopic surgery for, 208, 208*f*–209*f*
Thoracolumbar trauma, deformity after, 261–268
anatomy of, 261–262
biomechanics of, 262–263
causes of, 263–264
challenge of, 261
Charcot spine and, 264
classification of, 263
clinical presentation of, 262
combined, 263
coronal plane, 263, 267
cystic lesions with, 262
epidemiology of, 261
goal of treatment, 261
hardware failure and, 264
incidence of, 261
instability and, 263–264
kyphotic, 263, 271
surgical treatment of, 264, 265*f*–267*f*
lordotic, 263
surgical treatment of, 267
neurologic deficit with, 262
nutritional concerns in, 268
pseudoarthrosis and, 264
radiographic evaluation of, 262
sagittal plane, 262–263
scoliotic, 263
surgical treatment of, 267
surgical treatment of, 264–268
complications of, 268
outcomes of, 267–268
techniques of, 264–267
translational, 263
surgical treatment of, 267
Thoracolumbosacral orthosis (TLSO), 9
for adolescent idiopathic scoliosis, 274
for congenital scoliosis, 106
postoperative
in osteotomies, 237
in thoracic scoliosis surgery, 151
for Scheuermann's disease, 197, 203
Thoracoplasty
for adult scoliosis, 221
in anterior approach, 175
in posterior approach, 176
Thoracoscopic surgery, anterior
results of, 209, 209*f*–210*f*
for Scheuermann's disease, 198, 199*f*
for thoracic scoliosis, 148–152, 206–208
bone graft in, 150
cannulated screws in, 207–208, 208*f*
closure in, 208
contraindications to, 149, 206
disk annulus and end plate removal in, 148
diskectomy and release in, 150
flexibility obtained in, 148
indications for, 149, 149*f*, 206
instrumentation placement in, 150–151, 207–208, 208*f*
internal thoracoplasty in, 150
learning curve for, 151–152, 206
neurophysiologic monitoring in, 207
Newton, Betz, Clements technique of, 148
operating room setup for, 207, 207*f*
patient positioning for, 149–150, 207, 207*f*
Picetti technique of, 148–149
postoperative care in, 151
pseudoarthrosis prevention in, 151, 151*f*
results of, 151–152
screw-rod construct in, 150–151, 207–208, 208*f*
segmental vessels in, 207, 207*f*
surgeon positioning for, 207
surgical considerations in, 206
surgical technique in, 149–151, 207–208
for thoracolumbar deformity, 208, 208*f*–209*f*
Thoracotomy, for anterior approach, 173
Thromboembolic precautions, 9, 24–25, 88–89
Torticollis, with infantile scoliosis, 115
Total intravenous anesthesia (TIVA), 22, 30*f*, 34
Total parenteral nutrition, 89, 237
Trachlight, 21

Traction, for infantile scoliosis, 117
Traction films
  of adolescent idiopathic scoliosis, 179
  of adult scoliosis, 219
  of congenital scoliosis, 103
  for flexible *versus* fixed deformities, 79, 80*f*
Tranexamic acid, 23–24
Transcranial electric motor evoked potentials (TceMEPs), 29–30, 30*f*
  anesthesia and, 33–34
  for brachial plexus monitoring, 31
  changes in, pathophysiology of, 31–33
  H-reflex and F-response with, 31, 33
  mean arterial pressure and, 34–35, 35*f*
  in Scheuermann's disease, 203
Translational deformity, post-traumatic thoracolumbar, 263
  surgical treatment of, 267
Traumatic deformity
  computed tomography of, 14, 15*f*
  plain film of, 13–14
  thoracolumbar, 261–268. *See also* Post-traumatic thoracolumbar deformity
Traumatic spondylolisthesis, 254
Trimetaphan, for hypotension induction, 23
Triple major curves
  in adolescent idiopathic scoliosis, 47, 47*f*–48*f*, 48*t*
    treatment of, 51, 54*f*
  in thoracic scoliosis, 144, 144*t*
Truncal balance, 66–74. *See also* Coronal balance; Coronal plane deformity
Turi anterior technique, 179*t*
2D-3D analysis, in CT-based image guidance, 212

U

Ulnar nerve monitoring, 31, 33*f*
Ulnar nerve stimulation, for SSEP monitoring, 29
Ultrasound
  for DVT surveillance, 89
  venous, postoperative, 25
Unconscious fiberoptic-guided intubation, 21
Unilateral unsegmented bar, in congenital scoliosis, 101, 102*f*, 103, 104*f*–105*f*

V

Valvular heart disease, spinal surgery in patients with, 89–90
Venography, postoperative, 25
Ventrale derotations-spondylodese techniques, 178
Vertebral body(ies)
  in idiopathic scoliosis, 39
  in isthmic spondylolisthesis, 39, 39*f*
  in Scheuermann's disease, 38–39, 38*f*, 194, 195*f*
  variants with spinal deformity, 38–39
Vertebral column resection
  anterior-posterior approach in, 235
  for complex multiplanar deformities, 72–74, 74*f*, 234–235
  complications of, 237
  with halo-femoral traction, 235
  indications for, 235
  intraoperative management of, 236–237
  number of vertebra resected in, 235
  posterior, 74, 235–236, 236*f*
  postoperative care in, 236–237
  for rigid deformities, 175
  for sagittal plane deformity, 84*f*, 85
  for spondylolisthesis, 256
  staged, 235
  technique of, 235
Vertebral compression fractures, osteoporotic, 91–92
Vertebral growth, 253
Vertebral stapling, for neuromuscular scoliosis, 130
Vertebral wedging angle, relationship with other parameters, 62
Vertebrectomy. *See* Vertebral column resection
Vertebroplasty, for osteoporotic compression fractures, 91
Vertical expandable prosthetic titanium rib (VEPTR)
  for congenital scoliosis, 83, 110–111, 111*f*
  for neuromuscular scoliosis, 130
Visual loss, postoperative, 25
Vitamin D intake, 91
Volatile anesthesia, and evoked potentials, 34
Voltage, of evoked potentials, 31
  changes in, pathophysiology of, 31–33

W

Wake-up test, 21–22, 29, 236
Wedge osteotomy, 230, 232
Wedging of vertebral bodies, in Scheuermann's disease, 38–39, 38*f*, 194, 195*f*
Wilmington brace, 271, 272*f*
Wilson frame, 24
Wire fixation, 154, 171
Wisconsin wiring technique, 154
Wojcik anterior technique, 179*t*
Wolff's law, 195
Wound healing, nutrition and, 89
Wound infection, 10

X

X-rays. *See* Plain films

Z

Zeus System, 213–214
Zielke, Klaus, 144, 178
Zielke system, 178, 181, 188, 217, 231