

# Postoperative Management Protocol for Incidental Dural Tears During Degenerative Lumbar Spine Surgery

## A Review of 3,183 Consecutive Degenerative Lumbar Cases

Mustafa H. Khan, MD,\* Jeffery Rihn, MD,\* Garen Steele, MD,\* Rick Davis, MD,†  
William F. Donaldson, III, MD,\* James D. Kang, MD,\* and Joon Y. Lee, MD\*

### Study Design. Retrospective review.

**Objectives.** To review the experience of a single institution with degenerative lumbar surgery and to identify cases of incidental dural tears (DTs); and to report on the efficacy of our postoperative management protocol for DT, which relies on early mobilization.

**Summary of Background Data.** DTs are a common complication of degenerative lumbar spine surgery. However, the management strategies for this complication vary from one surgeon to another.

**Methods.** A total of 3,183 degenerative lumbar spine cases (decompression and/or fusion) were reviewed. Cases complicated by an incidental DT were identified. Patients who required a return to the operating room for a second procedure were identified and the operative findings were reviewed.

**Results.** The incidence of DT during primary lumbar surgeries was 7.6% (153 of 2,024 cases), which compares to an incidence of 15.9% for revision cases (185 of 1,159 cases). If recognized during the index procedure, all DTs were repaired using a 4-0 silk suture. Six patients (4 primary, 2 revisions) who did not improve despite our postoperative management protocol were taken to the operating room for irrigation and debridement, repair of the defect, and placement of a subfascial drain to closed suction. All 6 patients went on to do well and did not have any further complications.

**Conclusions.** DTs are common during degenerative lumbar spine surgery. Revision surgery is twice as likely as primary surgery to result in this complication. Our postoperative early mobilization protocol appears to be an effective and safe management strategy for treating this complication (98.2% success rate). Very few patients (6 of 338, or 1.8%) needed a reoperation.

**Key words:** dural tear, degenerative lumbar surgery, repair, reoperation, complication. **Spine 2006;31:2609–2613**

Although dural tears (DTs) are a known potential intraoperative complication of spine surgery, there is a relative lack of information about the true incidence of this common occurrence. Most of the studies in the literature are based on experience with relatively small numbers of

patients.<sup>1–5</sup> Its reported incidence has varied from 1.8% to as high as 17.4%, with a wide variability of patient characteristics and surgical procedures.<sup>2,6</sup> Unrecognized or unrepaired DT can result in continued cerebrospinal fluid (CSF) leak during the postoperative period.

Given this paucity of information in the literature, the incidence of DT needs to be studied in specific patient populations, such as those undergoing lumbar decompression and/or fusion for degenerative disease. Also, appropriate postoperative strategies for managing this complication need to be outlined. As is true for most of what has been presented in the literature about DT, the small numbers of patients in these disparate series do not suggest an easy, reliable, and effective clinically applicable postoperative management algorithm for treating DT.

This study had two specific aims: 1) to review a single institution experience with DT over a 10-year period, and 2) to report on the efficacy of a DT postoperative management protocol for DT developed at our institution, which relies on early mobilization. To our knowledge, this paper provides data on the largest series of patients with DT in the literature.

### Materials and Methods

**Study Design and Patient Population.** This study is a retrospective review of a single institution with lumbar surgery over a period of 10 years. Guidelines for inclusion in the study included those patients who had undergone lumbar decompression and/or fusion with or without instrumentation for degenerative lumbar disease. Trauma patients were excluded from this study. Thus, a total of 3,183 patients (47.9% male, 52.1% female) were included in the study (Table 1). All patients who had an intraoperative DT had the defect repaired at the time of surgery with a 4-0 silk suture using a running locking stitch. A subfascial drain was placed in patients who sustained a DT that was repaired. No other adjunct materials for repair, such as collagen matrix sheet or a tissue sealant, was used in this cohort during the index procedure. Tissue sealant was used only in cases where a repeat surgery for irrigation and debridement revealed a persistent leak with a Valsalva maneuver.

From the \*Department of Orthopedic Surgery, University of Pittsburgh, Pittsburgh, PA; and †Vanderbilt University, Nashville, TN. Acknowledgment date: October 31, 2005. Acceptance date: January 6, 2006.

The manuscript submitted does not contain information about medical device(s)/drug(s).

No funds were received in support of this work. No benefits in any form have been or will be received from a commercial party related directly or indirectly to the subject of this manuscript.

Address correspondence and reprint requests to Joon Y. Lee, MD, Division of Spinal Surgery, Department of Orthopedic Surgery, University of Pittsburgh Medical Center, 3741 Fifth Avenue, Suite 1010, Pittsburgh, PA 15213; E-mail: joonyunglee@yahoo.com

**Table 1. Type of Surgery (primary vs. revision) and Incidence of Dural Tears**

	No. of Patients	No. of Patients With Dural Tears	Dural Tear Incidence (%)
Primary surgeries	2024	153	7.6
Revision surgeries	1159	185	15.9
Total	3183	338	10.6

**Table 2. Demographic and Surgical Details for Patients Who Required a Second Procedure for a Symptomatic Dural Tear**

Patient No.	Age (yr)	Gender	Primary/Revision	Diagnosis	Procedure	DT Noted Intraoperatively?
1	51	Female	Revision	Pseudoarthrosis + flatback syndrome, s/p instrumented PSF L1–L5	ASF L2–L5 + L1–S1 days/c with instrumented PSF + ICBG	No
2	51	Female	Revision	s/p L4–S1 fusion; adjacent level stenosis, claudication	L3–L4 days/c with instrumented PSF + ICBG	Yes, -punctate dural holes from previous epidural injections at L3–L4 junction; repaired w/4-0 silk; no leak with VM
3	71	Female	Primary	L3–L5 stenosis, claudication	L3–L5 days/c with instrumented PSF + ICBG	Yes, 2 mm DT at R-L3–L4 subarticular recess; repaired with 4-0 silk; no leak with VM
4	78	Female	Primary	L4–L5 stenosis with degenerative spondylolisthesis	L3–L5 days/c with instrumented PSF + ICBG	Yes, 2 mm DT at L4–L5; no leak with VM
5	66	Female	Primary	L4–L5 stenosis with degenerative spondylolisthesis	L4–L5 days/c with instrumented PSF + ICBG	Yes, pinhole dural defect at L4–L5 repaired with 4-0 silk; intraoperatively developed coagulopathy
6	82	Female	Primary	L3–L5 stenosis with degenerative spondylolisthesis	L3–S1 days/c with instrumented PSF + ICBG	No

(Table Continues)

DT = dural tear; HA = headaches, VM = Valsalva maneuver, d/c = decompression, ICBG = iliac crest bone graft.

**Medical Record Review.** Patients with DT (n = 338) were identified from our records. The number of patients who required a second procedure in the operating room for an irrigation and debridement was also noted. For these patients, operative reports were reviewed to determine further details about the location and characteristics of the DT as well as the repair techniques used. Medical records were reviewed to delineate their postoperative course and whether or not treatment was successful.

**DT Mobilization Protocol.** At our institution, once a patient has been identified as having a DT, we use the following postoperative management protocol (Figure 1): Patients are kept supine in bed rest for 24 hours. The morning after surgery, the subfascial drain is taken off suction and put to gravity. After the first 24 hours, the patients are allowed to elevate the head of bed at 30° for 8 hours. If no headache occurs, they are allowed a period of trial ambulation with assistance. If they are able to tolerate the trial ambulation, they are allowed to ambulate as tolerated. On the other hand, if the patients have a recurrent headache as a result of the bed head-elevation trial, or if they have a headache with trial ambulation with assistance, the trial protocol is restarted with bed rest for 24 hours. The subfascial drain is maintained on gravity and removed by day 3. This drain theoretically allows the patients to get up early and avoid the buildup of CSF in the subfascial region. Patients who have a persistent headache despite these measures for more than 72 hours are taken back to the operating room for exploration, including placement of a subfascial drain to closed suction. Other indications for reoperation include persistent clear wound drainage. After this second procedure, our DT protocol is reinitiated as outlined (Figure 1).

■ **Results**

The overall rate of DT in this study was 10.6% (338 of 3,183 patients). Of the 2,024 patients who underwent primary surgery, 153 (7.6%) had an intraoperative DT. This compares to a rate of 15.9% (185 of 1,159 patients) in the revision group. The most common postoperative signs and symptoms of DT were persistent headaches and clear drainage from the drain after the index procedure.

The patients were mobilized according to the protocol outlined in Figure 1. Of the 338 patients, 332 were successfully mobilized without requiring a reoperation.

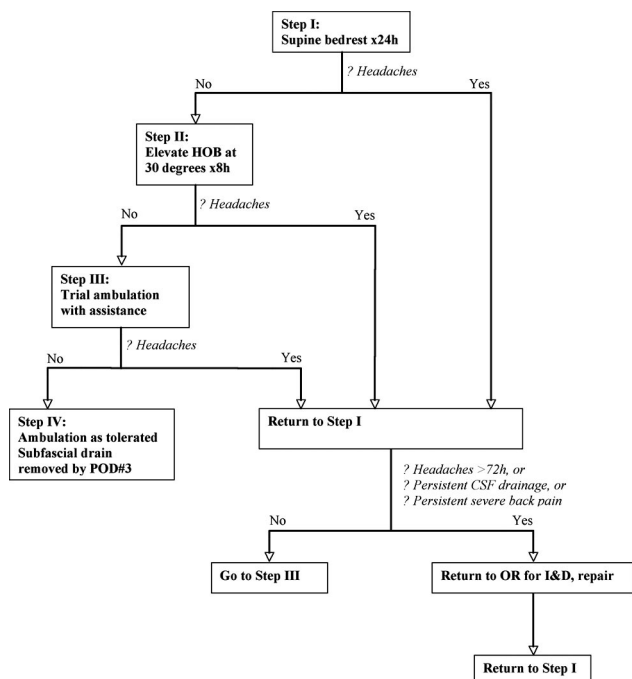


Figure 1. Flow diagram for postoperative management of dural tears.

**Table 2. Continued**

Postoperative Symptoms	Intraoperative Findings	Postoperative Course
Severe HA + persistent clear drainage from wound	POD 4: 1 mm DT at R-L4–L5 repaired with 4-0 silk, covered with muscle patch, Gelfoam, fibrin glue; no leak with VM	HA resolved; no CSF leak from wound
Severe HA + persistent CSF drainage from Hemovac	POD 3: 4 mm DT at R-L4 nerve root sleeve repaired with 4-0 silk, covered with muscle patch, Gelfoam; L1–L2 intrathecal lumbar drain placed	HA resolved; intrathecal lumbar drain removed on POD 3
Persistent clear drainage from wound	POD 3: pinhole at previously repaired DT site; repaired with 4-0 silk; no leak with VM; subfascial drain placed	CSF drainage resolved; no HA
Postoperative pulmonary edema and coughing; wound started to leak CSF + severe HA	POD 3: CSF leakage from site of previous DT repair suture hole; repaired with 4-0 silk; no leak with VM; subfascial drain placed	CSF drainage resolved; no HA
Postoperative HA + persistent CSF drainage from wound	POD 7: CSF leakage from site of previous DT repair suture; suture had cut through the friable dura; defect oversewn with 4-0 silk; attempts at intrathecal lumbar drain failed due to poor turgor; no leak with VM; subfascial drain placed	Persistent CSF wound drainage; taken to OR 1 wk later for repeat I&D; punctate leakage from previously repaired DT suture hole, covered with Tisseal; good turgor in dural sac; intrathecal lumbar drain placed; CSF drainage stopped; however, patient developed wound infection requiring further I&D ×2; infection resolved with IV antibiotics
Bloody wound drainage starting POD 10; no HA	POD 13: 1 cm long dural ectasia at L5–S1 with small bleb, repaired with running, locked 4-0 silk; no leak with VM; subfascial drain placed	No further complications

Therefore, the mobilization protocol was successful in 332 of 338 cases (98.2%). Six patients (4 primary, 2 revisions, all female), required a return trip to the operating room for irrigation and debridement and/or repair of the dural defect (Table 2). Headaches with or without persistent clear wound drainage were the most common indicators of a DT. Four patients had a recognized DT at the index procedure that was repaired with a 4-0 silk suture; after this repair, a Valsalva maneuver showed that there was no CSF leakage from the repair site. For these 4 patients, a reexploration showed that 3 patients were persistently leaking from the previous repair site, while 1 patient (Patient 2) had a second DT that was not appreciated during the first surgery. The other 2 patients did not have a recognized DT at the index procedure; on reexploration, Patient 1 had a small, 1-mm DT, whereas Patient 6 had a small DT at in a part of dura that was thin and ectatic. Both of these were repaired with a 4-0 silk suture. Subfascial drains were placed in 4 patients to prevent the formation of a pseudomeningocele. Intrathecal lumbar drains were used in two patients (Patients 2 and 5). Intrathecal drains were used when the second repair was not satisfactory (persistent leaks with Valsalva maneuver after the repair).

## ■ Discussion

The literature on iatrogenic DT during spine surgery is surprisingly sparse. An accurate understanding of the true incidence and treatment of DT during lumbar spine surgery is hampered by the fact that reports in the literature have small number of patients.<sup>1,3,4</sup> In the most comprehensive study on the subject, Wang *et al*<sup>2</sup> reported that 14% (88 of 641) patients undergoing degenerative lumbar spine surgery sustained DT. In a Euro-

pean study of 93 patients with DT, the incidence was 8.5% in patients who had surgery for spinal stenosis and 13.2% for revision discectomy.<sup>7</sup> Camissa *et al* had an overall DT rate of 3.1% in their series of patients and a rate of 8.1% in revision cases.<sup>5</sup> Stolke *et al* reported that 17.4% of patients undergoing revision lumbar surgery had DT.<sup>6</sup> In our report, the incidence of 7.6% for primary and 15.9% for revision lumbar cases compares favorably to these previous studies. To our knowledge, our experience with 338 cases of DT during degenerative lumbar spine surgery is the largest series reported in the literature. There are data to suggest that spine surgeons tend to underestimate the frequency of this complication.<sup>7</sup>

The signs and symptoms of DT are caused by a persistent leak of CSF from the subarachnoid space. Persistent headache exacerbated by head elevation and relieved by Trendelenburg position are characteristic of a CSF leak. Other signs and symptoms such as clear drainage or photophobia should also alert the physician to the presence of this complication. In this report, postural headaches and clear persistent drainage despite nonoperative management indicated a need for reoperation. Potential complications of DT include pseudomeningocele, CSF fistula, and even meningitis.<sup>5,8</sup> However, in a recent retrospective study with 10-year followup, Saxler *et al* reported that patients who had sustained a DT have increased rates of back pain and headaches compared with a matched cohort of control subjects.<sup>9</sup> The incidence of infections in patients with DT does not appear to be higher than those without DT.<sup>5</sup> Of note, this complication is the second most common cited cause of malpractice lawsuits in spine surgery.<sup>10</sup>

Nonoperative treatment of unrepaired DT is not successful.<sup>1</sup> Several methods of surgical repair for the treat-

ment of DT have been described in the literature. They include primary repair, application of tissue sealants or blood patches, and tissue grafting.<sup>11</sup> Recently, Narotam *et al* reported >95% success with a sutureless repair technique using a synthetic collagen matrix graft in a series of 110 patients.<sup>12</sup> The biology of DT repair has been studied in the dog model.<sup>13</sup> Fibroblastic bridging of the defect starts on the sixth day, and healing occurs approximately on the 10th day. However, the surgeon should not rely on spontaneous healing of the DT if it is recognized intraoperatively. The tear should be repaired. We repaired the dural defect with 4-0 nylon and placed subfascial drains in most cases. We routinely perform a few Valsalva maneuvers after the repair to confirm that the defect has been appropriately sealed. Although some authors advise against placement of a subfascial drain due to concerns about a CSF fistula,<sup>1,11</sup> others have advocated for placement of such drains.<sup>2,5</sup>

None of our patients who had subfascial drains placed had a resultant CSF fistula. We take the subfascial drain off suction and place it to gravity on the first morning after surgery, allowing approximately 80 to 100 mL of CSF to drain per shift. Keeping the drain to gravity off suction theoretically allows the subfascial CSF pressure to dictate amount of drainage, without extracting additional CSF from the subdural space. We have found that subfascial drains were helpful in decompressing the subfascial space to prevent the buildup of CSF, which is caustic to tissue and may lead to the formation of a fistula. We like to take the subfascial drain out on day 3 even if CSF is seen coming of the drain. The reason for this is that, if there is persistent drainage of CSF after 72 hours, the patient is likely to fail early mobilization and is likely to require repeat exploration of the dura. Patients who had persistent headaches or wound drainage after 72 hours were taken back to the OR for repair. Intrathecal drains were used in cases where persistent CSF leaks were detected with a Valsalva maneuver even after the second exploration and repair.

It has been our experience that a trial of brief bed rest followed by early mobilization was an effective strategy, which was successful in treating our patients in 98.2% of the cases. Persistent symptoms lasting more than 72 hours after the initial surgery were seen in only 6 cases, which was an indication for reoperation. On the other hand, Wang *et al* reported that their patients were on bed rest for an average of 2.9 days.<sup>2</sup> Bed rest is thought to reduce hydrostatic pressure on the repaired dura. However, in a study of 20 patients, Hodges *et al* showed that patients who had a repaired DT during the index procedure did well without bed rest.<sup>14</sup>

In their study, Wang *et al* had a 2.3% reoperation rate (2 of 88 patients; both were revision cases).<sup>2</sup> Similarly, Camissa *et al* had a reoperation rate of 9.1% (6 of 66 patients).<sup>5</sup> In comparison, only 6 of the 338 DT cases (1.8%) in this study required reexploration, repair of the defect, and placement of drains. This suggests that our postoperative management protocol is highly efficacious.

Although in our series the overall rate of DT was higher in the revisions as compared with the primary procedures (15.9% *vs.* 7.6%), only 2 of the 6 patients in our study who required a reoperation were revisions. Dural adhesions and fibrosis along with dural out-pouching may contribute to the nearly double the rate of DT in revisions. However, with adequate and careful repair technique, we have shown that these cases can be successfully treated. Meticulous surgical technique is therefore necessary during revision surgery.<sup>11</sup>

## ■ Conclusion

We recommend careful vigilance for DT, especially during revision surgery. If a DT is suspected, the Valsalva maneuver may help in identifying it. Prompt identification and careful closure of the dural defect at time of surgery lead to successful outcome in the overwhelming majority of cases. Subfascial drains have been useful in our experience for treating DT after repair. Only a small percentage of patients require a repeat surgical reexploration. The postoperative DT management protocol outlined in this report has proven very successful in our 10-year experience with 3,183 degenerative lumbar spine surgery cases.

## ■ Key Points

- Dural tears are approximately twice as frequent in revision degenerative lumbar spine surgery as compared with primary cases.
- Intraoperative vigilance is essential for recognizing this complication. When detected, meticulous repair is required.
- Subfascial drains do not lead to the formation of a fistula.
- The postoperative dural tear management protocol, outlined in this report, which relies on early mobilization, has a high success rate (98.2%).

## References

1. Eismont FJ, Wiesel SW, Rothman RH. Treatment of dural tears associated with spinal surgery. *J Bone Joint Surg Am* 1981;63:1132-6.
2. Wang JC, Bohlman HH, Riew DK. Dural tears secondary to operations on the lumbar spine: management and results after a two-year-minimum follow-up of eighty-eight patients. *J Bone Joint Surg Am* 1998;80:1728-32.
3. Jones AA, Stambough JL, Balderston RA, et al. Long-term results of lumbar spine surgery complicated by unintended incidental durotomy. *Spine* 1989; 14:443-6.
4. Kitchel SH, Eismont FJ, Green BA. Closed subarachnoid drainage for management of cerebrospinal fluid leakage after an operation on the spine. *J Bone Joint Surg Am* 1989;71:984-7.
5. Cammissa FP Jr, Girardi FP, Sangani PK, et al. Incidental durotomy in spine surgery. *Spine* 2000;25:2663-7.
6. Stolke D, Sollmann W, Seifert V. Intra- and postoperative complications in lumbar disc surgery. *Spine* 1989;14:56-9.
7. Tafazal SI, Sell PJ. Incidental durotomy in lumbar spine surgery: incidence and management. *Eur Spine J* 2005;14:287-90.
8. Verner EF, Musher DM. Spinal epidural abscess. *Med Clin North Am* 1985; 69:375-84.
9. Saxler G, Kramer J, Barden B, et al. The long-term clinical sequelae of incidental durotomy in lumbar disc surgery. *Spine* 2005;30:2298-302.

10. Goodkin R, Laska LL. Unintended 'incidental' durotomy during surgery of the lumbar spine: medicolegal implications. *Surg Neurol* 1995;43:4-12.
11. Bosacco SJ, Gardner MJ, Guille JT. Evaluation and treatment of dural tears in lumbar spine surgery. *Clin Orthop* 2001;389:238-47.
12. Narotam PK, Jose S, Nathoo N, et al. Collagen matrix (DuraGen) in dural repair: analysis of a new modified technique. *Spine* 2004;29:2861-7.
13. Cain JE Jr, Lauerma WC, Rosenthal HG, et al. The histomorphologic sequence of dural repair: observations in the canine model. *Spine* 1991;16(suppl):319-23.
14. Hodges SD, Humphreys CS, Eck JC, et al. Management of incidental durotomy without mandatory bed rest: a retrospective review of 20 cases. *Spine* 1999;24:2062-5.