

# Biomechanical analysis of anterior versus posterior instrumentation following a thoracolumbar corpectomy

## Laboratory investigation

STEPHANUS V. VILJOEN, M.D.,<sup>1</sup> NICOLE A. DEVRIES WATSON, PH.D.,<sup>2</sup>  
NICOLE M. GROSLAND, PH.D.,<sup>2,3</sup> JAMES TORNER, PH.D.,<sup>4</sup> BRIAN DALM, M.D.,<sup>1</sup>  
AND PATRICK W. HITCHON, M.D.<sup>1</sup>

*Departments of <sup>1</sup>Neurosurgery, <sup>2</sup>Orthopaedics and Rehabilitation, <sup>3</sup>Biomedical Engineering, and <sup>4</sup>Preventative Medicine and Environmental Health, The University of Iowa, Iowa City, Iowa*

**Object.** The objective of this study was to evaluate the biomechanical properties of lateral instrumentation compared with short- and long-segment pedicle screw constructs following an L-1 corpectomy and reconstruction with an expandable cage.

**Methods.** Eight human cadaveric T10–L4 spines underwent an L-1 corpectomy followed by placement of an expandable cage. The spines then underwent placement of lateral instrumentation consisting of 4 monoaxial screws and 2 rods with 2 cross-connectors, short-segment pedicle screw fixation involving 1 level above and below the corpectomy, and long-segment pedicle screw fixation (2 levels above and below). The order of instrumentation was randomized in the 8 specimens. Testing was conducted for each fixation technique. The spines were tested with a pure moment of 6 Nm in all 6 degrees of freedom (flexion, extension, right and left lateral bending, and right and left axial rotation).

**Results.** In flexion, extension, and left/right lateral bending, posterior long-segment instrumentation had significantly less motion compared with the intact state. Additionally, posterior long-segment instrumentation was significantly more rigid than short-segment and lateral instrumentation in flexion, extension, and left/right lateral bending. In axial rotation, the posterior long-segment construct as well as lateral instrumentation were not significantly more rigid than the intact state. The posterior long-segment construct was the most rigid in all 6 degrees of freedom.

**Conclusions.** In the setting of highly unstable fractures requiring anterior reconstruction, and involving all 3 columns, long-segment posterior pedicle screw constructs are the most rigid.  
(<http://thejns.org/doi/abs/10.3171/2014.6.SPINE13751>)

**KEY WORDS** • biomechanics • thoracolumbar corpectomy • thoracic • anterior instrumentation • posterior instrumentation

**T**HORACOLUMBAR corpectomies are performed to treat unstable burst fractures, tumors, and infections of the spine. In fractures, surgery is indicated when patients present with neurological deficit, pain, or evidence of structural instability.<sup>7,11,13</sup> Thoracolumbar corpectomies can be performed anterolaterally through the retroperitoneal flank approach or posteriorly through the transpedicular route. Following corpectomy, the vertebral column is reconstructed by inserting a graft or prosthesis. Anterior column reconstruction allows for correcting angulation and restoring the loss in vertebral body height.<sup>2,5,7</sup> Additional fixation with lateral vertebral body screws usually 1 level above and below, pedicle screws either short- or long-segment, or both, are required.

The decision of whether to place anterior versus posterior instrumentation is largely based on the approach used, surgeon preference, and integrity of the posterior ligamentous complex. Both anterior- and posterior-only fixation have shown good clinical results.<sup>1,5,14,15</sup> Biomechanical studies have compared anterior with posterior

instrumentation in the bovine spine,<sup>3</sup> as well as compared various anterior instrumentation systems, with the anterior 2-rod system being the most stable.<sup>2,4,6–8</sup>

In recent years expandable cages have become an increasingly common method of reconstructing the anterior column. Advantages include ease of deployment, induction of an axial loading force on the bodies above and below theoretically enhancing fusion rates, and ability to better preserve the adjacent endplates. However, few biomechanical studies have been performed using expandable cages. Therefore, the focus of this study was to compare the rigidity of anterolateral instrumentation versus posterior short- and long-segment pedicle screw fixation following an L-1 corpectomy and anterior column reconstruction with an expandable cage.

## Methods

### *Specimen Preparation*

Eight fresh-frozen human cadaveric spine specimens

were obtained from the deeded body program of the University of Iowa Department of Anatomy. Age, sex, and bone mineral density were recorded. The spines were radiographed in both the anteroposterior and lateral planes to ensure the absence of fractures, deformities, and any metastatic disease. Bone mineral density was measured using peripheral quantitative CT. The specimens were stored in double plastic bags at  $-20^{\circ}\text{C}$  and allowed to thaw at room temperature prior to any manipulation. Thawed specimens were denuded of paravertebral musculature, avoiding disruption of spinal ligaments, joints, and discs. Specimens were potted at T-10 and L-4 using polymer resin (Bondo, 3M Corp.). Prior to potting, wood screws were inserted into the endplates to improve interdigitation with the potting material.

#### *Experimental Setup*

Each specimen was mounted in a biaxial servohydraulic materials-testing machine (858 Bionix II, MTS Corp.) retrofitted with 2 spine gimbals and a passive XZ table. Custom-made rigid body markers consisting of 3 infrared light-emitting diodes affixed between 2 small aluminum plates were placed on each vertebral body and the 2 gimbals to track the segmental motions. Non-destructive flexibility tests were performed around each axis of rotation (flexion and extension, right and left lateral bending, and right and left axial rotation) by applying an isolated  $\pm 6\text{-Nm}$  moment around each of the primary axes. Each test initiated and concluded in the neutral position with zero load. Three loading and unloading cycles were performed, with motion data collected on the third cycle (the first 2 cycles served as preconditioning). The displacement of each vertebra was measured using an optoelectronic motion capture system (OptoTrak 3020, Northern Digital), the output of which was synchronized with that of the materials testing system. Moment-rotation curves were plotted for each scenario and the motions are reported for the greatest moment loading (6.0 Nm).

#### *Testing Paradigm*

Testing was performed in the following order: 1) intact spines were tested on the materials testing system as described above, prior to any surgical intervention, which served as a control; 2) specimens then underwent corpectomy followed by placement of the expandable cage; and 3) specimens were instrumented in a randomized order, with testing completed after each fixation technique (lateral instrumentation, posterior short-segment instrumentation, and posterior long-segment instrumentation).

#### *Corpectomy and Anterior Column Reconstruction*

Using a scalpel, the disc spaces at T12–L1 and L1–2 were incised, and the disc was removed using rongeurs. An osteotome was used to make a cut ventral to the L-1 pedicle; another cut was made dorsal to the anterior longitudinal ligament. A large wedge of bone was then freed with a curette. The remaining portion of the corpectomy was performed using a combination of punches and curettes, and care was taken to ensure that the disc material was thoroughly removed and the endplates were not

violated. A large footprint,  $24 \times 30\text{-mm}$  X-MESH expandable cage with  $0^{\circ}$  endplates (DePuy Spine) was then placed in the corpectomy defect and expanded until the cage was firmly seated against the endplates.

#### *Lateral Instrumentation*

Small staples (DePuy Spine) were placed into the bodies of T-12 and L-2. An awl was used to break the cortical surface, and a pedicle probe was used to create a trajectory parallel to the floor of the spinal canal. A 5.0-mm tap was used to prepare the trajectory. Next,  $6.5 \times 55\text{-mm}$  monoaxial screws were placed in the bodies of T-12 and L-2 bicortically. Two 5.5-mm titanium rods were cut to the appropriate length and inserted in the screw heads. Set screws were placed and final tightened according to the manufacturer's recommendation. Two cross-connectors were placed and final tightened prior to testing. Following removal of the lateral instrumentation, the cage was checked to ensure it had not become displaced.

#### *Posterior Short- and Long-Segment Instrumentation*

Using anatomical landmarks, the cortical surface was penetrated with an awl. A pedicle probe was used to engage the pedicle down to a depth of 30 mm. A ball-tip probe was used to ensure that the cortex of the pedicle was intact on all sides. A 5.0-mm tap was then used to prepare the pedicle. A  $6.0 \times 45\text{-mm}$  polyaxial screw was then inserted into the pedicle. Screw purchase did appear to correlate with the known bone mineral density for each specimen, but this was not quantified. For short-segment constructs, screws were placed at T-12 and L-2. For long-segment constructs, screws were placed at T-11, T-12, L-2, and L-3. Following placement of the pedicle screws, appropriate-length 5.5-mm titanium rods were cut and placed in the screw heads. The rod was fixed with set screws and all instrumentation was final tightened prior to testing. No cross-connector was used for posterior instrumentation to keep the results of the study applicable in the setting of percutaneous pedicle screws.

#### *Statistical Analysis*

Statistical analysis was conducted using the general linear models procedure for ANOVA. Pairwise comparisons were made using the Tukey test. Statistical significance was determined at the  $0.05 \alpha$  level.

## **Results**

The mean age of the cadaver spines was  $81.6 \pm 10.6$  years. The bone mineral densities ranged from  $0.395 \text{ g/cm}^3$  to  $1.584 \text{ g/cm}^3$ , with a mean of  $0.895 \pm 0.349 \text{ g/cm}^3$ . Graphic and numerical summaries of the motion are presented in Fig. 1 and Table 1.

#### *Flexion and Extension*

In flexion, posterior long-segment instrumentation had significantly less motion at T12–L2 ( $0.91^{\circ} \pm 0.44^{\circ}$ ) compared with the intact state ( $3.90^{\circ} \pm 1.84^{\circ}$ ), as well as significantly less motion than the lateral and short-segment constructs. Lateral instrumentation ( $2.46^{\circ} \pm 1.72^{\circ}$ )

## Anterior versus posterior instrumentation following corpectomy

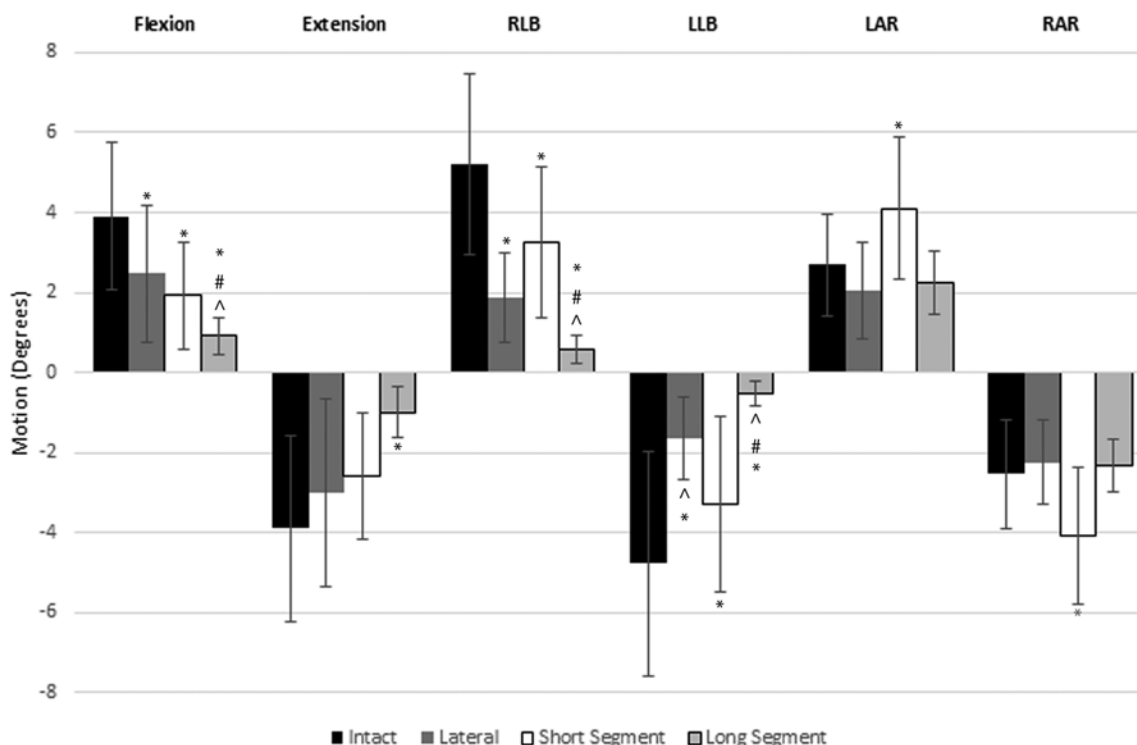


Fig. 1. Summary of motion across T12–L2 at 6 Nm. LAR = left axial rotation; LLB = left lateral bending; RAR = right axial rotation; RLB = right lateral bending. \* Statistically significant difference from the intact state. # Statistically significant difference from lateral fixation. ^ Statistically significant difference from short-segment fixation.

as well as posterior short-segment instrumentation ( $1.92^\circ \pm 1.33^\circ$ ) also produced significantly reduced motion in flexion compared with the intact state.

In extension, posterior long-segment instrumentation had significantly less motion at T12–L2 ( $-0.98^\circ \pm 0.64^\circ$ ) compared with the intact state ( $-3.90^\circ \pm 2.33^\circ$ ). Lateral ( $-3.00^\circ \pm 2.36^\circ$ ) as well as posterior short-segment constructs ( $-2.59^\circ \pm 1.58^\circ$ ) also had less motion than the intact state, but these differences did not reach statistical significance.

### Axial Rotation

In left axial rotation, short-segment instrumentation showed significantly more motion across T12–L2 ( $4.10^\circ \pm 1.79^\circ$ ) compared with the intact state ( $2.69^\circ \pm 1.26^\circ$ ).

Lateral ( $2.04^\circ \pm 1.21^\circ$ ) and posterior long-segment instrumentation ( $2.24^\circ \pm 0.78^\circ$ ) showed less motion than the intact state, but these differences did not reach statistical significance.

Similarly, in right axial rotation, short-segment instrumentation showed significantly more motion across T12–L2 ( $-4.07^\circ \pm 1.70^\circ$ ) compared with the intact state ( $-2.54^\circ \pm 1.36^\circ$ ). Lateral ( $-2.23^\circ \pm 1.06^\circ$ ) and posterior long-segment instrumentation ( $-2.32^\circ \pm 0.66^\circ$ ) showed less motion than the intact state, but these differences did not reach statistical significance.

### Lateral Bending

In left lateral bending, the posterior long-segment construct had significantly less motion across T12–L2

TABLE 1: Range of motion at T12–L2 for the intact specimen and each fixation technique\*

Test	Extension	Flexion	Axial Rotation		Lateral Bending	
			Lt	Rt	Lt	Rt
intact	$-3.90 \pm 2.33$	$3.90 \pm 1.84$	$2.69 \pm 1.26$	$-2.54 \pm 1.36$	$-4.77 \pm 2.81$	$5.21 \pm 2.27$
lateral	$-3.00 \pm 2.36$	$2.46 \pm 1.72^\ddagger$	$2.04 \pm 1.21$	$-2.23 \pm 1.06$	$-1.63 \pm 1.02^\ddagger\$$	$1.86 \pm 1.12^\ddagger$
posterior						
short	$-2.59 \pm 1.58$	$1.92 \pm 1.33^\ddagger$	$4.10 \pm 1.79^\ddagger$	$-4.07 \pm 1.70^\ddagger$	$-3.28 \pm 2.17^\ddagger$	$3.26 \pm 1.89^\ddagger$
long	$-0.98 \pm 0.64^\ddagger$	$0.91 \pm 0.44^\ddagger\$$	$2.24 \pm 0.78$	$-2.32 \pm 0.66$	$-0.53 \pm 0.31^\ddagger\$$	$0.58 \pm 0.36^\ddagger\$$

\* Data presented as mean ( $^\circ$ )  $\pm$  standard deviations.

† Statistically significant difference from the intact state.

‡ Statistically significant difference from lateral fixation.

§ Statistically significant difference from short-segment fixation.

( $-0.53^\circ \pm 0.31^\circ$ ) compared with the intact ( $-4.77^\circ \pm 2.81^\circ$ ), lateral ( $-1.63^\circ \pm 1.02^\circ$ ), and short-segment constructs ( $-3.28^\circ \pm 2.17^\circ$ ). In a pairwise comparison, the lateral construct showed statistically significant less motion than both the short-segment and intact states. The short segment also showed statistically less motion than the intact state.

In right lateral bending, the posterior long-segment construct had significantly less motion across T12–L2 ( $0.58^\circ \pm 0.36^\circ$ ) compared with the intact state ( $5.21^\circ \pm 2.27^\circ$ ), as well as the lateral and short-segment constructs. The lateral ( $1.86^\circ \pm 1.12^\circ$ ) and short-segment constructs ( $3.26^\circ \pm 1.89^\circ$ ) had significantly less motion than the intact spine. In a pairwise comparison, however, the difference in motion between the lateral and short-segment constructs did not reach statistical significance.

### Discussion

Multiple factors influence the decision to place anterior instrumentation, posterior instrumentation, or both following a thoracolumbar corpectomy. Factors such as the integrity of the posterior ligamentous complex, approach used, surgeon preference, and bone quality all potentially influence this decision. Advantages of anterior instrumentation include a shorter construct, a less technically demanding procedure than pedicle screw placement, and no need for an additional posterior procedure. However, the additional exposure required and needed to ligate adjacent segmental vessels does potentially add to the morbidity.

In the 150 cases of corpectomy and lateral instrumentation reported by Kaneda et al., there were 10 cases of pseudarthrosis necessitating posterior instrumentation and fusion. They found that there was loss of correction at follow-up, and in some cases an iatrogenic coronal deformity was created.<sup>11,12</sup> McAfee reported on complications associated with the anterior approach when used in patients with thoracolumbar fractures undergoing decompression and stabilization with various lateral implants. The failure rate was only 2 of 35 cases.<sup>14</sup>

Hitchon et al. compared 38 patients who underwent anterior corpectomy, strut graft placement, and lateral 2-rod instrumentation with 25 patients who underwent posterior instrumentation only for thoracolumbar burst fractures. The anterior group showed significantly better correction of kyphotic deformity from admission to discharge and maintained correction better at a mean of 1.8 years follow-up. Only 2 of the 38 patients who underwent lateral instrumentation required additional posterior instrumentation.<sup>9</sup>

Kallemeier et al. tested 9 human cadaveric spines after an L-1 burst fracture. They compared the intact spine with posterior pedicle screws alone, posterior instrumentation with corpectomy and femoral allograft, femoral allograft and anterior instrumentation only, and both anterior and posterior instrumentation with femoral allograft. These investigators found that only after combined anterior and posterior instrumentation was the range of motion similar to the intact state.<sup>10</sup> Eichholz et al. compared anterior versus posterior instrumentation following an

L-3 corpectomy and reconstruction of the anterior column with a wooden strut graft. As in other studies, they also found that circumferential instrumentation was more rigid than the intact spine. They found greater rigidity with pedicle screw fixation compared with anterior instrumentation alone, but this difference did not achieve statistical significance.<sup>2</sup>

Several conclusions can be made based on our results. First, posterior long-segment instrumentation with anterior column reconstruction reduced the T12–L2 motion more than short-segment fixation and lateral instrumentation in all degrees of motion. In a pairwise comparison, the long-segment construct performed significantly better at reducing motion than the lateral instrumentation and short-segment construct in flexion, and left and right lateral bending. Long-segment constructs take advantage of multiple points of fixation and use pedicle screws that engage all 3 columns of the spine.

Second, lateral instrumentation consisting of vertebral body staples, 4 bicortical monoaxial screws, 2 rods, and 2 cross-connectors, had less T12–L2 motion in both right and left axial rotation and left lateral bending than the short posterior pedicle screw construct. In right lateral bending, the lateral construct showed less motion than the posterior short segment, but this difference did not reach statistical significance. The increased rigidity in lateral bending and axial rotation is likely due to the use of monoaxial screws, bicortical purchase, and the use of 2 cross-connectors. Only in flexion and extension, where the pedicle screw and rods are effective in creating a posterior tension band, did the posterior short-segment construct restrict motion more than the lateral construct. In the pairwise comparison, however, these differences in motion did not achieve statistical significance.

### Conclusions

In the setting of highly unstable fractures requiring anterior reconstruction, and involving all 3 columns, long-segment posterior pedicle screw constructs are the most rigid. In situations in which the posterior column and ligamentous complex are intact, lateral instrumentation without supplemental posterior instrumentation should be sufficient.

### Disclosure

Dr. Hitchon is the recipient of research support from DePuy Spine for the Biomechanics Research Laboratory.

Author contributions to the study and manuscript preparation include the following. Conception and design: Viljoen. Acquisition of data: Viljoen, DeVries Watson, Dalm. Analysis and interpretation of data: Viljoen, DeVries Watson, Grosland, Torner, Hitchon. Drafting the article: Viljoen. Critically revising the article: all authors. Reviewed submitted version of manuscript: all authors. Approved the final version of the manuscript on behalf of all authors: Viljoen. Statistical analysis: DeVries Watson, Grosland, Torner. Administrative/technical/material support: Grosland, Dalm, Hitchon. Study supervision: Grosland, Hitchon.

### References

1. Dickman CA, Yahiro MA, Lu HT, Melkerson MN: Surgical

## Anterior versus posterior instrumentation following corpectomy

- treatment alternatives for fixation of unstable fractures of the thoracic and lumbar spine. A meta-analysis. **Spine (Phila Pa 1976)** **19** (20 Suppl):2266S–2273S, 1994
- Eichholz KM, Hitchon PW, From A, Rubenbauer P, Nakamura S, Lim TH, et al: Biomechanical testing of anterior and posterior thoracolumbar instrumentation in the cadaveric spine. **J Neurosurg Spine** **1**:116–121, 2004
  - Gurr KR, McAfee PC, Shih CM: Biomechanical analysis of anterior and posterior instrumentation systems after corpectomy. A calf-spine model. **J Bone Joint Surg Am** **70**:1182–1191, 1988
  - Hitchon PW, Brenton MD, Serhan H, Goel VK, Torner JC: In vitro biomechanical studies of an anterior thoracolumbar implant. **J Spinal Disord Tech** **15**:350–354, 2002
  - Hitchon PW, Follett KA: Transpedicular screw fixation of the thoracic and lumbar spine, in Hitchon PW, Traynelis VC, Rengachary SS (eds): **Techniques in Spinal Fusion and Stabilization**. New York: Thieme, 1995, pp 240–247
  - Hitchon PW, Goel VK, Rogge T, Grosland NM, Sairyo K, Torner J: Biomechanical studies of a dynamized anterior thoracolumbar implant. **Spine (Phila Pa 1976)** **25**:306–309, 2000
  - Hitchon PW, Goel VK, Rogge T, Grosland NM, Torner J: Biomechanical studies on two anterior thoracolumbar implants in cadaveric spines. **Spine (Phila Pa 1976)** **24**:213–218, 1999
  - Hitchon PW, Goel VK, Rogge TN, Torner JC, Dooris AP, Drake JS, et al: In vitro biomechanical analysis of three anterior thoracolumbar implants. **J Neurosurg** **93** (2 Suppl): 252–258, 2000
  - Hitchon PW, Torner J, Eichholz KM, Beeler SN: Comparison of anterolateral and posterior approaches in the management of thoracolumbar burst fractures. **J Neurosurg Spine** **5**:117–125, 2006
  - Kallemeier PM, Beaubien BP, Buttermann GR, Polga DJ, Wood KB: In vitro analysis of anterior and posterior fixation in an experimental unstable burst fracture model. **J Spinal Disord Tech** **21**:216–224, 2008
  - Kaneda K, Abumi K, Fujiya M: Burst fractures with neurologic deficits of the thoracolumbar-lumbar spine. Results of anterior decompression and stabilization with anterior instrumentation. **Spine (Phila Pa 1976)** **9**:788–795, 1984
  - Kaneda K, Taneichi H, Abumi K, Hashimoto T, Satoh S, Fujiya M: Anterior decompression and stabilization with the Kaneda device for thoracolumbar burst fractures associated with neurological deficits. **J Bone Joint Surg Am** **79**:69–83, 1997
  - Kirkpatrick JS, Wilber RG, Likavec M, Emery SE, Ghanayem A: Anterior stabilization of thoracolumbar burst fractures using the Kaneda device: a preliminary report. **Orthopedics** **18**:673–678, 1995
  - McAfee PC: Complications of anterior approaches to the thoracolumbar spine. Emphasis on Kaneda instrumentation. **Clin Orthop Relat Res** (306):110–119, 1994
  - McAfee PC, Bohlman HH, Yuan HA: Anterior decompression of traumatic thoracolumbar fractures with incomplete neurological deficit using a retroperitoneal approach. **J Bone Joint Surg Am** **67**:89–104, 1985

---

Manuscript submitted August 14, 2013.

Accepted June 25, 2014.

Please include this information when citing this paper: published online August 1, 2014; DOI: 10.3171/2014.6.SPINE13751.

Address correspondence to: Stephanus V. Viljoen, M.D., 200 Hawkins Dr., Iowa City, IA 52242. email: stephanus-viljoen@uiowa.edu.