

Fracture-dislocation of the fifth lumbar vertebra

A NEW CLASSIFICATION

Takato Aihara, Kazuhisa Takahashi, Masatsune Yamagata, Hideshige Moriya

From Chiba University, Chiba, Japan

We have studied fracture-dislocation of the fifth lumbar vertebra in seven patients and reviewed 50 previously reported cases. Based on this information, we have classified the injury into five types: type 1, unilateral lumbosacral facet-dislocation with or without facet fracture; type 2, bilateral lumbosacral facet-dislocation with or without facet fracture; type 3, unilateral lumbosacral facet-dislocation and contralateral lumbosacral facet fracture; type 4, dislocation of the body of L5 with bilateral fracture of the pars interarticularis; and type 5, dislocation of the body of L5 with fracture of the body and/or pedicle, with or without injury of the lamina and/or facet.

Conservative treatment of fracture-dislocation of L5 is generally not effective because the lesion is fundamentally unstable. Planning of the operation should be made on the basis of the various types of injury.

J Bone Joint Surg [Br] 1998;80-B:840-5.

Received 18 December 1997; Accepted after revision 2 April 1998

Fracture-dislocation of the fifth lumbar vertebra is relatively rare; its treatment presents challenging problems. About 70 cases have been reported in the literature, but there is as yet no rational classification of the disorder. Our aim is to describe the types of injury, the operative methods used, and the outcome of seven new cases and 50 published cases for which there is sufficient documentation.¹⁻³² Based on this analysis, a new classification of the disorder is proposed.

T. Aihara, MD, Head of Department
Department of Orthopaedic Surgery, Toyo Hospital, 12100 Miyagawa,
Hikari-town, Chiba 289-1727, Japan.

K. Takahashi, MD, Consultant Orthopaedic Surgeon
M. Yamagata, MD, Consultant Orthopaedic Surgeon
H. Moriya, MD, Professor and Head of Department
Department of Orthopaedic Surgery, School of Medicine, Chiba Uni-
versity, Chiba 260-0856, Japan.

Correspondence should be sent to Dr T. Aihara.

©1998 British Editorial Society of Bone and Joint Surgery
0301-620X/98/58657 \$2.00

Patients and Methods

This series. Between 1976 and 1997 seven men had surgery for fracture-dislocation of the fifth lumbar vertebra. Their mean age at operation was 22.6 years (16 to 28) with a mean period of follow-up of four years (2 to 6.75). The cause of injury was high-energy trauma in every case.

There was a unilateral lumbosacral facet-dislocation and contralateral lumbosacral facet fracture in three (cases 2, 3, 7), dislocation of the body of L5 with fracture of the vertebral body, lamina, and the L4/L5 facet in two (cases 4 and 5), bilateral lumbosacral facet-dislocation in one (case 1), and acute spondylolytic spondylolisthesis in one (case 6).

Before treatment, all patients complained of severe low back pain. Six had radicular symptoms and two bowel and bladder dysfunction (Table I). Six of the patients were referred to our hospital after long-term conservative treatment over a mean of seven months (5 weeks to 20 months).

Three patients had posterior decompression and posterolateral fusion using pedicle screws, followed by anterior interbody fusion at the L5/S1 level (cases 1, 3 and 7). One had posterior decompression and posterolateral fusion using pedicle screws from L3 to S1, followed by anterior interbody fusion at the L4/L5 level (case 4). One patient was treated by posterior decompression and posterolateral fusion using pedicle screws, without anterior interbody fusion (case 2). A posterior wire reduction device³³ was used to reduce the subluxation followed by anterior interbody fusion in our two earlier patients (cases 5, 6), in one without posterior decompression.

Reviewed cases. We reviewed 50 cases of fracture-dislocation of L5 reported in detail in the literature.¹⁻³² We excluded dislocation of L5 with sacral fracture, and lumbosacral facet fractures which were not associated with dislocation of L5. A summary is shown in Table I.

Results

Operative outcome of the present series. Low back pain disappeared after operation in four patients and improved in three. Radicular symptoms were improved in all six patients with preoperative neurological defects. Bowel and

Table I. Summary of our seven cases and the 50 reviewed according to our classification of types

| Author/s | L5 fracture-dislocation | | | | | | No neurological involvement | | | | | |
|-----------------------------------|--------------------------|----|---|----|----|-------|-----------------------------|----|---|---|---|-------|
| | Neurological involvement | | | | | Total | No neurological involvement | | | | | Total |
| | 1 | 2 | 3 | 4 | 5 | | 1 | 2 | 3 | 4 | 5 | |
| Abe et al ¹ | 1 | | | | 1 | 2 | | | | | 1 | 1 |
| Aufranc et al ² | | 1 | | | | 1 | | | | | | |
| Beguiristain et al ³ | | 1* | | | | 1 | | | | | | |
| Boger et al ⁴ | | | | | | | 1* | | | | | 1 |
| Carl and Blair ⁵ | 1* | | | | | 1 | 1 | | | | | 1 |
| Connolly et al ⁶ | 1 | | | | | 1 | 3 | | | | | 3 |
| Das De and McCreath ⁷ | 1* | 1 | | | | 2 | 1 | 1* | | | | 2 |
| Davis and Carragee ⁸ | | 1 | | | | 1 | | | | | | |
| Dewey and Browne ⁹ | | 1* | | | | 1 | | | | | | |
| Fardon ¹⁰ | | | | | 1† | 1 | | | | | | |
| Fujii et al ¹¹ | | | 1 | | | 1 | | 1 | | | | 1 |
| Fujimoto et al ¹² | | | | 1 | | 1 | | | | | | |
| Fukui et al ¹³ | | 1 | | | | 1 | | | | | | |
| Herron and Williams ¹⁴ | 1 | | | | | 1 | | | | | | |
| Hilibrand et al ¹⁵ | | | | 2† | | 2 | | | 2 | | | 2 |
| Horii et al ¹⁶ | | 2 | | | | 2 | 1 | | | 2 | | 1 |
| Kinoshita et al ¹⁷ | | 2 | 1 | 1 | | 4 | | | | | | |
| Kramer and Levine ¹⁸ | | | | | | | 1 | | | | | 1 |
| Maeda et al ¹⁹ | | | | 1 | | 1 | | | | | | |
| Minatani et al ²⁰ | 1 | | | | | 1 | | | | | | |
| Miz and Engler ²¹ | | | | | | | 1 | | | | | 1 |
| Morris ²² | | | | | | | 1 | | | | | 1 |
| Murayama et al ²³ | | | 1 | | | 1 | | | | | | |
| Newell ²⁴ | | | | 1 | | 1 | | | | | | |
| Okajima et al ²⁵ | 1 | | | | | 1 | | | | | | |
| Samberg ²⁶ | | | | | | | | | 1 | | | 1 |
| Van Savage et al ²⁷ | | | | | 1 | 1 | | | | | | |
| Shirado et al ²⁸ | 1 | | | | | 1 | | | | | | |
| Zoltan et al ²⁹ | | | | | | | 1 | | | | | 1 |
| Finkelstein et al ³⁰ | | 1 | | | | 1 | | | | | | |
| Gertzbein ³¹ | | 1* | | | | 1 | | | | | | |
| Steinitz et al ³² | | 1 | | | | 1 | | | | | | |
| Present series | | 1 | 2 | 1 | 2 | 6 | | | 1 | | | 1 |
| Total | | | | | | 39 | | | | | | 18 |

* pure dislocation of the fifth lumbar vertebra

† delayed appearance of neurological involvement

bladder dysfunction disappeared in one and was improved in another.

Radiographs at follow-up showed improvement of the spondylolistheses at L5 in five patients and none in two. The mean slip at L5 was 37.4% before operation and 19.4% at the latest follow-up. Bony union was achieved in five patients; two (cases 2 and 4) remained ununited. In these the pedicle screws had broken at the level showing no anterior interbody fusion.

Types of injury. Based on our seven patients and the 50 reported cases, we classified fracture-dislocation of the fifth lumbar vertebra into five types (Fig. 1):

Type 1. Unilateral lumbosacral facet-dislocation with or without facet fracture was recognised in 19 cases (none from our series). In this type, the contralateral facet remains intact.

Type 2. Bilateral lumbosacral facet-dislocation with or without facet fracture was seen in 16 cases (one from our series).

Type 3. Unilateral lumbosacral facet-dislocation and contralateral lumbosacral facet fracture was present in seven cases (three from our series).

Type 4. Dislocation of the body of L5 with bilateral fracture of the pars interarticularis (acute spondylolytic spondylolisthesis) was found in ten (one from our series).

Type 5. Dislocation of the body of L5 with fracture of the body and/or pedicle was observed in five (two from our series), either with or without injury of the lamina and/or facet.

Of our seven cases and the 50 reported, 39 (68.4%) showed neurological involvement (Table I). These included eight of the 19 in type 1, 14 of the 16 in type 2, five of the seven in type 3, eight of the ten in type 4, and four of the five in type 5.

Illustrative case reports

Case 1. A 25-year-old man was crushed in a flexed position between an elevator and a ceiling. He complained of severe pain in the low back and right thigh with bowel and bladder dysfunction. Radiographs revealed forward dislocation of the fifth lumbar vertebra on the sacrum (Fig. 2a) and fractures of the right transverse processes of L2, L4 and L5. Myelography showed total block at the L5/S1 level. Three-

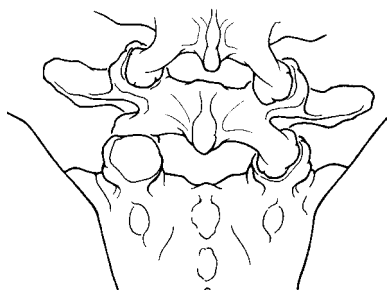


Fig. 1a

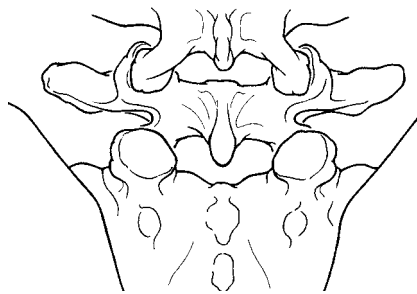


Fig. 1b

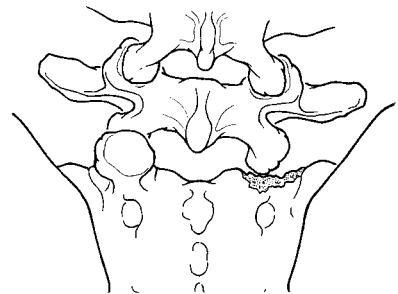


Fig. 1c

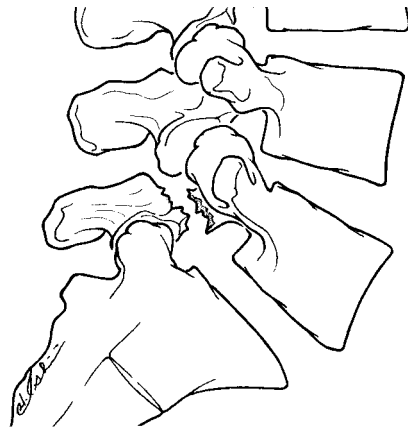


Fig. 1d

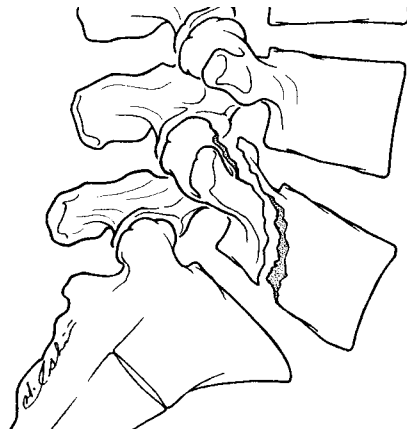

Fig. 1e

Diagrams showing the five types of L5 fracture-dislocation: a) type 1, b) type 2, c) type 3, d) type 4, and e) type 5.

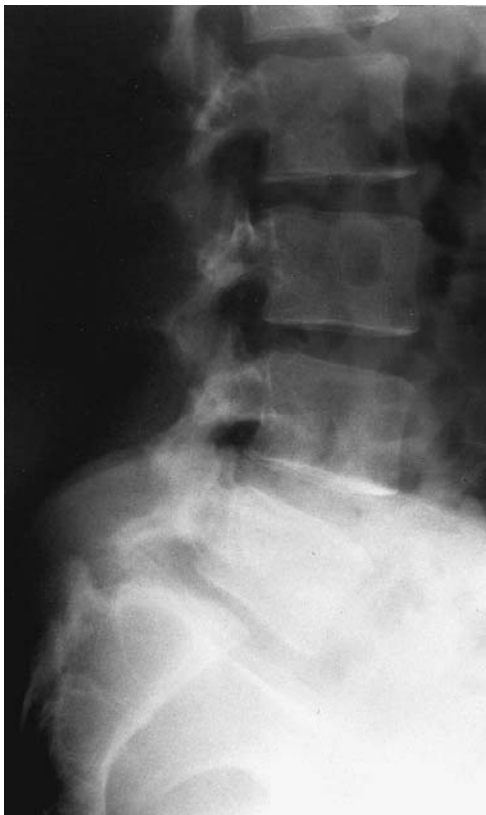

Fig. 2a

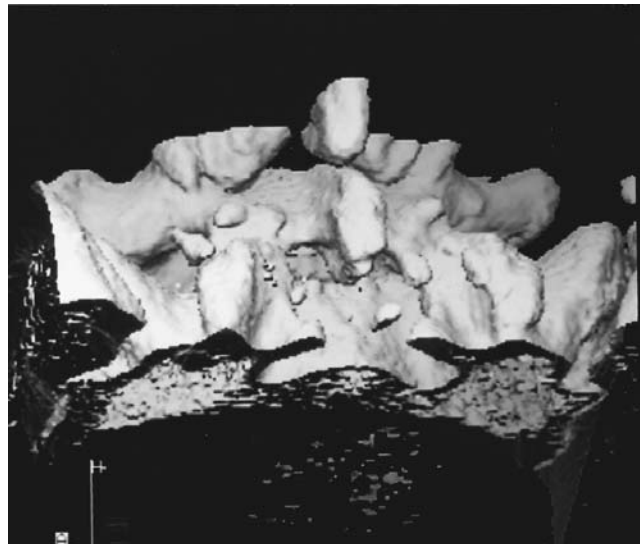


Fig. 2b

Case 1. Figure 2a – Lateral radiograph of the lumbar spine four months after injury, showing forward dislocation of the fifth lumbar vertebra on the sacrum. Figure 2b – Posterior view of a three-dimensional CT reconstruction of the lumbar-sacral junction showing bilateral lumbosacral facet interlocking. Fractures of the facet were not evident.

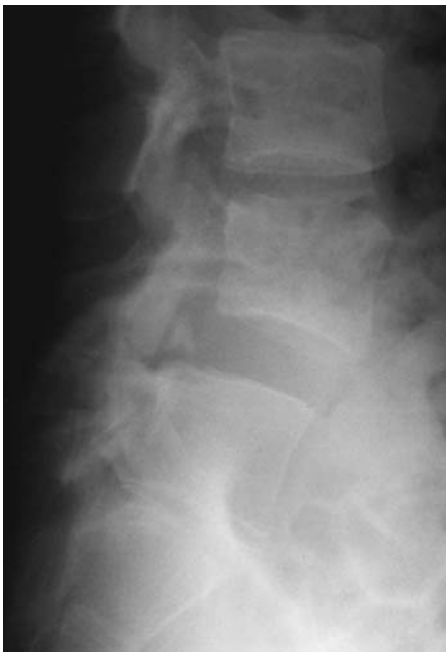

Fig. 3a

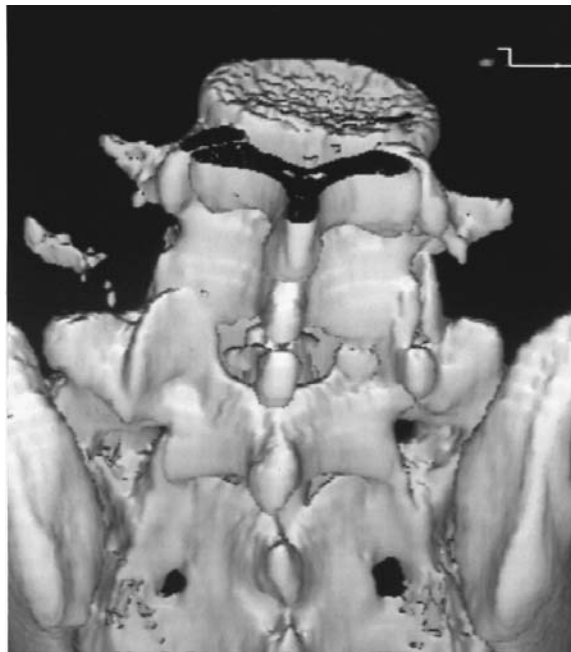

Fig. 3b

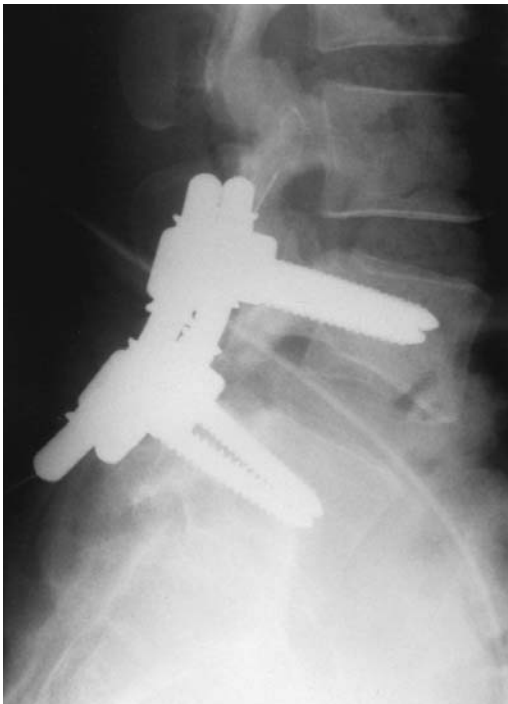


Fig. 3c

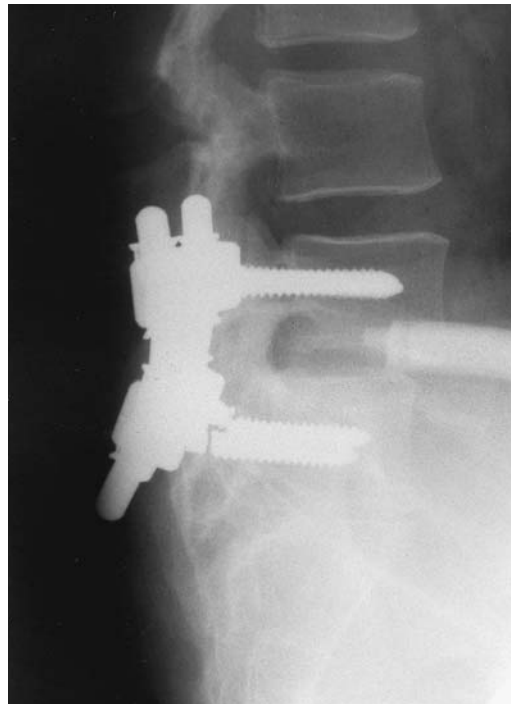


Fig. 3d

Case 2. Figure 3a – Lateral radiograph of the lumbosacral spine at the time of injury showing forward dislocation of the fifth lumbar vertebra on the sacrum. Figure 3b – Posterior view of a three-dimensional CT reconstruction showing interlocking of the left lumbosacral facet and fracture of the right superior sacral facet. Figure 3c – Lateral radiograph of the lumbosacral spine on the day of surgery. Figure 3d – Lateral radiograph 6.75 years after surgery, showing the narrowed L5/S1 disc space and breakage of the screws inserted into the pedicles of S1.

dimensional CT reconstruction showed bilateral lumbosacral facet interlocking (Fig. 2b) without fracture of the facet. The patient was referred to our hospital 24 weeks after the injury, which was judged to be type 2, and had posterior decompression and posterolateral fusion using

pedicle screws, followed by anterior interbody fusion five weeks later. A severely disrupted L5/S1 disc was revealed during surgery and removed. The pain in the low back and right thigh disappeared after operation, but the bowel and bladder dysfunction had not recovered four years later.

Case 2. A 22-year-old man complained of severe pain in the low back after jumping from a train. Radiographs showed forward dislocation of the fifth lumbar vertebra on the sacrum (Fig. 3a) and fractures of all the left lumbar transverse processes. Myelography revealed a dural injury. Three-dimensional CT reconstruction showed interlocking of the left lumbosacral facet and a fracture of the right superior sacral facet which was judged to be type 3 (Fig. 3b). Five weeks after the injury, posterior decompression and posterolateral fusion were carried out using pedicle screws (Fig. 3c). After 6.75 years, a lateral radiograph showed a narrowed L5/S1 disc space and breakage of the screws in the pedicles of S1 (Fig. 3d). Lateral radiographs in flexion and extension showed instability at the L5/S1 disc space. He still has mild pain in the low back.

Discussion

Wiltse and Rothman³⁴ classified lumbar and lumbosacral spondylolisthesis into six types. Their post-traumatic spondylolisthesis (type IV) was described as resulting from traumatic fracture of parts of the supporting bone other than the pars. They suggested that the slip would gradually occur over a period of weeks or longer, although it has since been reported that such late displacement is fairly rare.³² In our seven case studies, the slip occurred immediately at the time of severe injury, as had happened in most of the cases reviewed in the literature. Therefore the term 'L5 fracture-dislocation' seems to be more appropriate than 'traumatic spondylolisthesis.'

Injury pattern. There are various patterns of injury affecting the fifth lumbar vertebra. Analysis of our seven cases revealed four types, and review of the 50 reported cases revealed a fifth category.

The direction of dislocation was anterior in 51 of the 57 fracture-dislocations of L5, anterolateral in one,¹⁴ lateral in one,¹³ and posterior in four³⁰⁻³² (including case 4 from our series).

Fractures of the transverse processes of L5 were seen in 31 of the 57 patients, fracture of the spinous process of L5 in eight, and of the sacral promontory in ten.

In type 1, only eight of the 19 patients presented with neurological abnormality whereas 31 of the 38 other cases showed neurological damage. Present results indicated that type 1 was less severe than types 2, 3, 4 or 5 in terms of neurological involvement.

Treatment. Irrespective of the type of injury, fracture-dislocation of L5 is a three-column injury.³⁵ The cause is always a high-energy injury, resulting in severe spinal and ligamentous damage. As Hilibrand et al¹⁵ described, children may be managed by immobilisation in a cast,³ but conservative treatment is not effective in adolescents or adults because of severe instability.^{4,15} The pedicle screw system is useful for posterior reduction and fusion. With the high frequency of fractures of the transverse processes of

L5 (31 of the 57 patients) and the necessity for extensive posterior decompression (23 of the 57), posterolateral or posterior fusion alone may be insufficient to stabilise the lumbosacral junction. This is shown in our cases 2 and 4 and has been reported in the literature.^{12,14,20,22,23,32}

In a unilateral lumbosacral facet-dislocation (type 1), posterior instrumentation and fusion alone may be sufficient.^{5,6,16,18} Since the L5/S1 disc is disrupted, interbody fusion is required in types 2 and 3. Taking into consideration the trauma of major surgical invasion, posterior lumbar interbody fusion via a single approach may be preferable to the combined procedure. In our experience, posterior lumbar interbody fusion is a fairly difficult operation in fracture-dislocation of L5.

Although acute spondylolytic spondylolisthesis (type 4) seems radiologically similar to the standard isthmic spondylolisthesis, the former is always accompanied by disruption of the anterior and/or posterior ligamentous structures, resulting in much greater instability than in isthmic spondylolisthesis.¹⁵ We therefore believe that a combination of the anterior and posterior procedures is called for in such cases.

In type 5 (our case 4), the pedicle screw system is not effective for posterior reduction and fusion since it cannot be secured in the fractured body or pedicle of L5. Multi-level posterolateral or posterior fusion, using pedicle screws and interbody fusions of both L4 to L5 and L5 to S1, may be necessary in type 5.

Conservative treatment of fracture-dislocation of L5 is ineffective due to significant instability. Although the total number of cases in our own and the reviewed series is small, we propose a classification system in order to clarify the principles of the pathology and to enable operative treatment to be designed more efficiently and reliably.

No benefits in any form have been received or will be received from a commercial party related directly or indirectly to the subject of this article.

References

1. Abe E, Shimada Y, Minagawa H, Chiba M, Mizutani Y. Old lumbosacral unstable injury: report of three cases. *Orthop Surg Traumatol* 1991;34:319-23.
2. Aufranc OE, Jones WN, Harris WH. Traumatic spondylolisthesis. *JAMA* 1964;187:666-9.
3. Beguiristain J, Schweitzer D, Mora G, Pombo V. Traumatic lumbosacral dislocation in a 5-year-old boy with eight years' follow-up. *Spine* 1995;20:362-6.
4. Boger DC, Chandler RW, Pearce JG, Balciunas A. Unilateral facet dislocation at the lumbosacral junction: case report and literature review. *J Bone Joint Surg [Am]* 1983;65-A:1174-8.
5. Carl A, Blair B. Unilateral lumbosacral facet fracture-dislocation. *Spine* 1991;16:218-21.
6. Connolly PJ, Esses SI, Heggeness MH, Cook SS. Unilateral facet dislocation of the lumbosacral junction. *Spine* 1992;17:1244-8.
7. Das De S, McCreath SW. Lumbosacral fracture-dislocations: a report of four cases. *J Bone Joint Surg [Br]* 1981;63-B:58-60.
8. Davis AA, Carragee EJ. Bilateral facet dislocation at the lumbosacral joint: a report of a case and review of literature. *Spine* 1993;18:2540-4.
9. Dewey P, Browne PSH. Fracture-dislocation of the lumbo-sacral spine with cauda equina lesion: report of two cases. *J Bone Joint Surg [Br]* 1968;50-B:635-8.

10. **Fardon DF.** Displaced fracture of the lumbosacral spine with delayed cauda equina deficit. *Clin Orthop* 1976;120:155-8.
11. **Fujii E, Ootani K, Shibazaki K, Satomi K.** Surgical treatment for fracture-dislocation of the lumbo-sacral spine. *Orthop Surg Traumatol* 1984;27:803-7.
12. **Fujimoto Y, Kuroki H, Ueda H, et al.** Spinal injuries of middle, lower lumbar spine and lumbosacral junctions. *Nishimihon Sekitsui Kenkyukai* 1988;14:131-7.
13. **Fukui Y, Suzuki N, Hamano Y, Miyagawa J, Fukimoto T.** A case report of lateral dislocation of lumbosacral spine. *Rinsho Seikei Geka* 1986;21:1183-8.
14. **Herron LD, Williams RC.** Fracture-dislocation of the lumbosacral spine: report of a case and review of the literature. *Clin Orthop* 1984; 186:205-11.
15. **Hilibrand AS, Urquhart AG, Graziano GP, Hensinger RN.** Acute spondylolytic spondylolisthesis: risk of progression and neurological complications. *J Bone Joint Surg [Am]* 1995;77-A:190-6.
16. **Horii M, Watanabe T, Hase H, et al.** Fracture-dislocation of the lumbosacral spine: three case reports. *Seikeigeka* 1985;36:1849-53.
17. **Kinoshita H, Tokai T, Ito A, Kawanishi D.** Study on traumatic spondylolisthesis. *Seikeigeka* 1969;20:977-85.
18. **Kramer KM, Levine AM.** Unilateral facet dislocation of the lumbosacral junction: a case report and review of the literature. *J Bone Joint Surg [Am]* 1989;71-A:1258-61.
19. **Maeda K, Takahashi J, Kobayashi K, et al.** Clinical results of middle and lower lumbar spinal injuries. *JJOTM* 1989;37:727-33.
20. **Minatani N, Yumoto Y, Fujioka F, Oouchi E, Miyasaka H.** Fracture-dislocation of the lumbosacral spine: report of a case and review of the literature. *Kanto Seikeisaigai Gakkai Zasshi* 1985;16: 177-81.
21. **Miz GS, Engler GL.** Unilateral dislocation of a lumbosacral facet. *Spine* 1988;13:956-7.
22. **Morris BDA.** Unilateral dislocation of a lumbosacral facet: a case report. *J Bone Joint Surg [Am]* 1981;63-A:164-5.
23. **Murayama Y, Yamaoka H, Otsuka K, Ouchi E, Yagi R.** Fracture dislocation of the fifth lumbar spine: a case report. *Kanto Seikeisaigai-geka Gakkai Zasshi* 1978;9:283-6.
24. **Newell RL.** Lumbosacral fracture-dislocation: a case managed conservatively, with return to heavy work. *Injury* 1977;9:131-4.
25. **Okajima Y, Motegi M, Kinoshita K, et al.** Injuries of the lower lumbar spine. *Seikeigeka* 1986;37:707-18.
26. **Samberg LC.** Fracture-dislocation of the lumbosacral spine: a case report. *J Bone Joint Surg [Am]* 1975;57-A:1007-8.
27. **Van Savage JG, Dahners LE, Renner JB, Baker CC.** Fracture-dislocation of the lumbosacral spine: case report and review of the literature. *J Trauma* 1992;33:779-84.
28. **Shirado O, Kaneda K, Sato S, Abumi K.** Surgical treatment of fracture-dislocation at the lumbosacral junction. *East Jpn J Clin Orthop* 1994;6:280-4.
29. **Zoltan JD, Gilula LA, Murphy WA.** Unilateral facet dislocation between the fifth lumbar and first sacral vertebrae: case report. *J Bone Joint Surg [Am]* 1979;61-A:767-9.
30. **Finkelstein JA, Hu RW, Al-Harby T.** Open posterior dislocation of the lumbosacral junction: a case report. *Spine* 1996;21:378-80.
31. **Gertzbein SD.** Posterior dislocation of the lumbosacral joint: a case report. *J Spinal Disord* 1990;3:174-8.
32. **Steinitz DK, Alexander DI, Leighton RK, O'Sullivan JJ.** Late displacement of a fracture dislocation at the lumbosacral junction: a case study. *Spine* 1997;22:1024-7.
33. **Ohki I, Mikanagi K, Ohi Y, et al.** Reduction and fixation of severe spondylolisthesis with 'Ohki's wire reduction device'. *Kanto Seikeisaigai Gakkai Zasshi* 1977;8:240-3.
34. **Wiltse LL, Rothman SLG.** Classification, diagnosis and natural history. In: Weinstein JN, Wiesel SW, eds. *The lumbar spine*. Philadelphia: W. B. Saunders Company, 1990:471-99.
35. **Denis F.** The three column spine and its significance in the classification of acute thoracolumbar spinal injuries. *Spine* 1983;8:817-31.