

# Lateral Extracavitary vs Costotransversectomy Approaches to the Thoracic Spine: Reflections on Lessons Learned

Daniel Lubelski, BA\*‡§  
 Kalil G. Abdullah, MD\*‡§  
 Thomas E. Mroz, MD\*‡§  
 John H. Shin, MD¶  
 Matthew D. Alvin, MA\*||  
 Edward C. Benzel, MD\*‡§  
 Michael P. Steinmetz, MD||#

\*Cleveland Clinic Center for Spine Health and §Department of Neurological Surgery, Cleveland Clinic, Cleveland, Ohio; ‡Cleveland Clinic Lerner College of Medicine, Cleveland, Ohio; ¶Department of Neurosurgery, Massachusetts General Hospital, Boston, Massachusetts; ||Case Western Reserve University School of Medicine, Cleveland, Ohio; #Department of Neurosciences, MetroHealth Medical Center, Cleveland, Ohio

#### Correspondence:

Michael P. Steinmetz, MD,  
 Department of Neurological Surgery,  
 MetroHealth Medical Center,  
 2500 MetroHealth Dr,  
 Cleveland, OH 44109.  
 E-mail: msteinmetz@metrohealth.org  
 Daniel Lubelski, BA,  
 Center for Spine Health,  
 Department of Neurological Surgery,  
 Cleveland Clinic,  
 9500 Euclid Avenue, S-40,  
 Cleveland, OH 44195.  
 E-mail: dlubelski@gmail.com

Received, April 17, 2012.

Accepted, August 9, 2012.

Published Online, August 31, 2012.

Copyright © 2012 by the  
 Congress of Neurological Surgeons

**BACKGROUND:** The lateral extracavitary approach (LECA) and costotransversectomy (CTE) are 2 dorsolateral approaches that avoid entrance into the pleural cavity and facilitate ventral decompression. The indications and outcomes of each of these approaches have not been fully defined in the literature.

**OBJECTIVE:** To assess the techniques, indications, and complications associated with the LECA and CTE approaches to the thoracic spine.

**METHODS:** A retrospective analysis was performed on all patients who underwent LECA and CTE between 2000 and 2009 at our institution.

**RESULTS:** A total of 54 patient charts were reviewed (19 LECA, 35 CTE). Indications for operation included disk herniation, trauma, tumor, osteomyelitis, and scoliosis/kyphosis. Osteomyelitis was treated significantly more often with LECA (47%) than with CTE (9%;  $P = .002$ ). Mean blood loss was 2134 mL and 1556 mL ( $P = .3$ ) in LECA and CTE, respectively, and hospital stay was 17.2 days for LECA and 9.8 days for CTE ( $P = .07$ ). Thirteen LECA patients (68%) and 19 CTE patients (54%;  $P = 1.0$ ) had preoperative or postoperative complications.

**CONCLUSION:** LECA was used more often to treat complex pathologies such as osteomyelitis and trended toward significance for more frequent use in extensive procedures involving 1- or 2-level corpectomies. As can be expected, CTE was associated with slightly less blood loss and a shorter hospital stay compared with the more extensive LECA operation. Adverse outcomes occurred with similar frequency for CTE and LECA.

**KEY WORDS:** Complications, Costotransversectomy, Indications, Lateral extracavitary, Thoracic spine

*Neurosurgery* 71:1096–1102, 2012

DOI: 10.1227/NEU.0b013e3182706102

www.neurosurgery-online.com

The number and variety of surgical approaches to the thoracic spine have increased over the past several decades. Each of these approaches requires expertise with the specific technique, and each approach is associated with its own complication profile. Operative treatment for neoplasm, disk herniation, fracture/trauma, or infection requires thorough preoperative planning to access the site of the lesion and to determine the optimal approach. The lateral extracavitary approach (LECA) and costotransversectomy (CTE) are 2 dorsolateral approaches that avoid entrance into the pleural cavity and

facilitate ventral decompression. In addition, both facilitate dorsal fixation and fusion through a single incision. Although they are distinct procedures, because of their similarity, the terms LECA and CTE are often used interchangeably in the clinical setting. LECA provides a more optimal ventral exposure than CTE but at the expense of more extensive muscle, rib dissection, and incision. In the present study, LECA and CTE are distinguished on the basis of extent of rib resection and location of muscle dissection. Brief summaries are provided that compare the surgical technique of the 2 approaches. Because thoracic spinal disease is relatively uncommon, the literature, as expected, is relatively unclear regarding the advantages and disadvantages of each approach and their long-term outcomes. The goals of the present retrospective cohort

**ABBREVIATIONS:** CTE, costotransversectomy; LECA, lateral extracavitary approach; LOS, length of hospital stay

review are to define the outcomes associated with the LECA and CTE approaches and to help refine the operative approach decision-making process for ventral thoracic spine pathology.

## PATIENTS AND METHODS

### Study Sample

A retrospective chart review was performed for all Cleveland Clinic patients undergoing LECA or CTE between January 2000 and December 2009. The electronic medical record system was queried to retrieve patient data consistent with the inclusion criteria. Data were collected and managed with REDCap<sup>1</sup> (Research Electronic Data Capture).

Consecutive patients who had undergone thoracic spine surgery via one of the aforementioned approaches were identified. Indications for operation, as noted by the operating surgeon, included disk herniation, fracture/trauma, osteomyelitis, scoliosis, and kyphosis. Ten spine surgeons from 1 institution operated on all patients, with the bulk of patients (75%) being operated on by 4 of the surgeons. Operative details were collected, including vertebral level/levels, unilateral vs bilateral, whether instrumentation was used, the type of bone graft used, and whether rib was resected. We also identified whether corpectomy and/or discectomy were performed. Postoperative complications and follow-up time were recorded for all patients. Also recorded were the presenting symptoms (eg, back/leg pain, spasticity, paraparesis, myelopathy, bladder retention), number of previous spine surgeries, and other outcomes such as intraoperative complications (eg, dural tear, cerebrospinal fluid leak, nerve injury), blood loss, and length of hospital stay (LOS).

Patient characteristics were recorded for consideration in the regression modeling. These data included sex, age, body mass index, chronic conditions (hypertension, hyperlipidemia, coronary artery disease, diabetes mellitus), smoking status, and year of surgery.

### Statistical Analysis

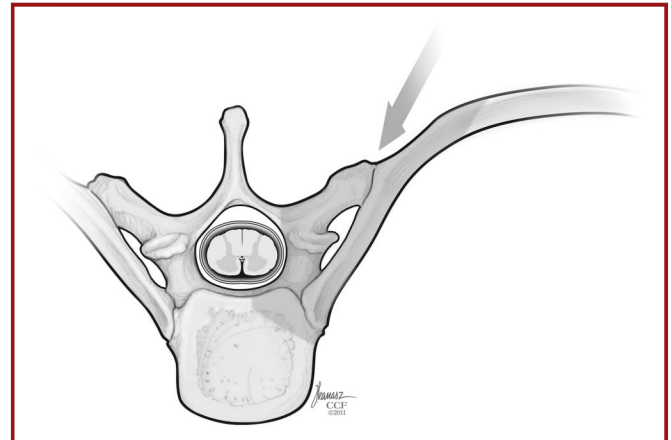
All data were analyzed with JMP 9.0 (SAS Institute Inc, Carey, North Carolina; 2007). Descriptive statistics summarizing patient characteristics were presented as counts with percents or means with standard errors when appropriate. For comparisons of continuous data, the Student *t* test for independent samples was used. Categorical variables were compared by use of the Fisher exact test or Pearson  $\chi^2$ . All values of  $P < .05$  were considered statistically significant.

### Procedures

We used the operative notes in each record to confirm the Current Procedural Terminology code that was chosen by the operating surgeon. The distinction between CTE and LECA was based on the extent of rib resection (CTE,  $\leq 6$  cm; LECA,  $\geq 6$  cm of rib) and/or surgical muscle dissection (CTE, access medial to erector spinae muscles; LECA, access lateral to or through the erector spinae muscles). Brief descriptions of the surgical approaches are provided below.

With CTE (Figure 1), the patient is placed in the prone position. The skin incision is typically midline, and the dissection is medial to the erector spinae muscles. The proximal 4 to 6 cm of rib, starting at the rib head, is removed.<sup>2,3</sup> This is to be differentiated from laminectomy with a dorso-lateral, often transpedicular, exposure with which minimal rib is resected.

In contrast, LECA (Figure 2) involves exposure that is more lateral than the CTE with retraction or transection of the paraspinous thoracic musculature. After the patient is placed in either the prone or three-quarter



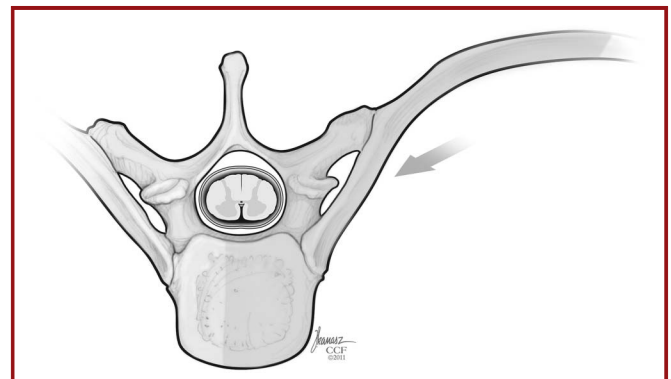
**FIGURE 1.** Artist's depiction of the costotransversectomy approach. The arrow indicates the trajectory that can be obtained with the approach, and the highlighted region identifies spinal elements that are typically resected.

prone position, a curvilinear or “hockey stick”-shaped incision is typically made (straight midline and L-shaped incisions can also be made). This incision is typically begun about 3 levels above the site of the lesion and ends 2 levels below. After retraction of the skin and fascia, a plane is developed in the paraspinous musculature.<sup>4,5</sup> Transection involves incising the paraspinous muscles to obtain sufficient exposure and then resuturing at the thoracodorsal fascia before closure. Retraction involves mobilization of the paraspinous musculature and reflection medially; thus, dissection is lateral to the muscle mass. With this technique, 6 to 12 cm of the underlying rib, starting at the rib head, is removed.<sup>6</sup> Both LECA and CTE allow ventral decompression and dorsal stabilization via a single dorsal exposure, thereby minimizing the need for 2 (ventral transpleural and dorsal) operations.

## RESULTS

### Patient Demographics

We reviewed a total of 54 patients (19 cases of LECA and 35 CTE) for a mean follow-up of  $25.7 \pm 5.35$  and  $20.5 \pm 4.08$



**FIGURE 2.** Artist's depiction of the lateral extracavitary approach. The arrow indicates the trajectory that can be obtained with the approach, and the highlighted region identifies spinal elements that are typically resected. Note that this approach includes greater rib resection and a more lateral trajectory than the costotransversectomy.

months, respectively ( $P = 0.5$ ; Table 1). The average age for all patients was 53.7 years. The percent of male patients who were operated on was 74% and 49% for LECA and CTE, respectively. Patients were well matched on all other characteristics recorded, and no clinically significant differences existed between groups.

### Operation and Hospital Course

The indications for operation are shown in Table 2. No statistically significant differences existed between the surgical approaches in terms of operative indications. The exception to this was that osteomyelitis was the primary surgical indication in 47% (9 of 19) of the operations in which LECA was used. This was significantly greater than for CTE, for which osteomyelitis was a relatively uncommon indication, occurring in only 8.6% (3 of 25;  $P = .01$ ).

Operative details are shown in Table 3; mean blood loss was 2134.6 mL for LECA and 1555.9 mL for CTE ( $P = .3$ ). Average LOS trended toward significance because patients required longer hospital stay with LECA (17.2 days) than they did with CTE (9.8 days;  $P = .07$ ).

### Adverse Outcomes

There was no statistically significant difference ( $P > .05$ ) in total number of complications after surgery between patients who underwent LECA (13 patients with complications, 68%) compared with those who underwent CTE (19 complications, 54%; Table 4). Ten patients (53%) undergoing LECA and 12 patients (34%) undergoing CTE experienced intraoperative or

**TABLE 2. Indication for Operation<sup>a</sup>**

Indication	LECA		CTE		<i>P</i> <sup>b</sup>
	n	%	n	%	
Disk herniation	1	5	8	23	.1
Fracture/trauma	2	11	9	26	.3
Tumor	7	37	16	46	.6
Osteomyelitis	9	47	3	9	.002 <sup>c</sup>
Scoliosis/kyphosis	4	21	7	20	1.0

<sup>a</sup>CTE, costotransversectomy; LECA, lateral extracavitary approach. Some patients had multiple indications for surgery and thus the number of individual indications is larger than the sum of patients in each sample.

<sup>b</sup>Pearson  $\chi^2$  test.

<sup>c</sup>Significant value,  $P \leq .05$ .

perioperative complications ( $P = .2$ ). Patients who underwent LECA experienced a rate of postoperative complications similar to that in patients who underwent CTE, occurring in 42% (8 of 19) and 34% (12 of 35) of patients, respectively ( $P = .8$ ). There were no significant differences in the rates of individual complications between the 2 approaches. There were 2 deaths among all patients, both occurring in CTE patients ( $P = .5$ ). Performing a multivariable logistic regression for demographic covariates (sex, hypertension, coronary artery disease, current smoking status) did not identify any findings that were statistically significant.

Table 5 describes the total number of subjects with complications by both their indication for operation and surgical approach. All patients (100%) who underwent LECA for either fracture of scoliosis/kyphosis had a postoperative complication.

## DISCUSSION

### Complications

Historically, the most common surgical treatment for thoracic compressive pathology was laminectomy. This approach was associated with significant morbidity and mortality and spurred the evolution of dorsal, lateral, and ventral surgical approaches to the thoracic spine. Since then, various studies have been published comparing the advantages, disadvantages, and postoperative outcomes of ventral and dorsal approaches to the thoracic spine.<sup>7-12</sup> Much of the present literature consists of studies with small sample sizes, comparing only a limited number of approaches and a limited number of surgical indications. Moreover, the specifics of the surgical procedures (ie, bilateral vs unilateral exposure, the use of instrumentation, type of graft or reconstructive method, corpectomy/discectomy, and vertebral levels operated) have not been defined clearly. In the present study, we have attempted to answer many of these questions and to provide surgical and outcome information to address these deficiencies.

The only difference between the approaches regarding the indications for operation was that LECA was associated with

**TABLE 1. Demographic Information<sup>a</sup>**

	LECA	CTE	<i>P</i> <sup>b</sup>
n	19	35	
Age, y	53.7 ± 3.1	53.74 ± 2.3	1.0
Male, n (%)	14 (74)	17 (49)	.1
BMI, kg/m <sup>2</sup>	31.0 ± 1.8	28.2 ± 1.3	.3
Chronic diseases, n (%)			
Hypertension	11 (58)	9 (26)	.04 <sup>c</sup>
Hyperlipidemia	7 (37)	5 (14)	.09
CAD	2 (11)	0 (0)	.1
Diabetes mellitus	5 (26)	3 (9)	.1
Smoking history, n (%)	6 (32)	9 (26)	.8
Smoking, pack-y	15 ± 4.9	11 ± 4.0	.5
Current smoker, n (%)	5 (26)	6 (17)	.5
Previous spine surgery, n (%)			
1 Previous	4 (21)	7 (20)	1.0
2+ Previous	3 (16)	3 (9)	.7
Follow-up time, mo	25.7 ± 5.9	20.5 ± 4.5	.5

<sup>a</sup>BMI, body mass index; CAD, coronary artery disease; CTE, costotransversectomy; LECA, lateral extracavitary approach. Values are mean ± SE for continuous variables.

<sup>b</sup>The *t* test, analysis of variance, or Kruskal-Wallis test was used for continuous variables; Fisher exact test or Pearson  $\chi^2$  was used for categorical variables

<sup>c</sup>Significant value,  $P \leq .05$ .

TABLE 3. Operation Details <sup>a</sup>			
	LECA (n = 19)	CTE (n = 35)	P <sup>b</sup>
Levels, n	1.74 ± 0.18	1.43 ± 0.13	.2
Approach, n (%) <sup>d</sup>			
Bilateral	6 (32)	9 (26)	.8 <sup>c</sup>
Unilateral	13 (68)	26 (74)	
Right (only)	8 (62)	10 (42)	.3 <sup>c</sup>
Left (only)	5 (38)	14 (58)	
Instrumented	14 (74)	24 (69)	.8
Substrate used, n (%)			
ICBG	5 (26)	4 (11)	.3
Allograft	2 (11)	5 (14)	1.0
Rib resection	19 (100)	33 (94)	.5
Rib autograft	9 (47)	13 (37)	.6
Corpectomy (No. of vertebra), n (%)			
1	6 (32)	18 (51)	.1
2+	7 (37)	5 (14)	
Diskectomy (No. of disks), n (%)			
1	2 (11)	8 (23)	.5
2+	2 (11)	2 (6)	
Blood loss, mL	2134.6 ± 397.5	1555.9 ± 347.6	.3
Hospital stay, d	17.2 ± 15.3	9.8 ± 8.8	.07

<sup>a</sup>CTE, costotransversectomy; ICBG, iliac crest bone graft; LECA, lateral extracavitary approach.

<sup>b</sup>Significant value  $P \leq .05$ .

<sup>c</sup>Right (only) and left (only) percentages are presented as the percent of total unilateral procedures for posterior or anterior.

<sup>d</sup>P values of bilateral/unilateral values represent comparisons between LECA and CTE.

a significantly higher percentage of cases (47%) for osteomyelitis compared with CTE (8.6%;  $P = .002$ ). This reflects surgeon preference at this institution. In cases of osteomyelitis, neurological decompression is often required with a corpectomy and reconstruction of the ventral column of the spine. Single corpectomies were performed slightly more frequently via CTE (51%, 18 of 35) than in LECA (32%, 6 of 19), whereas multiple corpectomies were more often performed via LECA (37%, 7 of 19) compared with CTE (14%, 5 of 35;  $P = .1$ ). This is explained logically by the fact that LECA provides wider (greater) exposure and is likely better suited for more extensive pathology. Such exposure, however, is limited to 2 or, at the most, 3 levels.

Both blood loss and LOS were greater in patients who underwent LECA compared with CTE (blood loss, 2135 and 1556 mL, respectively; LOS, 17 and 10 days, respectively). Although these differences were not statistically significant, it is likely due to the small sample size and the high standard error for both variables. The inherent morbidity associated with the extensive dorsolateral exposure of the LECA is well known; thus, the approach must be considered carefully in elderly patients and in those with extensive comorbidities.<sup>13,14</sup> Although it is possible that the increased blood loss and LOS are due to the inherent morbidity associated with treating osteomyelitis (which was treated more often by LECA than CTE in this series), subsequent analyses, both with and without osteomyelitis included, demonstrated that LECA remained a more morbid procedure in all cases.

Complications (both perioperative and postoperative) were observed in 68% (13 of 19) of LECA patients and in 54% (19 of 35) of CTE patients ( $P = .4$ ). The rates identified in the present study are corroborated by the historical incidence found in the literature. LECA and CTE are extensive procedures with inherent risks; they should be used only after a careful consideration of less morbid operations.<sup>15</sup> The historical complication rates for LECA range from 12% to 55%.<sup>10,13,15-17</sup> This is comparable to the 54% rate identified in the present study. CTE had a similar complication rate (54%) in this series. This is compared with the historical incidence of complications, which ranges from 13% to 38%.<sup>18-21</sup> If one considers only the more severe complications (ie, death, infection, pulmonary effusion, required tracheotomy/thoracostomy) in this series, there were 5 such complications associated with LECA (26%) and 12 with CTE (34%;  $P > .05$  [NS]). These complication rates fall in the aforementioned ranges of previously reported complications.

Dividing the complications into perioperative and postoperative complications also demonstrated no difference between LECA and CTE. Total perioperative complications occurred in 53% and 34% ( $P = .2$ ) for LECA and CTE respectively; and total postoperative complications occurred in 42% and 34% ( $P = .8$ ) for LECA and CTE, respectively. Alpantaki and colleagues,<sup>22</sup> in a review of the literature, created an algorithm for the optimal surgical approach based on the neurological compromise, injury status of the dorsal ligamentous complex, kyphotic angle, and vertebral height loss. The results of their review and several other prospective studies

**TABLE 4. Complications<sup>a</sup>**

Complication	LECA (n = 19)		CTE (n = 35)		P
	n	%	N	%	
<b>Total intraoperative complications</b>	10	53	12	34	.2
Required thoracostomy	2	11	1	3	.3
Dural tear	0	0	1	3	1.0
CSF leak	1	5	1	3	1.0
Blood transfusion	3	16	4	11	.7
Nerve injury	1	5	0	0	.4
Tracheotomy	0	0	2	6	.5
DVT/PE	2	11	5	14	1.0
UTI	1	5	0	0	.4
<b>Total postoperative complications</b>	8	42	12 <sup>b</sup>	34	.8
Radiculitis	1	5	1	3	1.0
Atelectasis	0	0	1	3	1.0
SOB	1	5	1	3	1.0
Pleural tear	1	5	1	3	1.0
Effusion	2	11	6	17	.7
Infection	2	11	6	17	1.0
Pseudoarthrosis	1	5	1	3	1.0
Reoperation	2	11	3	9	1.0
Death	0	0	2	6	.5
Total subjects with complications	13	68	19	54	.4

<sup>a</sup>CSF, cerebrospinal fluid; CTE, costotransversectomy; DVT/PE, deep vein thrombosis/pulmonary embolism; LECA, lateral extracavitary approach; SOB, shortness of breath; UTI, urinary tract infection.

<sup>b</sup>Several patients had > 1 postoperative complications and thus the sum of individual complications exceed the total number reported.

suggest that ventral and dorsal approaches have similar complication profiles and long-term outcomes.<sup>11,23-26</sup>

Despite LECA requiring increased rib resection, operative time, blood loss, and LOS, LECA and CTE had similar complication rates in this study. We believe that both are effective methods for treating ventral pathology in the thoracic spine. LECA is, at times, avoided because of concerns about increased morbidity. The data presented here suggest that in properly selected patients, LECA does not result in a greater number of complications compared with CTE. Therefore, we suggest that surgeons choose the best

**TABLE 5. Complications by Indication<sup>a</sup>**

Indication	LECA		CTE		P <sup>b</sup>
	n	%	n	%	
Disk herniation	0	0	2	25	1.0
Fracture	2	100	3	33	.2
Tumor	2	29	5	31	1.0
Osteomyelitis	4	44	1	33	1.0
Scoliosis/kyphosis	4	100	4	57	.2

<sup>a</sup>CTE, costotransversectomy; LECA, lateral extracavitary approach.

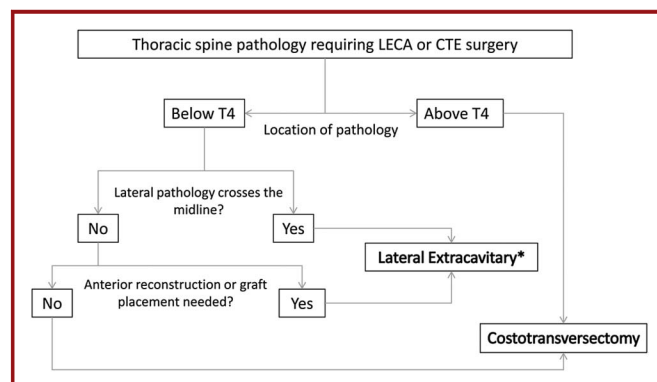
<sup>b</sup>Fisher exact test.

approach for the patient and the associated pathology rather than the theoretical morbidity associated with the operation.

**Surgeons’ Reflections on Lessons Learned**

LECA and CTE differ predominantly with regard to the trajectory by which the ventrolateral spine is approached. With LECA, the approach is beneath or through the paraspinous (erector spinae) muscles; with CTE, the approach is medial to these muscles. This distinction is important in many cases, particularly if a long multilevel exposure is used, which necessitates the detachment and mobilization of the erector spinae muscles. Such mobilization may result in paraspinous muscle devitalization/denervation. Regardless, with appropriate surgical technique, adequate and safe dural sac (spinal cord) decompression can be attained via CTE for most of the pathologies addressed in this study. On the other hand, the “side” of the paraspinous muscle (medial vs lateral) through which the spine is accessed is not as critical as the trajectory to the pathology achieved. Lateral retraction of the erector spinae muscles (CTE), particularly in thin patients, can provide an access trajectory similar to that achieved by the traditional LECA approach. Having noted this, the distinction between LECA and CTE becomes very blurry.

Many factors must be considered when deciding on the optimal approach. We have created an algorithm (Figure 3) describing the surgical decision-making process. It should be noted that this algorithm directs the surgeon toward either a unilateral CTE or a unilateral LECA. However, a bilateral CTE can enhance access to and facilitate reconstruction of the entire ventral column (ie, circumferential cord decompression, more complete end-plate preparation, and easier manipulation and deployment of the ventral structural grafts/cages). However, this is associated with the need for bilateral rib resection, greater muscle dissection, and nerve root and vascular dissection, along with destabilization. The following components of the algorithm are based on reflections on several



**FIGURE 3.** Decision-making algorithm based on characteristics of the patient and spinal pathology to assist choosing between a lateral extracavitary approach (LECA) and a costotransversectomy (CTE). \*In addition to the LECA, a ventral approach via a thoracotomy can be used for these patients/pathologies. LECA is an alternative to ventral approaches.

decades of experience by the senior authors (E.C.B., M.P.S., T.E.M.). Because LECA and CTE are 2 operations on the same spectrum and because the data from the present study indicate similar complication rates and outcomes, the senior authors are able to provide insight regarding their personal experience and the lessons learned from hundreds of LECA and CTE cases over the decades. The previously noted lack of clear distinction between LECA and CTE, however, relegates this algorithm to the realm of the theoretical rather than the objective clinical. Thus, the decision-making process becomes very fluid and individual.

### Location of Pathology: Ventral vs Ventrolateral

Location of pathology with respect to the dural sac or spinal cord is probably the most important factor in the decision-making process. Both CTE and LECA permit access to the ventral dural sac and spinal cord. In general, lateral pathology that ends at the midline (ie, does not cross the midline) may be ideally handled with CTE. However, if the pathology crosses midline, LECA theoretically provides a slightly better trajectory for visualization. One can still perform a CTE, but the contralateral ventral decompression and end-plate preparation must be done with tactile feedback, similar to the methods used during transforaminal lumbar interbody fusion. Of note, bilateral CTE allows direct access to the ventral pathology. Pan-ventral exposure can indeed often be achieved via a bilateral CTE approach. Again, the spectrum of pathologies, individual anatomic characteristics (eg, body mass index), and operative techniques dictate that the decision-making process be individualized. In 1 surgeon's hands, LECA may be most appropriate for a given pathology, whereas CTE may be most appropriate in another's hands.

### Need for Ventral Column Reconstruction

Dorsolateral approaches are often chosen to treat pathology that requires not only ventral decompression but also reconstruction of the ventral column of the spine, frequently involving corpectomy. Although corpectomy may be effectively performed via LECA or CTE, the placement of a ventral bone graft or cage may be difficult through a limited approach. Restrictions regarding the placement of a cage or graft after decompression (LECA or CTE) include the spinal cord medially, the rib cage laterally, and the adjacent rib (heads) rostrally and caudally. These anatomic barriers limit the ease of placement. In our experience, LECA, with its trajectory lateral to the paraspinal musculature, when accompanied by extensive lateral rib resection, significantly facilitates the placement of a cage or bone graft. If a CTE is performed and ventral reconstruction with a cage or structural bone graft is planned, it is critical to resect the entire proximal rib (ie, the rib in the region of the attachments to the vertebral body and transverse process at the costovertebral and costotransverse joints) so that the parietal pleura is exposed and mobile. The latter is then easily depressed with a malleable retractor laterally and ventrally, a maneuver that substantially improves access to the space through which a cage/graft can be effectively deployed.

The choice of the ventral reconstruction technique is important. Although the use of structural bone grafts is ideal from a biological perspective, the amount of "interference fit" that can be attained is limited. One must always remember to use the dorsal instrumentation and to compress across the reconstructed segment with the dorsal instrumentation to maximize the structural integrity and chances for fusion and to avoid graft dislodgement.

### Thoracic Spine Level: Below or Above T4

The level of the spine must be considered for a CTE or LECA. When operating between levels T2 to T4, the use of LECA (as traditionally defined; see above) may be difficult because of the presence of the scapula, the associated periscapular musculature, and the confines created by the increasingly smaller-diameter rib cage. Using the LECA in this region requires a lateral approach through the rhomboid and trapezius muscles and yields a small window through which to operate. In contrast, the access provided by the CTE approach in this periscapular region facilitates an operative exposure that is adequate, with much less exposure-related morbidity. Often, a bilateral approach can add substantially to the ventral exposure, as already discussed.

LECA and CTE are 2 distinct operative approaches to the thoracic spine. Although they may be considered to be approaches that sit on a continuum that encompasses approaches that range from true dorsal to true ventral approaches, they indeed accomplish similar operative goals. Therefore, the type and location of the pathology and the physical characteristics of the patient should dictate the type of procedure used, including consideration of the nuances of each approach.

Several newer, minimally invasive procedures have also been described. These include the minimally invasive transposas interbody fusion approaches and the minimally invasive LECA approach.<sup>27,28</sup> These approaches are purported to have decreased operative time, reduced blood loss, less tissue dissection, less perioperative pain, and earlier mobility.<sup>29</sup> These approaches, however, have not yet gained widespread acceptance for several reasons. First, no randomized studies have demonstrated equivalence or superiority of the minimally invasive approaches compared with the open approaches. Additionally, the benefit of the minimally invasive approaches in decompressing and reconstructing the ventral thoracic spine needs to be clinically demonstrated.<sup>30</sup> With increasing use of these minimally invasive procedures and demonstration of their safety and efficacy, they can offer the potential to surgically treat a great number of thoracic pathologies with the advantages of being minimally invasive and extrapleural.

The limitations of this study are well recognized. It is a retrospective review of a relatively small cohort of patients with substantial heterogeneity of surgical pathology who were treated by 10 surgeons. Still, this report represents the largest series of patients treated with these techniques. Looking forward, it will be important to prospectively define an algorithm for optimal surgical care of ventral thoracic pathology that is derived by a careful review of indications, intraoperative and perioperative morbidity, patient

comorbidities, and reconstructive options. Perhaps more important, however, is the consideration of reflections based on experience.

## CONCLUSION

Both LECA and CTE are effective options for the treatment of ventral and ventrolateral pathology of the thoracic spine. In this study, LECA was associated with increased blood loss and longer hospital stays than CTE. The choice of one over the other should be predicated on surgeon expertise, the extent and type of pathology, and the reconstruction requirements. Prospective studies are required to further define the indications, merits, and drawbacks of each technique.

## Disclosures

Institutional Review Board approval (study No. 11-321) was obtained before the start of the study. The authors have no personal financial or institutional interest in any of the drugs, materials, or devices described in this article.

## REFERENCES

- Harris PA, Taylor R, Thielke R, et al. Research electronic data capture (REDCap): a metadata-driven methodology and workflow process for providing translational research informatics support. *J Biomed Inform.* 2009;42(2):377-381.
- Herkowitz HN, Garfin SR, Eismont FJ, Bell GR, Balderston RA. *Rothman-Simeone The Spine*. Vol 2. 5th ed. Philadelphia, PA: Saunders; 2006.
- Benzel EC. *Spine Surgery: Techniques, Complication, Avoidance, and Management*. Philadelphia, PA: Gulf Professional Publishing; 2005.
- Lubelski D, Abdullah KG, Steinmetz MP, et al. Lateral extracavitary, costotransversectomy, and transthoracic thoracotomy approaches to the thoracic spine: review of techniques and complications [published online ahead of print December 2, 2011]. *J Spinal Disord Tech*. doi:10.1097/BSD.0b013e31823f3139.
- Larson SJ, Holst RA, Hemmy DC, Sances A Jr. Lateral extracavitary approach to traumatic lesions of the thoracic and lumbar spine. *J Neurosurg*. 1976;45(6):628-637.
- Stillerman CB, Weiss MH. Management of thoracic disc disease. *Clin Neurosurg*. 1992;38:325-352.
- Fessler RG, Sturgill M. Review: complications of surgery for thoracic disc disease. *Surg Neurol*. 1998;49(6):609-618.
- McCormick WE, Will SF, Benzel EC. Surgery for thoracic disc disease: complication avoidance: overview and management. *Neurosurg Focus*. 2000;9(4):e13.
- Mulier S, Debois V. Thoracic disc herniations: transthoracic, lateral, or posterolateral approach? A review. *Surg Neurol*. 1998;49(6):599-606; discussion 606-608.
- D'Aliberti G, Talamonti G, Villa F, et al. Anterior approach to thoracic and lumbar spine lesions: results in 145 consecutive cases. *J Neurosurg Spine*. 2008;9(5):466-482.
- Wood KB, Bohn D, Mehdod A. Anterior versus posterior treatment of stable thoracolumbar burst fractures without neurologic deficit: a prospective, randomized study. *J Spinal Disord Tech*. 2005;18(suppl):S15-S23.
- Xu R, Garcés-Ambrossi GL, McGirt MJ, et al. Thoracic vertebrectomy and spinal reconstruction via anterior, posterior, or combined approaches: clinical outcomes in 91 consecutive patients with metastatic spinal tumors. *J Neurosurg Spine*. 2009;11(3):272-284.
- Dietze DD Jr, Fessler RG. Thoracic disc herniations. *Neurosurg Clin N Am*. 1993;4(1):75-90.
- Benzel EC. The lateral extracavitary approach to the spine using the three-quarter prone position. *J Neurosurg*. 1989;71(6):837-841.
- Resnick DK, Benzel EC. Lateral extracavitary approach for thoracic and thoracolumbar spine trauma: operative complications. *Neurosurgery*. 1998;43(4):796-802; discussion 802-803.
- McCormick PC. Surgical management of dumbbell and paraspinous tumors of the thoracic and lumbar spine. *Neurosurgery*. 1996;38(1):67-74; discussion 74-75.
- Graham AW 3rd, Mac Millan M, Fessler RG. Lateral extracavitary approach to the thoracic and thoracolumbar spine. *Orthopedics*. 1997;20(7):605-610.
- Cybulski GR, Stone JL, Opanami O. Spinal cord decompression via a modified costotransversectomy approach combined with posterior instrumentation for management of metastatic neoplasms of the thoracic spine. *Surg Neurol*. 1991;35(4):280-285.
- Thorat JD, Rajendra T, Thirugnanam A, Ng IH. Single-stage posterior midline approach for dumbbell tumors of the thoracic spine, with intraoperative CT guidance. *Surg Neurol Int*. 2011;2:31.
- Wiggins GC, Mirza S, Bellabarba C, et al. Perioperative complications with costotransversectomy and anterior approaches to thoracic and thoracolumbar tumors. *Neurosurg Focus*. 2001;11(6):e4.
- Kim KD, Babbitt JD, Mimbs J. Imaging-guided costotransversectomy for thoracic disc herniation. *Neurosurg Focus*. 2000;9(4):e7.
- Alpantaki K, Bano A, Pasku D, et al. Thoracolumbar burst fractures: a systematic review of management. *Orthopedics*. 2010;33(6):422-429.
- Oner FC, Wood KB, Smith JS, Shaffrey CI. Therapeutic decision making in thoracolumbar spine trauma. *Spine (Phila Pa 1976)*. 2010;35(21 suppl):S235-S244.
- Reinhold M, Knop C, Beisse R, et al. Operative treatment of traumatic fractures of the thoracic and lumbar spinal column, part III: follow up data [in German]. *Unfallchirurg*. 2009;112(3):294-316.
- Reinhold M, Knop C, Beisse R, et al. Operative treatment of 733 patients with acute thoracolumbar spinal injuries: comprehensive results from the second, prospective, Internet-based multicenter study of the Spine Study Group of the German Association of Trauma Surgery. *Eur Spine J*. 2010;19(10):1657-1676.
- Verlaan JJ, Diekerhof CH, Buskens E, et al. Surgical treatment of traumatic fractures of the thoracic and lumbar spine: a systematic review of the literature on techniques, complications, and outcome. *Spine (Phila Pa 1976)*. 2004;29(7):803-814.
- Khoo LT, Smith ZA, Asgarzadeh F, et al. Minimally invasive extracavitary approach for thoracic discectomy and interbody fusion: 1-year clinical and radiographic outcomes in 13 patients compared with a cohort of traditional anterior transthoracic approaches. *J Neurosurg Spine*. 2011;14(2):250-260.
- Lidar Z, Lifshutz J, Bhattacharjee S, Kurpad SN, Maiman DJ. Minimally invasive, extracavitary approach for thoracic disc herniation: technical report and preliminary results. *Spine J*. 2006;6(2):157-163.
- Houten JK, Alexandre LC, Nasser R, Wollowick AL. Nerve injury during the transposas approach for lumbar fusion. *J Neurosurg Spine*. 2011;15(3):280-284.
- Smith JS, Ogden AT, Fessler RG. Minimally invasive posterior thoracic fusion. *Neurosurg Focus*. 2008;25(2):E9.

## Acknowledgments

We would like to acknowledge Joe Kanasz for his assistance and expertise with medical illustrations. We would also like to acknowledge all surgeons at the Center for Spine Health at our institution who operated on and treated the patients in the present study. We would like to thank Isador Lieberman, MD, currently at the Texas Back Institute, who treated a number of the patients in the present study.