

Surgical Strategy for Spinal Metastases

Katsuro Tomita, MD, PhD, Norio Kawahara, MD, PhD, Tadayoshi Kobayashi, MD, Akira Yoshida, MD, Hideki Murakami, MD, and Tomoyuki Akamaru, MD

Study Design. A new surgical strategy for treatment of patients with spinal metastases was designed, and 61 patients were treated based on this strategy.

Objectives. To propose a new surgical strategy for the treatment of patients with spinal metastases.

Summary of Background Data. A preoperative score composed of six parameters has been proposed by Tokuhashi et al for the prognostic assessment of patients with metastases to the spine. Their scoring system was designed for deciding between excisional or palliative procedures. Recently, aggressive surgery, such as total *en bloc* spondylectomy for spinal metastases, has been advocated for selected patients. Surgical strategies should include various treatments ranging from wide or marginal excision to palliative treatment with hospice care.

Methods. Sixty-seven patients with spinal metastases who had been treated from 1987–1991 were reviewed, and prognostic factors were evaluated retrospectively (phase 1). A new scoring system for spinal metastases that was designed based on these data consists of three prognostic factors: 1) grade of malignancy (slow growth, 1 point; moderate growth, 2 points; rapid growth, 4 points), 2) visceral metastases (no metastasis, 0 points; treatable, 2 points; untreatable, 4 points), and 3) bone metastases (solitary or isolated, 1 point; multiple, 2 points). These three factors were added together to give a prognostic score between 2–10. The treatment goal for each patient was set according to this prognostic score. The strategy for each patient was decided along with the treatment goal: a prognostic score of 2–3 points suggested a wide or marginal excision for long-term local control; 4–5 points indicated marginal or intralesional excision for middle-term local control; 6–7 points justified palliative surgery for short-term palliation; and 8–10 points indicated nonoperative supportive care. Sixty-one patients were treated prospectively according to this surgical strategy between 1993–1996 (phase 2). The extent of the spinal metastases was stratified using the surgical classification of spinal tumors, and technically appropriate and feasible surgery was performed, such as *en bloc* spondylectomy, piecemeal thorough excision, curettage, or palliative surgery.

Results. The mean survival time of the 28 patients treated with wide or marginal excision was 38.2 months (26 had successful local control). The mean survival time of the 13 patients treated with intralesional excision was 21.5 months (nine had successful local control). The mean survival time of the 11 patients treated with palliative surgery and stabilization was 10.1 months (eight had successful local control). The mean survival time of the patients with terminal care was 5.3 months.

Conclusions. A new surgical strategy for spinal metastases based on the prognostic scoring system is proposed. This strategy provides appropriate guidelines for treatment in all patients with spinal metastases. [Key words: decision making, prognosis, spinal metastasis, treatment strategy] **Spine 2001;26:298–306**

The surgical treatment of spinal metastases is controversial. Spine surgeons with oncologic backgrounds should be able to avoid recurrence of the tumor and to control spinal paralysis. Further, the surgeon must contribute to the patient's quality of life until the last moment. It therefore is very important to decide the treatment modality according to the patient's predicted survival period. Tokuhashi et al²⁷ proposed an original scoring system for the preoperative evaluation of metastatic spine tumor prognosis. Their scoring system is only valid for deciding whether to use either excisional or palliative procedures. Recently, aggressive surgery such as total *en bloc* spondylectomy has been advocated for spinal metastases.^{9,15,19,23,24,29,30} Oncologic concepts should be taken into consideration to achieve successful local control of the spine lesion. Although nonoperative treatment such as hospice care remains an important option, a surgical strategy including the whole range of operative options should be considered.

A new surgical strategy for spinal metastasis is proposed based on a prognostic scoring system to provide appropriate guidelines for treatment in all patients with spinal metastases.

Study Design. This study was composed of two phases; phase 1 (1987–1991) and phase 2 (1993–1996). During phase 1, the treatment of 67 patients was analyzed retrospectively to evaluate the predictive value of the prognostic factors and to design a new surgical scoring system with corresponding treatment proposals for patients with spinal metastases (surgical strategy for spinal metastases). During phase 2, 61 patients were evaluated and assigned scores using the described system. They were prospectively treated in line with the surgical strategy for spinal metastases.

■ Phase 1 Study (1987–1991)

I. Prognostic Factors.

Patients. Sixty-seven patients with spinal metastases who had been treated from 1987–1991 were entered into this study (phase 1). The last follow-up evaluation of these patients was at the end of 1992. There were 36 women and 31 men, with a mean age of 56.3 years (range, 32–72 years). The main lesion was located in the thoracic spine in 39 patients, in the lumbar spine in 19, and in the cervical spine in 9. The primary tumors were cancer of the breast (14), kidney (12), lung (10), thyroid

From the Department of Orthopaedic Surgery, School of Medicine, Kanazawa University, Kanazawa, Japan.
 Acknowledgment date: January 19, 2000.
 Acceptance date: May 2, 2000.
 Device status category: 1.
 Conflict of interest category: 12.

Scoring System				Prognostic Score	Treatment Goal	Surgical Strategy
Point	Prognostic factors					
	Primary tumor	Visceral mets.*	Bone mets.**			
1	slow growth (breast, thyroid, etc.)	/	solitary or isolated	2	Long-term local control	Wide or Marginal excision
				3		
2	moderate growth (kidney, uterus, etc.)	treatable	multiple	4	Middle-term local control	Marginal or Intralesional excision
				5		
4	rapid growth (lung, stomach, etc.)	un-treatable	/	6	Short-term palliation	Palliative surgery
				7		
				8	Terminal care	Supportive care
				9		
				10		

* No visceral mets. = 0 point. ** Bone mets. including spinal mets.

Figure 1. Surgical strategy for spinal metastases.

(9), colon (6), prostate (4), liver (4), stomach (3), uterus (3), and unknown (2).

Each patient was evaluated using plain anteroposterior and lateral radiographs of the affected segment of the spine, computed tomography (CT) of the involved vertebra(e), and magnetic resonance imaging (MRI) centered on the affected segment(s). A systemic search also was done for other metastases. This involved bone scintigraphy to detect other bony secondary tumors, MRI of the entire spine from C1 to sacrum to find other vertebral metastases, and CT of the chest, abdomen, and brain.

Methods. Three factors were considered in prognostic evaluation of patients with spinal metastases: 1) grade of malignancy of the primary tumors, 2) visceral metastases to vital organs (lungs, liver, kidneys, and brain) and 3) bone metastases (Figure 1).

Factor 1: Grade of Malignancy of the Primary Tumors. Grade of malignancy of the primary tumors is reflected by growth speed, which is divided into three categories: 1) slow growth (breast, prostate, thyroid, etc.), 2) moderate growth (kidney, uterus, etc.), and 3) rapid growth (lung, liver, stomach, colon, primary unknown, etc.).

Factor 2: Visceral Metastases to Vital Organs (Lungs, Liver, Kidneys, and Brain). The condition of visceral metastases is divided into three categories: 1) no visceral metastasis, 2) visceral metastases that are treatable by operation or transarterial embolization (TAE) etc., and 3) visceral metastases that are untreatable.

Factor 3: Bone Metastases Including Spine. Bone metastases were divided into two categories: 1) solitary or isolated spinal metastasis, and 2) multiple bone metastases (solitary or isolated spinal metastasis with any other bone metastases, or multiple spinal metastases with/without other bone metastases).

The authors examined the relation between length of survival and the aforementioned three prognostic factors. Cox's regression model analysis and the relative prognostic value (hazard ratio) of each parameter then was analyzed using the StatView program package (Abacus Concepts, Berkeley, CA,

USA). When testing the differences between groups, a significance level of $P < 0.05$ was used.

Results. Factor 1: Grade of Malignancy of the Primary Tumors.

The average survival period of 26 patients in the slow growth group was 40.8 months (range, 5–84 months), that of 15 patients in the moderate growth group was 24.2 months (range, 4–84 months), and that of 26 patients in the rapid growth group was 10.0 months (range, 1–32 months). There was a significant difference between any two of the three groups ($P < 0.05$). The hazard ratio of the slow, moderate, and rapid growth groups was 1.0: 1.82: 4.08.

Factor 2: Visceral Metastases to Vital Organs. The average survival period of 36 patients in the no visceral metastases group was 36.8 months (range, 5–84 months), that of 7 patients in the treatable visceral metastases growth group was 16.5 months (range, 4–31 months), and that of 24 patients in the untreatable visceral metastases

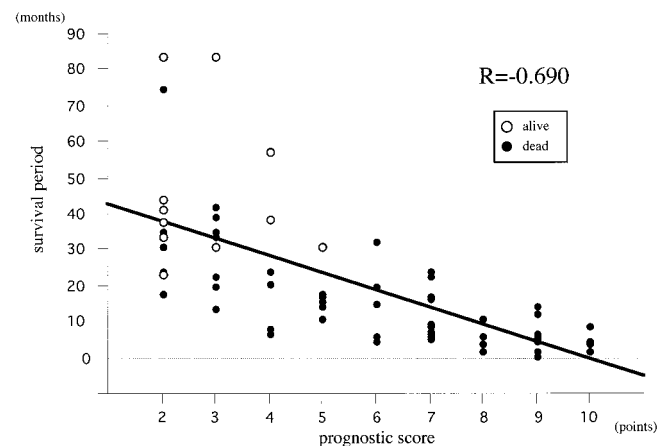


Figure 2. Relation between the prognostic score and the survival period. There was a high-grade correlation between the prognostic score and survival period, with a correlation coefficient of -0.690 ($P < 0.0001$).

group was 8.7 months (range, 1–24 months). There was a significant difference between the groups ($P < 0.05$). The hazard ratio of the treatable and untreatable visceral metastases groups was 1.0: 1.90.

Factor 3: Bone Metastases, Spine Inclusive. The average survival period of 33 patients in the solitary bone metastases group was 34.8 months (range, 1–84 months), and that of 34 patients in the multiple bone metastases group was 17.9 months (range, 2–57 months). There was a significant difference between the two groups ($P < 0.05$). The hazard ratio of the solitary and multiple bone metastases groups was 1.00: 1.94.

Standardized regression coefficients of the three prognostic factors (grade of malignancy of the primary organs, visceral metastases, and bone metastases) were -0.405, -0.416, and -0.199, respectively. According to the ratio of standardized regression coefficients of the three prognostic factors, the hazard ratio of the seven groups (slow growth, moderate growth, rapid growth, treatable visceral metastases, untreatable visceral metastases, solitary bone metastasis and multiple bone metastases) was standardized to be in the sequence of 1.00: 1.82: 4.08: 2.16: 4.11: 1.01: 1.97.

II. Scoring System.

Methods. The score for each group was derived from the hazard ratio by rounding off to the nearest integer (e.g., 1.82 becomes 2, 4.08 becomes 4, etc.). The scores for each prognostic factor were added together to produce a prognostic score (Figure 1). The relation between the prognostic score and the survival period was studied in the 67 patients who were treated from 1987–1991 as mentioned above (phase 1).

Results. Correlation coefficients between survival time and the three prognostic factors were calculated: grade of malignancy of the primary organs, -0.492 ($P < 0.0001$); visceral metastases to vital organs, -0.536 ($P < 0.0001$); and bone metastases, -0.250 ($P < 0.05$). The correlation coefficient between survival time and prognostic score was -0.690 ($P < 0.0001$; Figure 2). This was higher than for any of the three prognostic factors.

The average survival period of 21 patients with a prognostic score of 2 or 3 points was 49.9 months (range, 18–84 months), that of 13 patients with 4 or 5 points was 23.5 months (range, 7–57 months), that of 17 patients with 6 or 7 points was 15.0 months (range, 5–33 months), and that of 17 patients with 8, 9 or 10 points was 5.9 months (range, 1–14 months).

■ Phase 2 Study (1993–1996)

Patients. Sixty-one patients who were treated for spinal metastases between 1993–1996 were entered into this study (phase 2). There were 34 women and 27 men, with a mean age of 57.7 years (range, 33–72). The primary tumors were breast cancer in 16 patients, lung cancer in 10 patients, thyroid cancer in 8 patients, renal cell carcinoma in 8 patients, colon cancer in 7 patients, hepato-

cellular carcinoma in 3 patients, gastric cancer in 3 patients, prostate cancer in 2 patients, uterus cancer in 2 patients, and unknown in 2 patients. The main lesion of the spinal metastases was located in the cervical spine in 3 patients, in the thoracic spine in 34 patients, and in the lumbar spine in 24 patients. Each patient was evaluated by a local tumor study and a systemic search for other metastases in the same way as the patients who were treated from 1986–1991 (phase 1).

Methods. Surgical Strategy for Spinal Metastases. Surgical strategy for spinal metastases (Figure 1) was designed based on the treatment goal that was decided according to the prognostic score. An appropriate oncologic surgical procedure was selected for each patient based on the prognostic score, which is the summation of points of the three prognostic factors. Wide or marginal excision such as total *en bloc* spondylectomy is recommended for patients with a prognostic score of 2 or 3 points to achieve long-term local control. When the prognosis is intermediate and treatment goals are for middle-term local control (prognostic score of 4 or 5 points), intralaminar excision such as piecemeal excision or eggshell curettage would be the main modalities used, but, if possible, intralaminar excision including barrier tissues (thorough debulking) or marginal excision (total *en bloc* spondylectomy) can be selected as appropriate. Palliative surgery such as spinal cord decompression with spinal stabilization is the first choice of treatment for the patient with a prognostic score of 6 or 7 points for short-term palliation. The patient with a prognostic score of 8, 9, or 10 points generally is not a candidate for surgery, but for supportive care.

Some spinal metastases respond to nonsurgical methods such as radiation therapy, chemotherapy, and hormonal therapy. These treatment options should be discussed individually with the specialist of each primary cancer.

Surgical Classification of Spinal Tumors (SCST). Surgical classification of spinal tumors has been reported in several papers.^{28,29} Briefly, spinal tumors are grouped into three (intracompartmental, extracompartmental, multiple) and subdivided into seven types (Figure 3). The surgical procedure was decided for each patient based on surgical strategy for spinal metastases and surgical classification of spinal tumors.

Pain was assessed on a 4-point scale as follows: 0 = no pain, 1 = minimal or occasional pain not requiring medication, 3 = moderate pain controlled with occasional narcotic analgesics, and 4 = severe constant pain requiring regular narcotic analgesics.¹⁶ The Frankel grading system⁸ was used to assess the neurologic outcome.

Results. Twenty-eight patients were oncologically treated with wide or marginal excision. Their mean prognostic score was 3.3 points (range, 2–5 points). Total *en bloc* spondylectomy was performed in 26 patients, and *en bloc* corpectomy was performed in two patients. Of these 28 patients, 19 patients had died and 9 were alive at the time of the last follow-up evaluation. Mean

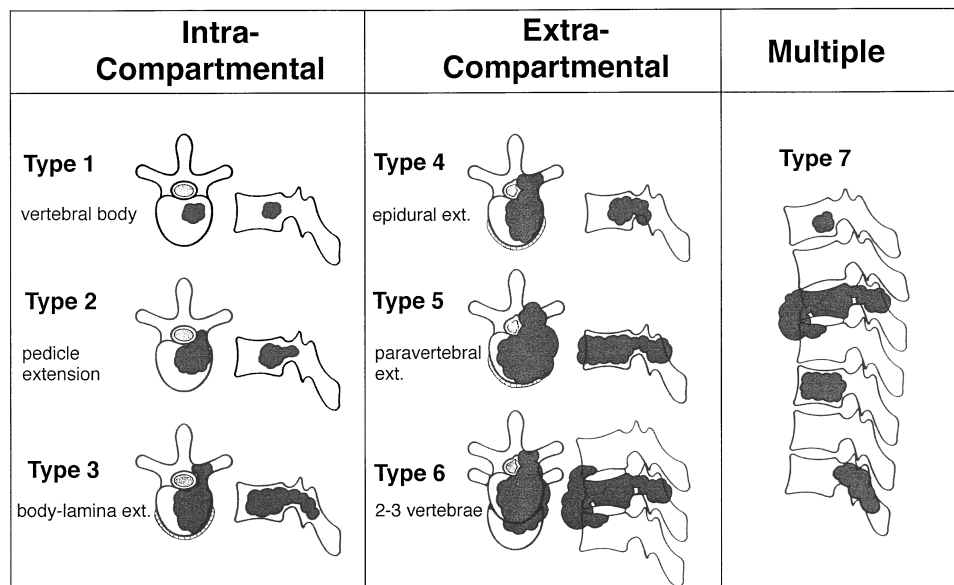


Figure 3. Schematic diagram of surgical classification of spinal tumors.

length of survival of the 28 patients was 38.2 months (range, 6–84 months). Twenty-six of these 28 patients achieved successful local control (Figure 4).

Thirteen patients were treated with intralesional excision such as piecemeal subtotal excision, eggshell curettage, or thorough debulking. Their mean prognostic score was 5.0 points (range, 3–7 points). Of these 13 patients, 11 patients had died and two were alive at the time of the last follow-up evaluation. Mean length of survival of the 13 patients was 21.5 months (range, 4–60 months). Nine of 13 patients achieved successful local control. Even the four patients who had neurologic deterioration because of local recurrence achieved successful local control for more than 80% of their remaining lifespan (Figure 4).

Eleven patients were treated with palliative decompression and stabilization. Their mean prognostic score was 7.5 points (range, 5–10 points). All patients had died by the time of the last follow-up evaluation, and their mean length of survival was 10.1 months (range, 3–23 months). Eight of the 11 patients achieved successful local control. Even the three patients who had neurologic deterioration because of local recurrence had successful local control for more than 75% of their remaining lifespan (Figure 4).

Fifty of 52 patients who underwent operative treatment had pain before surgery. Thirty-four patients (68%) had severe pain requiring regular narcotic analgesics (Grade 4), 10 had Grade 3 pain, and 7 had Grade 2 pain. Thirty-five patients were pain free after their recovery from surgery. Four patients had minimal pain (Grade 1), five patients required nonnarcotic analgesics (Grade 2), two had moderate pain controlled with occasional narcotic analgesics, and two still had Grade 4 pain.

Thirty-four (65%) of the 52 patients who underwent operative treatment had neurologic compromise before surgery. Neurologic improvement of at least one Frankel grade was noted in 25 patients (74%). Improvement was noted in 14 (78%) of 18 patients after wide or marginal excision, in 6 (75%) of 8 patients after intralesional excision, and in 5 (63%) of 8 patients after palliative decompression and stabilization. Ten of the 34 patients had bowel and bladder dysfunction before surgery. Six of these (60%) regained voluntary control after surgery. No patient experienced neurologic deterioration secondary to surgical intervention.

Nine patients were treated with terminal supportive care. Their mean prognostic score was 9.2 points (range, 8–10 points). All patients had died by the time of the last follow-up evaluation, and mean length of survival was 5.3 months (range, 1–12 months; Figure 4).

Illustrative Case Presentations

Case 1 (Patient No. 3 in Figure 4). The patient was a 54-year-old woman. She visited the authors' hospital because of back pain. She had a history of breast cancer (1 point), with a mastectomy performed 3 years previously. Visceral metastases were not detectable (0 point). Bone scan revealed only a T10 solitary metastatic lesion (1 point). Her total prognostic score was 2 points, thus the treatment goal was for long-term local control and the surgical strategy was wide or marginal excision. The surgical classification of her T10 metastatic lesion was extracompartmental lesion (type 5), and wide removal with total *en bloc* spondylectomy (TES) was performed (Figures 5A through 5F). After successful TES surgery, she had been disease-free for more than 5 years.

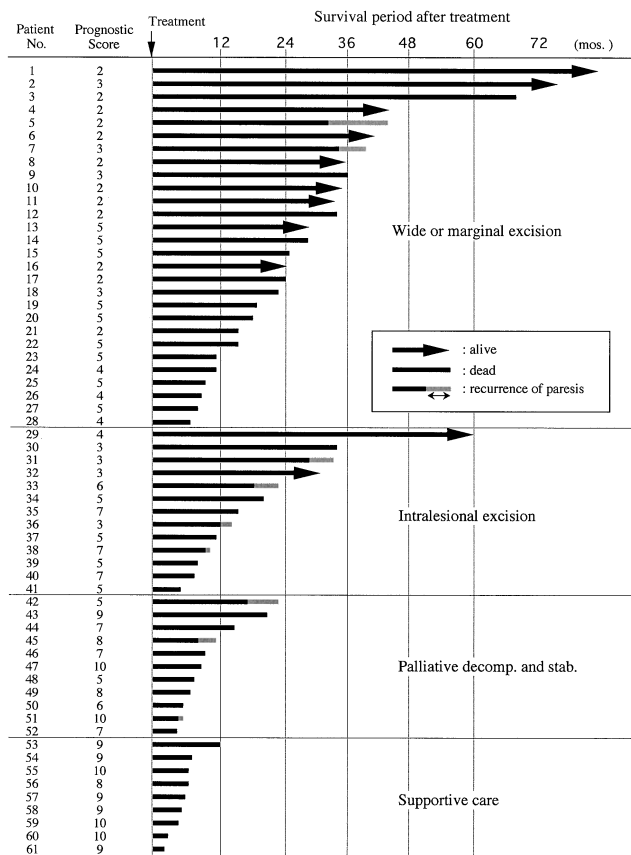


Figure 4. Survival periods of each patient treated with the surgical strategy for spinal metastases. Twenty-eight patients were oncologically treated with wide or marginal excision. Thirteen patients were treated with intralesional excision such as piecemeal subtotal excision, eggshell curettage, or through debulking. Eleven patients were treated with palliative decompression and stabilization. Nine patients were treated with terminal supportive care.

Case 2 (Patient No. 34 in Figure 4). A 52-year-old man had a history of renal cell carcinoma (2 points). The patient had paraparesis because of a solitary metastasis (1 point) at T6. A further work-up revealed a single metastatic lesion in the lung, which was resectable (2 points). The total prognostic score was 5 points, suggesting middle-term local control as the treatment goal. The tumor extended into the spinal canal as well as into the paravertebral area (type 5 by surgical classification), and marginal or intralesional excision was the surgery of choice, so thorough extended curettage was performed. The patient did not experience local recurrence, but because of general dissemination of metastatic disease, he died 20 months after surgery.

Case 3 (Patient No. 44 in Figure 4) A 60-year-old man who had been treated with chemotherapy for 5 years for prostatic cancer (1 point) was seen for back pain. General examination revealed multiple lung metastases (4 points) as well as multiple spinal metastases (2 points). The total prognostic score of 7 points suggested short-term palliation as the best treatment option. Palliative surgery with

spinal cord decompression and stabilization was performed. The patient died 14 months after surgical intervention without paresis.

Case 4 (Patient No. 58 in Figure 4) A 50-year-old man had a history of hepatocellular carcinoma (4 points). He was referred to the authors' hospital with an isolated spinal metastasis (type 4) at T10 (1 point). General examination revealed multiple metastatic foci in the lung (4 points). The total prognostic score of 9 points suggested supportive care. The patient died 3 months later.

Discussion

A clear consensus does not yet exist for deciding which patients should undergo surgical treatment of their spinal metastases, let alone with what type of surgery. Several management principles have been proposed to help indicate treatment options.^{11,14,17}

Many spinal metastases respond favorably to nonsurgical methods such as radiation therapy, hormonal manipulation, or chemotherapy. The specialist for the primary cancer as well as the medical and radiation oncologists are the best resources to identify those patients who are suitable candidates for each treatment. Harrington¹¹ devised a five-category classification scheme for metastatic spine tumors based on bone destruction and neurologic compromise: 1) no significant neurologic involvement; 2) involvement of bone without collapse or instability; 3) major neurologic impairment (sensory or motor) without significant involvement of bone; 4) vertebral collapse with pain resulting from mechanical causes or instability, but with no significant neurologic compromise; and 5) vertebral collapse or instability combined with major neurologic impairment. He mainly recommended that patients in categories 1, 2, and 3 be treated nonsurgically with chemotherapy, hormonal manipulation, and/or local irradiation.¹¹ Patients in categories 4 or 5 require surgical intervention. A category 3 lesion, however, represents a gray area where the physician has wide latitude to exercise judgment about medical or surgical intervention (Kowalski JM, Heller JG. Personal communication). If the spinal cord is severely compressed by an epidural tumor that is not radiosensitive, the patient may have a greater risk of neurologic degradation during radiation therapy and should be considered a candidate for surgery as initial treatment. Also, lesions unlikely to respond to radiation or chemotherapy, such as renal cell carcinoma, are candidates for operative intervention, regardless of their Harrington class (Kowalski JM, Heller JG. Personal communication). Patients who have reached spinal cord tolerance after prior radiation therapy are candidates for surgery based on neurologic symptoms, radiographic progression of tumor, and spinal instability. Conversely, postoperative radiation therapy could be applied as supplementary therapy to inhibit regrowth of the residual tumor.

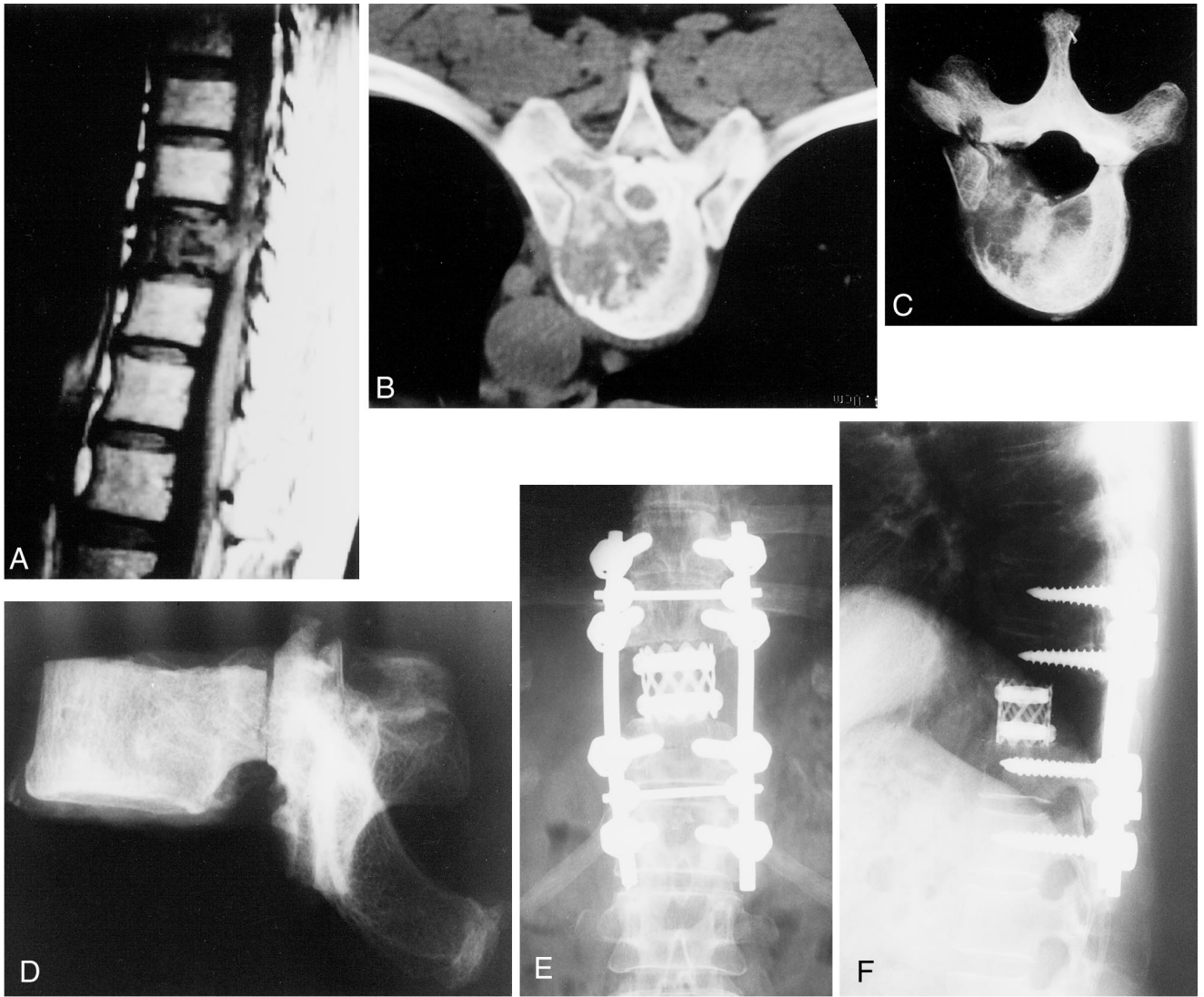


Figure 5. Imaging findings of patient no. 3. **A**, T1-weighted magnetic resonance image demonstrating solitary lesion of T10. **B**, Computerized tomography of T10 demonstrating tumor invasion from the vertebral body to the epidural space and the costovertebral joint. Radiographs of the resected specimen of the T10 vertebra: **C**, Horizontal view. **D**, Lateral view. Radiographs 5 years after operation: **E**, Anteroposterior view. **F**, Lateral view.

Spinal stability is another concern. Kostuik et al¹⁴ believe that the need for surgical intervention is based on spinal stability. They attempted to define stability using a two-column concept of spinal architecture. Their anterior column consists of the entire vertebral body including the cortex, whereas the posterior column consists of pedicles, laminae, and spinous processes. The anterior column is divided further into anterior and posterior halves, as well as left and right sides, which results in four quadrants within the vertebral body. The posterior column is divided into left and right sides, for a total of six vertebral segments. Based on retrospective study, Kostuik et al¹⁴ thought that the spine was stable if no more than two of the six segments were destroyed and unstable if three or more segments were destroyed.¹⁴ Taking into consideration the results from several other papers, instability may be presumed if radiologic studies show

any of the following features^{5,6,12,13}: transitional deformity, vertebral body collapse greater than 50%, three column involvement (as defined by Denis⁵), or involvement of the same column in two or more adjacent levels. Surgical intervention may be determined according to the degree of instability.

Therefore, indications for surgical intervention of metastatic spinal disease are (Kowalski JM, Heller JG. personal communication)^{1,16,20}:

1. Intractable pain unresponsive to nonoperative measures, such as radiation therapy, chemotherapy, or hormonal therapy.
2. Existence of a growing tumor that is resistant to radiation therapy, chemotherapy, or hormonal therapy.

3. Patients who have reached spinal cord tolerance after prior radiation therapy.
4. Spinal instability manifested as pathologic fracture, progressive deformity, or neurologic deficit.
5. Clinically significant neural compression, especially by bone or bone debris.

McLain and Weinstein¹⁷ divided the vertebra into four zones for selection of practical surgery: I) the spinous process to pars intraarticularis and the inferior facets; II) the superior articular facet, the transverse process, and the pedicle; III) anterior three fourths of the vertebral body; and IV) the posterior one fourth of the vertebral body. They also designated tumor extension as A–C for intraosseous, extraosseous, and distant tumor spread. They suggested that the optimal surgical approach should be based on the extent of bony involvement. Weinstein³¹ and Boriani et al² improved this classification. On the transverse plane, the vertebra is divided into 12 radiating zones (numbered 1–12 in a clockwise order) and into five layers.^{2,31} The authors of the present study also have proposed the surgical classification of the spinal tumors according to tumor progression.^{28,29} These management principles take into account neither the primary cancer type nor generalized metastases that may better indicate the patient's prognosis, but only the local condition of the spine lesions.

Constans et al⁴ advocated that the choice of surgical treatment depends on the primary cancer involved and on the results of the local and systemic search for secondary tumor lesions. Tokuhashi et al²⁷ proposed a prognostic scoring system for the preoperative evaluation of patients with metastatic spine tumors. The scheme takes six variables into account: general medical condition, number of extraspinal metastases, number of vertebral metastases, visceral metastases, primary tumor type, and presence of neurologic deficit. Each parameter is evaluated with a score from 0–2 points, giving a maximum total score of 12. Excisional surgery would be indicated for a patient with a total score of 9 or more, whereas a palliative method would be appropriate for a patient with a score of 5 or less. Enkaoua et al⁷ affirmed the prognostic value of the Tokuhashi score, except that they recommended assigning fewer points than originally proposed for carcinoma of unknown primary because of the worse prognosis for this subgroup.

The authors of the present study tried to take this approach one step further, so that the surgical strategy for spinal metastases might be used to select not only whether a patient is a candidate for surgical intervention, but to guide the selection of the type of surgery as well. In the past, many major or minor prognostic factors have been discussed. In the present study, the authors used what they believe are the three most important prognostic factors: grade of malignancy of the primary tumor, visceral metastases to vital organs, and bone metastases (spine inclusive).

Variable results have been reported by several authors dependent on the primary tumor site.^{3,10,18,21,32,34} Tatsui et al²⁶ recently reviewed the survival of 425 patients with spinal metastases after scintigraphic detection. Their 1-year survival rate from the diagnosis of spinal metastasis was 83.3% for patients with prostatic cancer, 77.7% for those with breast cancer, 51.2% for those with renal cancer, 44.6% for those with uterine cervical cancer, 21.7% for those with lung cancer, and 0% for those with gastric cancer. It seems fundamental to select a treatment modality based on consideration of the primary lesions and the expected prognosis. This study used "grade of malignancy of the primary tumor" as one of the major prognostic factors (factor 1). Grade of malignancy is reflected by growth speed, which was divided into three groups: 1) slow growth (breast, thyroid, prostate, *etc.*), 2) moderate growth (kidney, uterus, *etc.*), and 3) rapid growth (lung, stomach, liver, colon, unknown, *etc.*).^{7,26,27}

The presence or absence of visceral metastases to vital organs is critical for the prognostication of the patients with spinal metastases, which is also reflected as general condition. Several papers have reported that prognosis of patients with visceral metastases to vital organs was much worse than that of patients without metastases.^{25,27,33} In the system presented here, this was divided into three groups [1) no visceral metastases, 2) treatable visceral metastases, and 3) untreatable visceral metastases] because of the apparent difference of adverse effect to the survival.

It has been reported that patients with bone metastases have a longer survival time than patients with involvement of other visceral organs.^{25,33} It has been reported, however, that when there are no visceral metastases, extent of bone metastases was useful in predicting the prognosis of patients with metastatic spine lesions.³³ Most patients with metastases have multiple bone lesions, whereas some patients have solitary or isolated bone metastases. It was decided to use bone metastases as the third prognostic factor.

Can paraplegia be an important prognostic factor? Generally, even with paraplegia, patients may have a long survival period with appropriate treatment. The presence of paralysis, *per se*, is not absolutely predictive of survival. Spiegel et al²² reported that the presence of a neurologic deficit did not significantly influence survival among melanoma patients. Enkaoua et al⁷ also reported that epidural metastases were not significantly associated with length of survival. Further, paralytic conditions can be improved by spinal cord decompression. Patients with paralysis seem to die sooner because of progression of the cancer, not because of the paralysis itself. For all these reasons, paralysis was not used as a prognostic factor in the system presented here.

The Tokuhashi score²⁷ has been widely accepted as the first trial of a scoring system; however, it has been questioned in the following points. There was no statis-

tical background of points 0, 1, and 2 in each factor, and the important value of each prognostic factor was not considered in their scoring system. The authors of the present study retrospectively looked at the relations between the length of survival and the aforementioned three prognostic factors in 67 patients with spinal metastases treated between 1987–1991 (phase 1). The hazard ratios in a total of seven groups of three prognostic factors were analyzed and standardized, and the slow growth group was determined as 1.0. The ratios were rounded off to integers and used for the group score in the scoring system. The scoring system presented here was devised statistically based on these patients' data. There was a high degree of correlation between the 67 patient's survival times and the total prognostic scores; the correlation coefficient was -0.690 ($P < 0.0001$).

The surgical strategy for spinal metastases was designed based on the treatment goal, which can be determined by the scoring system. The appropriate oncologic surgical procedure can be selected to control the spinal metastases during the expected survival period for each patient.

In the patient with a prognostic score of 2 or 3, the treatment goal is long-term local control, with an expected survival period of more than 2 years. If intralesional excision or palliative surgery is performed in such patients, there is a high possibility of local recurrence from the residual tumor tissue. To prevent this, wide or marginal excision dependent on the concept of compartment and barrier⁹ such as total *en bloc* spondylectomy^{28–30} is appropriate.

When the treatment goal is middle-term local control (prognostic score of 4 or 5 points), intralesional excision such as piecemeal excision or eggshell curettage will be the appropriate surgical modality. If possible, intralesional excision including barrier tissues (thorough debulking) or marginal excision (total *en bloc* spondylectomy) can be applied for a better local prognosis.

Length of survival of patients with a prognostic score of 6 or 7 points was approximately 12 months in this study series. In these patients, palliative surgery such as spinal cord decompression with stabilization is the first choice for short-term palliation.

The patient with the prognostic score of 8, 9, or 10 points is not a candidate for surgery, but for supportive care.

In this series, 61 patients with spine metastases with various prognostic scores were prospectively treated according to this strategy between 1993–1996 (phase 2). Successful local control was achieved in 43 (83%) of 52 patients who were treated surgically. Local control also was achieved during more than 80% of the survival period even in most of the patients who had local tumor recurrence. These results suggest that this strategy is practical, with reliable accuracy.

■ Conclusion

A new surgical scoring system with a corresponding treatment proposal for patients with spinal metastases based on three prognostic factors was designed. This simple surgical strategy may provide appropriate guidelines for the treatment of patients with spinal metastases.

■ Key Points

- A new scoring system for spinal metastases consists of three prognostic factors: 1) grade of malignancy, 2) visceral metastases, and 3) bone metastases.
- The treatment goal for each patient was set according to this prognostic score: long-term local control, middle-term local control, short-term palliation, and supportive care.
- The strategy for each patient was decided along with the treatment goal: a wide or marginal excision for long-term local control, marginal or intralesional excision for middle-term local control, palliative surgery for short-term palliation, and nonoperative supportive care.
- This strategy provides appropriate guidelines for treatment in the patients with spinal metastases; however, the final decision should be made by the individual patient.

Acknowledgment

The authors thank Dr. John G. Heller and Dr. John P. Dormans for their kind criticism and advice and all spine surgeons of Kanazawa group for their contribution to this work.

References

1. Asdourian PL. Metastatic disease of the spine. In: Bridwell KH, DeWald RL, eds. *The Textbook of Spinal Surgery*, 2nd edition. Philadelphia, PA: Lippincott-Raven Publishers, 1997: 2007–50.
2. Boriani S, Chevalley F, Weinstain JN, et al. Chordoma of the spine above the sacrum. *Spine* 1996;21:1569–77.
3. Brice J, McKissock W. Surgical treatment of malignant extradural spinal tumors. *BMJ* 1965;1:1341–4.
4. Constans JP, Divitiis E, Donzelli R, et al. Spinal metastases with neurological manifestations. *J Neurosurg* 1983;59:111–8.
5. Denis F. The three column spine and its significance in the classification of acute thoracolumbar spine injuries. *Spine* 1983;8:817–31.
6. DeWald RL, Bridwell KH, Prodromas C, et al. Reconstructive spinal surgery as palliation for metastatic malignancy of the spine. *Spine* 1985;10:22–6.
7. Enkaoua EA, Doursounian L, Chatellier G, et al. Vertebral metastases. A critical application of the preoperative prognostic Tokuhashi score in a series of 71 cases. *Spine* 1997;22:2293–8.
8. Frankel HL, Hancock DO, Hyslop G, et al. The value of postural reduction in the initial management of closed injuries of the spine with paraplegia and tetraplegia. *Paraplegia* 1969;7:179–92.
9. Fujita T, Ueda Y, Kawahara N, et al. Local spread of metastatic vertebral tumors. *Spine* 1997;22:1905–12.
10. Hall AJ, McKay NS. The result of laminectomy in compression of the cord or cauda equina by extradural malignant tumor. *J Bone Joint Surg* 1973;55B: 497–505.
11. Harrington KD. Metastatic disease of the spine. *J Bone Joint Surg* 1986;68A: 1110–5.
12. Kaneda K, Takeda N. Reconstruction with a ceramic vertebral prosthesis and Kaneda device following subtotal or total vertebrectomy in metastatic

- thoracic and lumbar spine. In: Bridwell KH, DeWald RL, eds. *The Textbook of Spinal Surgery*, 2nd edition. Philadelphia, PA: Lippincott-Raven Publishers, 1997: 2071-87.
13. Kem, MB, Malone DG, Benzel EC. Evaluation and surgical management of thoracic and lumbar instability. *Contemp Neurosurg* 1996;18:1-8.
 14. Kostuik JP, Errico TJ, Gleason TF, et al. Spinal stabilization of vertebral column tumors. *Spine* 1988;13:250-6.
 15. Magerl F, Coscia MF. Total posterior vertebrectomy of the thoracic or lumbar spine. *Clin Orthop* 1988;232:62-9.
 16. McAfee PC, Zdeblick TA. Tumors of the thoracic and lumbar spine: Surgical treatment via the anterior approach. *J Spinal Disord* 1989;2:145-54.
 17. McLain RF, Weinstein JN. Tumors of the spine. *Semin Spine Surg* 1990;2: 157-80.
 18. Onimus M, Schraub S, Bertin D, et al. Surgical treatment of vertebral metastases. *Spine* 1986;11:883-91.
 19. Roy-Camille R, Mazel C, Sallant G, et al. Treatment of malignant tumors of the spine with posterior instrumentation. In: Sundaresan N, Schmidek HH, Schiller AL, Rosenthal DI, eds *Tumor of the Spine*. Philadelphia, PA: W.B. Saunders, 1990: 473-87.
 20. Siegal T, Siegal T. Current considerations in the management of neoplastic spinal cord compression. *Spine* 1989;14:223-8.
 21. Smith R. An evaluation of surgical treatment for spinal cord compression due to metastatic carcinoma. *J Neurol Neurosurg Psychiatry* 1965;28:152-8.
 22. Spiegel DA, Sampson JH, Richardson WJ, et al. Metastatic melanoma to the spine. Diagnosis, risk factors, and prognosis in 114 patients. *Spine* 1995;20: 2141-6.
 23. Stener B. Complete removal of vertebrae for extirpation of tumors. *Clin Orthop* 1989;245:72-82.
 24. Sundaresan N, DiGiacinto GV, Krol G, et al. Spondylectomy for malignant tumors of the spine. *J Clin Oncol* 1989;7:1485-91.
 25. Swenerton KD, Legha SS, Smith T, et al. Prognostic factors in metastatic breast cancer treated with combination chemotherapy. *Cancer Res* 1979;39: 1552-62.
 26. Tatsui H, Onomura T, Morishita S, et al. Survival rates of patients with metastatic spinal cancer after scintigraphic detection of abnormal radioactive accumulation. *Spine* 1996;18:2143-8.
 27. Tokuhashi Y, Matsuzaki H, Toriyama S, et al. Scoring system for the pre-operative evaluation of metastatic spine tumor prognosis. *Spine* 1990;15: 1110-3.
 28. Tomita K, Kawahara N, Baba H, et al. Total en bloc spondylectomy: A new surgical technique for primary malignant vertebral tumors. *Spine* 1997;22: 324-33.
 29. Tomita K, Kawahara N, Baba H, et al. Total *en bloc* spondylectomy for solitary spinal metastases. *Int Orthop* 1994;18:291-8.
 30. Tomita K, Toribatake Y, Kawahara N, et al. Total *en bloc* spondylectomy and circumspinal decompression for solitary spinal metastasis. *Paraplegia* 1994;32:36-46.
 31. Weinstein JN. Spine neoplasms. In: Weinstein SL, ed. *The Pediatric Spine: Principles and Practice*. New York: Raven Press, 1994:887-916.
 32. White WA, Patterson RH, Bergland RM. Role of surgery in the treatment of spinal cord compression by metastatic neoplasm. *Cancer* 1971;27:558-61.
 33. Yamashita K, Yonenobu S, Fuji T. Staging of metastatic spinal tumor. *Rinsho Seikei Geka* 1986;21:445-50.
 34. Young RF, Feldmann RA. Metastatic tumor of the spine. *J Neurosurg* 1979; 50:536-7.

Address reprint requests to

Katsuro Tomita, MD
 Professor and Chairman
 Department of Orthopaedic Surgery
 Kanazawa University School of Medicine
 13-1 Takara-machi
 Kanazawa, 920-8641, Japan
 E-mail: seikei@kenroku.ipc.kanazawa-u.ac-jp