

VIPER[®]

3D MIS Correction Set

Surgical Technique Guide



never stop moving[®]


Spine Inc.
a Johnson & Johnson company



CONTRIBUTING SURGEONS

D. Greg Anderson, MD – Philadelphia, PA
John Ashgar, MD – Miami, FL
Randy Betz, MD – Philadelphia, PA
Atiq Durrani, MD – Cincinnati, OH
Kamal Ibrahim, MD – Chicago, IL
Frank Lamarca, MD – Ann Arbor, MI
Baron Lonner, MD – New York, NY
Steven Ludwig, MD – Baltimore, MD
Praveen Mummaneni, MD – San Francisco, CA
Peter Newton, MD – San Diego, CA
Mike O'Brien, MD – Dallas, TX
Paul Park, MD – Ann Arbor, MI
Kees Poelstra, MD, PhD – Destin, FL
Amer Samdani, MD – Philadelphia, PA
Khalid Sethi, MD – Binghamton, NY
Suken Shah, MD – Wilmington, DE
Harry Shufflebarger, MD – Miami, FL
Justin Smith, MD, PhD – Charlottesville, VA
Tony Tannoury, MD – Boston, MA
Mike Wang, MD – Miami, FL
Cornelis Wimmer, MD – Votareg, Germany



CONTENTS

INSTRUMENT AND IMPLANT OPTIONS FOR SURGICAL PROCEDURE	1
Spondylolisthesis Reduction and Rod Approximation Options	5
Compression/Distrraction Options	7
Vertebral Body Derotation (VBD Options)	8
Rod Rotator/Introducer Options	9
OUTLINE OF MIS DEFORMITY SURGICAL PROCEDURE	11
Pedicle Cannulation and Posterolateral Fusion Preparation	15
Posterior Deformity Correction Options	21
Spondylolisthesis Correction	26
Pelvic Fixation	29

NOTE: For a comprehensive surgical technique, refer to the VIPER2 System Guide. The information herein describes proper usage instructions for VIPER 3D components only.

Instrument and Implant Options for Surgical Procedure

- *Spondylolisthesis Reduction and Rod Approximation Options*
- *Compression/Distraction Options*
- *Vertebral Body Derotation (VBD Options)*
- *Rod Rotator/Introducer Options*



Instrument and Implant Options for Surgical Procedure

During preoperative planning, it is critical to be aware of all instrument and implant options to help facilitate a balanced three dimensional correction of the spine. Understanding the subtle differences in implant options, and more importantly, where to place them throughout the construct, will enable a more simplified manipulation of individual spinal elements.

The instrument and implant options listed herein are components of the VIPER® MIS Spine System. This list is not intended to be comprehensive of the entire system, rather, it is shown here as a method of describing options available for the treatment of complex spinal pathologies. By providing a choice of instruments and implants, the VIPER Platform allows surgeons to treat patients minimally invasively by using techniques they are accustomed to using in an open procedure.

Screw Options

CANNULATED POLYAXIAL

- Dual lead thread form
- 4.35 mm-9 mm
- Self tapping

CANNULATED MONOAXIAL

- Single lead thread form
- No head toggle – acts as long solid post when attached to screw extension

NOTE: Can be used for fracture reduction or listhesis reduction
Rod passage may be difficult if screw placement is poor

CANNULATED POLYAXIAL LONG SHANK SCREW

- Longer shank to accommodate anatomy
- Same VIPER head size

NOTE: Used to link up to pelvis or in larger anatomy



FIGURE 2: VIPER Cannulated Screw

CANNULATED UNIPLANAR

- Single lead thread form
- Head resists motion in the medial/lateral direction

NOTE: Helpful when used towards the apex of the curve on the convexity for derotation and medial/lateral translation

CANNULATED POLYAXIAL EXTENDED TAB

(10 mm and 25 mm options)

- 10 mm or 25 mm of built in reduction threads
- Smaller diameter prevents crowding

NOTE: Not intended for medial/lateral manipulation due to tab break off



FIGURE 3: VIPER Cannulated Extended Tab Screw

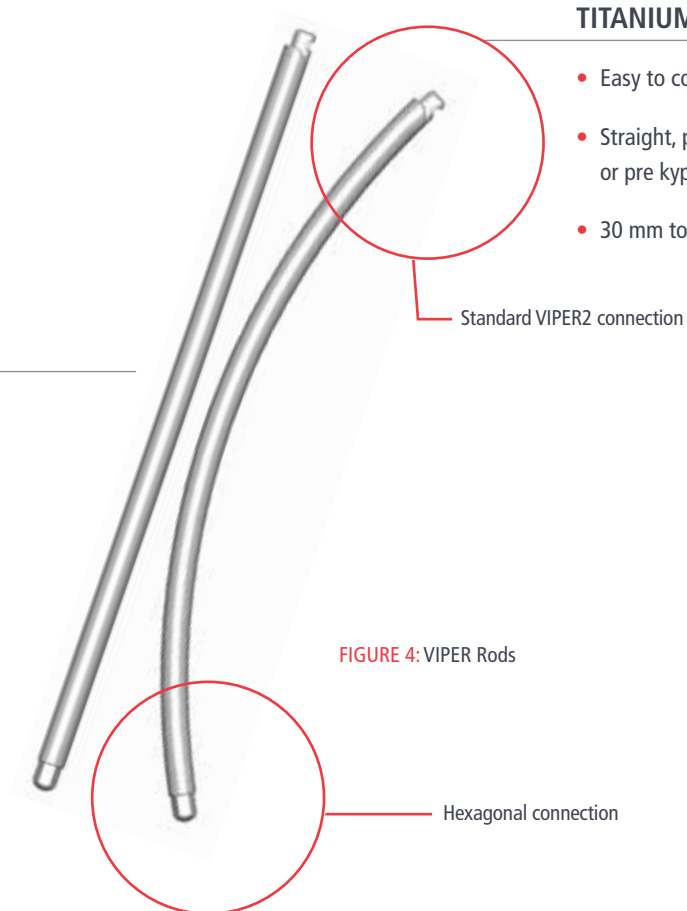
Rod Options

COBALT CHROMIUM ALLOY (CoCr)

- Provides for a stiffer construct than Ti
- If rod is improperly contoured, reduction may be difficult and cause high forces on bone/screw interface and/or screw/screw extension interface
- Better imaging properties compared to stainless steel
- Can be used with Ti screws

TITANIUM ALLOY (Ti)

- Easy to contour vs. CoCr
- Straight, pre lordosed or pre kyphosed
- 30 mm to 600 mm



Spondylolisthesis Reduction and Rod Approximation Options

Reduction maneuvers can be performed to manipulate and stabilize deformities of the thoracolumbar spine through the use of segmental anchors and specialized instrumentation. Multiple anchors provide increased rigidity while allowing for safe and consistent correction.

Reduction can be achieved by bringing the spine to meet the rod (as in the case of translation maneuvers) or by simply pushing the rod to meet the spine to capture the rod for fixation (cantilever maneuver). With flexible deformities, locking the proximal and distal ends of the construct (neutral levels) and segmentally reducing can result in translation of the spine. Anterior releases or osteotomies may be needed for correction of more rigid curves.

Care should be taken not to overload the screw/bone interface in the osteopenic patient and also to avoid overloading the screw/screw extension interface.

TORQUE LIMITING THREADED ROD REDUCER

- Reduces rod until there is a spike in torque indicating that set screw has reached the top of the implant
- Handle automatically switches to drive set screw
- Also used to persuade vertebral body in to proper alignment
- Handle will make audible snap/click when set screw is seated

NOTE: Not a final tightener

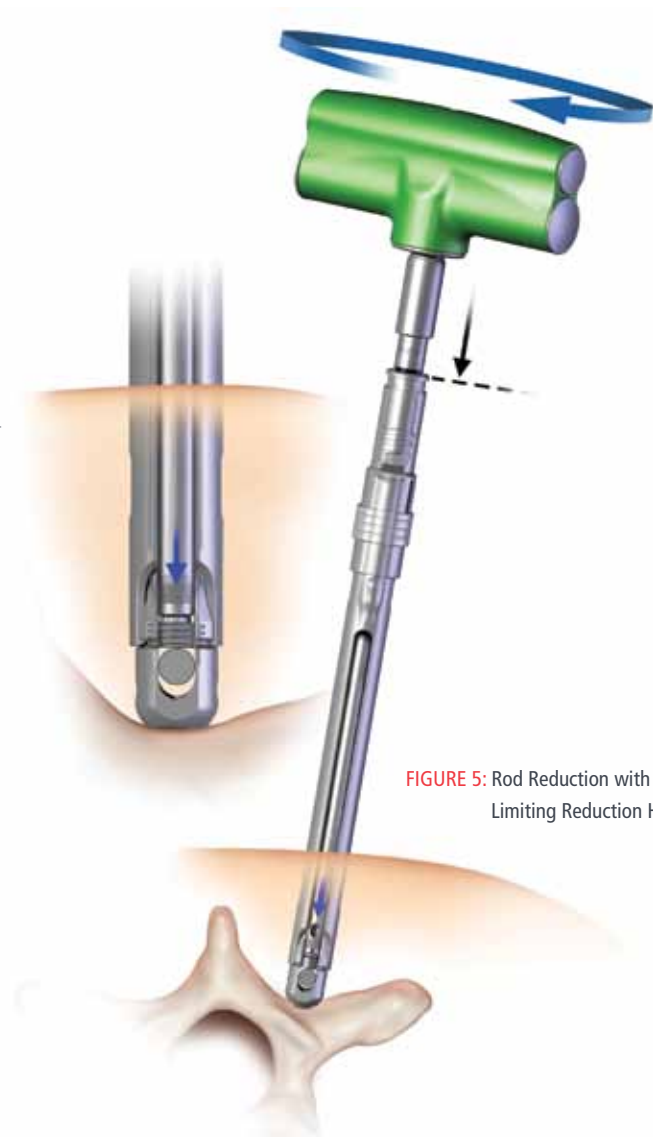


FIGURE 5: Rod Reduction with Torque Limiting Reduction Handle

Spondylolisthesis Reduction and Rod Approximation Options

MULTI-PIECE THREADED ROD REDUCER

- Used to persuade rod down and simultaneously introduce/lock set screw
- Used in the event that Torque Limiting handle is unable to reduce rod
- Also used to persuade vertebral body into proper alignment

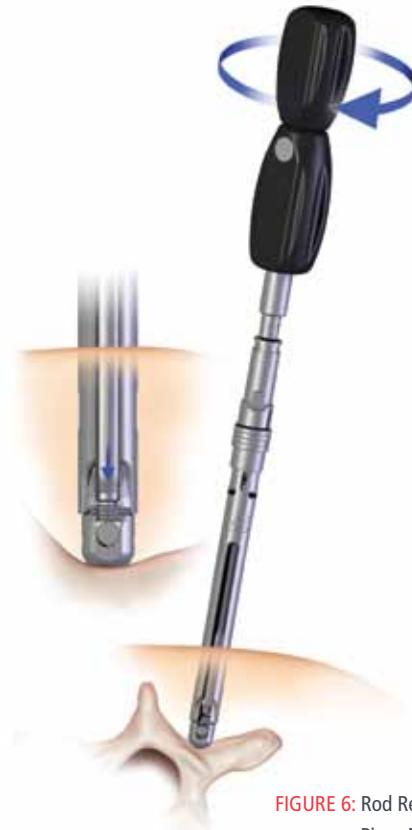

FIGURE 6: Rod Reduction with Two Piece Reduction handle

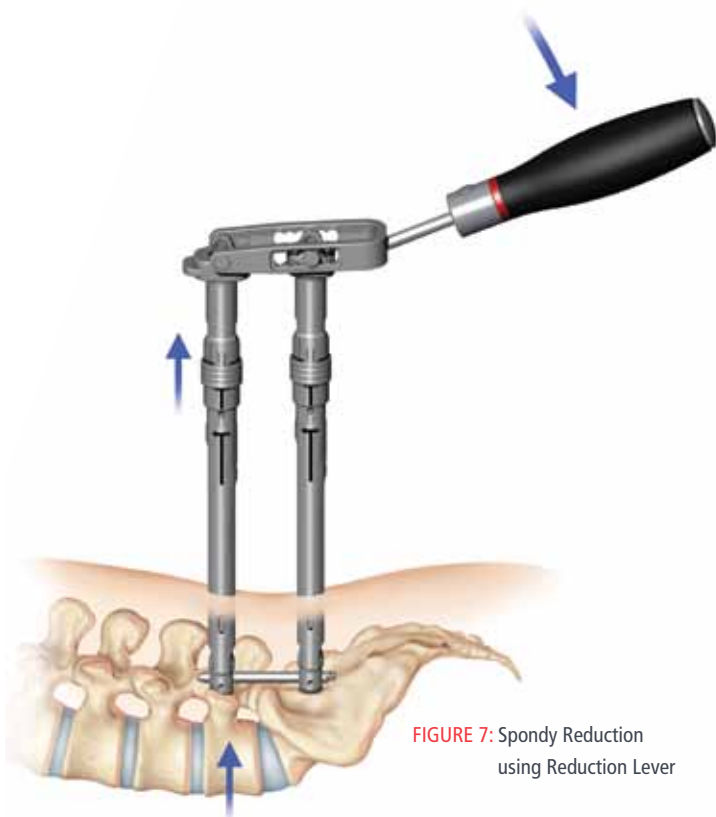


FIGURE 7: Spondy Reduction using Reduction Lever

SPONDY REDUCTION LEVER

- Levers off of neutral level to pull listhesis into proper alignment
- Can also be used to link across spine for derotation

Compression/Distraktion Options

Compression and distraction maneuvers are very powerful in global correction of the spine and also in fracture reduction. Compression and distraction across multiple levels can be complicated in a percutaneous setting and should be done with caution due to the lack of direct visualization of the vertebral elements.

COMPRESSION/DISTRACTION RACK

- Used for controlled multi-level compression/distraktion
- Can be used for fracture reduction
- Can compress unilaterally to correct coronal deformity

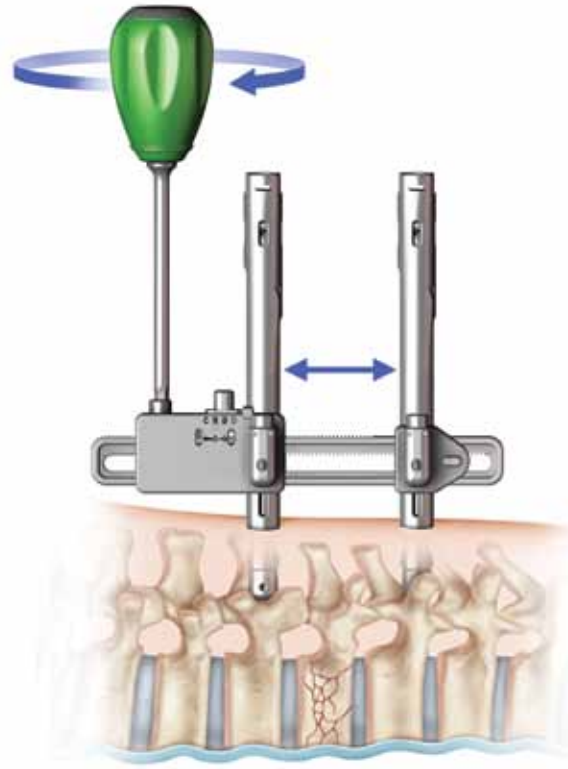


FIGURE 8: Fracture Reduction with Compression/Distraktion Rack

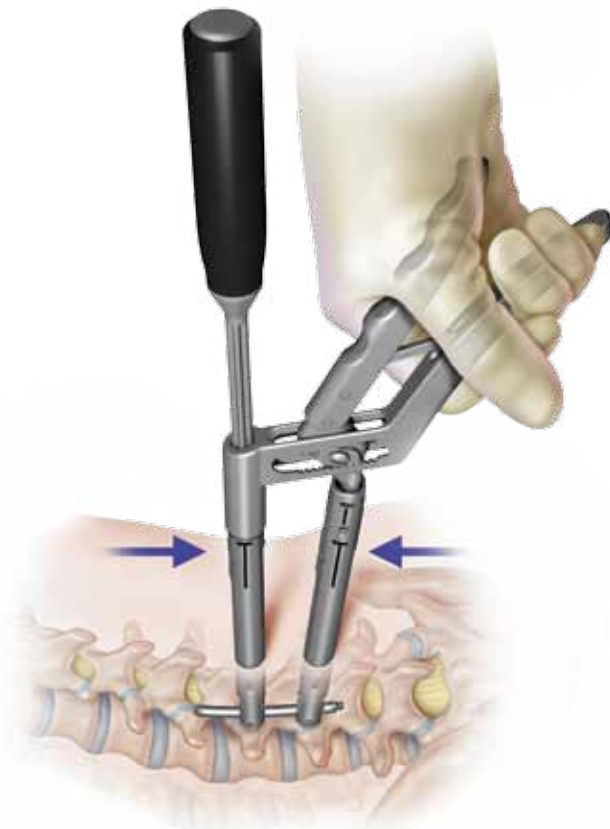


FIGURE 9: Unilateral compression with Compression Forceps

COMPRESSION FORCEPS

- Fast multi-level compression
- Can compress unilaterally to correct coronal deformity

Vertebral Body Derotation (VBD) Options

In trying to achieve three dimensional correction, the role of vertebral body derotation is to address the torsional asymmetry created by scoliosis.^{1,2} Fixed angle pedicle screws like Monoaxial and Uniplanar Screws will offer better control of individual spinal elements, but can also make rod passage more challenging due to their limited mobility compared to polyaxial screws. Care must be taken to use slow and deliberate force while manipulating screws to avoid pedicle fracture and screw pull out. Secondly, surgeons should be mindful not to transfer forces outside to compensatory curves or neutral levels. This can be done by locking neutral levels prior to any derotation maneuvers¹.

TOP LOADING DEROTATION FRAME

- Allows for segmental derotation
- Can be used up the spine for fracture reduction

NOTE: Connects to VIPER 3D Reduction Cap or EXPEDIUM® Spine System Quick Sticks

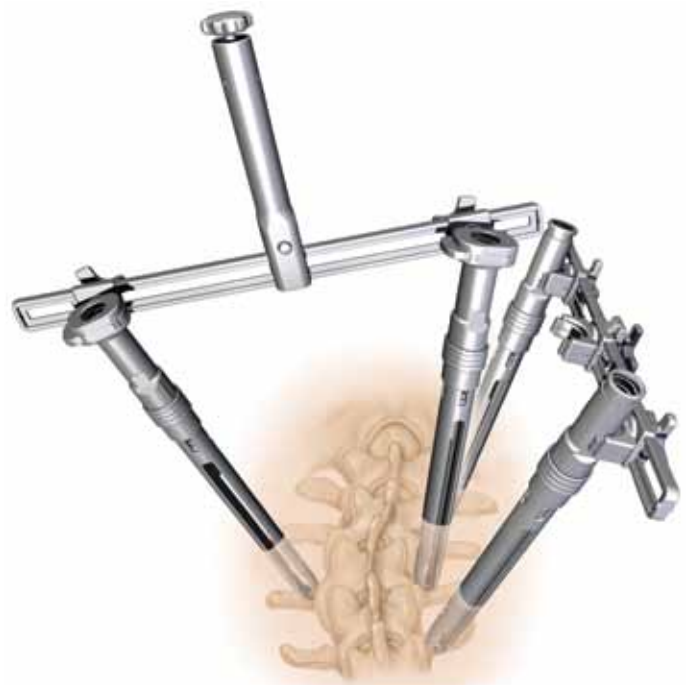

FIGURE 10: Segmental Derotation



FIGURE 11: En Bloc Derotation

SIDE LOADING DEROTATION FRAME

- Link up the spine for *en bloc* derotation
- Link across the spine for segmental derotation

NOTE: Connects to VIPER 3D Reduction Cap, VIPER2 Screw Extension, or EXPEDIUM® Spine System Quick Sticks

Rod Rotator/Introducer Options

Rod Rotation can be a powerful tool in both passing rods through a deformed spine and also in using the rod to correct flexible deformities.^{1,3} A combined Rod Rotator/Introducer is valuable specifically for percutaneous procedures in maintaining control over the rod during rod passage and simultaneously rotating the rod to match the curvature of the spine.

When passing dual curve rods or kyphotic rods, the Rod Rotator can be used to simplify rod insertion. Pre-contoured rods can be introduced to match the orientation of the spine and then rotated as that curvature changes. When passing dual curve rods caudal to cephalad, this technique can be used to introduce the rod into the lordosis of the lumbar spine. Next, rotate the rod 180 degrees into kyphosis to cross the thoracolumbar junction and continue passing the rod up the kyphosis of the thoracic spine.

In the presence of a coronal plane deformity, the lordosis or kyphosis of the rod can be used to facilitate rod placement and then rotation of that rod 90 degrees can facilitate correction.

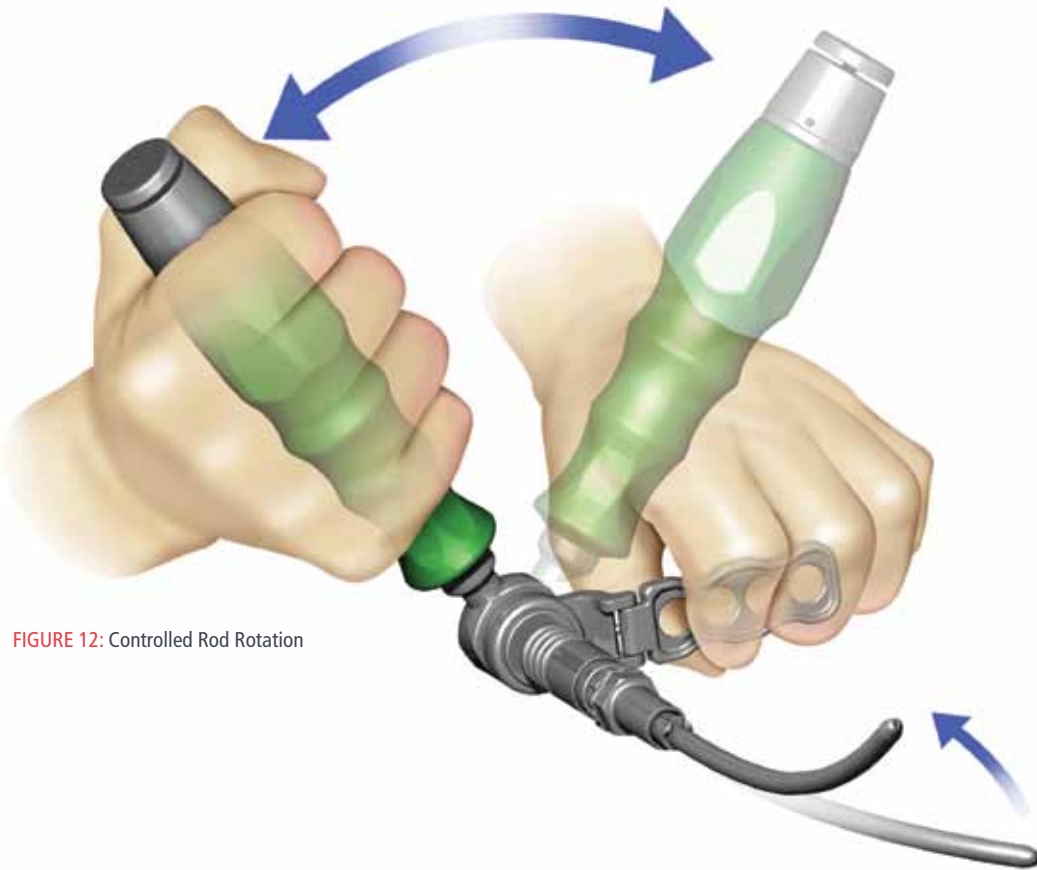


FIGURE 12: Controlled Rod Rotation

Rod Rotator/Introducer Options

ROD ROTATOR/INTRODUCER

- Allows for controlled rotation of pre-contoured rods during rod introduction

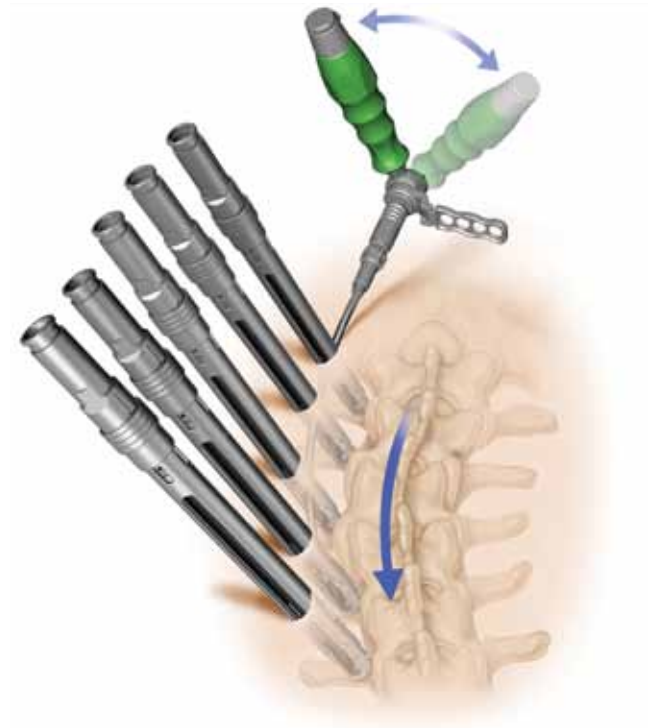


FIGURE 13: Rod introduction using the Rod Rotator

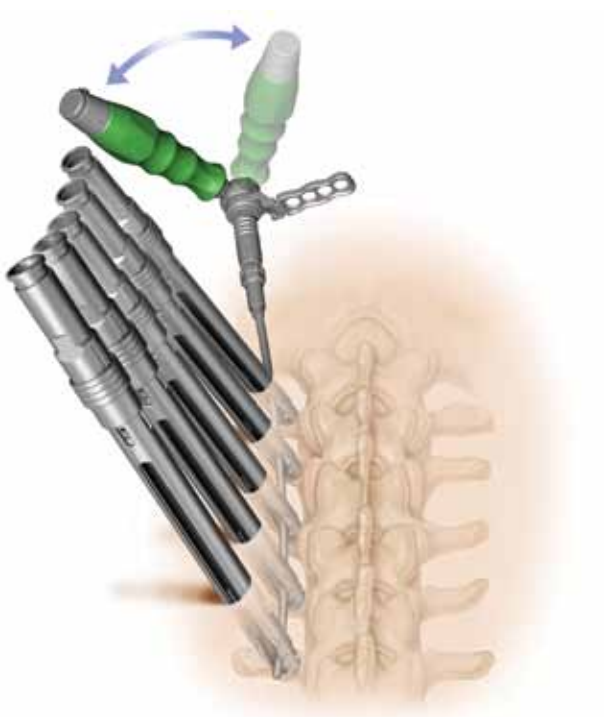


FIGURE 14: Rod Rotation to correct deformity

INTENDED APPLICATIONS

1. Introduce a lordosed rod into a coronal plane deformity, then rotate 90 degrees to correct deformity and seat rod in to sagittal alignment
2. Introduce a dual curve rod in lumbar spine matching the lordosis, then at the thoracolumbar junction rotate 180 degrees to pass into the thoracic spine

Outline of MIS Deformity Surgical Procedure



Outline of MIS Deformity Surgical Procedure

Before applying MIS techniques to deformity correction, the basic skills of MIS should be mastered and applied over cases of varying complexity. More rigid curves should be avoided until a comfort level has been reached performing anterior releases, minimally invasive osteotomies, and other difficult maneuvers to facilitate three dimensional correction.

Surgical considerations will vary with surgeon experience and may change with the advent of new technologies and techniques. At the moment, it is generally accepted that these surgical considerations may include a grade three or higher spondylolisthesis, rigid curves with severe sagittal or coronal imbalance, tissue depth or body mass index (BMI) that would prevent use of MIS instruments from accessing or viewing critical anatomy, and/or osteopenia preventing adequate imaging of critical anatomy.

There are many methods used for MIS approaches to address complex spinal pathologies. With increased experience, surgeons learn various techniques and develop their preferred method of choice for patient treatment based on the individual anatomy. It is also important to consider the types of pathologies amenable to an MIS approach, as discussed earlier in this monograph. The following information outlines many of the typical steps completed during an MIS deformity correction procedure.

Interbody Fusion Options for the Restoration of Sagittal and/or Coronal Balance

For deformities which result from degenerative disc disease, much of the correction achieved through minimally invasive procedures can be achieved through the use of interbody devices from various approaches. Strategic placement of interbody cages can provide much of the required corrective action along with indirect decompression of the neural elements.

NOTE: For a comprehensive surgical technique on Lateral Interbody Fusion, refer to the COUGAR® LS Surgical Technique Guide.

1. LATERAL INTERBODY FUSION

- Plan the incision based on the direction of the lumbar and thoracic curve.
- Making the incision on the concave side of the curve will allow access to multiple levels from the same incision, however the disc space will be compressed due to the deformity. Several incisions may be necessary to access the all levels.
- Anterior releases should be performed under fluoroscopic guidance to prevent iatrogenic endplate violation.

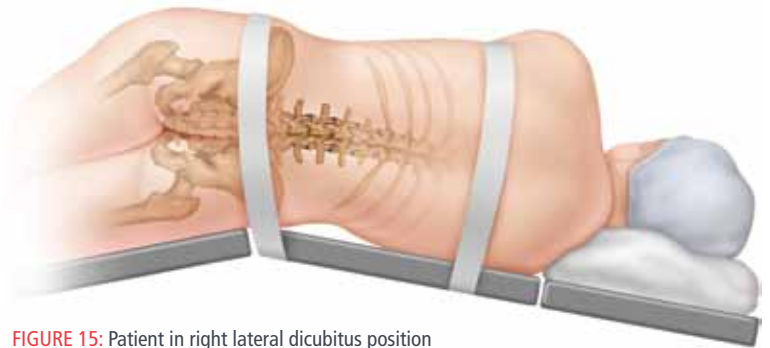


FIGURE 15: Patient in right lateral decubitus position

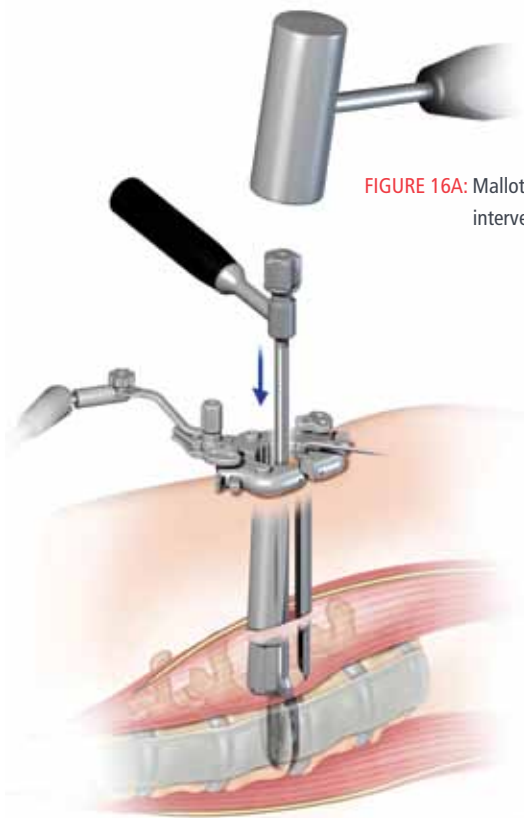


FIGURE 16A: Malleting COUGAR LS into intervertebral space

- Approaching from the convexity will allow the disc space to be easily accessed from the “open” side of the disc without fear of damaging the endplates. The approach should be based on surgeon experience and patient pathology.
- To achieve the necessary flexibility to correct the deformity, it is critical to perform a full discectomy and release of the interbody space.
- Use as large a cage as possible to aid in the restoration of height and also proper sagittal and coronal balance.

Interbody Fusion Options for the Restoration of Sagittal and/or Coronal Balance

2. POSTERIOR TRANSFORAMINAL INTERBODY FUSION

NOTE: For a comprehensive surgical technique on Posterior Transforaminal Interbody Fusion, refer to the CONCORDE™ Bullet Surgical Technique Guide.

- Posterior Transforaminal Interbody Fusions can be used as the primary fusion approach at levels where a Lateral Interbody Fusion procedure is not favorable.

- For surgical access, a SPOTLIGHT® Port can be used through percutaneous incisions or the PIPELINE™ Expandable Retractor can be used in a mini-open fashion.

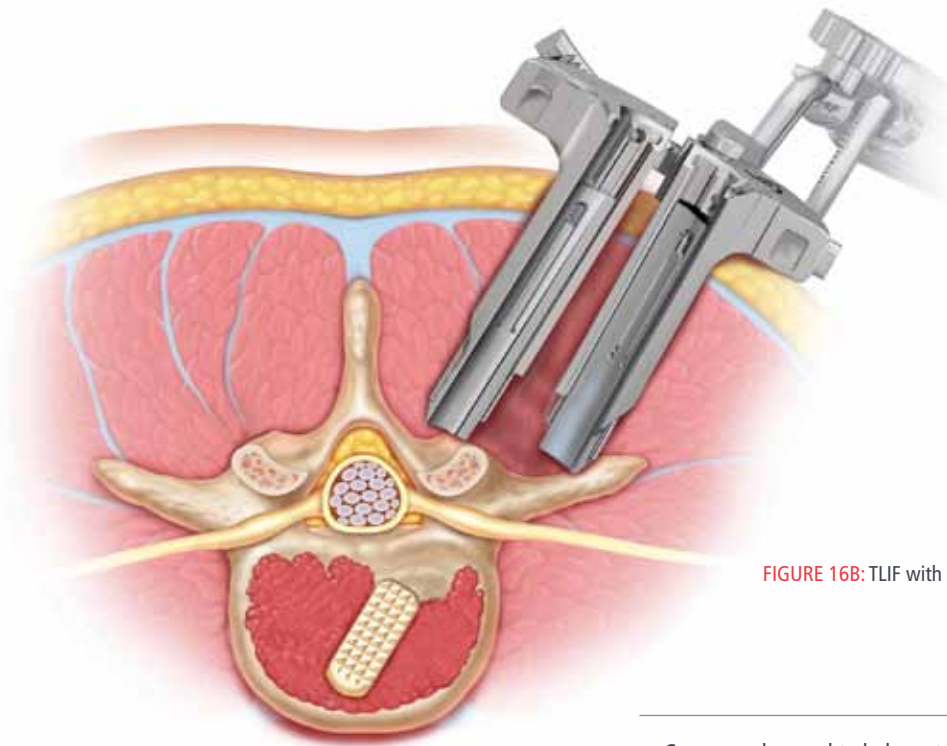


FIGURE 16B: TLIF with PIPELINE Expandable

- Cages can be used to help restore sagittal balance, but also used to restore coronal balance through a modified unilateral TLIF⁴. Placement of a single cage on the concave side of a scoliotic spine while also applying asymmetrical compressive forces to the pedicle screw construct can result in excellent coronal curve correction. This simultaneously allows for adequate autogenous bone graft to be placed on the convex side of the interbody space.

*Pedicle Cannulation
and Posterolateral Fusion Preparation*



Pedicle Cannulation

- Pedicle cannulation should be performed prior to any bony destruction, due to the potential of “losing” landmarks during facet excision.

NOTE: Consider making skin incisions in the medial/lateral direction with musculofascial incisions in the cephalad/caudal direction. This avoids having small skin bridges in between incisions and may assist in healing.

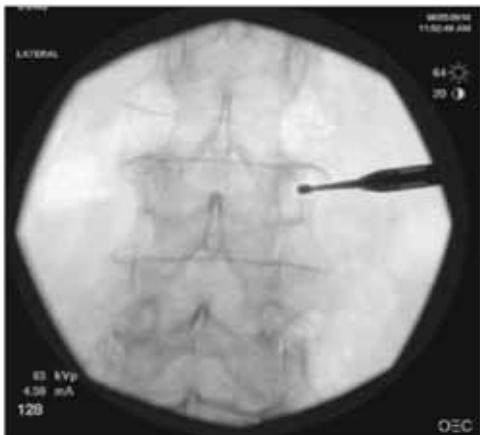


FIGURE 17A: A/P fluoro image showing burr docked on lateral aspect of the pedicle



FIGURE 17B: Cannulated Pedicle Probe

- Docking a Jamshidi needle at the apex of a bony prominence may be difficult in the presence of sclerotic bone or a hypertrophied facet, thus a burr may be utilized to create a starting point. Once a docking point has been created under fluoroscopic guidance, a Jamshidi needle or Cannulated Pedicle Probe shaft can be reintroduced and advanced in a standard fashion.

- Prior to screw placement, it is an option to aspirate bone marrow from each pedicle using a Jamshidi needle^{5, 6}. This source of marrow may reduce time and morbidity associated with iliac crest harvest. The aspirate can then be mixed with a variety of bone graft substitutes, such as HEALOS® Fx Injectable Bone Graft Replacement, that are often used in spinal fusion procedures.

Posterolateral Fusion Preparation

NOTE: If possible, use the same incisions for facet excision, decortications, and osteotomies.

FACET FUSION

- Make separate bilateral fascial incisions at each level around each Guidewire.
- It is recommended to use either a 15 or 18 mm SPOTLIGHT Port. If larger access is needed, the PIPELINE Expandable Retractor or similar type retractor can be used.

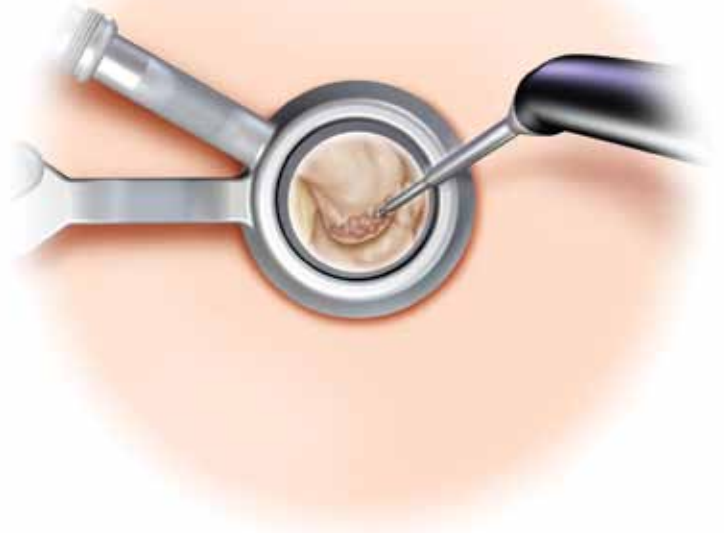

FIGURE 18: Facet excision and decortication through a SPOTLIGHT Port

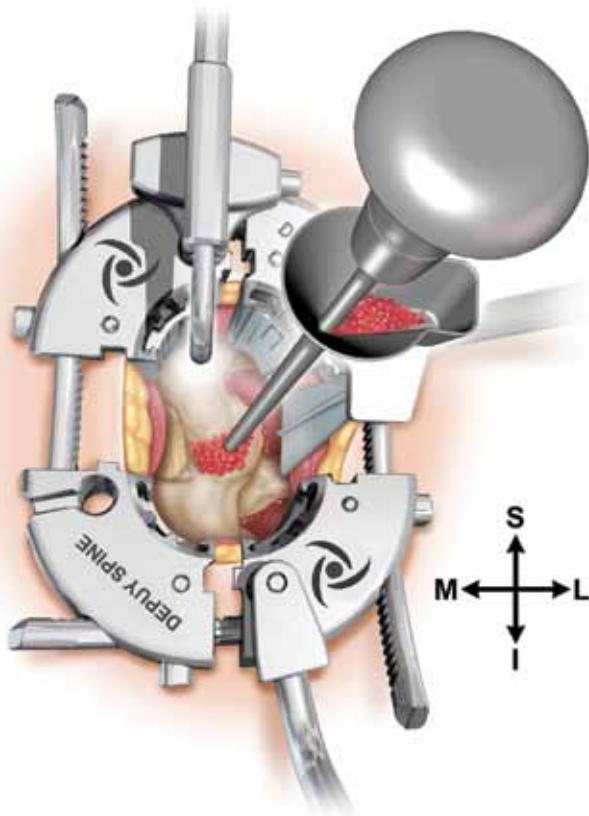


FIGURE 19: Bone graft being packed in to facet through PIPELINE EXPANDABLE retractor

- For port use, dilate muscle over guide-wire while “wandering” the port up to the facet. Dilation can also occur along side of the Guidewire.
- Insert port around dilators.
- Use reamers or sheathed burrs to decorticate facets as necessary.

Posterolateral Fusion Preparation

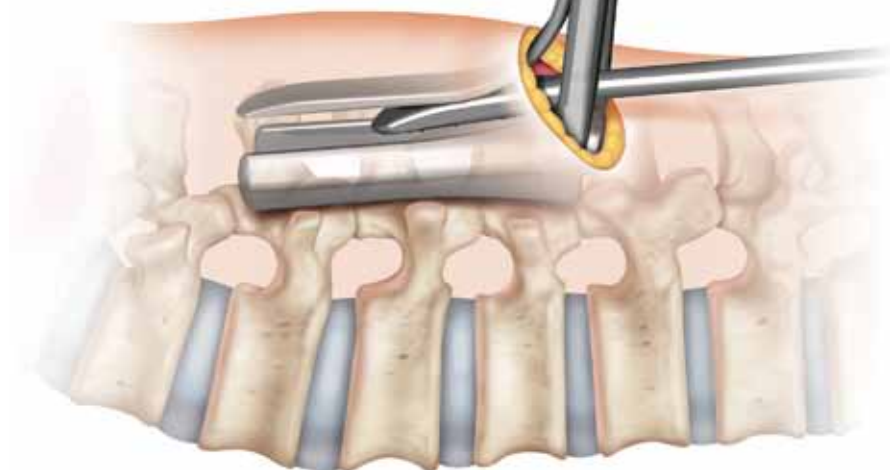
TRANSVERSE PROCESS AND LAMINA DECORTICATION

- If necessary, a multi-level "tunneling" approach may be performed to quickly perform access the lamina, facets, and/or transverse processes of adjoining levels.



- Insert retractor to elevate muscle and allow for interlaminar and/or intertransverse decortication and fusion.

FIGURE 20: Retractor for posterolateral fusion



- Use posterolateral fusion instruments such as rasps and reamers to decorticate.
- Decortication can be accompanied by haemostatic agents to reduce bleeding.

Osteotomies

If necessary, a minimally invasive Ponte osteotomy may be performed for either sagittal and/or coronal plane correction⁷. If segmental Kyphosis (T5-T12) is 10 degrees or less, mini-open Ponte Osteotomies may be performed at appropriate levels.

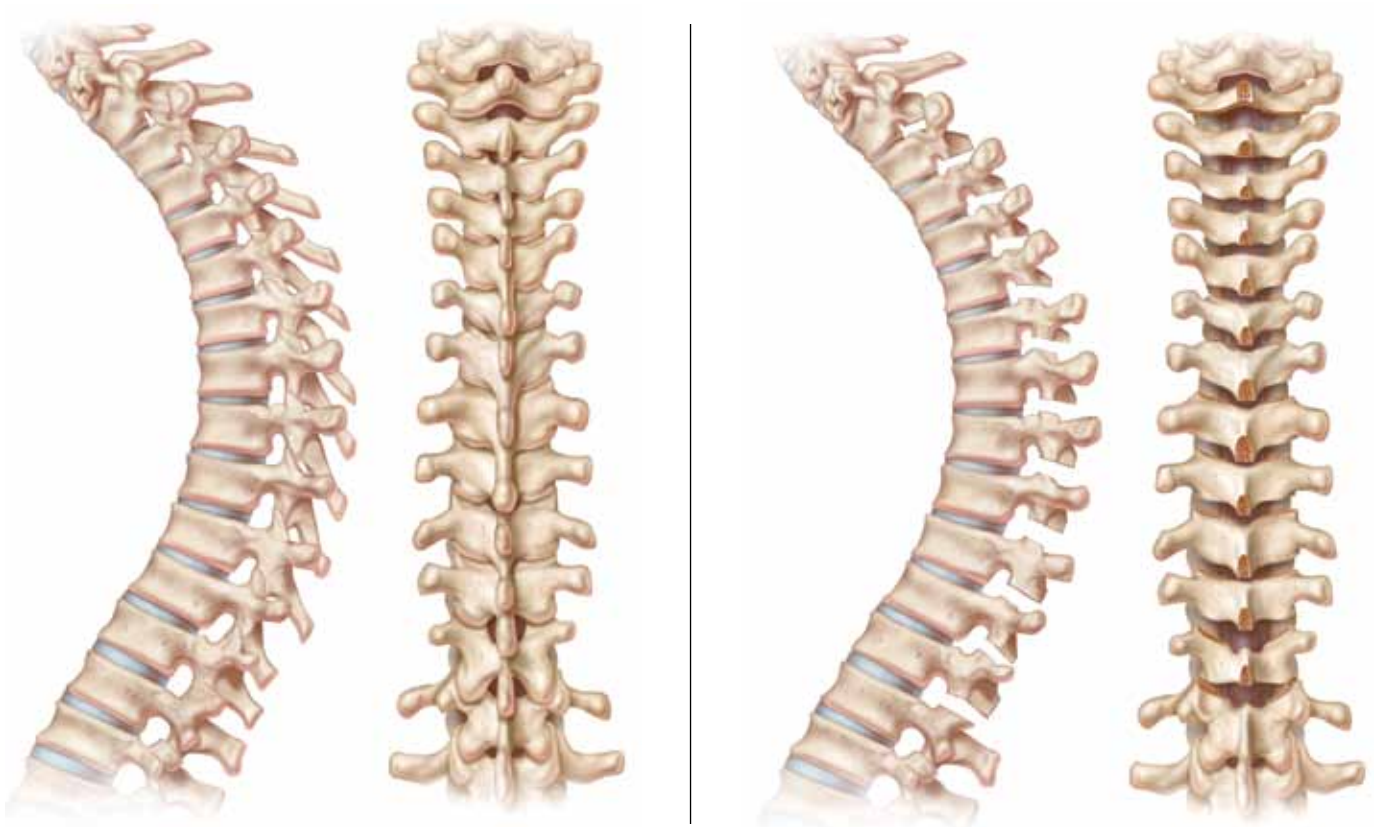


FIGURE 21: Osteotomy to further correct spine

- For single level osteotomies, if possible, extend and utilize the same incisions used for the facet fusions. If necessary, make separate bilateral incisions directly over the facet at the level that an osteotomy is needed.
- If multiple osteotomies are needed, utilize a single Wiltse incision centered on the middle level. It is recommended to use a PIPELINE Expandable Retractor for access.

- Access to the interspinous ligament can be achieved by "wandering" the retractor towards the midline.

Bone Graft Placement

There are several recommended methods for bone graft placement to aid in achieving posterolateral fusion via inter-facet, inter-lamina and/or inter-transverse process techniques. The exact method, or combination of methods, is dependent upon bone graft indications, surgeon experience, levels being treated, and surgical need.

It is highly recommended to perform at least one of following fusion methods at EVERY instrumented level.

1. HEALOS Fx Injectable Bone Graft Replacement mixed with autologous marrow, can be placed directly into the open facet joint (Fig 19). Ensure the joint is well packed with bone graft to maximize the surface area of the fusion.
2. HEALOS or HEALOS Fx Bone Graft Replacements mixed with autologous marrow, can be placed from lamina to lamina, or transverse process to transverse process, then covered by allograft or autograft if desired.

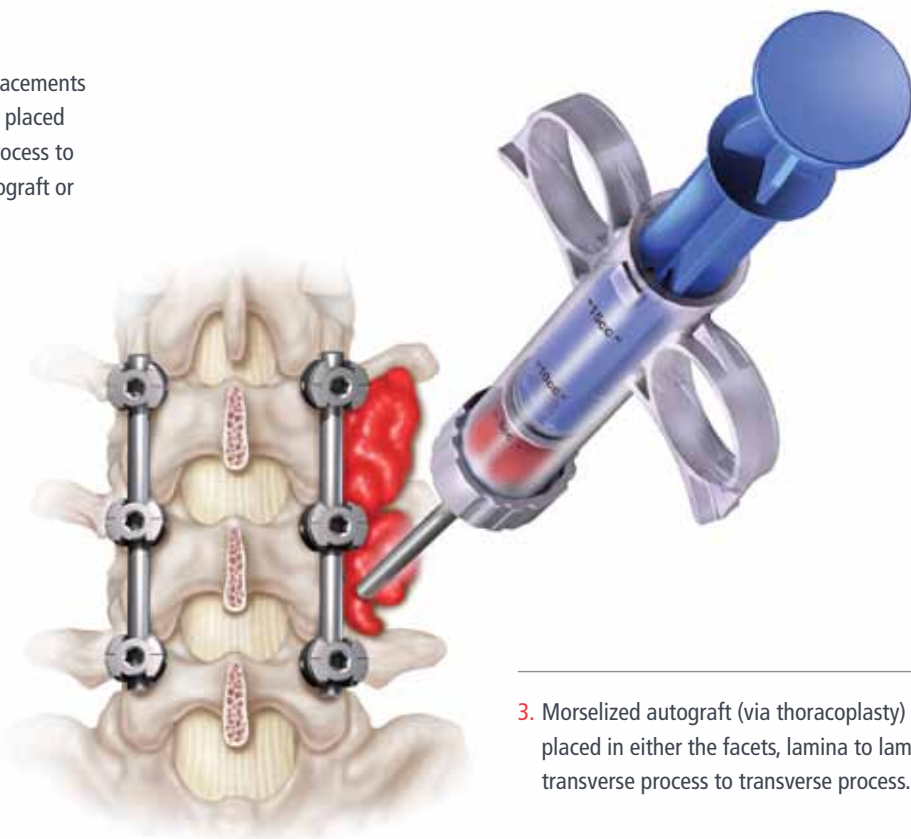


FIGURE 22: HEALOS Fx injected for posterolateral fusion

3. Morselized autograft (via thoracoplasty) can be placed in either the facets, lamina to lamina, or transverse process to transverse process.

NOTE: For a comprehensive surgical technique on HEALOS or HEALOS Fx Bone Graft Replacements, refer to their respective Surgical Technique Guides.

Posterior Deformity Correction Options



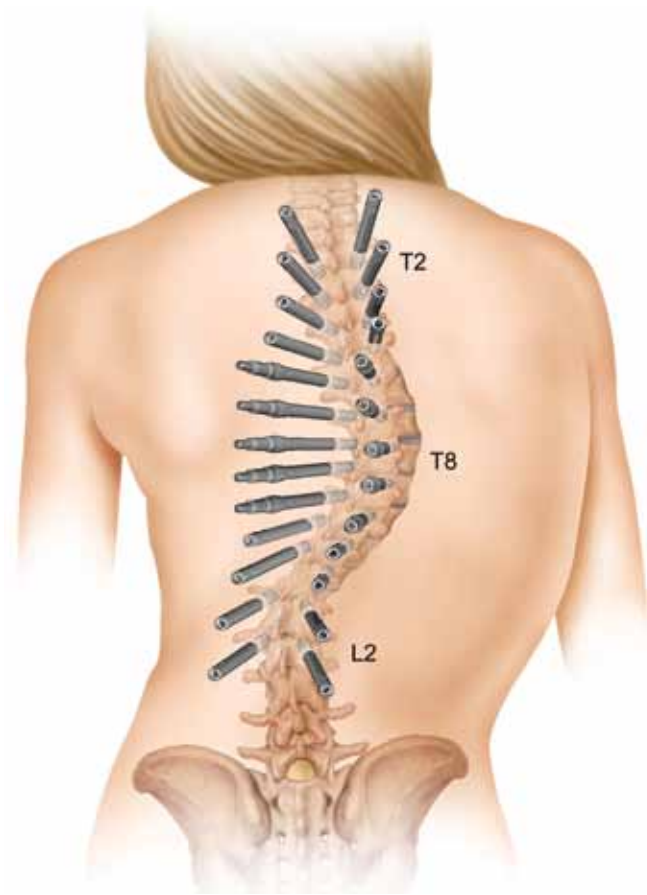
Posterior Deformity Correction Options

For most levels, cannulated Ti polyaxial screws should be used. In cases where moderate to severe derotation is required or for levels at the apex of the curve, cannulated uniplanar screws may be used to facilitate easier derotation. It can also be useful to place alternating closed extensions and extended tab screws at the apex to reduce crowding and facilitate rod approximation.

NOTE: 1) In osteoporotic patients, care should be taken to avoid screw pull out or pedicle fracture during forceful maneuvers such as derotation or translation.

2) For levels where a mini-open exposure has already been performed, it may be easier to use non-cannulated instruments and implants.

Deformity Correction



In treating true three dimensional deformities in the sagittal, coronal, and axial planes, vertebral body derotation has become an invaluable tool in treating the rotational component affecting the ribs and trunk. Segmental pedicle screw fixation distributes the load across multiple implants to pull the concavity out of the chest and reducing the convex rib deformity while decreasing the need for thoracoplasty. Identical to an open corrective deformity procedure, translation, reduction and derotation maneuvers are utilized to gain optimal a balanced three dimensional correction.

Uniplanar screws may offer better axial plane control of the vertebral body as compared to polyaxial screws thus placing them in the apical area of the construct should allow for more controlled manipulation of spinal elements. Care should be taken not to overload the screw/bone interface, or the screw/screw extension interface.

Vertebral body derotation can be achieved with either an *en bloc* method, by linking up the spine, or segmentally, by linking across the spine.

FIGURE 23: Skeletally Mature Idiopathic Scoliosis patient instrumented percutaneously from T2 to L2

Option 1: “Rod First” Technique

There are two generally accepted options for correcting a deformity minimally invasively. One uses the rod to perform the correction and the other holds the correction with external frames prior to placing the rod. Either option can be used to correct deformities depending on surgeon preference, curve flexibility, interbody release, and cage placement.

STEP 1

- A properly contoured rod can be introduced using a ratcheting rod rotator. The rod can be advanced segmentally up the spine toggling between a locked rod angle and the ratcheting position to simultaneously advance and rotate the rod to correct the spine.

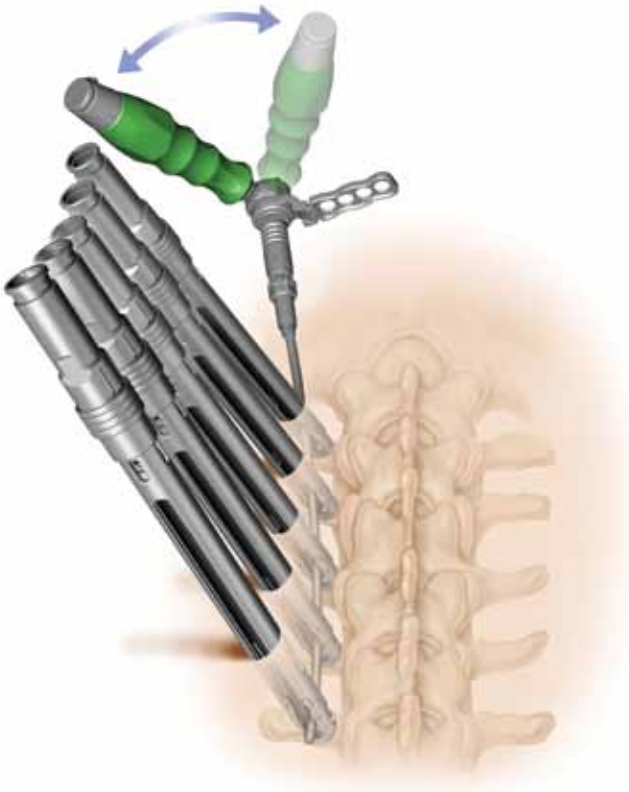


FIGURE 25: Lordosed rod rotated 90 degrees to match sagittal plane and simultaneously correct coronal deformity

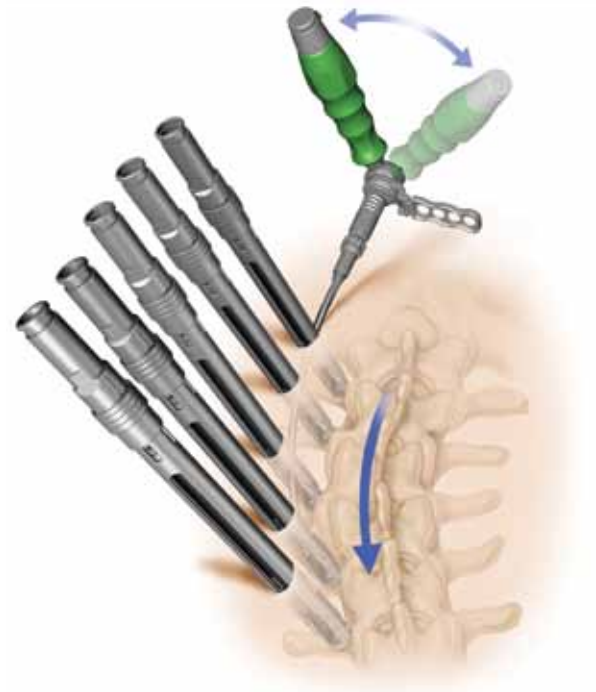


FIGURE 24: Rod being introduced using rod rotator matching lordosis of the rod to the coronal deformity

STEP 2

- Once the rod has been loosely captured in all screws, the rod can then be rotated to further correct the spine by rotating the coronally bent rod in to the sagittal plane.
- Rods can then be reduced into place. It is important to distribute the force of reduction across several screws at a time by sequentially reducing the rod down and not reducing off of one screw at a time.

NOTE: For thoracolumbar scoliosis, performing a rod rotation maneuver as described in the Cotrel-Dubousset technique while simultaneously pushing down on the convex ribs should result in translation of the spine dorsally and medially.

Option 2: Deformity Correction Using External Frames

The Derotation Racks can be used as an external frame on either the VIPER2 Extension and/or EXPEDIUM Quick sticks to facilitate deformity correction. This technique can be employed for curves that may be somewhat flexible and able to withstand the forces of segmental manipulation. Cannulated uniplanar screws can be used at the apex of the curve to help facilitate segmental or en bloc derotation maneuvers.

STEP 1

- Determine which levels will be used as “anchor” neutral levels. Attach a side loading rack to those levels.
- Attach the side loading rack to a table mounted rigid arm using the rigid arm attachment. Two attachments may be required for stiff curves.

STEP 2

- Connect the appropriate amount of modular clamps to the side loading rack.
- Assemble the Top Loading Derotation Racks bi-laterally on levels requiring derotation.
- Lock the orientation of the extensions to facilitate the optimal control of each level.

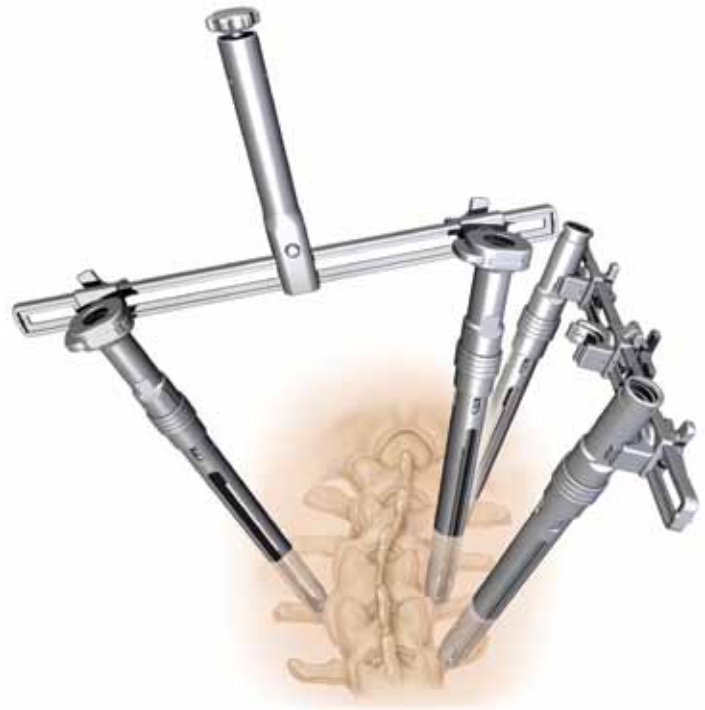

FIGURE 26: Segmental derotation




FIGURE 27: En bloc derotation

STEP 3

- Carefully rotate the assembly to meet the side loading rack. A modular handle can be used to facilitate easier de-rotation.
- Hold the now derotated level in alignment by locking the appropriate extension or quick stick to the side loading rack using the modular clamps.
- Repeat for subsequent levels.

Rod Placement

STEP 1

- It is generally suggested to pass the rod from “top to bottom,” cephalad to caudal. For many cases, this is the easiest rod passing technique due to the relative shallowness of the tissue in the upper thoracic areas of the spine. However, depending on the specific deformity and patient anatomy, it may be easier to pass in the opposite direction from caudal to cephalad. Ultimately, the rod passing direction should be chosen based on each surgeon’s technique, the specific patient anatomy, and levels instrumented.

NOTE: It is critical to get below the fascia with the tip of the rod when introducing through the first screw extension. If the tip of the rod is not subfascial on the initial pass, it will remain above the fascia. This can cause difficulty when reducing, possibly leading to screw pull out or screw extension pop off.

STEPS 2, 3 & 4

- If little or no derotation is needed, it is generally suggested to pass the rod on the convex side of the deformity first. The rod can then be loosely captured on that side prior to passing the concave side.
- Once the rod is in position, insert set screws into the proximal and distal screw heads. These screws should be firmly tightened to control unintended rod rotation and unintended leveling of top and bottom instrumented vertebral bodies.
- Gradually reduce the rod at the apex by reducing at several levels sequentially. This can be accomplished using extended tab screws or reduction instruments. Rod reduction should be done across several levels to adequately distribute the force across several screws at a time.

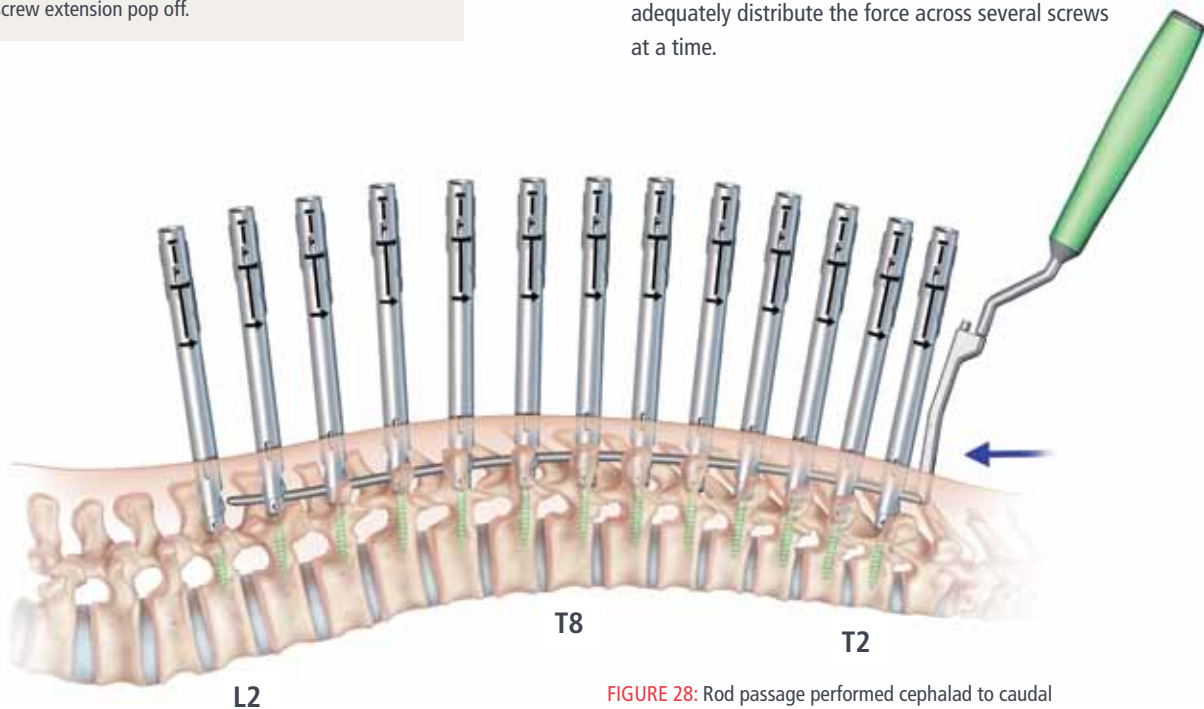


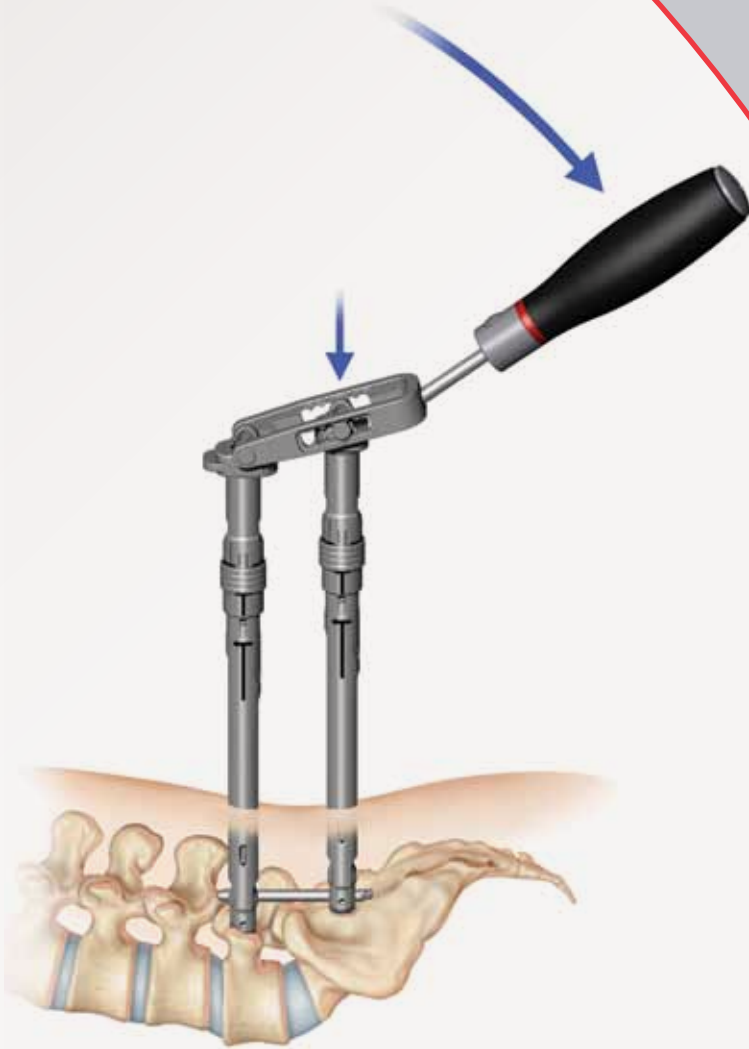
FIGURE 28: Rod passage performed cephalad to caudal

STEP 5

- Once the apex is translated and the rod is seated, insert set screws into the remainder of the screws.

NOTE: For thoracolumbar scoliosis, it is generally suggested to introduce the rod from cephalad to caudal. The rod should be fully seated in the distal screw first and then gradually be reduced into each proximal screw until the rod is fully seated.

Spondylolisthesis Correction



Spondylolisthesis Correction

Single level, high grade spondylolistheses can be reduced either using an implant only approach (based off the interbody cage and reduction screws) or by using supplemental instrumentation to lever off of a locked neutral level. With the latter technique, leaving the rod proud above the level of the listhesis and levering down onto the neutral level should result in pulling the slipped vertebral body into proper alignment to allow for set screws to capture and hold the correction. Adequate anterior release may be necessary to allow for proper reduction.

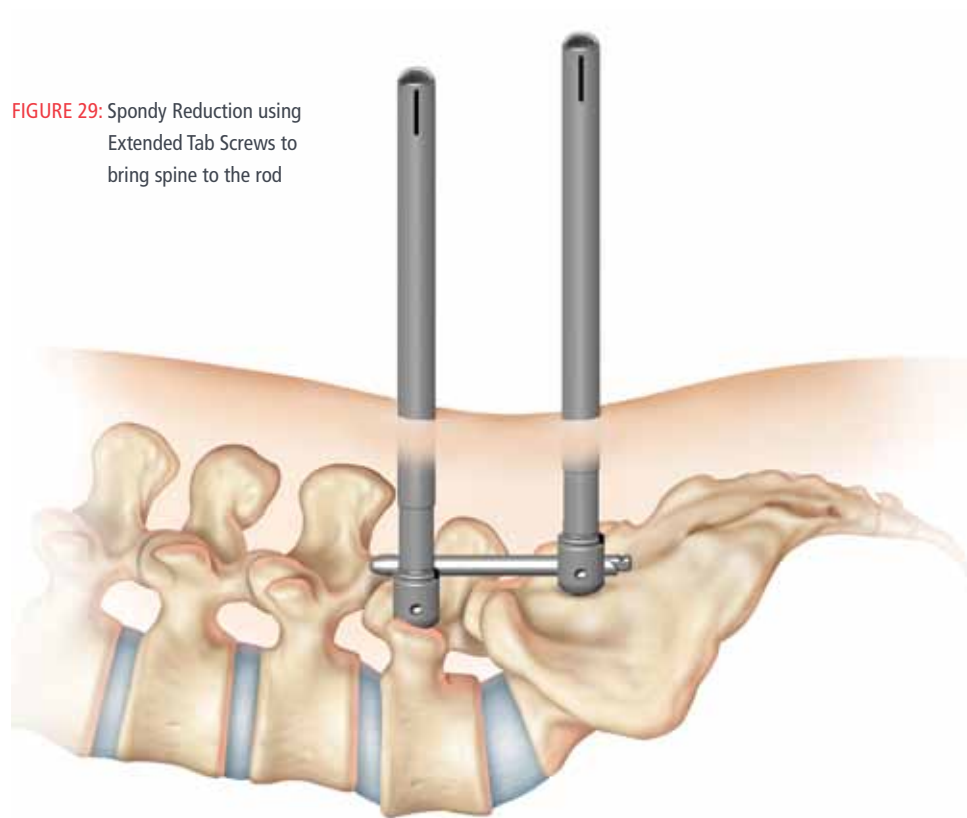


FIGURE 29: Spondy Reduction using Extended Tab Screws to bring spine to the rod

NOTE: Care should be taken in the presence of osteopenia to avoid screw pullout and pedicle fracture. Sleeves should be used when reducing with extended tab screws.

- After final tightening the neutral levels, the reduction threads of the Extended Tab Screws are used to persuade the misaligned vertebral bodies up into proper alignment by turning down the set screw.

Spondylolisthesis Correction

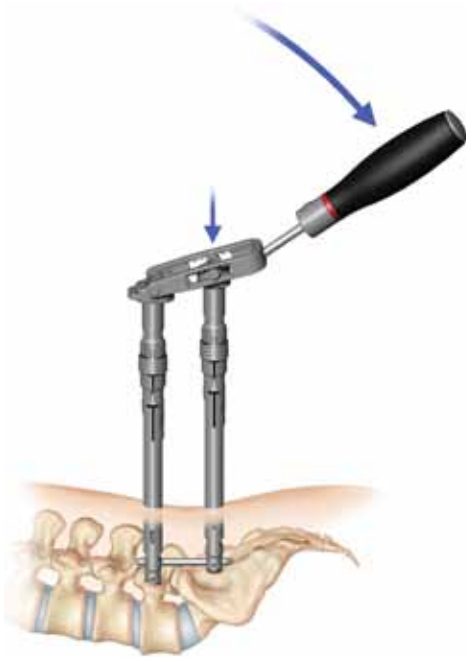


FIGURE 30: Spondy Lever used to bring L5 body back to proper alignment

NOTE: The Spondy Reduction Lever should be used bilaterally and it is recommended to monitor the progression of the reduction via lateral fluoroscopy.

- When using the Spondy Reduction Lever, the rod should be in place (proud above the level of the spondy) and the set screw of the neutral level should be final tightened. Levering down on the neutral level should result in a posterior movement of the anteriorly slipped vertebral body.

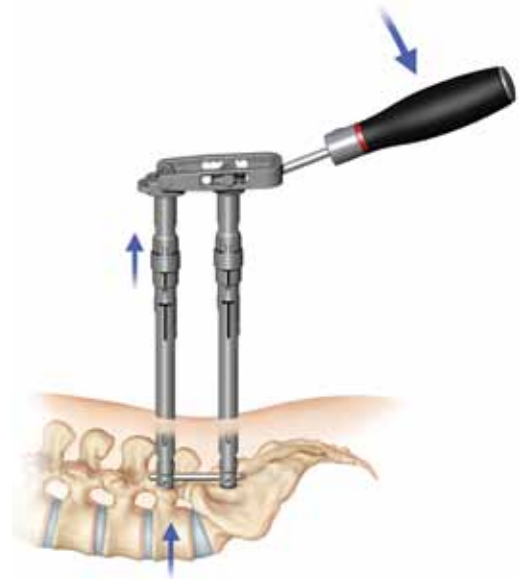


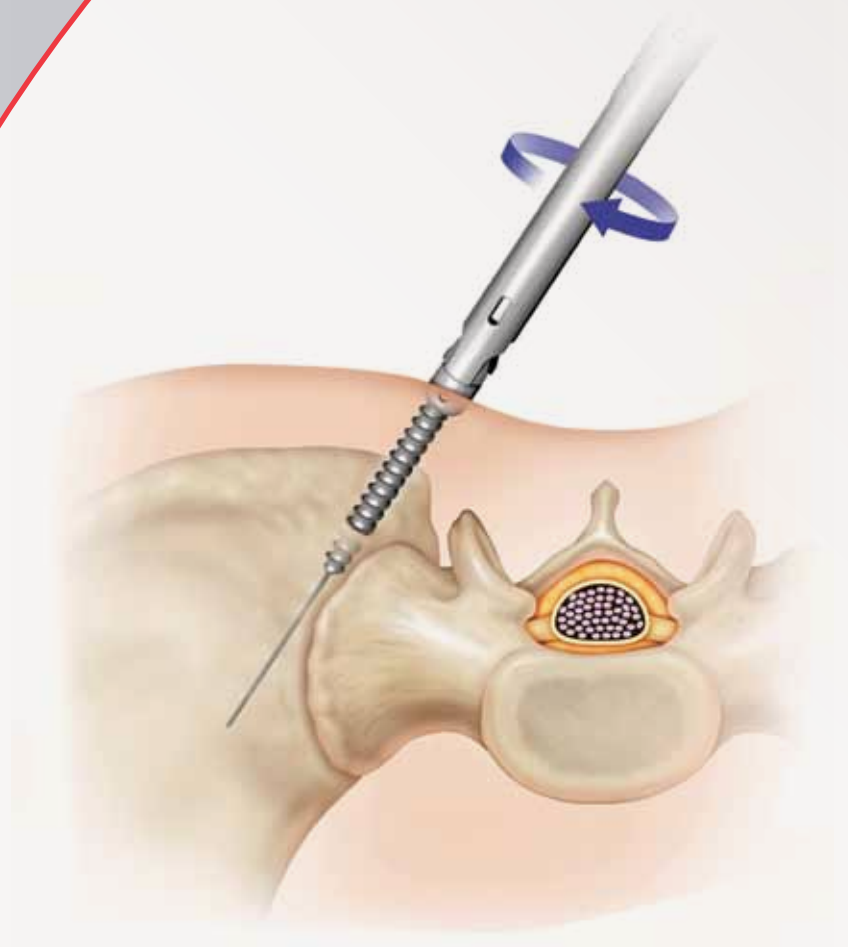
FIGURE 31: Spondy Lever pulling L5 vertebral body up by leveraging down on S1

- This technique can also be used to restore lumbar lordosis in deformity cases.

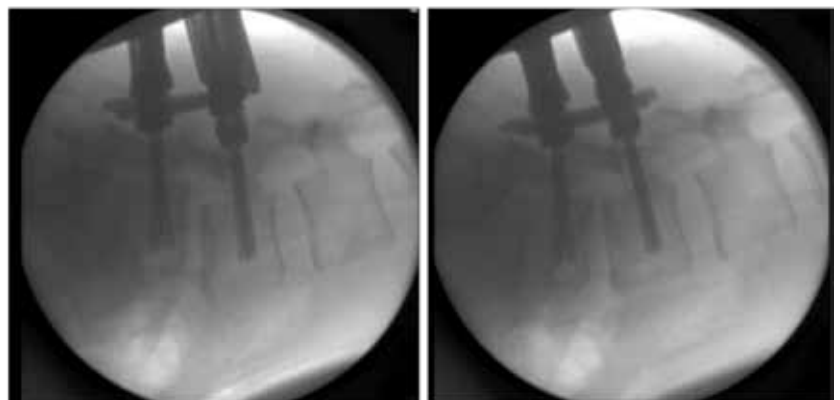

FIGURE 32: Before (left) and After (right) Lateral Fluoro images of spondylolisthes correction using VIPER Spondy Reduction Lever

Pelvic Fixation



Pelvic Fixation

Pelvic fixation is an important tool in spinal stabilization and provides anchor points in long constructs to treat coronal and sagittal plane deformities. Although the placement of iliac screws has become widely accepted since first described by Allen and Ferguson⁹, the technique requires significant lateral muscle dissection. This has led many surgeons to try alternate techniques for solid stabilization points near the sacro-iliac junction. One such technique, described by Wang¹⁰, uses the principles of MIS to safely target, cannulate, and place screws into the ilium.

- Three methods for linking a spinal construct to the pelvis via a minimally invasive technique are:
 1. Using standard gelpe retractors, a mini-open technique can be employed whereby a lateral bend is created in the rod (in the coronal plane) and the rod is simply laid in to place after being passed subfascially through the inline screw construct.

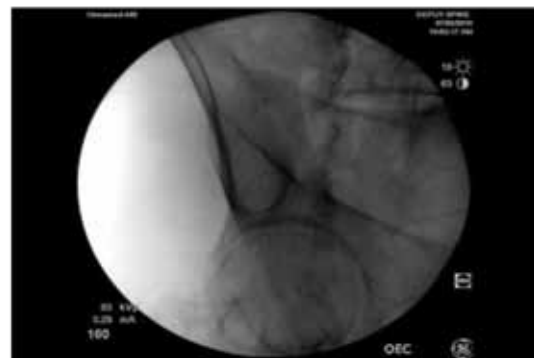

FIGURE 33: Fluoroscopic "tear drop" view showing both inner and outer tables of the ilium

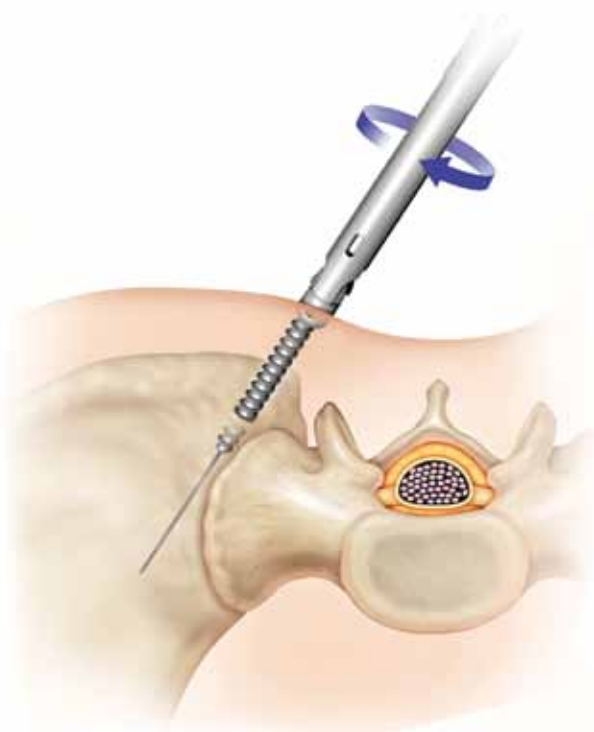


FIGURE 34: Screw being placed percutaneously in to ilium

2. A lateral connector can be employed in a minimally invasive fashion to connect the laterally offset iliac screw to the inline pedicle screw construct.
 - a. Place an appropriately sized screw onto a screw extension, insert over the Guidewire, and thread into the ilium.
 - b. Place a lateral connector onto a screw extension and insert a monoaxial screw driver down through the screw extension to lock the angle of the rod on the connector. The extension can now be used as a rod holder to pass the connector.
 - c. Pass the lateral connector from medial to lateral by placing it subfascially into the adjacent screw/screw extension while attached to the screw extension and monoaxial driver.
 - d. Lock into place with a set screw. The lateral connector/screw extension assembly should now be in-line with the lumbar pedicle screws and allow for linking up to the pelvis. The monoaxial driver can be removed from the lateral connector/screw extension assembly.




FIGURE 35: Polyaxial lateral connector being locked using a monoaxial screw driver

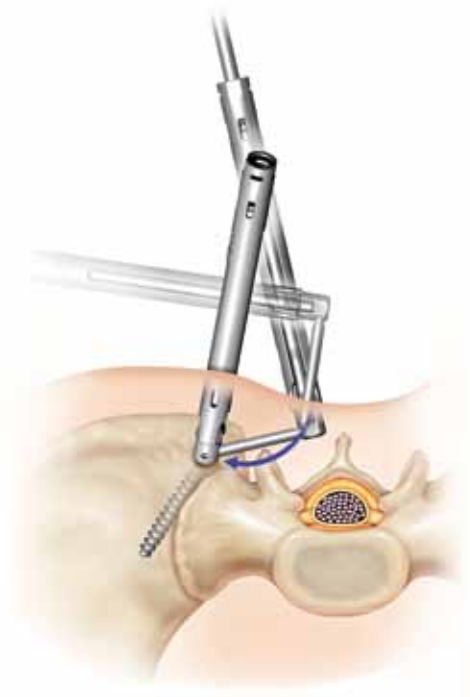


FIGURE 36: Lateral connector being placed subfascially into the offset screw

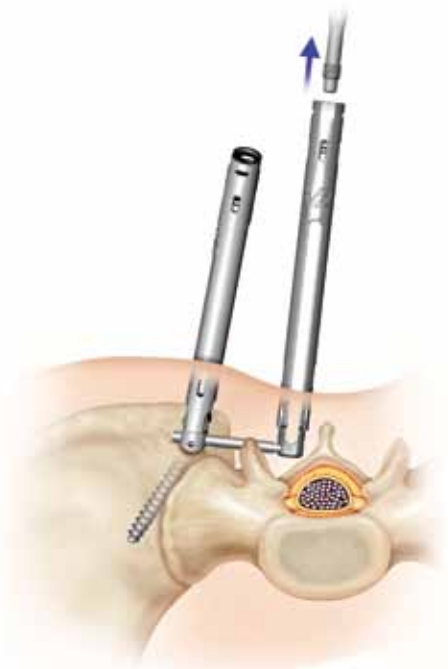

FIGURE 37: Monoaxial screwdriver being removed from screw extension making offset screw now inline for rod passage

3. As another option, an inline technique allows for cannulation of the column of iliac bone from the inner table of the posterior superior iliac spine towards the anterior superior iliac spine which facilitates connection to the thoracolumbar pedicle screws.

References

1. Shah, S.A., *Derotation of the Spine*. Neurosurgery Clinics of North America, 2007. **18**(2): p. 339-345.
2. Chang, M.S. and L.G. Lenke, *Vertebral Derotation in Adolescent Idiopathic Scoliosis*. Operative Techniques in Orthopaedics, 2009. **19**(1): p. 19-23.
3. Ito, M., et al., *Simultaneous double-rod rotation technique in posterior instrumentation surgery for correction of adolescent idiopathic scoliosis*. Journal of Neurosurgery: Spine. **12**(3): p. 293-300.
4. Heary, R.F. and R.J. Karimi, *Correction of lumbar coronal plane deformity using unilateral cage placement*. Neurosurgical Focus, 2010. **28**(3): p. E10.
5. McLain, R.F., et al., *Aspiration of osteoprogenitor cells for augmenting spinal fusion: comparison of progenitor cell concentrations from the vertebral body and iliac crest*. Journal of Bone & Joint Surgery – American Volume, 2005. **87**(12): p. 2655-61.
6. McLain, R.F., et al., *Transpedicular aspiration of osteoprogenitor cells from the vertebral body: progenitor cell concentrations affected by serial aspiration*. Spine Journal: Official Journal of the North American Spine Society, 2009. **9**(12): p. 995-1002.
7. Voyadzis, J.-M., et al., *Minimally invasive posterior osteotomies*. Neurosurgery, 2008. **63**(3 Suppl): p. 204-10.
8. Vallespir, G.P., et al., *Vertebral coplanar alignment: a standardized technique for three dimensional correction in scoliosis surgery: technical description and preliminary results in Lenke type 1 curves*. Spine, 2008. **33**(14): p. 1588-97.
9. Allen, B.L., Jr. and R.L. Ferguson, *The Galveston technique for L rod instrumentation of the scoliotic spine*. Spine, 1982. **7**(3): p. 276-84.
10. Wang, M.Y., et al., *Percutaneous iliac screw placement: description of a new minimally invasive technique*. Neurosurgical Focus, 2008. **25**(2): p. E17.
11. Wang, M.Y., et al., *An analysis of the differences in the acute hospitalization charges following minimally invasive versus open posterior lumbar fusion*. Journal of Neurosurgery Spine, 2010. **12**(5): p. 694-9.

INDICATIONS

The VIPER® Spine System is intended to provide immobilization and stabilization of spinal segments in skeletally mature patients as an adjunct to fusion in the treatment of acute and chronic instabilities or deformities of the thoracic, lumbar and sacral spine.

The VIPER Spine System metallic components are intended for noncervical pedicle fixation and nonpedicle fixation for fusion for the following indications: degenerative disc disease (defined as back pain of discogenic origin with degeneration of the disc confirmed by history and radiographic studies); spondylolisthesis; trauma (i.e., fracture or dislocation); spinal stenosis; curvatures (i.e., scoliosis, kyphosis, and/or lordosis); tumor, pseudoarthrosis; and failed previous fusion in skeletally mature patients.

When used in a posterior percutaneous approach with MIS instrumentation, the VIPER System metallic components are intended for noncervical pedicle fixation and nonpedicle fixation for fusion for the following indications: degenerative disc disease (defined as back pain of discogenic origin with degeneration of the disc confirmed by history and radiographic studies); spondylolisthesis; trauma (i.e., fracture or dislocation); spinal stenosis; curvatures (i.e., scoliosis, kyphosis, and/or lordosis); tumor, pseudoarthrosis; and failed previous fusion in skeletally mature patients.

The VIPER PEEK rods are only indicated for fusion procedures for spinal stenosis with instability (no greater than Grade I spondylolisthesis) from L1-S1 in skeletally mature patients.

CONTRAINDICATIONS

Disease conditions that have been shown to be safely and predictably managed without the use of internal fixation devices are relative contraindications to the use of these devices.

Active systemic infection or infection localized to the site of the proposed implantation are contraindications to implantation.

Severe osteoporosis is a relative contraindication because it may prevent adequate fixation of spinal anchors and thus preclude the use of this or any other spinal instrumentation system.

Any entity or condition that totally precludes the possibility of fusion, i.e., cancer, kidney dialysis, or osteopenia is a relative contraindication. Other relative contraindications include obesity, certain degenerative diseases, and foreign body sensitivity. In addition, the patient's occupation or activity level or mental capacity may be relative contraindications to this surgery. Specifically, patients who because of their occupation or lifestyle, or because of conditions such as mental illness, alcoholism, or drug abuse, may place undue stresses on the implant during bony healing and may be at higher risk for implant failure. See also the WARNINGS, PRECAUTIONS AND POSSIBLE ADVERSE EFFECTS CONCERNING TEMPORARY METALLIC INTERNAL FIXATION DEVICES section of this insert.

WARNINGS, PRECAUTIONS, AND POSSIBLE ADVERSE EFFECTS CONCERNING TEMPORARY METALLIC INTERNAL FIXATION DEVICES

Following are specific warnings, precautions, and possible adverse effects that should be understood by the surgeon and explained to the patient. These warnings do not include all adverse effects that can occur with surgery in general, but are important considerations particular to metallic internal fixation devices. General surgical risks should be explained to the patient prior to surgery.

WARNINGS

PEEK RODS AND DDD. The safety and effectiveness of the EXPEDIUM and VIPER Spine System PEEK Rods for the treatment of degenerative disc disease has not been established.

CORRECT SELECTION OF THE IMPLANT IS EXTREMELY IMPORTANT. The potential for satisfactory fixation is increased by the selection of the proper size, shape, and design of the implant. While proper selection can help minimize risks, the size and shape of human bones present limitations on the size, shape and strength of implants. Metallic internal fixation devices cannot withstand activity levels equal to those placed on normal healthy bone. No implant can be expected to withstand indefinitely the unsupported stress of full weight bearing.

IMPLANTS CAN BREAK WHEN SUBJECTED TO THE INCREASED LOADING ASSOCIATED WITH DELAYED UNION OR NONUNION. Internal fixation appliances are load-sharing devices which are used to obtain alignment until normal healing occurs. If healing is delayed, or does not occur, the implant may eventually break due to metal fatigue. The degree or success of union, loads produced by weight bearing, and activity levels will, among other conditions, dictate the longevity of the implant. Notches, scratches or bending of the implant during the course of surgery may also contribute to early failure. Patients should be fully informed of the risks of implant failure.

MIXING METALS CAN CAUSE CORROSION. There are many forms of corrosion damage and several of these occur on metals surgically implanted in humans. General or uniform corrosion is present on all implanted metals and alloys. The rate of corrosive attack on metal implant devices is usually very low due to the presence of passive surface films. Dissimilar metals in contact, such as titanium and stainless steel, accelerate the corrosion process of stainless steel and more rapid attack occurs. The presence of corrosion often accelerates fatigue fracture of implants. The amount of metal compounds released into the body system will also increase. Internal fixation devices, such as rods, hooks, etc., which come into contact with other metal objects, must be made from like or compatible metals.

PATIENT SELECTION. In selecting patients for internal fixation devices, the following factors can be of extreme importance to the eventual success of the procedure:

The patient's weight. An overweight or obese patient can produce loads on the device that can lead to failure of the appliance and the operation.

The patient's occupation or activity. If the patient is involved in an occupation or activity that includes heavy lifting, muscle strain, twisting, repetitive bending, stooping, running, substantial walking, or manual labor, he/she should not return to these activities until the bone is fully healed. Even with full healing, the patient may not be able to return to these activities successfully.

A condition of senility, mental illness, alcoholism, or drug abuse. These conditions, among others, may cause the patient to ignore certain necessary limitations and precautions in the use of the appliance, leading to implant failure or other complications.

Certain degenerative diseases. In some cases, the progression of degenerative disease may be so advanced at the time of implantation that it may substantially decrease the expected useful life of the appliance. For such cases, orthopaedic devices can only be considered a delaying technique or temporary remedy.

Foreign body sensitivity. The surgeon is advised that no preoperative test can completely exclude the possibility of sensitivity or allergic reaction. Patients can develop sensitivity or allergy after implants have been in the body for a period of time.

Smoking. Patients who smoke have been observed to experience higher rates of pseudarthrosis following surgical procedures where bone graft is used. Additionally, smoking has been shown to cause diffuse degeneration of intervertebral discs. Progressive degeneration of adjacent segments caused by smoking can lead to late clinical failure (recurring pain) even after successful fusion and initial clinical improvement.

PRECAUTIONS

SURGICAL IMPLANTS MUST NEVER BE REUSED. An explanted metal implant should never be reimplanted. Even though the device appears undamaged, it may have small defects and internal stress patterns which may lead to early breakage. Reuse can compromise device performance and patient safety. Reuse of single use devices can also cause cross-contamination leading to patient infection.

CORRECT HANDLING OF THE IMPLANT IS EXTREMELY IMPORTANT. Contouring of metal implants should only be done with proper equipment. The operating surgeon should avoid any notching, scratching or reverse bending of the devices when contouring. Alterations will produce defects in surface finish and internal stresses which may become the focal point for eventual breakage of the implant. Bending of screws will significantly decrease the fatigue life and may cause failure.

CONSIDERATIONS FOR REMOVAL OF THE IMPLANT AFTER HEALING. If the device is not removed after the completion of its intended use, any of the following complications may occur: (1) Corrosion, with localized tissue reaction or pain; (2) Migration of implant position resulting in injury; (3) Risk of additional injury from postoperative trauma; (4) Bending, loosening, and/or breakage, which could make removal impractical or difficult; (5) Pain, discomfort, or abnormal sensations due to the presence of the device; (6) Possible increased risk of infection; and (7) Bone loss due to stress shielding. The surgeon should carefully weigh the risks versus benefits when deciding whether to remove the implant. Implant removal should be followed by adequate postoperative management to avoid refracture. If the patient is older and has a low activity level, the surgeon may choose not to remove the implant thus eliminating the risks involved with a second surgery.

ADEQUATELY INSTRUCT THE PATIENT. Postoperative care and the patient's ability and willingness to follow instructions are among the most important aspects of successful bone healing. The patient must be made aware of the limitations of the implant, and instructed to limit and restrict physical activities, especially lifting and twisting motions and any type of sports participation. The patient should understand that a metallic implant is not as strong as normal healthy bone and could loosen, bend and/or break if excessive demands are placed on it, especially in the absence of complete bone healing. Implants displaced or damaged by improper activities may migrate and damage the nerves or blood vessels. An active, debilitated, or demented patient who cannot properly use weight-supporting devices may be particularly at risk during postoperative rehabilitation.

CORRECT PLACEMENT OF ANTERIOR SPINAL IMPLANT. Due to the proximity of vascular and neurologic structures to the implantation site, there are risks of serious or fatal hemorrhage and risks of neurologic damage with the use of this product. Serious or fatal hemorrhage may occur if the great vessels are eroded or punctured during implantation or are subsequently damaged due to breakage of implants, migration of implants or if pulsatile erosion of the vessels occurs because of close apposition of the implants.

Refer to the Surgical Technique Manual for COUGAR® LS Lateral Access System for detailed instructions for use, complete information on contraindications, warnings, precautions and adverse events associated with the use of this system.



3D MIS Correction Set

Limited Warranty and Disclaimer: DePuy Spine products are sold with a limited warranty to the original purchaser against defects in workmanship and materials. Any other express or implied warranties, including warranties of merchantability or fitness, are hereby disclaimed.

WARNING: In the USA, this product has labeling limitations. See package insert for complete information.

CAUTION: USA Law restricts these devices to sale by or on the order of a physician.

To order in the US, call DePuy Spine Customer Service (1-800-227-6633).

Not all products are currently available in all markets.

DePuy Spine, Inc.
325 Paramount Drive
Raynham, MA 02767
USA
Tel: +1 (800) 227-6633

www.depuy.com

©DePuy Spine, Inc., 2011. All rights reserved.
MI09-20-002 4/11 ADDB/RPI



never stop moving®

